



Received: 2016.06.08  
Accepted: 2016.08.16  
Published: 2017.04.13

**Authors' Contribution:**

- A** Study Design
- B** Data Collection
- C** Statistical Analysis
- D** Data Interpretation
- E** Manuscript Preparation
- F** Literature Search
- G** Funds Collection

## Usefulness of Apparent Diffusion Coefficient of Diffusion-Weighted Imaging for Differential Diagnosis of Primary Solid and Cystic Renal Masses

Mehmet Öztürk<sup>1A</sup>, Afra Ekinci<sup>2B</sup>, Şenol Fatih Elbir<sup>3BC</sup>, Aylin Okur<sup>4DE</sup>, Serap Doğan<sup>2EF</sup>, Ökkeş İbrahim Karahan<sup>2EG</sup>

<sup>1</sup> Department of Radiology, Diyarbakır Children's Hospital, Diyarbakır, Turkey

<sup>2</sup> Department of Radiology, Erciyes University Medical Faculty, Kayseri, Turkey

<sup>3</sup> Department of Radiology, Private Gözde Academy Hospital, Malatya, Turkey

<sup>4</sup> Department of Radiology, Bozok University Medical Faculty, Yozgat, Turkey

**Author's address:** Mehmet Öztürk, Department of Radiology, Diyarbakır Children's Hospital, Diyarbakır, Turkey, e-mail: drmehmet4242@gmail.com

### Summary

**Background:**

To evaluate the value of diffusion-weighted imaging (DWI) for distinguishing between benign and malignant renal masses.

**Material/Methods:**

Seventy-five patients with 75 unilateral renal lesions were included, and 75 normal contralateral kidneys served as controls. The lesions were categorized into four groups as malignant cystic, malignant solid, benign cystic and benign solid. The apparent diffusion coefficients (ADCs) were evaluated for two different b values (b=600 s/mm<sup>2</sup> and b=1000 s/mm<sup>2</sup>). Receiving operating characteristic analysis was performed to identify threshold ADCs.

**Results:**

Sensitivity and specificity were 67% and 77% (p=0.003) at the cutoff value of 1.5 for b=600 s/mm<sup>2</sup>, and 79% and 62% (p=0.004) at the cutoff value of 1.99 for b=1000 s/mm<sup>2</sup> as regards the differentiation between solid benign and malignant renal lesions. Sensitivity and specificity were 78% and 79% (p=0.001) at the cutoff value of 3.1 for b=600 s/mm<sup>2</sup>, and 86% and 61% (p=0.003) at the cutoff value of 2.9 for b=1000 s/mm<sup>2</sup> as regards the differentiation between benign and malignant cystic renal lesions.

**Conclusions:**

DWI can be an effective diagnostic method for distinguishing between benign and malignant renal masses.

**MeSH Keywords:**

**Carcinoma, Renal Cell • Diffusion Magnetic Resonance Imaging • Magnetic Resonance Imaging**

**PDF file:**

<http://www.polradiol.com/abstract/index/idArt/899984>

### Background

Magnetic resonance imaging (MRI) is a useful diagnostic modality for evaluating renal masses. It offers a high contrast resolution, provides triplanar images and displays characteristics of soft tissues [1,2]. Primary renal masses of benign and malignant etiology can be cystic or solid. However, a renal mass with necrotic or cystic components may reveal scant or no contrast enhancement. Thus, some renal tumors may mimic benign, complex kidney cysts on conventional MRI sequences [3].

Diffusion-weighted imaging (DWI) is a noninvasive method that is based on the movement of water molecules across tissues. The sensitivity of DWI changes depending of different b values. The term "b value" indicates the power of the diffusion sensitizer gradient [3]. Detection of a greater signal loss with higher b values suggests that diffusion is not only under the influence of water molecules, but it may also be affected by tissue perfusion. Diffusion-weighted imaging and the apparent diffusion coefficient (ADC) may provide additional information to that obtained from conventional MRI. In the current literature, there is scarce

data on the application of DWI for the assessment of renal masses [4–6].

The aim of the present study was to investigate the value of DWI and the ADC in the differential diagnosis of benign and malignant renal masses.

## Material and Methods

### Patients

The study was conducted according to the principles of the Helsinki Declaration and approved by the local Institutional Review Board. Written informed consent was obtained from all subjects. This study involved 80 patients, aged 20 to 82 years. All patients had been diagnosed with renal masses by abdominal ultrasound and abdominal computed tomography (CT), and abdominal MRI and DWI were performed routinely. The study excluded three participants who were unable to keep breathing and two patients who were noncompliant with the protocol.

The diagnoses of renal cell carcinoma (RCC), malignant mesenchymal tumor, transitional cell carcinoma, abscess, oncocytoma and undifferentiated carcinoma were made histopathologically after resection. Patients with simple cysts, hemorrhagic cysts and renal angiomyolipoma (AML) who had not been operated on and existed in addition to typical imaging findings were followed up. The mean duration of follow-up was 36 months.

### Magnetic resonance imaging

Magnetic resonance imaging (MRI) was performed using a 1.5-T scanner (*Gyrosan Intera; Philips, Best, The Netherlands*) with a maximal gradient strength of 30 mT/m and a slew rate of 120 mT/m/ms using a phased-array coil. The imaging procedure was implemented as reported in the relevant literature [4]. Before DWI, axial spoiled gradient-echo (fast-field echo) T1-weighted (TR/TE: 169/4, section thickness: 7 mm, intersection gap: 1 mm), gradient-echo T1-weighted in-phase and out-of-phase (TR/TE: 80/4.2–3.6) and axial turbo spin-echo T2-weighted sequences with fat saturation (TR/TE: 700/80, section thickness: 7 mm, intersection gap: 1 mm) were performed. Transverse breath-hold DWI was performed using a single-shot spin-echo echo-planar sequence (TR: 3656 ms, TE: 89 ms [b=1000 s/mm<sup>2</sup>], TR: 2673, TE: 60 [b=600 s/mm<sup>2</sup>], matrix: 128×256, field of view: 35–40 cm, section thickness: 7 mm, intersection gap: 1 mm). Before contrast material was administered, b values were set at 0, 600 and 1000 s/mm<sup>2</sup>. The apparent diffusion coefficient (ADC) maps were reconstructed at a workstation (View Forum R4.1; Philips). After DWI, contrast-enhanced dynamic imaging was performed with an axial gradient-echo T1-weighted MRI sequence after the administration of gadopentetate dimeglumine at a dose of 0.1 mmol/kg of body weight as a bolus injection at 30 s, 60 s, 120 s and 5 min.

### Image analysis

Two radiologists (10 and 8 years of experience of abdominal radiology) who were blinded to the histopathologic analysis

and radiologic follow-up results manually defined multiple regions of interest (ROIs) together at the workstation. First, they established the largest available ROIs on the renal masses to calculate ADCs of the entire lesions, which included solid and cystic areas. The renal masses that contained both enhancing viable solid tissue and nonenhancing necrotic or cystic areas were defined on the unenhanced and contrast-enhanced T1-weighted images and the subtracted images. Depending on the lesion size, the ROIs were outlined in up to three sections for each renal mass and each viable solid area or necrotic or cystic tumor region. When more than one ROI was placed in a mass or area, the mean ADC was measured and indicated as the ADC for that mass or area. The DWI images, including the images obtained with b values of 600 and 1000 s/mm<sup>2</sup>, were evaluated by both radiologists together. The ADCs were calculated from each lesion for both b=600 and b=1000 s/mm<sup>2</sup> gradient values using three circumferential ROIs. The ROIs were placed in the normal parenchyma of each kidney to define the ADC. The ADCs of the normal kidney parenchyma for the different b values were measured and compared with the ADCs of the renal masses.

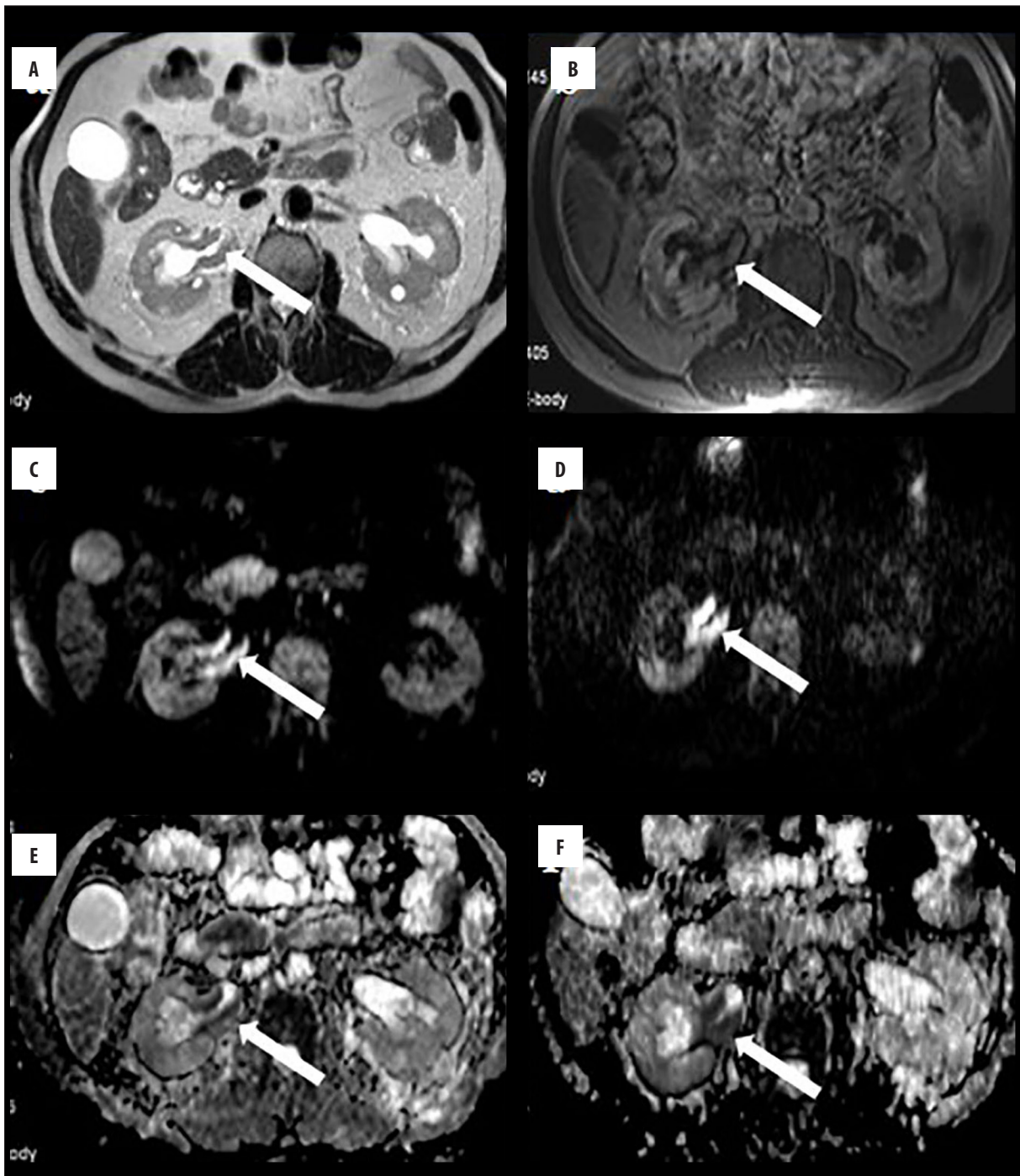
### Statistical analysis

Data were analyzed using the IBM Statistical Package for Social Sciences v16 (SPSS Inc., Chicago, IL, USA). A normal distribution of the quantitative data was checked using the Kolmogorov-Smirnov test. Parametric tests were applied to normally distributed data and otherwise non-parametric tests were used. The unpaired Student's t-test was used to determine the significance of the differences in ADCs between benign solid and malignant solid renal lesions as well as between benign cystic and malignant cystic renal lesions. The receiver-operating characteristic (ROC) curve method was used to identify a suitable cutoff for the diagnostic tests. The ROC analysis was applied twice: first for all lesions including AMLs and then for all lesions excluding AMLs. Group comparisons were evaluated using the unpaired Student's t-test. A p-value of <0.05 was considered to indicate statistical significance. The sensitivity and specificity values for distinguishing benign renal lesions from malignant lesions using DWI, including images with b values of 600 and 1000 s/mm<sup>2</sup>, were measured.

## Results

The renal lesions were categorized into malignant cystic, malignant solid, benign cystic and benign solid groups. The malignant solid lesions included RCC (n=34), transitional cell carcinoma (n=7) (Figure 1), MMT (n=1) and undifferentiated carcinoma (n=1). The benign solid lesions included AML (n=7), oncocytoma (n=7) and an abscess capsule (n=1). The malignant cystic lesions included RCC with cystic or necrotic areas (n=11), cystic RCC (n=2) (Figure 2) and MMT with cystic or necrotic areas (n=1). The benign cystic lesions consisted of simple cysts (n=16), hemorrhagic cysts (n=1) and a central area abscess (n=1).

The mean ADCs of normal kidney parenchyma using b=600 and 1000 s/mm<sup>2</sup> were  $2.50 \pm 0.33 \times 10^{-3}$  mm<sup>2</sup>/s and  $2.25 \pm 0.44 \times 10^{-3}$  mm<sup>2</sup>/s, respectively. Table 1 shows the mean ADCs of the solid malignant and solid benign renal

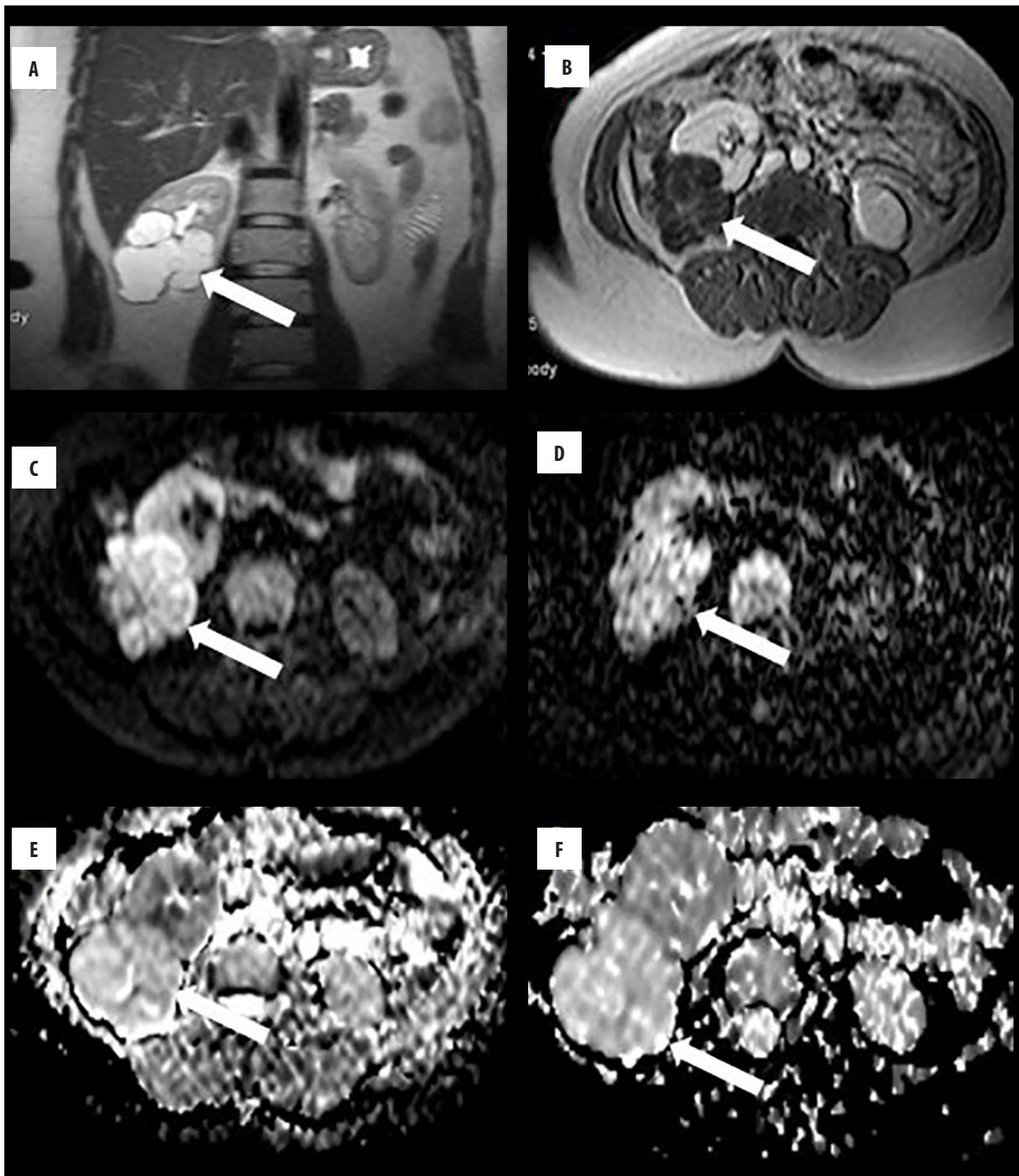


**Figure 1.** A 66-year-old man with transitional cell carcinoma in the right kidney. (A) T2-weighted axial image shows an isointense right renal pelvic mass. (B) Gadolinium-enhanced fat-suppressed T1-weighted magnetic resonance image demonstrates enhanced right renal pelvic mass. (C, D) Axial diffusion-weighted images with b values of 600 and 1000 s/mm<sup>2</sup> show markedly high signal intensity. (E, F) The apparent diffusion coefficients are  $1.3 \times 10^{-3}$  and  $1.03 \times 10^{-3}$  mm<sup>2</sup>/s at b=600 and 1000 s/mm<sup>2</sup>, respectively.

lesions. ROC analysis was implemented for both b=600 and b=1000 s/mm<sup>2</sup>. When AMLs were included, the sensitivity and specificity values were 67% and 77% (p=0.003) at the critical value of 1.5 for b=600 s/mm<sup>2</sup>, whereas they were 79% and 62% (p=0.004) at the critical value of 1.99 for b=1000 s/mm<sup>2</sup>. When AMLs were not taken into account, the sensitivity and specificity values were 67% and 83% (p=0.001) at the critical value of 1.5 for

b=600 s/mm<sup>2</sup>, while they were 81% and 83% (p=0.001), respectively at the critical value of 1.49 for b=1000 s/mm<sup>2</sup> (Figure 3). ROC analysis exhibited 95% confidence intervals of 0.734 to 0.843 for b=600 s/mm<sup>2</sup> and 0.753 to 0.668 for b=1000 s/mm<sup>2</sup>, if AMLs were excluded.

Table 2 displays the mean ADC values for benign and malignant cystic renal lesions. ROC analysis was performed for



**Figure 2.** A 38-year-old woman with cystic renal cell carcinoma in the right kidney. (A) T2-weighted coronal image shows a cystic mass. (B) Gadolinium-enhanced T1-weighted magnetic resonance image demonstrates a complex cystic mass that contains an enhanced wall and numerous septae. (C, D) Axial diffusion-weighted images at b values of 600 and 1000 s/mm<sup>2</sup> show increased signal intensity. (E, F) The apparent diffusion coefficients are  $2.23 \times 10^{-3}$  and  $2.03 \times 10^{-3}$  mm<sup>2</sup>/s at b = 600 and 1000 s/mm<sup>2</sup>, respectively.

b=600 and 1000 s/mm<sup>2</sup>. The sensitivity and specificity values were 78% and 79% (p=0.001) at the critical value of 3.1 for b=600 s/mm<sup>2</sup>. They were 86% and 61% (p=0.003) at the critical value of 2.9 for b=1000 s/mm<sup>2</sup>, respectively.

## Discussion

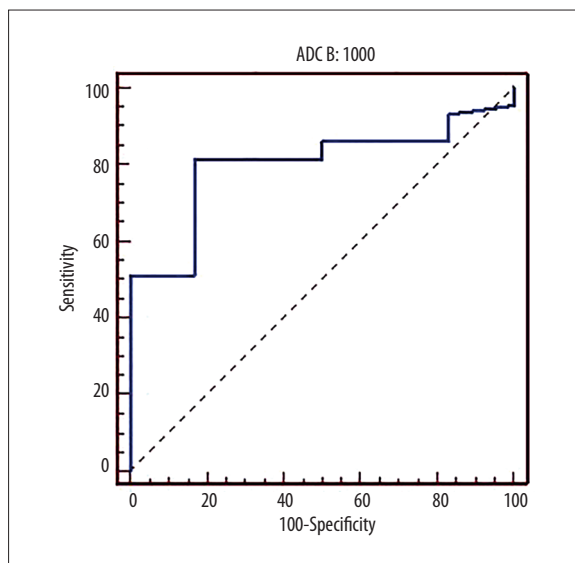
The current study was carried out in order to assess ADC values, derived from diffusion-weighted imaging (DWI), in distinguishing between benign and malignant renal masses. Our results showed that ADC can be a useful parameter for discriminating malignant lesions in both cystic or solid renal masses.

**Table 1.** Mean apparent diffusion coefficients (ADCs) of the solid-malignant and solid-benign renal lesion areas.

Solid renal lesions	b=600 ( $\times 10^{-3}$ mm <sup>2</sup> /s)	b=1000 ( $\times 10^{-3}$ mm <sup>2</sup> /s)
Solid- malignant lesions (n=43)	1.45± 0.49	1.33± 0.49
Solid-benign lesions (n=13)	1.85± 0.50	1.61± 0.59
P value	0.015	0.017

**Table 2.** Mean apparent diffusion coefficients (ADCs) of the cystic-malignant and cystic-benign renal lesion areas.

Cystic renal lesions areas	b=600 ( $\times 10^{-3}$ mm <sup>2</sup> /s)	b=1000 ( $\times 10^{-3}$ mm <sup>2</sup> /s)
Cystic-malignant lesions (n=14)	2.72±0.49	2.49±0.44
Cystic-benign renal lesions (n=18)	3.58±0.83	3.08±0.86
P value	0.001	0.001

**Figure 3.** Receiver operating characteristic curve for apparent diffusion coefficients. The area under the curve represents the probability that a lesion will be classified as solid, benign or solid, malignant with respect to the apparent diffusion coefficient with a b value of 1000 s/mm<sup>2</sup> is 1.49 (renal angiomyolipomas were excluded).

Diffusion-weighted imaging (DWI) is based on the random motion of water molecules. The extent of tissue cellularity and the presence of intact cell membrane help to outline the impedance of water molecule diffusion. This impedance of water molecule diffusion can be quantitatively assessed using ADC values [7].

Angiomyolipoma and oncocytoma are the main benign, solid renal masses, while the common malignant tumors of the kidney are RCC, transitional cell carcinoma and lymphoma. In 1986, Bosniak created a classification system for renal cystic lesions that necessitate surgical treatment [8]. Even though the Bosniak renal cyst classification system was based on CT findings only, CT and MRI images of the vast majority of cystic renal masses exhibited similar results [9]. Benign cystic masses are mostly asymptomatic

and they are frequently diagnosed incidentally. However, RCC and loculated infections must be included in the differential diagnosis of such lesions. Ultrasound, CT and MRI can be used alone or in combination for characterization of solid or cystic renal masses [10,11].

The movement of water molecules, owing to the effect of heat on biological tissues, is termed as diffusion or Brownian motion. Diffusion of the microscopic movement of water molecules in the human body is dependent on blood and microcirculation (perfusion) in capillaries. The diffusion coefficient, which is linked to the movement at the molecular level, is under the influence of intracellular organelles, macromolecules, membranes, viscosity, environmental temperature and magnetic sensitivity of tissues. Therefore, ADC maps can be used instead of the diffusion coefficient [12]. Physiological artifacts resulting from intestinal peristalsis, cardiac pulsation and respiratory movements have been reduced with the development of DWI echo-planar imaging techniques. DWI is a rapid process that does not require contrast material, which provides additional significant qualitative and quantitative information to the conventional imaging sequences. Thus, it is particularly advantageous for patients with renal insufficiency and patients at risk of nephrogenic systemic fibrosis [13].

In previous studies, ADCs of normal parenchyma were found to be 1.78 to 3.56  $\times 10^{-3}$  mm<sup>2</sup>/s using different b values (such as 600, 800, and 1000 s/mm<sup>2</sup>). In the present study, the ADC values (2.50  $\pm$  0.33  $\times 10^{-3}$  mm<sup>2</sup>/s at b=600 s/mm<sup>2</sup>; 2.25  $\pm$  0.44  $\times 10^{-3}$  mm<sup>2</sup>/s at b=1000 s/mm<sup>2</sup>) were similar to those in the relevant literature. Numerical differences in ADCs can be attributed to methodological and technical variables, changes in gradient, imaging techniques and selection of different b values [14–16].

In recent studies on solid masses that used b=500 s/mm<sup>2</sup>, ADCs were found to be 1.55  $\pm$  0.20  $\times 10^{-3}$  mm<sup>2</sup>/s and 1.7  $\times$  0.48  $\times 10^{-3}$  mm<sup>2</sup>/s [17,18]. In another study using b=800 s/mm<sup>2</sup>, ADC was 1.88  $\pm$  0.21  $\times 10^{-3}$  mm<sup>2</sup>/s for all malignant solid masses [19]. Doğanay et al. [20] conducted studies using low (100 s/mm<sup>2</sup>) and high (600 and 1000 s/mm<sup>2</sup>) b values, and all masses were separated

into two groups of malignant or benign tumors without discrimination between solid and cystic lesions. For benign cysts ( $n=35$ ), the ADCs at  $b=100$ ,  $600$  and  $1000$   $\text{s/mm}^2$  were  $2.88 \pm 0.88 \times 10^{-3}$ ,  $2.58 \pm 0.91 \times 10^{-3}$  and  $2.10 \pm 0.93 \times 10^{-3}$   $\text{mm}^2/\text{s}$ , respectively. In the malignant masses, the ADCs at  $b=100$ ,  $600$  and  $1000$   $\text{s/mm}^2$  were  $2.74 \pm 0.58 \times 10^{-3}$ ,  $2.09 \pm 0.91 \times 10^{-3}$  and  $1.66 \pm 0.51 \times 10^{-3}$   $\text{mm}^2/\text{s}$ , respectively. The difference between the ADCs measured at  $b=600$  and  $100$   $\text{s/mm}^2$  was statistically significant. Nevertheless, there was no statistically significant difference for ADC values at  $b=1000$   $\text{s/mm}^2$ .

In contrast to previous studies, all masses in the present study were separated into four groups as benign cystic, malignant cystic, benign solid and malignant solid. The ADCs of the benign solid masses at  $b=600$  and  $1000$   $\text{s/mm}^2$  were higher than those of the malignant solid masses. The difference in the ADCs was associated with the fact that malignant lesions contain more cells than benign lesions. In several studies, the ADCs of AML were reported as  $1.23$  to  $1.81 \times 10^{-3}$   $\text{mm}^2/\text{s}$ , which is less than in RCC and normal kidney parenchyma [4,21,22]. In the current study, the ADC was  $1.79 \pm 0.17 \times 10^{-3}$   $\text{mm}^2/\text{s}$ . Diffusion may be restricted in AML due to a high muscle and adipose content. This is important since lesions with low ADCs may mimic malignant lesions. Consequently, the ROC analyses of the current study were applied twice: initially, the AML values were included, and were later excluded. The highest values were noted in the ROC analyses conducted at  $b=1000$   $\text{s/mm}^2$ , excluding the AML values (sensitivity 81%, specificity 83%). These data imply that a diagnosis of AML can be confirmed using other methods such as CT or in-phase/out-of-phase MRI. Hence, DWI examinations should exclude AML particularly for distinguishing benign and malignant solid renal masses [4,22].

Zhang et al. reported that ADC was  $2.2 \pm 0.63 \times 10^{-3}$   $\text{mm}^2/\text{s}$  at  $b=500$   $\text{s/mm}^2$  in malignant necrotic or cystic tumor areas and  $3.26 \pm 0.61 \times 10^{-3}$   $\text{mm}^2/\text{s}$  in benign cysts [4]. Doğanay et al. found that ADC was  $2.52 \pm 0.52 \times 10^{-3}$   $\text{mm}^2/\text{s}$  in cystic RCC and  $3.26 \pm 0.49 \times 10^{-3}$   $\text{mm}^2/\text{s}$  in benign cysts [20]. In a study where the  $b$  value was  $800$   $\text{s/mm}^2$  [17], the

ADC of cystic RCC was  $2.02 \pm 0.12 \times 10^{-3}$   $\text{mm}^2/\text{s}$  and the ADC of benign cysts was  $2.76 \pm 0.32 \times 10^{-3}$   $\text{mm}^2/\text{s}$  with a threshold value of  $2.22 \times 10^{-3}$   $\text{mm}^2/\text{s}$ . The sensitivity and specificity values were 94% and 87%, respectively. In a study using  $b=500$  and  $1000$   $\text{s/mm}^2$ , Inci et al. found that the ADCs of Bosniak category I cysts were higher than those of Bosniak categories II and III [14]. In the present study, cystic masses were separated into malignant and benign groups and such a division was not used in previous studies. However, our findings are consistent with previous publications. Benign cystic lesions had increased ADCs compared to malignant cystic lesions possibly due to the cellular, necrotic and blood content of the tissue. This finding is particularly important for the diagnosis of cystic masses where contrast agent cannot be introduced, optimal contrast imaging cannot be accomplished or the mural nodule cannot be clearly visualized.

In a recent publication, DWI has been utilized for kidneys after transplantation and the most useful parameter was ADC in the renal cortex, which was associated with glomerular filtration rate. We foresee that the use of DWI and ADC for renal pathologies may become more popular in the near future [23].

The present study has some limitations. First, the mainstay of diagnosis for a benign lesion was based on a prolonged stable follow-up. Second, our sample size in each subgroup is relatively small. Third, technical limitations of DWI such as poor anatomical localization and insufficient spatial resolution must be kept in mind. In particular, the use of a high  $b$  value may have resulted in a lower signal-to-noise ratio and increased anatomic distortion.

## Conclusions

In conclusion, we suggest that ADC derived from DWI can be a useful alternative in the evaluation of renal masses, especially for distinguishing between cystic benign lesions from cystic RCC. Thanks to its speed and no need for a contrast agent, DWI may aid in the discrimination between benign and malignant lesions of solid or cystic content.

## References:

1. Semelka RC, Shoenut JP, Kroeker MA et al: Renal lesions: Controlled comparison between CT and 1.5-T MR imaging with nonenhanced and gadolinium-enhanced fat-suppressed spin-echo and breath-hold FLASH techniques. *Radiology*, 1992; 182: 425–30
2. Bosniak MA: Problems in the radiologic diagnosis of renal parenchymal tumors. *Urol Clin North Am*, 1993; 20: 217–30
3. Hecht EM, Israel GM, Krinsky GA et al: Renal masses: Quantitative analysis of enhancement with signal intensity measurements versus qualitative analysis of enhancement with image subtraction for diagnosing malignancy at MR imaging. *Radiology*, 2004; 232: 373–78
4. Zhan J, Tehrani YM, Wang L et al: Renal masses: characterization with diffusion-weighted MR imaging – a preliminary experience. *Radiology*, 2008; 247: 458–64
5. Taouli B, Thakur RK, Mannelli L et al: Renal lesions: Characterization with diffusion-weighted imaging versus contrast-enhanced MR imaging. *Radiology*, 2009; 251: 398–407
6. Sevcenco S, Heinz-Peer G, Pohnhold L et al: Utility and limitations of 3-Tesla diffusion-weighted magnetic resonance imaging for differentiation of renal tumors. *Eur J Radiol*, 2014; 83: 909–13
7. Rana S, Albayram S, Lin DD, Yousem DM: Diffusion-weighted imaging and apparent diffusion coefficient maps in a case of intracerebral abscess with ventricular extension. *Am J Neuroradiol*, 2002; 23: 109–12
8. Bosniak MA: The current radiological approach to renal cysts. *Radiology*, 1986; 158: 1–10
9. Balci NC, Semelka RC, Patt RH et al: Complex renal cysts: findings on MR imaging. *Am J Roentgenol*, 1999; 172: 1495–500
10. Semelka RC, Hricak H, Stevens SK et al: Combined gadolinium-enhanced and fat-saturation MR imaging of renal masses. *Radiology*, 1991; 178: 803–9
11. Ho VB, Allen SF, Hood MN, Choyke PL: Renal masses: Quantitative assessment of enhancement with dynamic MR imaging. *Radiology*, 2002; 224: 695–700
12. Le Bihan D: Molecular diffusion nuclear magnetic resonance imaging. *Magn Reson Q*, 1991; 7: 1–30
13. Turner R, Le Bihan D, Maier J et al: Echo planar imaging of intravoxel motion. *Radiology*, 1990; 17: 407–14

14. Inci E, Hocaoglu E, Aydin S, Cimilli T: Diffusion-weighted magnetic resonance imaging in evaluation of primary solid and cystic renal masses using the Bosniak classification. *Eur J Radiol*, 2012; 81: 815–20
15. Yu X, Lin M, Ouyang H et al: Application of ADC measurement in a characterization of renal cell carcinomas with different pathological types and grades by 3.0T diffusion weighted MRI. *Eur J Radiol*, 2012; 81: 3061–66
16. Göya C, Hamidi C, Bozkurt Y et al: The role of apparent diffusion coefficient quantification in differentiating benign and malignant renal masses by 3 Tesla magnetic resonance imaging. *Balkan Med J*, 2015; 32: 273–78
17. Cova M, Squillaci E, Stacul F et al: Diffusion-weighted MRI in the evaluation of renal lesions: Preliminary results. *Br J Radiol*, 2004; 77: 851–57
18. Squillaci E, Manenti G, Di Stefano F et al: Diffusion-weighted MR imaging in the evaluation of renal tumours. *J Exp Clin Cancer Res*, 2004; 23: 39–45
19. Sandrasegaran K, Sundaram CP, Ramaswamy R et al: Usefulness of diffusion-weighted imaging in the evaluation of renal masses. *Am J Roentgenol*, 2010; 194: 438–45
20. Doğanay S, Kocakoç E, Çiçekçi M et al: Ability and utility of diffusion-weighted MRI with different b values in the evaluation of benign and malignant renal lesions. *Clin Radiol*, 2011; 66: 420–25
21. Yoshikawa T, Kawamitsu H, Mitchell DG et al: ADC measurement of abdominal organs and lesions using parallel imaging technique. *Am J Roentgenol*, 2006; 187: 1521–30
22. Koh DM, Collins DJ: Diffusion-weighted MRI in the body: Applications and challenges in oncology. *Am J Roentgenol*, 2007; 188: 1622–35
23. Wypych-Klunder K, Adamowicz A, Lemanowicz A et al: Diffusion-weighted MR imaging of transplanted kidneys: Preliminary report. *Pol J Radiol*, 2014; 79: 94–98