

Available online at [www.sciencedirect.com](http://www.sciencedirect.com)

journal homepage: [www.elsevier.com/locate/radcr](http://www.elsevier.com/locate/radcr)

## Case Report

# Could ultrasound-guided cryoablation be used to manage “low-risk” DCIS?: a feasibility case report <sup>☆,☆☆</sup>

Michael J. Plaza, MD<sup>a,\*</sup>, Denzel A. Cole, MD<sup>b</sup>

<sup>a</sup>Diagnostic Center for Women, LLC, 7500 SW 87th Ave, Suite 100, Miami, FL 33173 USA

<sup>b</sup>Larkin Community Hospital, Miami, FL, USA

### ARTICLE INFO

#### Article history:

Received 29 April 2020

Revised 21 May 2020

Accepted 22 May 2020

### ABSTRACT

Management of ductal carcinoma in-situ (DCIS) is controversial as there is concern that the majority of diagnoses will never become life threatening such that a subset of patients may be overtreated with surgery. Active surveillance is an alternative proposed management strategy; however, we cannot accurately predict which DCIS will never progress to invasive disease potentially undertreating a large proportion of women. We present a case of a 58-year-old female with DCIS successfully treated with only ultrasound-guided cryoablation without resection. A follow-up needle biopsy of the ablation zone was benign and imaging follow-up has demonstrated no evidence of disease at 14-months. Cryoablation of DCIS is feasible with appropriate patient selection and warrants further investigation as an alternative to surgical resection or active surveillance.

© 2020 The Authors. Published by Elsevier Inc. on behalf of University of Washington.

This is an open access article under the CC BY-NC-ND license.

(<http://creativecommons.org/licenses/by-nc-nd/4.0/>)

## Introduction

Ductal carcinoma in-situ (DCIS) is an intraepithelial neoplasm of the breast with the potential to progress to invasive carcinoma of the breast. Recently, current opinions differ on the malignant transformation potential of the lesion and whether active surveillance is an appropriate option for this lesion. As less than 40% of untreated DCIS lesions progress to invasive

breast cancer, active surveillance aims to spare the patient from overtreatment with surgical intervention [1]. Others disagree that the criteria used to select patients for active surveillance of “low-risk” DCIS results in undertreatment as more than 20% of these lesions would upgrade to invasive carcinoma [2]. The question arises if cryoablation could potentially represent a middle ground for the management of DCIS as it can effectively treat DCIS, yet is minimally invasive and less costly compared to surgery.

<sup>☆</sup> Competing interests: Michael J. Plaza is on the medical advisory board for Sanarus Technologies.

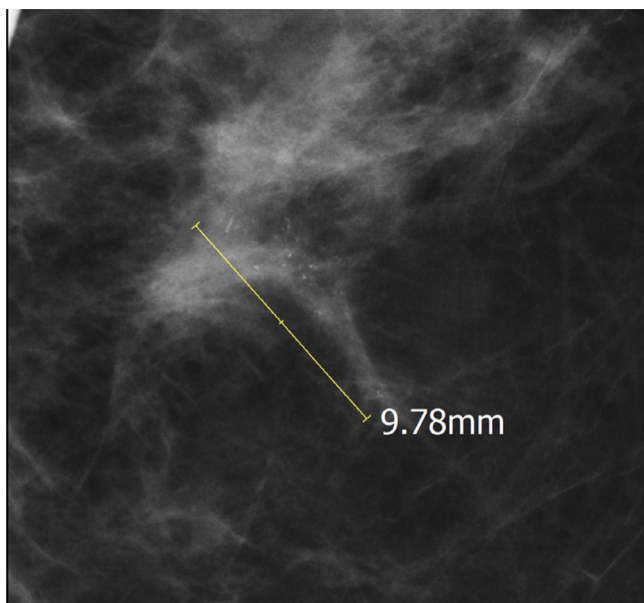
<sup>☆☆</sup> IRB Statement: No IRB approval required.

\* Corresponding author.

E-mail address: [Michael.j.plaza@gmail.com](mailto:Michael.j.plaza@gmail.com) (M.J. Plaza).

<https://doi.org/10.1016/j.radcr.2020.05.045>

1930-0433/© 2020 The Authors. Published by Elsevier Inc. on behalf of University of Washington. This is an open access article under the CC BY-NC-ND license. (<http://creativecommons.org/licenses/by-nc-nd/4.0/>)



**Fig. 1** – 58-year-old female left CC magnification view demonstrating pleomorphic calcifications for which subsequent stereotactic biopsy yielded DCIS.

## Case presentation

A 58-year-old female presenting for screening mammogram was found to have grouped pleomorphic calcifications spanning 0.9 cm in the left breast 11-o'clock middle depth which were confirmed on magnification views (Fig. 1). Subsequently, the patient underwent stereotactic biopsy of the lesion which yielded estrogen receptor positive grade 2 DCIS. Magnetic resonance imaging (MRI) evaluation of the lesion confirmed unifocal disease corresponding to an area of focal nonmass enhancement spanning 1.6 cm (Fig. 4A). The patient declined conventional surgical management and was presented with

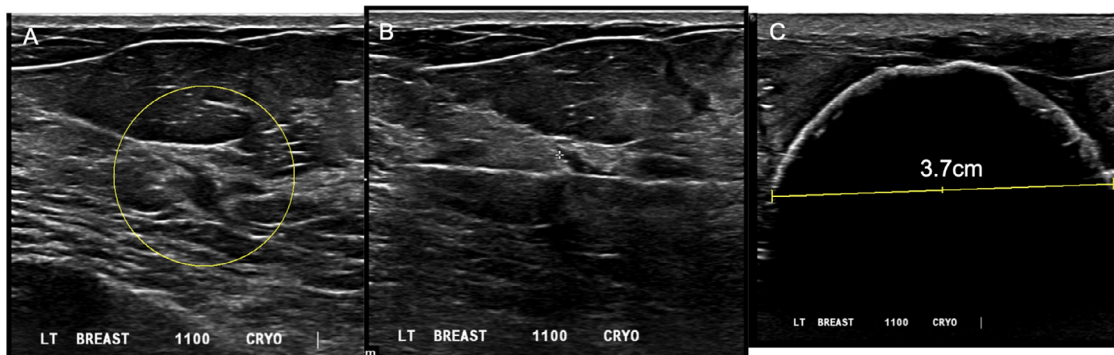the option of treating the lesion with cryoablation. The tumor was determined to be amenable to ultrasound-guided cryoablation as she had residual calcifications, a postbiopsy hematoma, and a biopsy clip there were all visible sonographically (Fig. 2A).

Ultrasound-guided cryoablation was performed using a single probe liquid nitrogen-based system (Visica 2 Treatment System, Sanarus Medical, Pleasanton, CA). An 8-minute freeze–10-minute thaw– 8 minute freeze treatment was performed to generate a  $4.4 \times 3.7 \times 3.7$  ice ball/ablation zone completely engulfing the lesion (Figs. 2B and C). The procedure was successfully completed in the outpatient setting using local anesthesia without any adverse events. The patient declined adjuvant endocrine or radiation therapy.

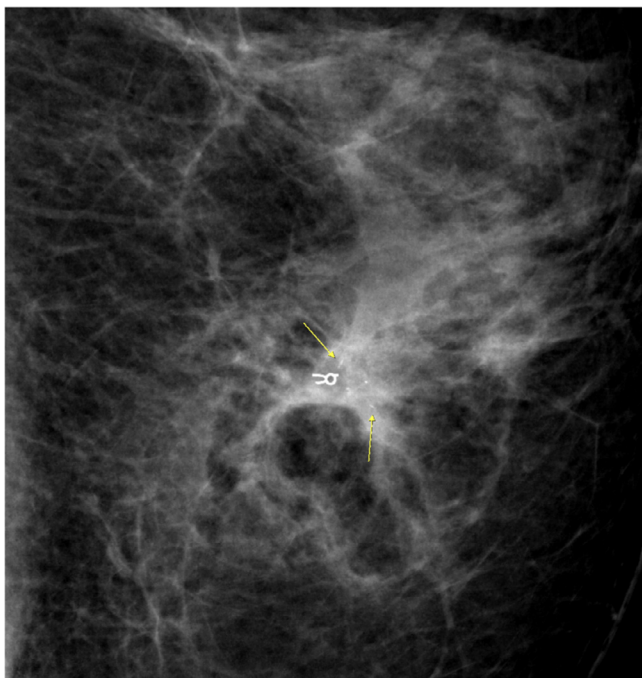
The patient returned at 6 months for follow-up mammography which revealed residual pleomorphic calcifications unchanged from before the cryoablation (Fig. 3). However, 6-month follow-up post cryoablation MRI demonstrated complete resolution of the tumoral nonmass enhancement (Fig. 4B). Given it was unclear whether the calcifications may represent residual viable disease, a stereotactic biopsy was performed at 8 months post cryoablation. Calcifications were obtained on specimen radiograph, confirming adequate sampling. The subsequent pathology yielded benign breast parenchyma with fibroinflammatory remodeling, a macrophagic response and crystals of calcium oxalate associated with the inflammatory response. This result was benign and concordant with the mammographic findings. At 14-month follow-up mammogram, there was no change in the residual calcifications that remained after the postcryoablation stereotactic biopsy as well as no new suspicious mammographic findings.

## Discussion

Review of the literature investigating cryoablation to treat early stage breast cancer is heterogeneous, but tends to agree that cryoablation should be reserved for invasive breast can-



**Fig. 2** – 58 year old female with DCIS undergoing ultrasound guided cryoablation. (A) Left breast ultrasound depicting the postbiopsy associated hematoma (yellow circle) at site of biopsy proven DCIS. Clip and calcifications were best appreciated during real-time imaging. (B) Cryoprobe traversing the hematoma with tip positioned 2cm past the hematoma such that the target will be centered within the ablation zone. (C) Postcryoablation “iceball” completely engulfing the lesion and demonstrating a short axis measurement of 3.7 cm.



**Fig. 3 – 58-year-old female 6 months postcryoablation treatment for DCIS. Left CC view magnification views demonstrate clip from original stereotactic biopsy and residual calcifications (yellow arrows). Oval lucency reflects fat necrosis from the cryoablation procedure.**

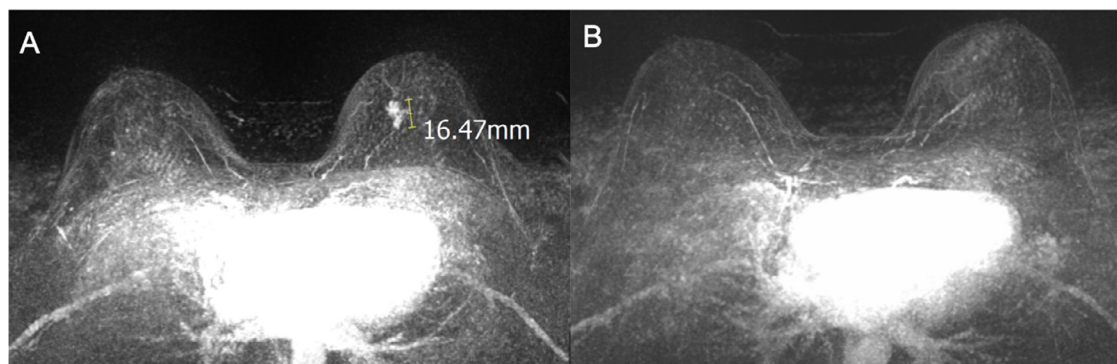
cer with no evidence of an extensive intraductal component [3]. This sentiment is echoed by the inclusion criteria for the 2 ongoing clinical trials in the United States, the FROST [NCT01992250] and Ice3 Trials [NCT02200705]. Both trials were designed to treat prognostically favorable invasive ductal carcinoma meeting the following criteria: unifocal with size  $\leq 1.5$  cm, hormone receptor positive, HER2/neu negative, and clinically node negative. Exclusion criteria include multifocal or multicentric disease, presence of lobular carcinoma, and an extensive intraductal component in the biopsy sample.

The concern is not that DCIS is resistant to cryoablation, but rather that the DCIS extends beyond what is visible at

imaging and may extend outside of the cryoablation-targeted ablation zone. However, with advances in MRI one recent study has shown that MRI is accurate to within 1 mm of measuring the extent of pure DCIS [4]. Another consideration is that if treating DCIS with cryoablation is limited to a certain imaging size, the treatment algorithm can generate “iceball” sizes measuring up to 6.5 cm in long axis and 5 cm in short axis such that ablation margins are well beyond the visible lesion allowing for a large window of error in the image-based determination of disease extent [5]. Last, one must recall that we are in an era of multimodal treatment of breast cancer such that DCIS would not be treated with cryoablation alone, but ideally would rather also include adjuvant radiotherapy and medical therapy. There is evidence that in the setting of multimodal clinical management there may be no oncologic benefit of re-excising breast carcinoma with positive margins in selected patients with low-risk breast cancers [6]. Therefore, it is logical to postulate that even if there is imaging occult disease outside a cryoablation zone, the adjuvant therapies would treat the remaining disease.

Another reasonable concern is that most DCIS is sonographically occult reportedly only visible on ultrasound in 8%-50% of cases; and so most cases would not be amenable to cryoablation as currently cryoablation can only be performed under ultrasound guidance [7]. However, there exist breast biopsy markers (ie, MammotomeHydroMARK) that can be placed at time of stereotactic biopsy or MR-guided biopsy that are visible for 12-15 months under ultrasound; thus, providing a target for ultrasound-guided cryoablation even if the tumor itself is sonographically occult [8].

DCIS most commonly presents as mammographically detected tumoral calcifications and so the case study presented raises the question of the significance of residual calcifications after the cryoablation of DCIS. Residual calcifications post neoadjuvant chemotherapy may represent necrotic material in the tumor bed from successfully treated cancer, fat necrosis, or sequelae of a postbiopsy hematoma rather than viable tumor [9]. Likewise, in our case study the residual calcifications did not reflect viable tumor; rather, it was the postcryoablation MRI that accurately predicted there was no residual disease. In the ACOSOG Z1072 trial evaluating cryoablation of invasive ductal carcinoma with  $\leq 25\%$  intraductal



**Fig. 4 – 58-year-old female with DCIS pre- (A) and 6 months postcryoablation (B) breast MRI 1 minute postcontrast subtraction maximum intensity projection images.**

component followed by surgical resection, the negative predictive value of MRI performed before adjuvant therapies was 81.2% overall and 100% for tumors less than 1.0 cm in size [10]. Furthermore, Machida and colleagues demonstrated a 100% negative predictive value of MRI performed after cryoablation treatment and adjuvant radiotherapy in 54 invasive breast cancers [11]. These results suggest that MRI surveillance may be a viable non-invasive approach for monitoring the postcryoablation breast for local recurrence or incomplete ablation.

## Conclusions

The preliminary results from the FROST trial (follow-up ranging from 6 months–36 months as of 2020), ICE3 trial (follow-up ranging from 6 to 36 months as of 2019), and Kameda Medical Center trial (follow-up ranging from 1 to 13 years as of 2019) are very promising for the treatment of early stage invasive ductal carcinoma demonstrating a recurrence rate of 1.1% in 549 patients treated with cryoablation without surgical resection (Kaufman CS, presented at American Society of Breast Surgeons 2019 annual meeting). A corollary would be that cryoablation would give similar results in treating select cases of DCIS as evidenced by this case presentation and thus warrants further investigation. In time, cryoablation could prove to be a compromise in the debate over the appropriate management for low-risk DCIS.

## REFERENCES

- [1] Cowell CF, Weigelt B, Sakr RA, et al. Progression from ductal carcinoma in situ to invasive breast cancer: revisited. *MolOncol* 2013;7(5):859–69.
- [2] Patel GV, Van Sant EP, Taback B, Ha R. Patient selection for Ductal Carcinoma In Situ Observation Trials: Are the lesions truly low risk? *AJR*. 2018;211:712–13.
- [3] Pusceddu C, Paliogiannis P, Nigir G, Fancellu A. Cryoablation in the management of breast cancer: evidence to date. *Breast Cancer Targets Ther* 2019;11:283–92.
- [4] Preibsch H, Beckmann J, Pawlowski J, et al. Accuracy of breast magnetic resonance imaging compared to mammography in the preoperative detection and measurement of pure ductal carcinoma in situ: a retrospective analysis. *AcadRadiol* 2019;26(6):760–5.
- [5] Ward RC, Lourenco AP, Mainiero MB. Ultrasound-guided breast cancer cryoablation. *AJR* 2019;213:716–22.
- [6] Sorrentino L, Agozzino M, Albasini S, et al. Involved margins after lumpectomy for breast cancer: always to be re-excised? *SurgOnvol* 2019;30:141–6.
- [7] Shehata M, Grimm L, Ballentyne N, et al. Ductal carcinoma in situ: current concepts in biology, imaging, and treatment. *Journal of Breast Imaging* 2019;1(3):166–76.
- [8] Portnow LH, Thornton CM, Milch HS, Mango VL, Morris EA, Saphier NB. Biopsy marker standardization: what's in the name? *AJR* 2019;212:1400–5.
- [9] Feliciano Y, Mamtani A, Morrow M, Stempel MM, Sujata P, Jochelson MS. Do calcifications on mammography after neoadjuvant chemotherapy for breast cancer always need to be excised? *Ann SurgOncol* 2017;24(6):1492–8.
- [10] Simmon RM, Ballman KV, Cox C, et al. A phase II trial exploring the success of cryoablationtherapt in the treatment of invasive breast carcinoma: results from the ACOSOG (Alliance) Z1072. *Ann SurgOncol* 2016;23(8):2438–45.
- [11] Machida Y, Shimauchi A, Igarashi T, Fukuma E. MRI findings after cryoablation of primary breast cancer without surgical resection. *Acad Radiol* 2019;26(6):744–51.