




Case Report

# Surgical removal using V3-radial artery graft-V4 bypass and occipital artery-posterior inferior cerebellar artery bypass for a giant thrombosed aneurysm of vertebral artery compressing brain stem: Case report

Sho Tsunoda, Tomohiro Inoue, Kazuaki Naemura, Atsuya Akabane

Department of Neurosurgery, NTT Medical Center Tokyo, Shinagawa, Tokyo, Japan.

E-mail: \*Sho Tsunoda - s.tsunoda1024@gmail.com; Tomohiro Inoue - t.inouentnsu@gmail.com; Kazuaki Naemura - naemura-tky@umin.ac.jp; Atsuya Akabane - baneab@ybb.ne.jp



**\*Corresponding author:**

Sho Tsunoda,  
Department of Neurosurgery,  
NTT Medical Center Tokyo,  
5-9-22, Higashigotanda,  
Shinagawa-ku, Tokyo 141-0022,  
Japan.

[s.tsunoda1024@gmail.com](mailto:s.tsunoda1024@gmail.com)

Received : 02 July 19

Accepted : 29 October 19

Published : 15 November 19

DOI

10.25259/SNI\_385\_2019

Videos available on:

[www.surgicalneurologyint.com](http://www.surgicalneurologyint.com)

Quick Response Code:



## ABSTRACT

**Background:** Giant thrombosed vertebral artery aneurysms (GTVAs) are difficult disease to treat. Here, we are reporting a case of GTVA successfully treated with excluding the pathological segment and restoring the anterograde blood flow of the parent artery, highlighting the reliable surgical procedure.

**Case Description:** A 55-year-old man with a left GTVA complained of right hemiparesis (manual muscle testing 4/5) represented by hand clumsiness and gait disturbance, in addition to severe left-sided dysesthesia, was referred to our hospital. The posterior inferior cerebellar artery (PICA) was incorporated into the GTVA segment, and the contralateral vertebral artery showed atherosclerotic change. Thus, we decided to treat the aneurysm with aneurysm trapping and thrombectomy, in conjunction with V3-radial artery graft (RAG)-V4 bypass and occipital artery (OA)-PICA bypass through a suboccipital transcondylar approach. The distal end of the dilated segment was meandering and deflecting outwardly to the vicinity of the internal auditory canal and was stretched in an axial direction. Thus, the V4 stump can be transposed to the triangle space made by the medulla, lower cranial nerves, and sigmoid sinus, and we could perform a safe and reliable anastomosis through the corridor. After the surgery, the compression of the brain stem was released, and right hemiparesis was improved completely after rehabilitation. The patient was discharged with a modified Rankin Scale score of 1.

**Conclusion:** Trapping of the aneurysm and thrombectomy are the most radical treatment for GTVA, and if possible, reconstruction of anterograde blood flow with V3-RAG-V4 bypass and OA-PICA bypass is desirable.

**Keywords:** Giant thrombosed aneurysm, Occipital artery-posterior inferior cerebellar artery bypass, Reconstruction, V3-radial artery graft-V4 bypass

## INTRODUCTION

Giant thrombosed vertebral artery aneurysms (GTVAs) are associated with a very poor prognosis once they become symptomatic.<sup>[10]</sup> As they progressively enlarge, GTVAs can cause brain stem compression with severe neurological deficits including hemiparesis or cranial nerves palsy, and ultimately result in catastrophic aneurysmal rupture.<sup>[10,20]</sup> Where possible, trapping of the aneurysm and thrombectomy followed by possible vertebral artery (VA) reconstruction should

be performed to reduce the mass effect of the aneurysm and maintain antegrade blood flow of the V4 portion of the VA (this may include vital perforators that could be thrombosed because of blind-end termination after simple GTVA trapping). However, there are limited reports describing this surgical method.<sup>[6,18]</sup>

Herein, we present a case with GTVA involving the posterior inferior cerebellar artery (PICA), who was treated with trapping of the aneurysm and thrombectomy, in conjunction with a V3-radial artery graft (RAG)-V4 bypass and occipital artery (OA)-PICA bypass. Furthermore, we discuss the safety and reliability of the surgical procedure in detail.

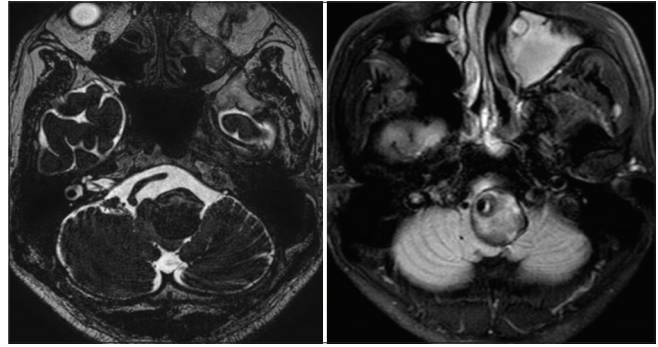
## CASE DESCRIPTION

A 55-year-old man with a left GTVA was referred to our institution for possible surgical treatment. On admission, neurological examinations revealed right hemiparesis (manual muscle testing 4/5) represented by hand clumsiness and gait disturbance, in addition to severe left-sided dysesthesia. These symptoms had progressively worsening over the previous month.

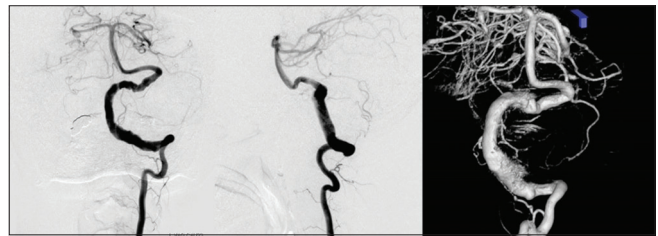
Magnetic resonance imaging (MRI) revealed a GTVA at the left V4 portion (maximum diameter of 30 mm) that severely compressed the medulla oblongata contralaterally. The GTVA also demonstrated a heterogenic signal intensity suggesting different stages of thrombus formation inside the aneurysm [Figure 1]. Digital subtraction angiography (DSA) revealed serpentine intraluminal opacification of the left GTVA, with a normal-appearing distal V4 segment that was pushed up distally, and thus bent toward the internal auditory canal. The PICA was possibly incorporated into the GTVA segment, and thus occluded at its origin. As such, the distal portion of the corresponding PICA was retrogradely opacified through the ipsilateral superior cerebellar artery (SCA) and its pial anastomosis [Figure 2].

After a thorough discussion, trapping of the GTVA and intraluminal thrombectomy, followed by V3-RAG-V4 bypass reconstruction, in conjunction with possible OA-PICA bypass, was indicated [Figure 3].

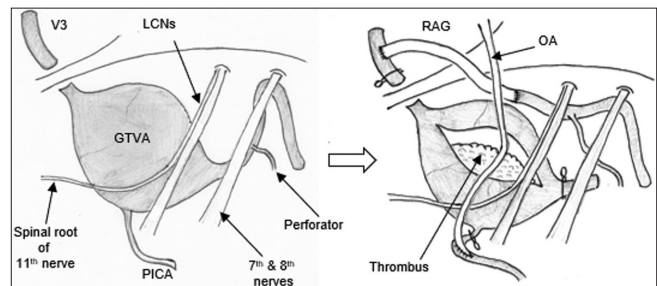
The surgical procedure was performed with motor evoked potentials, somatosensory evoked potentials, and auditory brainstem response monitoring. The patient placed in a park bench position with the left side up, and his head was slightly rotated contralaterally to sublaxate the craniocervical joint so that the left condylar fossa was well exposed for far lateral drilling. An L-shape skin incision was performed, and the skin flap was reflected medially [Figure 4]. The suboccipital muscles were dissected and reflected layer-by-layer, and the OA was simultaneously harvested from the exit of the digastric groove to the entry to the skin, in the layer between the splenius capitis and semispinalis capitis



**Figure 1:** Preoperative magnetic resonance imaging showing giant thrombosed vertebral artery aneurysm at left V4 portion compressing the medulla oblongata contralaterally.



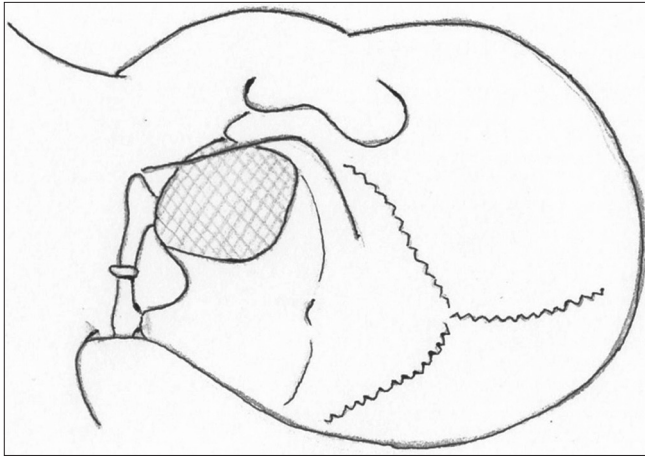
**Figure 2:** Preoperative digital subtraction angiography showing serpentine aneurysm of the left vertebral artery with normal appearance distal V4 segment which was pushed up distally and thus bending toward the internal auditory canal. The posterior inferior cerebellar artery was possibly incorporated in the lesioned part and retrogradely opacified through the ipsilateral superior cerebellar artery and its pial anastomosis.



**Figure 3:** The schema demonstrating the actual surgical design of the final situation: trapping of the aneurysm and intraluminal thrombectomy, followed by V3-radial artery graft-V4 bypass reconstruction, in conjunction with possible occipital artery-posterior inferior cerebellar artery bypass.

[Figure 5a]. The superior oblique muscle was reflected in the attachment on the C1 lateral mass, and the horizontal segment (V3) of the VA was exposed in the suboccipital triangle [Figure 5b]. A lateral suboccipital craniotomy was made, followed by drilling of the ipsilateral magnum and condylar fossa, and exposure of the sigmoid sinus. This provided a maximum surgical field through the triangle made by the medulla, the spinal root of the 11<sup>th</sup> nerve, and

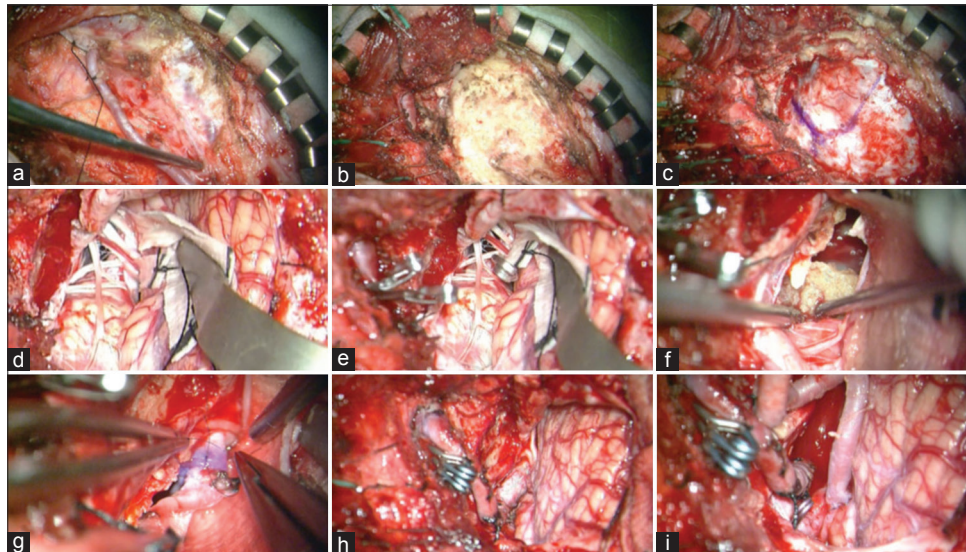
the lower cranial nerves (LCNs) complex [Figure 5c]. The cerebellomedullary cistern was opened along the spinal root of the 11<sup>th</sup> nerve, and the cerebellar hemisphere was retracted gently. The GTVA was so large that the medulla oblongata and the spinal root of the 11<sup>th</sup> nerve were deviated medially [Figure 5d]. A relatively robust perforator was confirmed approximately 20 mm distal from the aneurysm. Therefore, we trapped the aneurysm between the V3 portion and just distal to the dilated segment [Figure 5e], and then incised the aneurysmal wall and removed the intraluminal laminated



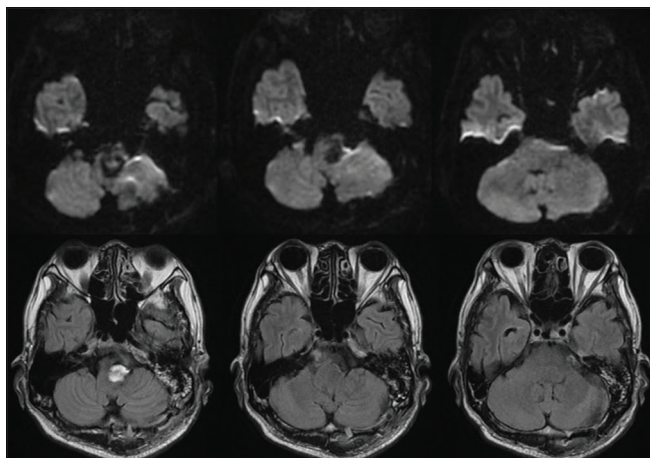
**Figure 4:** L shaped skin incision was designed and a lateral suboccipital craniotomy was made followed by the drilling of ipsilateral magnum, condylar fossa as well as sigmoid sinus exposure.

thrombus through the space lateral to the 11<sup>th</sup> nerve [Figure 5f]. After thorough intraluminal thrombectomy and decompression, the medial wall adhering to the brainstem was left to avoid injury. Subsequently, the distal V4 was cut distal to the dilated segment and pulled down below the LCNs. The stump of the V4 was made fish mouth-like, and end-to-end anastomosis with RAG was performed through the triangular corridor, lateral to the medially-deviated 11<sup>th</sup> nerve/medulla, inferior to the LCNs, and medial to the sigmoid sinus [Figure 5g]. Another end of the RAG was anastomosed to the V3 portion in an end-to-side method, and the V3-RAG-V4 bypass was completed [Figure 5h]. In the cerebellomedullary fissure, the PICA was found with the origin from the GTVA, which was occluded. However, in preoperative DSA, retrograde blood flow was observed through the pial collateral through the ipsilateral SCA. Therefore, we added an OA-PICA anastomosis in an end-to-side method [Figure 5i]. Finally, we confirmed good patency of each bypass and disappearance of the aneurysm using indocyanine green video angiography and microvascular Doppler sonography. The actual surgical procedure can be found in online supplementary resources [Video 1].

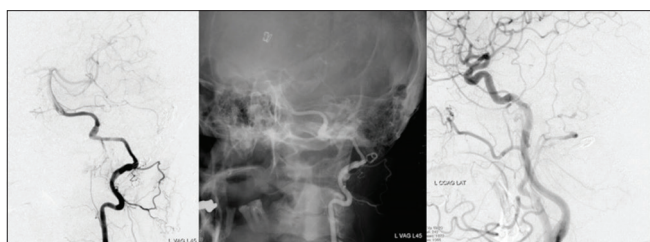Postoperative MRI and DSA demonstrated the disappearance of the aneurysm, improvement of brainstem compression, and good patency of each bypass [Figures 6 and 7]. Slight dysesthesia remained, while all other symptoms improved completely after rehabilitation. The patient was discharged with a modified Rankin Scale score of 1.



**Figure 5:** The intraoperative images. (a) The occipital artery (OA) was harvested from the exit of the digastric groove to the entry to the skin. (b) V3 portion of the left vertebral artery was exposed in the suboccipital triangle. (c) Left suboccipital craniotomy and far-lateral drilling were performed. (d) The giant thrombosed vertebral artery aneurysm (GTVA) compressing the medulla oblongata as well as the spinal root of the 11<sup>th</sup> nerve medially was exposed. (e) The GTVA was trapped between V3 portion and just distal to the dilated segment. (f) Intraluminal laminated thrombus was removed. (g and h) V3-radial artery graft-V4 bypass was performed through the space lateral to the 11<sup>th</sup> nerve. (i) Finally, OA-posterior inferior cerebellar artery anastomosis was added.



**Figure 6:** Postoperative magnetic resonance imaging showing improvement of the brain stem compression.



**Figure 7:** Postoperative digital subtraction angiography demonstrating good patency of each bypass.

## DISCUSSION

The mechanism underlying intra-aneurysmal thrombosis and aneurysm enlargement was reported to involve repeated minor hemorrhages from the vasa vasorum during the dynamic process of neovascularization,<sup>[5,14]</sup> although the development of intra-thrombotic capillary channels was also suggested to play a role in GTVA growth.<sup>[14,15]</sup>

In recent years, endovascular procedures have been considered less invasive, especially for avoiding effects on the LCNs, when compared with open surgical manipulation.<sup>[1,4]</sup> However, endovascular proximal occlusion or internal trapping does not obliterate the vasa vasorum or intra-thrombotic capillary channels, both of which are associated with growth or rupture of the GTVA. Thus, the long-term treatment efficacy of these procedures remains unclear.<sup>[5,14]</sup> As such, continual intra-aneurysmal thrombosis and growth may proceed after endovascular coiling.<sup>[2,19]</sup> Recently, the efficacy of flow diverter devices has been reported, although the mass reduction effect and long-term curability of GTVAs are largely unknown.<sup>[3,21]</sup> Based on these factors, surgical aneurysmal trapping, intra-aneurysmal thrombectomy, followed by anterograde revascularization whenever possible, is an ideal treatment for GTVA.

Reconstruction of the VA after trapping and thrombectomy is not typically performed for a patent contralateral VA, as the procedure is invasive and complicated. However, there are several reasons why revascularization of VA should be considered whenever possible. First, there is no guarantee of permanent patency of the contralateral VA because of severe atherosclerosis in our patient. Indeed, most patients with VA aneurysms were reported to have accompanying atherosclerotic degeneration in other vessels.<sup>[17]</sup> Second, the development of many dissecting VA aneurysms is associated with hemodynamic stress caused by occlusion or dissection of the contralateral VA.<sup>[9,16]</sup> Furthermore, pathological bilateral VA dissection was observed in 40% of autopsy cases of subarachnoid hemorrhage caused by dissecting VA aneurysms.<sup>[13]</sup> Third, if reconstruction of the VA is not performed, there is a chance that the perforating branches arising from the V4 portion distal to the trapped GTVA may be occluded by blind-end formation relative to the VA union (i.e., by thrombus propagation caused by the VA stump), resulting in brainstem infarction. Indeed, cases of brainstem infarction caused by the VA stump have been reported after endovascular parent artery occlusion,<sup>[7]</sup> while brainstem infarction was not observed in cases with a relatively thick anterior spinal artery, which may provide a robust blood outflow.<sup>[8]</sup>

There are two important points related to obtaining a surgical corridor to perform a safe RAG-distal V4 anastomosis in GTVA cases. First, a suboccipital transcondylar approach with complete drilling of the condylar fossa can be used to widen the triangular space made by a spinal root of the 11<sup>th</sup> nerve, LCNs, and medulla. However, in the present case, the huge GTVA deviated the spinal root of the 11<sup>th</sup> nerve rostromedially. Thus, we performed the anastomosis through the space lateral to the medially deviated 11<sup>th</sup> nerve/medulla, inferior to the LCNs, and medial to the sigmoid sinus. Second, in cases of serpentine VA aneurysms, the distal end of the dilated segment is often meandering and deflecting outwardly to the vicinity of the internal auditory canal and is stretched in an axial direction.<sup>[11]</sup> Thus, the V4 stump can be transposed to the triangle corridor made by the 11<sup>th</sup> nerve, LCNs, and the medulla, or between the LCNs and the acoustic nerve, thus avoiding perforating branch injury of the VA.<sup>[12,18]</sup> In our case, the space widened by removal of the GTVA, and the patency of the contralateral VA that provided substantial ischemic tolerance, allowed a safe and reliable surgical procedure using V3-RAG-V4 anastomosis.

## CONCLUSION

Trapping of the aneurysm and thrombectomy, in conjunction with V3-RAG-V4 bypass and OA-PICA bypass, should be considered as the most radical treatment for GTVA involving the PICA.

## Acknowledgments

We thank Edanz Group ([www.edanzediting.com/ac](http://www.edanzediting.com/ac)) for editing a draft of this manuscript.

## Declaration of patient consent

The authors certify that they have obtained all appropriate patient consent forms.

## Financial support and sponsorship

Nil.

## Conflicts of interest

There are no conflicts of interest.

## REFERENCES

- Ahn JY, Han IB, Kim TG, Yoon PH, Lee YJ, Lee BH, *et al.* Endovascular treatment of intracranial vertebral artery dissections with stent placement or stent-assisted coiling. *AJNR Am J Neuroradiol* 2006;27:1514-20.
- Chang SD, Marks MP, Steinberg GK. Recanalization and rupture of a giant vertebral artery aneurysm after hunterian ligation: Case report. *Neurosurgery* 1999;44:1117-20.
- Fang YB, Wen WL, Yang PE, Zhou Y, Wu YN, Hong B, *et al.* Long-term outcome of tubridge flow diverter(S) in treating large vertebral artery dissecting aneurysms a pilot study. *Clin Neuroradiol* 2017;27:345-50.
- He M, Zhang H, Lei D, Mao BY, You C, Xie XD, *et al.* Application of covered stent grafts for intracranial vertebral artery dissecting aneurysms. *J Neurosurg* 2009;110:418-26.
- Iihara K, Murao K, Sakai N, Soeda A, Ishibashi-Ueda H, Yutani C, *et al.* Continued growth of and increased symptoms from a thrombosed giant aneurysm of the vertebral artery after complete endovascular occlusion and trapping: The role of vasa vasorum. Case report. *J Neurosurg* 2003;98:407-13.
- Inoue T, Tamura A, Saito I. Trapping and V3-radial artery graft-V4 bypass for ruptured dissecting aneurysm of the vertebral artery. *Neurosurgical Focus* 2015; 38:Video1. Available from: <https://thejns.org/view/journals/neurosurg-focus/38/videosuppl1/2015.v1.focus14465.xml>. [Last accessed on 30 Apr 2019].
- Iwai T, Naito I, Shimaguchi H, Suzuki T, Tomizawa S. Angiographic findings and clinical significance of the anterior and posterior spinal arteries in therapeutic parent artery occlusion for vertebral artery aneurysms. *Interv Neuroradiol* 2000;6:299-309.
- Kado K, Hirai S, Kobayashi S, Kobayashi E, Yamakami I, Uchino Y, *et al.* Potential role of the anterior spinal artery in preventing propagation of thrombus in a therapeutically occluded vertebral artery: Angiographic studies before and after endovascular treatment. *Neuroradiology* 2002;44:347-54.
- Katsuno M, Mizunari T, Kobayashi S, Takahashi H, Teramoto A. Rupture of a vertebral artery dissecting aneurysm developing immediately after trapping of a dissecting aneurysm on the contralateral vertebral artery: Case report. *Neurol Med Chir (Tokyo)* 2009;49:468-70.
- Krings T, Alvarez H, Reinacher P, Ozanne A, Baccin CE, Gandolfo C, *et al.* Growth and rupture mechanism of partially thrombosed aneurysms. *Interv Neuroradiol* 2007;13:117-26.
- Mahmood A, Dujovny M, Torche M, Dragovic L, Ausman JI. Microvascular anatomy of foramen caecum medullae oblongatae. *J Neurosurg* 1991;75:299-304.
- Matsushima T, Kawashima M, Masuoka J, Mineta T, Inoue T. Transcondylar fossa (supracondylar transjugular tubercle) approach: Anatomic basis for the approach, surgical procedures, and surgical experience. *Skull Base* 2010;20:83-91.
- Mizutani T, Aruga T, Kirino T, Miki Y, Saito I, Tsuchida T, *et al.* Recurrent subarachnoid hemorrhage from untreated ruptured vertebralbasilar dissecting aneurysms. *Neurosurgery* 1995;36:905-11.
- Nagahiro S, Takada A, Goto S, Kai Y, Ushio Y. Thrombosed growing giant aneurysms of the vertebral artery: Growth mechanism and management. *J Neurosurg* 1995;82:796-801.
- Nakatomi H, Segawa H, Kurata A, Shiokawa Y, Nagata K, Kamiyama H, *et al.* Clinicopathological study of intracranial fusiform and dolichoectatic aneurysms: Insight on the mechanism of growth. *Stroke* 2000;31:896-900.
- Nashimoto T, Komata T, Honma J, Yamashita S, Seki Y, Kurashima A, *et al.* Successful treatment of bilateral vertebral artery dissecting aneurysms with subarachnoid hemorrhage: Report of three cases. *J Stroke Cerebrovasc Dis* 2012;21:422-7.
- Nijensohn DE, Saez RJ, Reagan TJ. Clinical significance of basilar artery aneurysms. *Neurology* 1974;24:301-5.
- Ota N, Tanikawa R, Eda H, Matsumoto T, Miyazaki T, Matsukawa H, *et al.* Radical treatment for bilateral vertebral artery dissecting aneurysms by reconstruction of the vertebral artery. *J Neurosurg* 2016;125:953-63.
- Park JC, Kwon BJ, Cho YD, Han MH. Growing thrombosed dissecting aneurysm of the vertebral artery after endovascular proximal artery occlusion: The role of the vasa vasorum. *Neurointervention* 2009;4:33-7. Available from: <https://www.neurointervention.org/journal/view.php?number=31>. [Last accessed on 2019 Feb 25].
- Sharma BS, Gupta A, Ahmad FU, Suri A, Mehta VS. Surgical management of giant intracranial aneurysms. *Clin Neurol Neurosurg* 2008;110:674-81.
- Siddiqui AH, Abla AA, Kan P, Dumont TM, Jahshan S, Britz GW, *et al.* Panacea or problem: Flow diverters in the treatment of symptomatic large or giant fusiform vertebralbasilar aneurysms. *J Neurosurg* 2012;116:1258-66.

**How to cite this article:** Tsunoda S, Inoue T, Naemura K, Akabane A. Surgical removal using V3-radial artery graft-V4 bypass and occipital artery-posterior inferior cerebellar artery bypass for a giant thrombosed aneurysm of vertebral artery compressing brain stem: Case report. *Surg Neurol Int* 2019;10:220.