

## Retrobulbar Lymphangioma: A Rare Case Report

### Abstract

We report a case of biopsy-proven retrobulbar lymphangioma in a 14-year-old girl. She presented with chief complaints of swelling in the left eye for 2 months. The patient underwent imaging evaluation and it was diagnosed as cavernous hemangioma, radiologically. However, later on, the patient underwent surgery, and the specimen was sent for histopathology which revealed it to be a lymphangioma.

**Keywords:** *Lymphangioma, orbital mass, proptosis, retrobulbar*

### Introduction

Lymphangiomas are benign vascular malformations (venous-lymphatic malformations), usually diagnosed in early childhood, especially in the head-and-neck region but rarely involving the orbit. It usually presents at an early age, from infancy to the first decade of life and constituted 0.3%–1.5% of all histopathologically diagnosed orbital tumors.<sup>[1]</sup> It is likely that orbital lymphangiomas are of congenital origin, but these lesions cannot be marked as a hamartoma, as orbit is devoid of lymphatic vessels. These malformations are slow to evolve but very invasive and have a malformed component that is a mix of venous and lymphatic tissue.<sup>[2]</sup> Lymphangiomas are not encapsulated and often infiltrate the fat, orbital septa, nerves, and muscles making complete excision impossible.<sup>[2]</sup> We report a case of retrobulbar lymphangioma that was removed successfully by lateral orbitotomy approach.

### Case Report

A 14-year-old girl presented with gradually progressive proptosis of the left eye (6 mm on Hertel) with lateral globe displacement. There was no history of visual loss, restricted eye movement, or diplopia. The patient underwent complete clinical ocular examination and radiological evaluation. Magnetic resonance imaging (MRI) showed well-defined mass lesion at superolateral aspect of left orbit

in retrobulbar space with extension in both intra- and extraconal space and splaying the superior and lateral rectus muscles apart. It appeared to be isointense on T1 and hyperintense on T2 with irregular heterogeneous enhancement on contrast administration. It measured around 26 mm × 24 mm × 23 mm in size and was located predominantly in the posteromedial aspect of the globe. Lesion caused minimal expansion of the left orbit with inferomedial displacement of the optic nerve. Proptosis of the left eye was noted [Figures 1-3]. The left globe *per se* appeared normal. The right eye and orbit did not reveal any abnormality. Visualized intracranial structures were normal. There was no extension of this lesion intracranially. On the basis of imaging, the patient was diagnosed to have cavernous hemangioma of the left eye. The lesion was approached through a left lateral orbitotomy. Intraoperatively, the lesion was well defined with distinct borders and could be excised completely.

At histopathologic analysis, the malformation was composed of multiple large lymphatic channels, focally lined by flattened epithelium with small scattered mature lymphoid aggregates in the wall, and dysplastic channels were filled with pink, amorphous, homogeneous proteinaceous fluid, and lymphocytes. Features were suggestive of lymphangioma [Figure 4].

The surgical treatment was completely curative and successful. Pathological findings were suggestive of orbital lymphangioma. The postoperative course was uneventful with excellent esthetic

**Anil Kumar,  
Lokesh Nehete,  
Jitender Chaturvedi<sup>1</sup>,  
Nighat Hussain<sup>2</sup>**

*Departments of Neurosurgery and <sup>2</sup>Pathology, All India Institute of Medical Sciences, Raipur, Chhattisgarh, <sup>1</sup>Department of Neurosurgery, All India Institute of Medical Sciences, Rishikesh, Uttarakhand, India*

#### Address for correspondence:

*Dr. Anil Kumar,  
Department of Neurosurgery,  
All India Institute of Medical  
Sciences, Raipur, Chhattisgarh,  
India.  
E-mail: dr.anilsharma02@gmail.  
com*

#### Access this article online

**Website:** [www.asianjns.org](http://www.asianjns.org)

**DOI:** 10.4103/ajns.AJNS\_165\_18

#### Quick Response Code:



**How to cite this article:** Kumar A, Nehete L, Chaturvedi J, Hussain N. Retrobulbar lymphangioma: A rare case report. *Asian J Neurosurg* 2018;13:1292-4.

This is an open access journal, and articles are distributed under the terms of the Creative Commons Attribution-NonCommercial-ShareAlike 4.0 License, which allows others to remix, tweak, and build upon the work non-commercially, as long as appropriate credit is given and the new creations are licensed under the identical terms.

**For reprints contact:** [reprints@medknow.com](mailto:reprints@medknow.com)

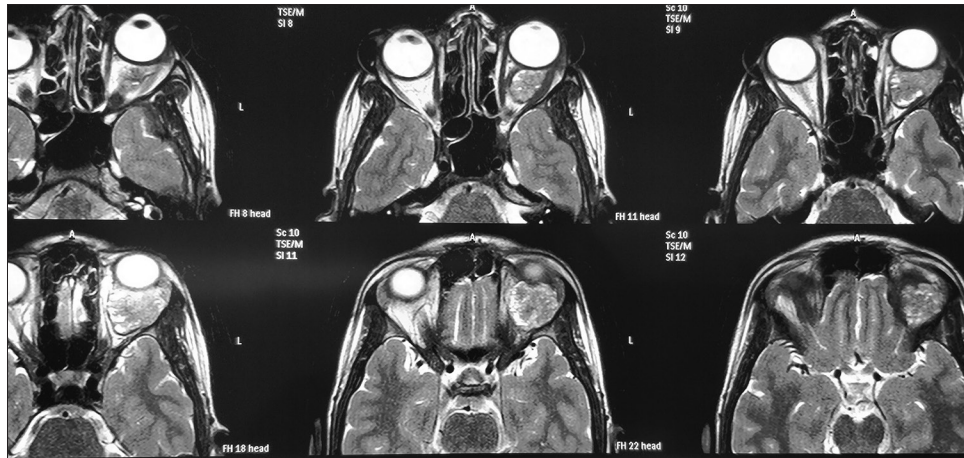


Figure 1: Magnetic resonance imaging T2-weighted axial images – hyperintense lesion involving extraconal as well as intraconal compartment of the left eye

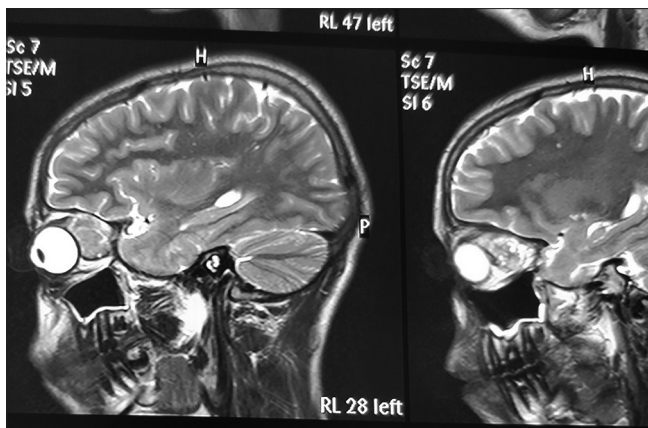


Figure 2: Magnetic resonance imaging T2-weighted sagittal image showing heterogeneously hyperintense lesion

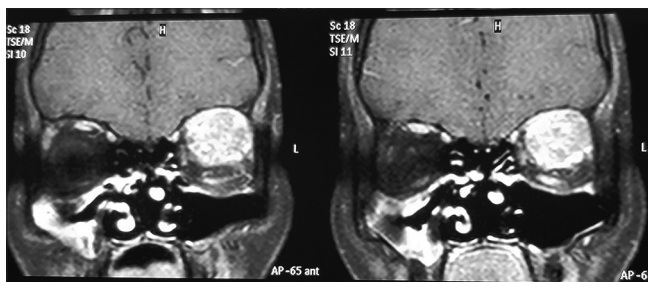


Figure 3: Coronal magnetic resonance image obtained in the plane of the left globe shows a large lesion occupying most of the left orbit with heterogeneous enhancement on contrast administration. The left globe is proptosed and is not seen on this image

result with the complete reduction of proptosis. At 1-year follow-up, the patient had no proptosis with normal clinical ocular examination.

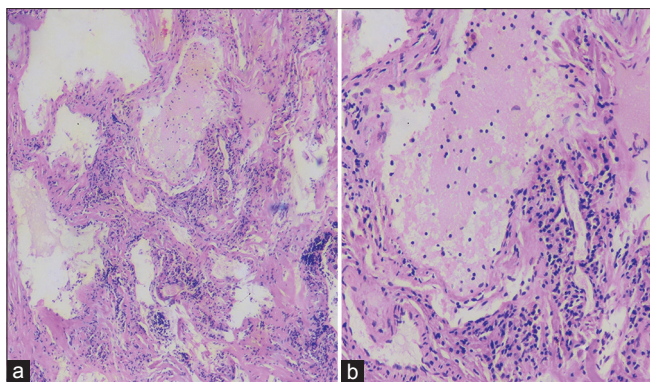
### Discussion

Venous–lymphatic malformations are prevalent vascular lesions in the orbit. The malformations are present at birth, but they may not be discovered until they undergo expansion. Clinically, lymphangiomas usually present with a slowly

progressive exophthalmos, displacement of the globe, ptosis, restricted eye movements, or with sudden proptosis due to intratumoral hemorrhage and expansion.<sup>[1]</sup> Lymphatic malformations are unencapsulated, diffuse infiltrating with ill-defined margins, and multicompartmental, often including both intraconal and extraconal components that are insinuated between normal orbital structures. The lesions may extend across tissue planes to infiltrate the eyelid and orbit and can have components with cysts. The intralesional hemorrhage is common and frequently produces distinctive fluid–fluid levels within the cystic portions. Venous–lymphatic malformations of the orbit are associated with noncontiguous, ipsilateral, and intracranial vascular anomalies.

Overall, radiologic analysis alone has a diagnostic specificity of 77% for this type of tumor. However, radiological appearance may mimic other tumors and orbital lymphangioma can sometimes be misdiagnosed as orbital hemangioma, rhabdomyosarcoma, or lymphoma when only imaging studies are used.<sup>[3]</sup>

Tunç *et al.*, in their series of 26 cases, reported that five cases of lymphangiomas were misdiagnosed as orbital hemangiomas on preoperative imaging.<sup>[1]</sup> Lymphangiomas do not enhance with gadolinium, suggesting that they are isolated from the systemic circulation.<sup>[4]</sup> However, in the present case, heterogeneous contrast enhancement was noted. Lymphatic malformations of the orbit must be differentiated from cavernous hemangiomas, venous malformations, rhabdomyosarcomas, and lymphomas. MRI is the modality of choice to identify the hemorrhagic cyst as well as the lymphatic cystic component. Hemorrhagic cyst (acute and subacute) shows increased signal on both T1- and T2-weighted MRI images, whereas lymphatic cysts are hypointense on T1-weighted images and hyperintense on T2-weighted images. MRI study is most helpful in documenting fluid level within the multicystic lesion. Intralesional hemorrhage is common and frequently produces distinctive fluid–fluid levels



**Figure 4:** (a) Photomicrograph shows multiple large lymphatic channels, focally lined by flattened epithelium with small scattered mature lymphoid aggregates in the wall, and filled with pink, amorphous, homogeneous proteinaceous fluid, and lymphocytes (H and E, ×20). (b) Photomicrograph shows a higher magnification of the same focus (H and E, ×100)

within the cystic portions. Before the surgery, we thought it likely on the basis of the results of MR imaging that the patient's lesion was a cavernous hemangioma. The utilization of MRI and CT can help in narrowing the differential diagnosis; however, a definitive diagnosis of orbital venous–lymphatic malformations requires surgical excision with confirmatory pathological analysis.

The pathogenesis of orbital lymphangioma is controversial, and there has been considerable debate in the literature about the origin of orbital lymphangiomas, whether they represent hamartomas, orbital venous anomalies, combined venous–lymphatic malformations, or distinct entities.<sup>[5-7]</sup>

Management of orbital and adnexal lymphangioma can be challenging and difficult due to diffuse infiltration and associated hemorrhage. Surgery remains the treatment of choice with the main aim to preserve visual function and cosmesis. Surgical approach should be determined by careful study of axial, sagittal, and coronal sections from MRI with an emphasis on size, shape, location of tumor, and its relations to critical orbital structures. In symptomatic patients, the infiltrative, diffuse nature of the lesion usually allows only a partial resection.<sup>[1]</sup> Gündüz *et al.*, in a series of 18 patients with periocular lymphangioma, reported total resection of the lesion in five patients and concluded that surgically well-delineated extraconal lymphangiomas can be resected totally with no clinical recurrence at short-term follow-up.<sup>[8]</sup> In the present case, lesion was well defined with distinct borders and could be excised completely. Systemic corticosteroids and intralesional injections of bleomycin or Ok-432 (penicillin G-treated low-virulence Su strain of human origin group A *Streptococcus pyogenes*) are also used and recommended by some authors for

recurrent lesions; however, surgical excision is the modality of choice for curative treatment at least for primary and/or retrobulbar lymphangiomas.<sup>[9]</sup>

## Conclusion

Orbital lymphangioma should be considered in differential diagnosis of orbital masses. This study also highlights the significance of MRI in the diagnosis of lymphangioma. Surgically well-delineated intra- and extraconal lymphangiomas can be resected totally with preservation of visual function and satisfactory cosmetic appearance.

## Declaration of patient consent

The authors certify that they have obtained all appropriate patient consent forms. In the form the patient(s) has/have given his/her/their consent for his/her/their images and other clinical information to be reported in the journal. The patients understand that their names and initials will not be published and due efforts will be made to conceal their identity, but anonymity cannot be guaranteed.

## Financial support and sponsorship

Nil.

## Conflicts of interest

There are no conflicts of interest.

## References

1. Tunç M, Sadri E, Char DH. Orbital lymphangioma: An analysis of 26 patients. *Br J Ophthalmol* 1999;83:76-80.
2. Marchal JC, Civit T. Neurosurgical concepts and approaches for orbital tumours. *Adv Tech Stand Neurosurg* 2006;31:73-117.
3. Gandhi NG, Lin LK, O'Hara M. Sildenafil for pediatric orbital lymphangioma. *JAMA Ophthalmol* 2013;131:1228-30.
4. Malhotra AD, Parikh M, Garibaldi DC, Merbs SL, Miller NR, Murphy K. Resection of an orbital lymphangioma with the aid of an intralesional liquid polymer. *AJNR Am J Neuroradiol* 2005;26:2630-4.
5. Wright JE, Sullivan TJ, Garner A, Wulc AE, Moseley IF. Orbital venous anomalies. *Ophthalmology* 1997;104:905-13.
6. Iliff WJ, Green WR. Orbital lymphangiomas. *Ophthalmology* 1979;86:914-29.
7. Katz SE, Rootman J, Vangveeravong S, Graeb D. Combined venous lymphatic malformations of the orbit (so-called lymphangiomas). Association with noncontiguous intracranial vascular anomalies. *Ophthalmology* 1998;105:176-84.
8. Gündüz K, Demirel S, Yagmurlu B, Erden E. Correlation of surgical outcome with neuroimaging findings in periocular lymphangiomas. *Ophthalmology* 2006;113:1231.e1-8.
9. Wiegand S, Eivazi B, Zimmermann AP, Sesterhenn AM, Werner JA. Sclerotherapy of lymphangiomas of the head and neck. *Head Neck* 2011;33:1649-55.