

Non-syndromic odontogenic keratocysts: A rare case report

Department of Oral Surgery, Jodhpur Dental College General Hospital, Jodhpur, Rajasthan, ¹IDST College, Kadrabad, Modinagar, Uttar Pradesh, India

Raghavendra S. Kurdekar, Jeevan Prakash, A. S. Rana¹, Puneet Kalra¹

ABSTRACT

Odontogenic keratocysts are very well documented in the literature. Multiple odontogenic keratocysts (OKCs) are one of the most frequent features of nevoid basal cell carcinoma syndrome (NBCCS). It is linked with mutation in the PTCH gene (human homolog of the drosophila segment polarity gene, "patched"). Partial expression of the gene may result in occurrence of only multiple recurring OKC without any associated systemic findings. A rare case of multiple odontogenic keratocysts unassociated with any syndrome is reported, so as to add to the growing number of such cases in the literature. The possibility of this case being a partial expression of the Gorlin-Goltz syndrome is discussed.

Key words: Gorlin-Goltz syndrome, jaw cysts, nevoid basal cell carcinoma syndrome, odontogenic keratocysts, Protein patched homolog gene

Address for correspondence:
Dr. Raghavendra S. Kurdekar,
Department of Oral Surgery,
Jodhpur Dental College General
Hospital, Jhawar Road, Narnadi,
Boranada, Jodhpur, Rajasthan,
India.
E-mail: rkurdekar@yahoo.co.in

INTRODUCTION

Odontogenic keratocysts (OKCs) are the most common form of cystic lesions affecting the maxillofacial region.^[1] They are clinically aggressive lesions which are thought to arise from the dental lamina or its remnants.^[2] The OKC was first described in 1876,^[3] and named by Phillipson in 1956.^[4] It is one of the most aggressive odontogenic cysts of the oral cavity. OKC is known for its rapid growth,^[5-7] and its tendency to invade the adjacent tissues including bone.^[3,7-9] It has a high recurrence rate,^[9-11] and is associated many a times with nevoid basal cell carcinoma syndrome (NBCCS).^[12]

Usually, multiple OKCs occur as a component of NBCCS with concomitant cutaneous, skeletal, ophthalmic, and neurologic abnormalities. Gorlin and Goltz first described the spectrum of features associated with this syndrome in 1960; hence, it is also called Gorlin-Goltz syndrome.^[13] Multiple OKCs have been known to occur

in non-Syndromic cases, though it is very rare.^[14] These multiple lesions may be the first manifestation of the NBCCS or otherwise it may be because of the multifocal nature of OKCs.^[15,16] We discuss the possibility that the current case is a partial expression of NBCCS and briefly review the current trends in treatment of recurrent OKCs associated with this syndrome.

CASE REPORT

A 23-year-old male normally fit and well reported to the outpatient department of our hospital with a chief complaint of asymptomatic swelling and pus discharge from the left maxillary posterior region since 10 days.

There was no significant past medical history. A detailed examination of the maxillofacial region had no significant extra-oral findings. Intra-oral examination revealed a partially edentulous state; teeth 13, 14, 18, 27, 28, 37, and 47 were missing with slight expansion of the buccal cortical plate in the left maxillary posterior region. On exertion of pressure, a white creamy exudate expressed out of the area between 23 and 24, but there was no tenderness or bleeding on further palpation.

A panoramic radiograph revealed multiple radiolucencies in all four quadrants [Figure 1]. Lesion in the left maxillary quadrant was associated with multiple impacted teeth and

Access this article online	
Quick Response Code: 	Website: www.njms.in
	DOI: 10.4103/0975-5950.117874

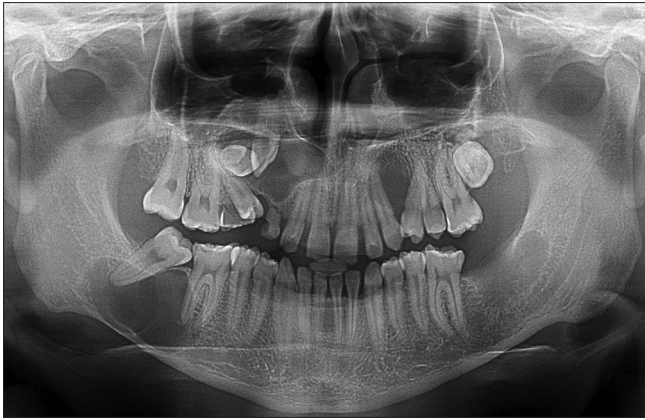


Figure 1: Radiograph-OPG

retained deciduous teeth. In the lower jaw, well-defined radiolucencies were associated with missing 37 and 47 which mimics dentigerous cysts. Diagnostic biopsy from the maxillary left quadrant was reported as OKC.

The patient's chest and skull radiographs were unremarkable. Dermatology consultation did not reveal any cutaneous abnormality. Hematological investigations were within normal limits. The patient was admitted to hospital, and enucleation of the cystic lesions was performed under general anesthesia and the surgical bed was treated with Carnoy's Solution. It was interesting to note that there were two separate entities in the right maxillary region with one of the lesion associated with the impacted canine and they were sent as two separate specimens. Four lesions (excluding the small lesion distal to tooth 36) were enucleated and sent for histopathological examination. The small cystic lesion distal to tooth 36 was kept under observation. The patient recovered uneventfully and was discharged the next day and is presently being kept under observation with regular follow ups at the interval of 3 months are being conducted.

The histopathologic report revealed that three out of four lesions were OKC and the other lesion which was associated with the impacted canine in the maxillary right quadrant was dentigerous cyst. Cystic lining of all three Keratocystic lesions was parakeratinized stratified squamous epithelium of uniform 6-8-cell thickness. The lining epithelium consisted of well-defined columnar basal cells in a palisade arrangement and with polarized nuclei. The height of the epithelial cells and the number of nuclei they contained were reduced. Satellite cysts and epithelial remnants were observed in the connective tissue capsule.

DISCUSSION

Multiple OKCs usually occur as a component of NBCCS or Gorlin-Goltz syndrome, Orofacial digital syndrome, Noonan syndrome, Ehler-Danlos

syndrome, Simpson-Golabi-Behmel syndrome, or other syndromes.^[14,17-19] Our patient was normally fit and well with no significant family history and had no features suggestive of these syndromes, such as basal cell carcinoma, skeletal or orofacial defects, stunted growth, bleeding diathesis, hyper extensible skin and hyper mobile joints, or other congenital anomalies associated with overall growth. In a study by Brannon,^[11] 5.1% of 312 cases were associated with NBCCS and 5.8% were accompanied by multiple keratocysts, but without any other features of the syndrome.

NBCCS is associated with mutation in the PTCH gene 9q (22.3-q31). Mutation within PTCH occurs in sporadic OKCs as well as those associated with NBCCS. It is suggested that a "two-hit" mechanism may underlie the variable expression of NBCCS and sporadic OKCs. In NBCCS, the basal cell carcinomas and keratocysts arise as a consequence of a "first-hit" of allelic loss of PTCH within the precursor cell. The development of basal cell carcinoma and Keratocysts in the absence of NBCCS reflects two somatic hits in which there are mutations of PTCH within locally susceptible cells that ultimately result in allelic loss. The absence of all the manifestations of NBCCS may be due to variability of the PTCH gene expression.^[14]

The biological behavior of OKCs associated with NBCCS is more aggressive and these cysts have higher recurrence rates (82%) compared with solitary keratocysts (61%).^[20] The higher recurrence rates are attributed to epithelial remnants of the cystic lining or satellite cysts left behind following surgery.^[21] A recurring OKC can be a new cyst that originates from epithelial residue or a microcyst left behind in the overlying mucosa. This is reinforced by the fact that OKCs can occur in bone grafts if the overlying mucosa is not excised.^[21,22] The term "multiple cysts" does not necessarily mean that the patient must have more than one cyst at a given time; rather it refers to occurrence of cysts over the lifetime of the patient.^[23]

One of the interesting findings in our patient was the concomitant occurrence of dentigerous cyst associated with impacted canine along with OKC in the maxillary right quadrant which is very rare finding in itself. It is a well-known fact that dentigerous cysts associated with unerupted teeth occur only in few individuals, whereas unerupted teeth are common occurrence. This suggests that some people are prone to cyst formation. A genetic predisposition may be a possibility. This also suggests that our patient might have a predisposition for jaw cysts.

Histologically, parakeratinization, intramural epithelial remnants, and satellite cysts are more frequent among OKCs associated with NBCCS than in solitary keratocysts. In our patient, the lining of

the OKCs revealed the presence of parakeratinization with underlying connective tissue infiltrated by mild inflammatory cells and at some place with foreign body type of giant cell reaction indicating NBCCS association [Figure 2].^[23,24] The cystic space of the maxillary right quadrant associated with the impacted canine showed non-keratinized stratified squamous epithelium with 4-6 cells thick which appears to be collision of OKC and dentigerous cyst [Figure 3].

In the management, the recurrent OKCs are conventionally treated with enucleation or marsupialization with adjuvant chemical cautery using Carnoy's solution and cryosurgery. Cryosurgery seemed to be very promising as documented by Schmidt and Pogrel where they have treated these lesions with enucleation along with liquid nitrogen cryotherapy.^[25] Electro-cauterization may also be used in these areas to eliminate possible remnants of the cyst wall that tends to tear in those areas. We have treated the lesions in our patient with enucleation followed by electrocautery and also with Carnoy's solution.

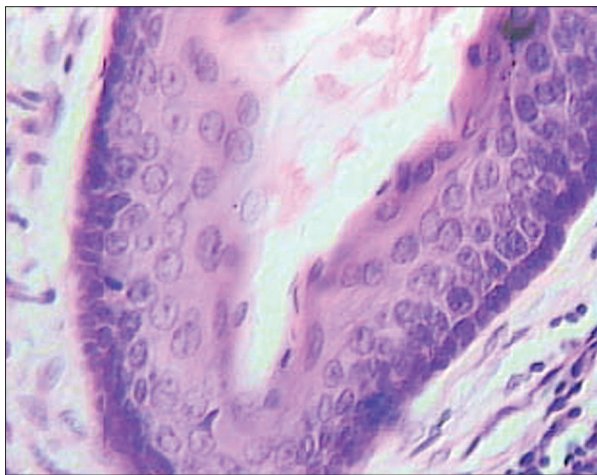


Figure 2: Lining of odontogenic keratocyst

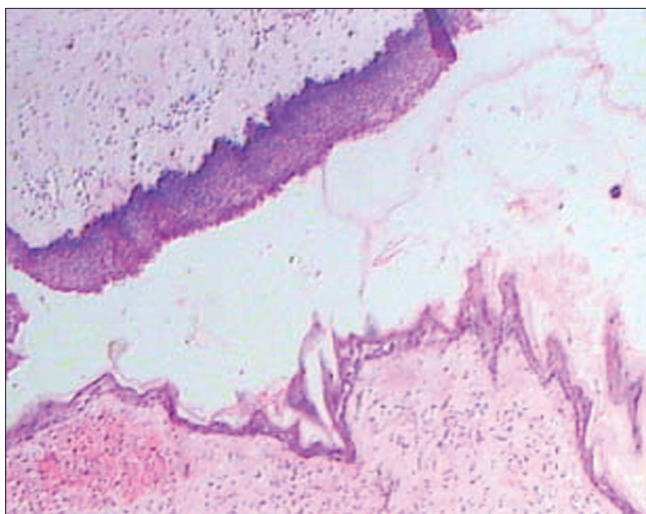


Figure 3: Collision of odontogenic keratocyst with dentigerous cyst

At present the patient is kept under observation with a regular follow up at an interval of 3 months. The patient and his relatives have been explained about the possibility of developing other features of NBCCS in the coming years and are advised to keep a strict vigil of the same.

In conclusion, any patient reporting with the multiple OKCs should be evaluated thoroughly for the possibility of NBCCS as OKCs may be the first and only manifestation of this syndrome. Also for the fact that OKCs associated with this syndrome have higher rate of recurrence than the isolated OKCs, a very strict follow up has to be followed for a long period of time. The possibility of other features of NBCCS has to be explained to the patient as well as his relatives, so as to allow appropriate genetic counseling and serial screening for the development of malignancies and other complications besides OKCs.

ACKNOWLEDGEMENT

Our sincere thanks to Dr. Mrs Sumita Kaswan the Vice – Principle of Jodhpur Dental College General Hospital for her constant encouragement and support.

REFERENCES

1. Koseoglu BG, Atalay B, Erdem MA. Odontogenic cysts: A clinical study of 90 Cases. *J Oral Sci* 2004;46:253-7.
2. Kramer IR, Pindborg JJ, Shear M. *Histological typing of odontogenic tumors*. 2nd ed. Berlin: Springer Verlag; 1992.
3. Philipsen HP. Om keratocyster (kolesteatom) I kaekberne. *Tandlaegegebladet* 1956;60:963-81.
4. Browne RM. The odontogenic keratocyst. Histological features and their correlation with clinical behavior. *Br Dent J* 1971;131:249-59.
5. Sharffetter K, Balz-Herrmann C, Lagrange W, Koberg W, Mittermayer C. Proliferation kinetics-study of the growth of keratocysts. Morpho-functional explanation for recurrences. *J Craniomaxillofac Surg* 1989;17:226-33.
6. Stoelinga PJ, Bronkhorst FB. The incidence, multiple presentation and recurrence of aggressive cysts of the jaws. *J Craniomaxillofac Surg* 1988;16:184-95.
7. Browne RM. The odontogenic keratocyst. Clinical aspects. *Br Dent J* 1970;128:225-31.
8. Lund VJ. Odontogenic keratocyst of the maxilla: A case report. *Br J Oral Maxillofac Surg* 1985;23:210-5.
9. Forssell K, Forssell H, Kahnberg KE. Recurrence of keratocysts. A long-term follow-up study. *Int J Oral Maxillofac Surg* 1988;17:25-8.
10. Pindborg JJ, Hansen J. Studies on odontogenic cyst epithelium. Clinical and roentgenologic aspects of odontogenic keratocysts. *Acta Pathol Microbiol Scand* 1963;58:283-94.
11. Brannon RB. The odontogenic keratocyst. A clinicopathologic study of 312 cases. Part II. Histologic features. *Oral Surg Oral Med Oral Pathol* 1977;43:233-55.
12. Crowley TE, Kaugars GE, Gunsolley JC. Odontogenic keratocysts: A clinical and histologic comparison of the parakeratin and orthokeratin variants. *J Oral Maxillofac Surg* 1992;50:22-6.
13. Mcgrath CJ, Myall RW. Conservative management of recurrent keratocysts in basal-cell naevus syndrome. *Aust Dent J* 1997;42:399-403.

14. Auluck A, Suhas S, Pai KM. Multiple odontogenic keratocysts: Report of a case. *J Can Dent Assoc* 2006;72:651-6.
15. Lo Muziol L, Nocini P, Bucci P, Pannone G, Consolo U, Procaccini M. Early diagnosis of nevoid basal cell carcinoma syndrome. *J Am Dent Assoc* 1999;130:669-74.
16. Boyne PJ, Hou D, Moretta C, Pritchard T. The multifocal nature of Odontogenic keratocysts. *J Calif Dent Assoc* 2005;33:961-5.
17. Lindeboom JA, Kroon FH, de Vires J, van den Akker HP. Multiple recurrent and de-novo odontogenic Keratocysts associated with oral-facial-digital syndrome. *Oral Surg Oral Med Oral Pathol Oral Radiol Endod* 2003;95:458-62.
18. Carr RJ, Green DM. Multiple odontogenic Keratocysts in a patient with type II (mitis) Ehler-Danlos syndrome. *Br J Oral Maxfacial Surg* 1988;26:205-14.
19. Connor JM, Evans DA, Goose DH. Multiple odontogenic keratocysts in a case of the Noonan syndrome. *Br J Oral Surg* 1982;20:213-6.
20. Dominguez FV, Keszler A. Comparative study of keratocysts, associated and non-associated with nevoid basal cell carcinoma syndrome. *J Oral Pathol* 1988;17:39-42.
21. Stoelinga PJ. Excision of the overlying, attached mucosa, in conjunction with cyst enucleation and treatment of the bony defect with carnoy solution. *Oral Maxillofac Surg Clin North Am* 2003;15:407-14.
22. Yeo JF, Loh FC. Multiple odontogenic keratocysts of the jaws. Case report. *Aust Dent J* 1989;34:503-6.
23. Woolgar JA, Rippin JW, Browne RM. The odontogenic keratocyst and its occurrence in the nevoid basal cell carcinoma syndrome. *Oral Surg Oral Med Oral Pathol* 1987;64:727-30.
24. Todd R, August M. Molecular approaches to the diagnosis of sporadic and nevoid basal cell carcinoma syndrome-associated odontogenic keratocysts. *Oral Maxillofac Surg Clin North Am* 2003;15:447-61.
25. Schmidt BL, Pogrel MA. The use of enucleation and liquid nitrogen cryotherapy in the management of odontogenic keratocysts. *J Oral Maxillofac Surg* 2001;59:720-5.

How to cite this article: Kurdekar RS, Prakash J, Rana AS, Kalra P. Non-syndromic odontogenic keratocysts: A rare case report. *Natl J Maxillofac Surg* 2013;4:90-3.

Source of Support: Nil. **Conflict of Interest:** None declared.

Announcement

iPhone App



Download
iPhone, iPad
application

FREE

A free application to browse and search the journal's content is now available for iPhone/iPad. The application provides "Table of Contents" of the latest issues, which are stored on the device for future offline browsing. Internet connection is required to access the back issues and search facility. The application is Compatible with iPhone, iPod touch, and iPad and Requires iOS 3.1 or later. The application can be downloaded from <http://itunes.apple.com/us/app/medknow-journals/id458064375?ls=1&mt=8>. For suggestions and comments do write back to us.