

A history of the path towards imaging of the brain: From skull radiography through cerebral angiography

Received: 07 Mar. 2020
Accepted: 10 May 2020

Haris Kamal¹, Edward J. Fine², Banafsheh Shakibajahromi³, Ashkan Mowla⁴

¹ Department of Neurology, University of Texas Health Science Center at Houston, Houston, Texas, USA

² Department of Neurology, State University of New York at Buffalo, Buffalo, New York, USA

³ Clinical Neurology Research Center, Shiraz University of Medical Sciences, Shiraz, Iran

⁴ Division of Stroke and Endovascular Neurosurgery, Department of Neurological Surgery, Keck School of Medicine, University of Southern California, Los Angeles, USA

Keywords

Cerebral Angiography; Cerebrovascular Disorders; Pneumoencephalography; Cerebral Ventriculography

Abstract

This publication reviews the steps in the path towards obtaining a complete image of the brain. Up to the 1920s, plain X-ray films could demonstrate only calcified tumors, shifts in midline position of a calcified pineal gland due to a mass in the cranium, or foreign metallic objects within the skull. Walter Dandy reported in 1918 that he visualized cerebral ventricles by introducing air as a contrast agent through a trocar into one of the occipital lobes or the right frontal horn of the ventricular system. Dandy localized lesions that distorted or shifted the ventricles. In 1920, Dandy placed air by lumbar puncture into the spinal subarachnoid space that could visualize the brain and entire ventricles. Antonio Egas Moniz with the assistance of his neurosurgeon colleague, Almeida Lima, obtained X-ray images of cerebral arteries of dogs and

decapitated human heads from corpses after injecting strontium bromide into their carotid arteries. Satisfied by these experiments, Moniz injected strontium bromide directly into carotid arteries of five patients which failed to show intracranial vessels. In the sixth patient, intracranial arteries were outlined but that patient died of cerebral thrombosis presumably due to the hyper-osmolality of that contrast agent. Finally, on June 18, 1927, Moniz injected 22% sodium iodine into a 20-year-old man and obtained clear visualization of his carotid artery and intracerebral branches after temporarily occluding the artery with a ligature.

How to cite this article: Kamal H, Fine EJ, Shakibajahromi B, Mowla A. A history of the path towards imaging of the brain: From skull radiography through cerebral angiography. *Curr J Neurol* 2020; 19(3): 131-7.

Direct percutaneous puncture of the cervical carotid artery remained the primary technique until the 1960s to visualize intracranial blood vessels until

Seldinger's technique was introduced in 1953. Computerized axial tomography (CAT) and magnetic resonance imaging (MRI) replaced cerebral arteriography for localizing tumors and epidural or subdural hemorrhage. However, angiography is used currently for embolization of aneurysms and removal of thrombi or emboli in patients with acute stroke.

Roentgen's discovery of X-rays initiated the quest for an image of cerebral vessels

The first step in the path towards obtaining a complete image of the human brain began on November 8, 1895, with a serendipitous observation.

Wilhelm Konrad Roentgen (1845-1923) "immobilized ...the hand of his wife in the path of these rays and observed after development, an image of his wife's hand which showed the shadows thrown by the bones of her hand and that of a ring she was wearing, surrounded by the penumbra of the flesh which was more permeable to the rays...". These unknown "X"-rays darkened silver-coated photographic paper when developed.¹ Roentgen announced his discovery on December 28, 1895,² and received the Nobel Prize for physics in 1901.³

Plain X-rays of the skull yield limited information about its content

Roentgen's discovery launched a tsunami of publications beginning in 1896 on its use to locate metallic objects in the human body. Fowler used X-rays to remove a .32 caliber self-inflicted bullet from extracranial tissue of a 19-year-old depressed student,⁴ contrary to a widely held belief that Harvey Cushing was the first surgeon to localize bullets in the skull. Cushing first used X-ray to locate a bullet lodged in the neck of a woman that caused Brown-Séquard syndrome (BSS).⁵ Archibald Church (1861-1952), an American neurologist, reported that a 15-year-old boy who staggered to his right side when walking suffered from an ever-increasing headache. His skull X-ray demonstrated a shadow in the right posterior fossa. Autopsy revealed glioma in the right cerebellar hemisphere with hemorrhage and marked vascularity. Church postulated that blood in the tumor produced X-ray enhancement of the tumor.⁶ X-rays were used to locate oligodendrogliomas because these tumors contain radioopaque calcifications. Arthur Schüller (1874-1957) published an exhaustive survey of changes in the plain skull films caused by extra- and intracranial lesions in *Die Schädelbasis im*

*Röntgenbilde in 1905.*⁷

Development of ventriculography and pneumoencephalography (PEG)

Objects that were not opaque to X-rays could be visualized by agents that would render them opaque or contrast their outlines. Haschek and Lindenthal⁸ injected the brachial artery of a cadaver with Teichmann's mixture, consisting of mercury as the contrast agent along with pumice to visualize the arteries of the hand in 1896 (Figure 1). The neurotoxic effects of mercury and the arterial obstruction that pumice injections would cause prohibited use of this mixture to outline the blood vessels of living animals.

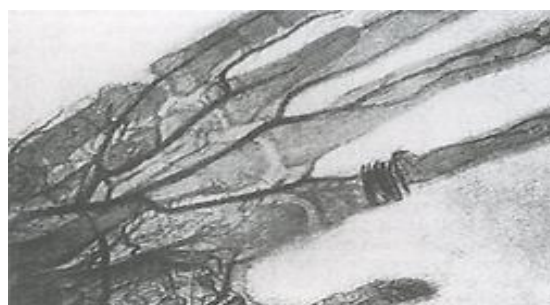

Figure 1. X-ray after Haschek and Lindenthal's injection of cadaver hand

Walter E. Dandy (1886-1946) (Figure 2) was the first one who performed ventriculography and PEG in 1918 and 1919, respectively. These techniques visualized cerebral cortex and ventricles using air as a contrast agent.⁹ Dandy's idea of using air as a contrast agent was based on a report by Luckett that air in the skull due to a skull fracture outlined the cerebral cortex. Air being more translucent to X-rays than the brain provided the contrast to outline patients' surrounding ventricles and cortex.¹⁰ Dandy introduced air with a needle placed through a burr hole over the frontal or the occipital horn of the lateral ventricle. In 1919, Dandy visualized the entire ventricular system when he performed a lumbar puncture, withdrew a small amount of cerebrospinal fluid, and injected air into the lumbar subarachnoid space. Air floated upwards to outline the patient's 3rd, 4th, and lateral ventricles.¹¹ Distortions in the natural diamond shape of the 4th ventricle allowed Dandy to localize and successfully operate on tumors in the spinocerebellar area.¹² When the 4th ventricle was dilated and no air could outline lateral ventricles, Dandy would localize and quickly operate to remove an obstruction at the 3rd ventricle. He noted

that frontal tumors would depress and shift portions of the ipsilateral lateral ventricle. PEG was rapidly accepted in European neurology through the publications of the highly respected Viennese radiographer and neurologist, Arthur Schüller and others.^{7,13} Further details about alterations in ventricles caused by intracranial tumors can be found in Diagnostic Neuroradiology.¹⁴



Figure 2. Walter E. Dandy (1886-1946)

Harvey Cushing was unwilling to use ventriculography as he recognized its dangers and technical pitfalls. He believed that a meticulous neurological examination would yield more information than ventriculography.¹⁵ Even Dandy cautioned that ventriculography was “extremely dangerous if used inadvisably or incorrectly”. He urged that after observing a dilated ventricle due to outflow obstruction, more cerebral spinal fluid be removed than the amount of injected air. He stressed urgent operation of tumors to prevent herniation and possible death.¹⁶

PEG was the second step in the path toward obtaining better images of the brain. However, PEGs were painful because injected air irritated pain receptors in the meninges and often triggered violent episodes of nausea and vomiting. Patients were strapped into a rotating chair which would somersault them to position air into the lateral ventricles. Then their heads would need to be tilted for the air to pass into the temporal horns. All too often structures surrounding the temporal horns were poorly visualized. Sometimes, only distorted ventricles could be seen after multiple attempts to fill the ventricles with air. Additionally, ventriculography and PEG provided no information about the vascular supply of tumors. Therefore, a safer method to obtain a clearer

image of the brain was needed.

Moniz's experiments that lead to cerebral arteriography

The third major breakthrough appeared in the second decade of the 20th century. Antonio Egas Moniz (1874-1955) (Figure 3) developed an interest in obtaining images of cerebral vasculature to safely visualize brain tumors.¹⁷ Moniz was a Portuguese neurologist and a leading politician for progressive causes in his country. His birth name was Antonio Caetano de Abreu Freire. He adopted the nom de plume of Moniz for a medieval Spanish hero who defended his country against the invading Moors.



Figure 3. Egas Moniz (1874-1955); his ears were deformed by gouty tophi

Moniz worked closely with Pedro Almeida Lima (1903-1985), an Associate Professor of Neurosurgery at the University of Lisbon, Lisbon, Portugal. Lima performed all the carotid injections for Moniz as Moniz's hands were severely deformed due to gouty arthritis.¹⁸

One of the challenges that Moniz recognized was to find a contrast agent that would not be toxic to the vasculature, yet would be radiopaque enough to generate adequate quality X-ray images. He knew that the Teichmann's mixture would not be a safe option in live subjects for angiography.

Moniz very methodically organized his search for an optimal contrast agent amongst multiple options present at that time. He injected decapitated cadaver heads obtained from the Anatomical Institute (Almada, Portugal) with different contrast agents and radiographed them to compare their opacity. He found strontium bromide to be the best agent to provide reasonably good contrast while having the least toxicity.

In 1926, Moniz with the assistance of his dexterous neurosurgical colleague, Lima, began to

perform experiments on dogs using strontium bromide. Lima would ligate the ipsilateral external carotid artery and inject a 70% solution of strontium bromide. After failing multiple times, cerebral arteries showed up faintly in the 15th dog.

Having completed trials in animals and cadavers, Moniz and Lima began trials in humans with percutaneous injections of 10 cc of 70% strontium bromide into the internal carotid artery (ICA). After failing to visualize any vessels in 4 patients, Lima decided to surgically expose the carotid artery and inject the contrast directly.¹⁸

They finally met with success in the 6th patient who was suffering from post-encephalitic Parkinson's disease (PD). Lima injected 14 cc of 60% strontium bromide after proximally occluding the ICA. Moniz and Lima were pleased that they had visualized intracranial vessels for the first time. Tragically, 8 hours after this carotid injection, the patient died due to carotid thrombosis. Moniz was deeply distressed and temporarily stopped all arteriography experiments. "This accident...was a great shock to us".¹⁸

After regaining his courage, Moniz re-started investigating properties of iodide salts as contrast agents. After experimenting with several salts of iodine, Moniz and Lima finally chose 25% sodium iodide for the next injections. After two unsuccessful attempts to visualize intracranial vessels, success came with a third patient when Lima injected 5 cc of 25% sodium iodide into the carotid artery. Lima tied a temporary ligature around the proximal portion of the internal carotid to direct the sodium iodine toward the cranial vessels.¹⁸ Moniz and Lima visualized distortion of cerebral vasculature caused by an intracranial tumor.¹⁷ This was the first instance of using cerebral angiography to diagnose intracranial pathology. Moniz further demonstrated that arteriography could identify thrombotic occlusion of the ICA.^{17,19} Direct exposure of the carotid artery for injection would become the accepted technique for the next 20 years.

Distortion of cerebral arteries and veins or abnormal vascular structures localized solid and vascular tumors within the skull. For example, the middle cerebral artery (MCA) branches appeared to be elevated and moved rostrally due to a tumor in the temporal lobe (Figure 4).¹⁸ Identification of changes caused by a temporal lobe tumor was apparent on inspection of the MCA and anterior cerebral artery (ACA) anatomy (Figure 5).

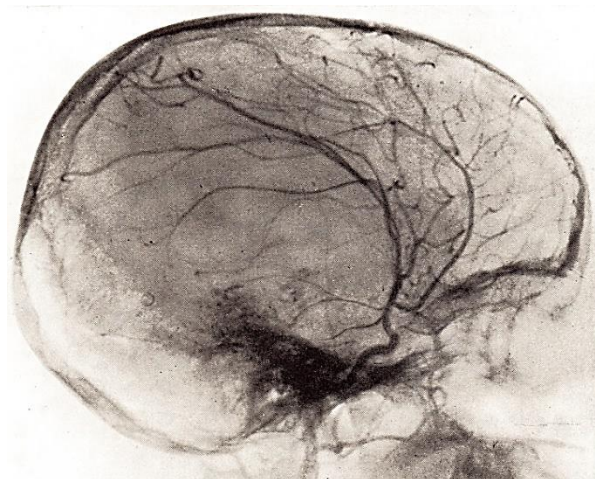


Figure 4. Cerebral angiogram (lateral view), temporal lobe tumor; anterior cerebral, middle cerebral, and posterior temporal (PT) branches are elevated and moved rostrally by temporal lobe tumor¹⁸

Moniz described the distinct vascular pattern and blood flow alterations that confirmed a diagnosis of meningioma in 1929.¹⁸ Discussion of the methods to interpret cerebral angiograms is beyond the scope of this publication. Lima's monumental publication of Cerebral Angiography provides accurate descriptions of the effects of intracranial lesions that altered normal cerebral vascular anatomy.¹⁸ This publication collected observations that constituted the third step in the path toward a complete image of the brain and its vessels.

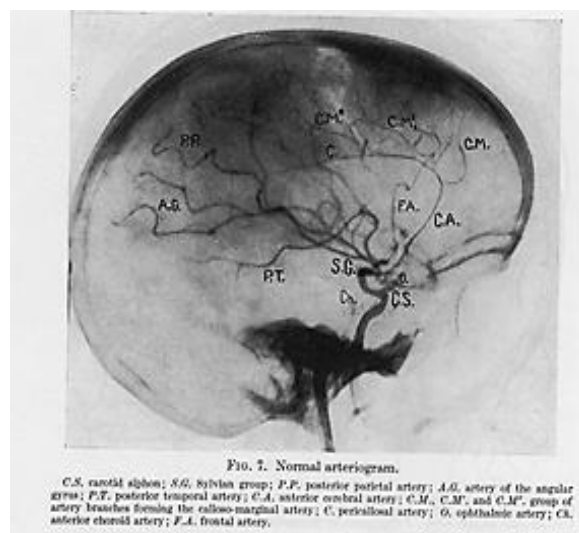


Figure 5. Lateral view; note central position of posterior temporal (PT) artery, branch of middle cerebral artery (MCA)

Attempts to improve the safety of contrast agents

for arteriography

In the 1950s, iodinated contrast agents were developed for percutaneous injections that proved to be safer than sodium iodine and were rapidly accepted. The search for better contrast agents with more chemical stability and longer shelf lives led Moniz to thorium dioxide. Thorotrast containing 25% thorium dioxide was used by Moniz in 1931. This agent was more well-tolerated by patients and produced sharper images than sodium iodine. Thorotrast contained radioactive thorium (88% by weight) that was not eliminated from the body. Thorotrast was eventually found to cause liver cirrhosis, leukemia, hemangioendothelioma, and aplastic anemia in patients many years after injections.²⁰

The next substantial improvement in the angiographic contrast agents was introduction of organically bound iodinated contrast media. These molecules are water soluble and chemically stable and contain little or no ionized or elemental iodine. Tri-iodinated compounds like diatrizoate were superior due to their reduced osmolality per iodine atom and did not cause luminal sclerosis. These agents also caused minimal hypersensitivity reactions and were rapidly excreted by the kidneys. Along with the improved safety profile of these iodinated compounds, direct carotid injection was no longer required. Far safer percutaneous carotid punctures supplanted direct injection.

Experiments with injection of contrast agents through a catheter

At the same time improved contrast agents were being investigated, revolutionary work began in the concept of catheterization of blood vessels. Werner Forssmann in Eberswalde, Germany, in 1929 inserted a number 4 Charriere ureteral catheter into his cubital vein and pushed it all the way up into the right atrium. He then walked to the radiography suite where a chest X-ray visualized the catheter in the right atrium. This film proved that Forssmann had performed the world's first right heart catheterization. However, this X-ray was the basis for his reprimand and dismissal from surgical training. Forssmann belatedly received the Nobel Prize for Medicine along with André Cournand and Dickinson W. Richards in 1956. This bold innovation paved the way for discovery of improved techniques to visualize the heart and its vessels over the next few decades.²¹

Seldinger (1921-1998), a radiologist at Karolinska Institute in Stockholm, Sweden, perfected a technique for percutaneous catheter placement into blood vessels.²² This technique paved the way for the development of the field of interventional neuroradiology. Farinas, in the 1940s, first described femoral catheterization for retrograde angiography using a natural rubber ureteral catheter inserted through a trocar.²³

Although femoral puncture caused temporary discomfort for the patient, this cannulation significantly reduced the risk of cerebral embolization when compared to direct carotid punctures that could discharge atheromatous plaques into cerebral circulation. Other risks which were significantly reduced were: creating an intimal flap, inadvertent injection of a local anesthetic into the carotid artery wall, and air embolization.

Ziedses des Plantes developed subtraction in angiography which allowed photographic elimination of all soft tissues and obscuring shadows that resulted in a distinct image of only the vascular tree.²⁴ This tool foreshadowed development of digital subtraction which provides detailed images of cerebral vessels needed to perform interventional endovascular thrombectomy.

Cerebral arteriography and interventional neuroradiology has improved stroke management

A technique described less than 90 years ago has evolved into a field where miraculous treatments of strokes and other vascular diseases are provided to patients all over the world on a daily basis. Endovascular treatment of strokes²⁵ has opened up the window of treatment to patients who previously were thought to be untreatable and destined to a life of disability and frustration. Patients with undissolved thrombi after intravenous tissue plasminogen activator (tPA)²⁶⁻³¹ treatment can have these obstructions removed through catheters that are precisely placed by angiography.³² Then a device threaded through the catheter grabs the clot and the operator removes the clot. Arterial blood flow is then restored to ischemic brain tissue.²⁵ A pooled data study has shown decreased disability when endovascular thrombectomy is performed to achieve reperfusion of ischemic brain up to 7 hours post onset of stroke.³³

Cerebral arteriography and interventional

neuroradiology changed management of arteriovenous malformations (AVMs) and aneurysms

Magnetic resonance imaging (MRI) has supplanted cerebral angiography for localization of intracranial tumors. However, angiography remains the quintessential tool for endovascular treatment of cerebral vascular anomalies. Aneurysms and AVMs are treated by techniques dependent upon cerebral angiography.³⁴⁻³⁹ These procedures have eliminated need for craniotomy that was required previously to directly apply a clip on the neck of an aneurysm. Currently, catheter-based techniques produce thrombosis in the sac of an aneurysm to prevent future rupture. AVMs are obliterated by controlled thrombosis.⁴⁰ Neurosurgeons employing catheter-guided angiography perform minimally invasive operations for cure of these diseases after which patients are discharged home within 2-3 days.

Epilogue

Moniz¹⁷ was nominated twice for a Nobel Prize in Medicine for angiography, but paradoxically was rewarded that prize in 1949 for his research and clinical trial of frontal lobotomy for intractable psychosis. This operation rapidly

fell out of favor due to its severe side effects of destroying patients' ability to plan and execute strategies. After introduction of chlorpromazine, frontal lobotomy was abandoned.⁴¹ We believe that Moniz must be remembered for his diligent research and ultimate success with discovering cerebral angiography, rather than the evanescent fame gained from the harmful and now discredited cerebral leucotomy.

Conflict of Interests

The authors declare no conflict of interest in this study.

Acknowledgments

The authors wish to thank Linda A. Lohr, MA, Manager of the Robert L. Brown, MD, History of Medicine Collection, Division of the Special Collections of the University at Buffalo, The State University of New York, United States (US), for finding many of the historical references cited in this article and Jackie Cheshire at the Archives of the National Hospital for Neurological Diseases, Queen Square, London, United Kingdom (UK) who provided access to records about Frederick Batten in that institution.

References

1. Physics 1901-1921. Amsterdam, Netherlands: Elsevier; 1967.
2. Roentgen WC. On a new kind of rays. *Science* 1896; 14; 3(59): 227-31
3. The Nobel Prize in Physics 1901. [Online]. [cited 2020 Dec 10]; Available from: <https://www.nobelprize.org/prizes/physics/1901/summary/>
4. Fowler GR. A case of gunshot - wound of the head in which the bullet was located by means of the roentgen - rays and the telephonic probe, and removed by operation. *Brooklyn Medical Journal* 1896; 10: 753-5.
5. Cushing HW. Haematomyelia from gunshot wounds of the spine. *Am J Med Sci* 1898; 115(6): 654-83.
6. Church A. Cerebellar tumor: Recognized clinically, demonstrated by the X-ray, and proved by autopsy. *Q Bull Northwest Univ Med Sch* 1899; 1(1): 33-6.
7. Alper MG. Three pioneers in the early history of neuroradiology: The Snyder lecture. *Doc Ophthalmol* 1999; 98(1): 29-49.
8. Haschek E, Lindenthal OT. A contribution to the practical use of X-ray photography. *Wien Klin Wochenschr* 1896; 9: 63-4. [In German].
9. Dandy WE. Ventriculography following the injection of air into the cerebral ventricles. *Ann Surg* 1918; 68(1): 5-11.
10. Luckett WH. Air in the ventricles of the brain following a fracture of the skull. *J Nerv Ment Dis* 1913; 40(5): 326-7.
11. Dandy WE. Roentgenography of the brain after the injection of air into the spinal canal. *Ann Surg* 1919; 70(4): 397-403.
12. Dandy WE. Localization of brain tumors by cerebral pneumography. *Amer J Roentgenol* 1923; 10: 610-2.
13. Schuller A. Roentgenographic diagnosis of intracranial affections by means of the Dandy procedure. *Wien Klin Wochenschr* 1922; 35: 709-11. [In German].
14. Taveras JM, Wood EH. Diagnostic neuroradiology. Baltimore, MD: Williams and Wilkins; 1964. p. 1-960.
15. Fulton JF. Harvey Cushing: A biography. Springfield, IL: Charles C Thomas; 1946.
16. Dandy WE. The brain. In: Lewis D, editor. *Practice of surgery*. Hagerstown, MD: Prior; 1932.
17. Moniz E. *L'Encéphalographie artérielle, son importance dans la localisation des tumeurs cérébrales*. Paris, France: Masson; 1927. p. 72.
18. Lima PA. *Cerebral angiography*. London, UK: Oxford University Press; 1950.
19. Lowis GW, Minagar A. The neglected research of Egas Moniz of internal carotid artery (ICA) occlusion. *J Hist Neurosci* 2003; 12(3): 286-91.
20. Becker N, Liebermann D, Wesch H, Van KG. Mortality among Thorotrast-exposed patients and an unexposed comparison group in the German Thorotrast study. *Eur J Cancer* 2008; 44(9): 1259-68.
21. Forssmann-Falck R, Werner Forssmann: A pioneer of cardiology. *Am J Cardiol* 1997; 79(5): 651-60.
22. Seldinger SI. Catheter replacement of the needle in percutaneous arteriography. A new technique. *Acta Radiol Suppl (Stockholm)* 2008; 434: 47-52.
23. Farinas P. A new technique for the arteriographic examination of the abdominal aorta and its branches. *Am J Roentgenol* 1941; 46: 641-65.
24. Ziedses des Plantes BG. Subtraction: A radiographic method of imaging certain parts of the object separately. *Fortschr Röntgenstr* 1935; 52: 69-79. [In German].
25. Mowla A, Singh K, Mehla S, Ahmed MK, Shirani P, Kamal H, et al. Is acute reperfusion therapy safe in acute ischemic stroke patients who harbor unruptured intracranial aneurysm? *Int J Stroke* 2015; 10(Suppl A100): 113-8.
26. Singh K, Mowla A, Mehla S, Ahmed MK, Shirani P, Zimmer WE, et al. Safety of intravenous thrombolysis for acute ischemic stroke in patients with preexisting intracranial neoplasms: a case series. *Int J Stroke* 2015; 10(3): E29-E30.
27. Shahjouei S, Tsvigoulis G, Goyal N, Sadighi A, Mowla A, Wang M, et al. Safety of intravenous thrombolysis among patients taking direct oral anticoagulants: A

- systematic review and meta-analysis. *Stroke* 2020; 51(2): 533-41.
28. Mowla A, Kamal H, Lail NS, Vaughn C, Shirani P, Mehla S, et al. Intravenous thrombolysis for acute ischemic stroke in patients with thrombocytopenia. *J Stroke Cerebrovasc Dis* 2017; 26(7): 1414-8.
 29. Mowla A, Kamal H, Mehla S, Shirani P, Sawyer R. Rate, clinical features, safety profile and outcome of intravenous thrombolysis for acute ischemic stroke in patients with negative brain imaging. *J Neurol Res* 2020; 10(4): 144-5.
 30. AbdelRazek MA, Mowla A, Hojnacki D, Zimmer W, Elsadek R, Abdelhamid N, et al. Prior asymptomatic parenchymal hemorrhage does not increase the risk for intracranial hemorrhage after intravenous thrombolysis. *Cerebrovasc Dis* 2015; 40(5-6): 201-4.
 31. Kamal H, Mowla A, Farooq S, Shirani P. Recurrent ischemic stroke can happen in stroke patients very early after intravenous thrombolysis. *J Neurol Sci* 2015; 358(1-2): 496-7.
 32. Mowla A, Doyle J, Lail NS, Rajabzadeh-Oghaz H, Deline C, Shirani P, et al. Delays in door-to-needle time for acute ischemic stroke in the emergency department: A comprehensive stroke center experience. *J Neurol Sci* 2017; 376: 102-5.
 33. Warach S, Johnston SC. Endovascular thrombectomy for ischemic stroke: The second quantum leap in stroke systems of care? *JAMA* 2016; 316(12): 1265-6.
 34. Rajabzadeh-Oghaz H, Varble N, Davies JM, Mowla A, Shakir HJ, Sonig A, et al. Computer-assisted adjuncts for aneurysmal morphologic assessment: Toward more precise and accurate approaches. *Proc SPIE Int Soc Opt Eng* 2017; 10134: 101341C.
 35. Shirani P, Mirbagheri S, Shapiro M, Raz E, Mowla A, Semsarieh B, et al. Endovascular reconstruction of intracranial aneurysms with the pipeline embolization device in pediatric patients: A single-center series. *Interv Neurol* 2020; 8(2-6): 101-8.
 36. Baharvahdat H, Ooi YC, Kim WJ, Mowla A, Coon AL, Colby GP. Updates in the management of cranial dural arteriovenous fistula. *Stroke Vasc Neurol* 2020; 5(1): 50-8.
 37. Waqas M, Rajabzadeh-Oghaz H, Tutino VM, Vakharia K, Poppenberg KE, Mowla A, et al. Morphologic parameters and location associated with rupture status of intracranial aneurysms in elderly patients. *World Neurosurg* 2019; 129: e831-e837.
 38. Varble N, Rajabzadeh-Oghaz H, Wang J, Siddiqui A, Meng H, Mowla A. Differences in morphologic and hemodynamic characteristics for "Phases-Based" intracranial aneurysm locations. *AJNR Am J Neuroradiol* 2017; 38(11): 2105-10.
 39. Rajabzadeh-Oghaz H, Varble N, Shallwani H, Tutino VM, Mowla A, Shakir HJ, et al. Computer-assisted three-dimensional morphology evaluation of intracranial aneurysms. *World Neurosurg* 2018; 119: e541-e550.
 40. Roa JA, Ortega-Gutierrez S, Martinez-Galdamez M, Maud A, Dabus G, Pazour A, et al. Transcirculation approach for endovascular embolization of intracranial aneurysms, arteriovenous malformations, and dural fistulas: A multicenter study. *World Neurosurg* 2020; 134: e1015-e1027.
 41. Valenstein ES. *Great and desperate cures: The rise and decline of psychosurgery and other radical treatments for mental illness*. New York, NY, US: Basic Books; 1986.