

The first case of myxoinflammatory fibroblastic sarcoma affecting the maxillary bone

Çetin Boran¹,
Asuman Kilitci²,
Hilal Ahsen³,
Fahri Yılmaz⁴

¹Department of Pathology, Abant İzzet Baysal University, Faculty of Medicine, Bolu, Turkey,
²Department of Pathology, Faculty of Medicine, Kırşehir Ahi Evran University, Kırşehir, Turkey,
³Department of Pathology, Ankara City Hospital, Ankara, Turkey, ⁴Department of Pathology, Faculty of Medicine, Sakarya University, Sakarya, Turkey

Address for correspondence:

Asuman Kilitci, Department of Pathology, Faculty of Medicine, Kırşehir Ahi Evran University, Kırşehir, 40000, Turkey.
E-mail: dr.asuk@gmail.com

WEBSITE: ijhs.org.sa

ISSN: 1658-3639

PUBLISHER: Qassim University

ABSTRACT

Myxoinflammatory fibroblastic sarcoma (MIFS) is rare and malignant soft-tissue neoplasms that typically present in the extremities. In the literature, MIFS has been reported in the groin, back, neck, nose, and temporal regions in addition to the extremities. We report a case of MIFS presenting with the complaints of nasal bleeding, purulent nasal discharge, and swelling on the right side of his face. Polypoid tissues protruded from the middle meatus were observed and initial diagnosis was inverted papilloma. The painless tumor was initially mistaken for low-grade myxofibrosarcoma in biopsy. Maxillectomy was performed and made the rare diagnosis of MIFS. Fibroblastic proliferation with extensive local spread from subcutaneous tissue to the epithelium of the maxillary sinus mucosa, maxillary bone, and especially along the bone marrow was observed. To the best of our knowledge, this is the first reported case of MIFS involving the maxillary bone.

Keywords: Fibroblastic sarcoma, histopathology, maxilla, myxoinflammatory

Introduction

Myxoinflammatory fibroblastic sarcoma (MIFS) is a malignant tumor of modified fibroblasts. It has been reported to be confused with various benign tumors, sarcomas, inflammatory processes, and diseases such as Hodgkin's lymphoma.^[1,2] Tumor is often located in the distal parts of the extremities, mostly in the fingers, and usually appears in the form of subcutaneous masses of 4–5 cm in diameter.

In addition to being a rare tumor, our case is located in the maxilla. There is no case of MIFS located in the maxillary bone in the literature. Therefore, the case was regarded to be valuable for reporting.

Case Presentation

A 55-year-old male patient presented to the otorhinolaryngology outpatient clinic with the complaints of nasal bleeding, purulent nasal discharge, and recently swelling on the right side of his face. Polypoid tissues protruded from the middle meatus were observed in the right nasal cavity and the patient underwent biopsy from the right middle turbinate with the initial diagnosis of inverted papilloma. The biopsy result was reported to be consistent with low-grade myxofibrosarcoma, on which the right maxillectomy was performed and the specimen was sent to the pathology laboratory.

The histopathological examination of the maxillectomy specimen revealed tumoral development characterized by intertwined fibroblastic-cellular and myxoid areas [Figure 1a and b]. In fibroblastic areas, fascicles of spindle cells were observed to extend in various directions or appeared in disorganized form. Dense lymphocyte and plasmacyte infiltration accompanying the lesion were notable [Figure 1c]. Poorly differentiated spindle cells with large rounded nuclei and prominent red nucleoli were also noted. These cells partially exhibited similar nucleolus prominence and size to Reed–Stenberg cells [Figure 2a and b]. In myxoid areas, sparsely distributed fibroblastic cells and curved capillary structures were noted in places, around which the tumor cells tended to cluster [Figure 1d]. The tumor also exhibited coagulation necrosis and sparse atypical mitoses partially [Figure 2c]. Fibroblastic proliferation was observed within the bone tissue, especially along the bone marrow.

On immunohistochemical examination, the tumor partially exhibited strongly positive staining for vimentin. Strong positivity was also remarkable in some areas for MSA [Figure 3]. Focal positivity was seen for S-100. SMA, LCA, and CD68 were negative.

Discussion

Acral MIFS was first described by Montgomery *et al.* in 1998 as an inflammatory myxohyaline tumor of the distal extremity containing Reed–Sternberg-like cells and virocytes.^[3] Shortly

thereafter, Meis–Kindblom and Kindblom published a case series of the same tumor as acral MIFS.^[4] In the same year, Michal *et al.* reported a case series of the same tumor with the title “Inflammatory myxoid tumor of the soft parts with bizarre giant cells.”^[5] In 2002, the World Health Organization used the name of MIFS of intermediate malignancy potential for this tumor.^[6]

The etiopathogenesis of MIFS is unknown. It is characterized by fibroblastic and myxoid areas on microscopic examination along with the infiltration of inflammatory cells accompanying the tumor, most of which are lymphocytes and plasmocytes. These cells may appear as spindled cells with prominent atypical nuclei, large epithelioid cells with prominent and vesicular nuclei similar to ganglion cells, Reed–Sternberg-like binucleate or multinucleated cells, and occasionally cells with multivacuolated cytoplasm resembling pseudolipoblasts.^[7,8] The immunohistochemical findings of MIFS are non-specific. According to the immunohistochemical study, the tumor cells

show strongly positive for vimentin and variable positivity for CD34, CD68, cytokeratin, and smooth-muscle actin.^[1,2,7]

In 1998, all 100 cases reported were located in the distal extremity.^[3-5,9] Therefore, the prefix of acral was adopted and the tumor was widely referred as acral MIFS. In the following years, subsequent case reports reported the tumor localization again in the distal extremities, whereas non-distal extremity cases were extremely rare. However, a few cases were reported to be located in the upper extremity and groin, and one case in the neck, which has led to the omission of the prefix acral from the nomenclature.^[3,10]

In the literature, MIFS has been reported in the groin, back, neck, nose, and temporal regions in addition to the extremities.^[7,11] In our case, it was located in the maxilla and extended to the epithelium of the maxillary sinus mucosa, which has not been previously reported. Although it can be seen in both men and women across all age groups, it most

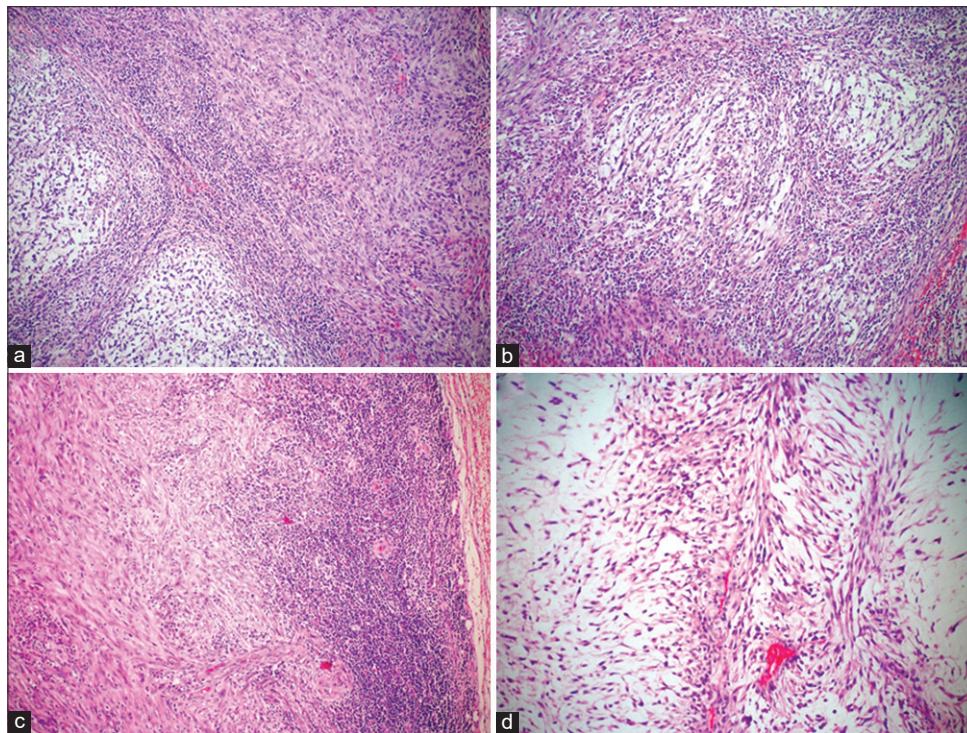


Figure 1: The tumor exhibits intertwined myxoid and cellular areas, dense cellular areas composed of spindled cells (a, b) (H and E, $\times 40$; H and E, $\times 100$). The scattered lymphocytes and plasmocytes in the tumor are notable (c) (H and E, $\times 40$). Myxoid areas, elongated vascular structures in the central part of the image, the tumor cells surrounding these vascular structures (d) (H and E, $\times 200$)

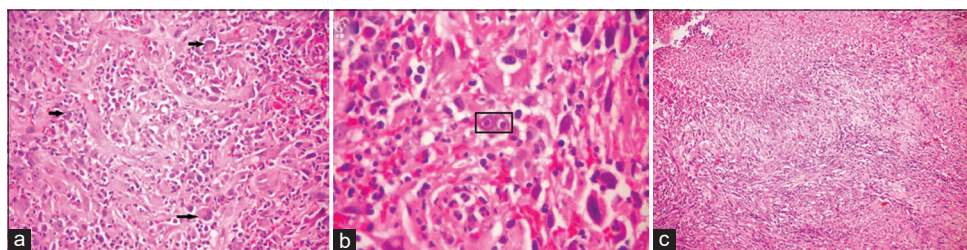


Figure 2: Giant Reed–Stenberg-like cells (a, b) (H and E, $\times 100$; H and E, $\times 200$). Diffuse coagulation necrosis in the tumor (c) (H and E, $\times 40$)

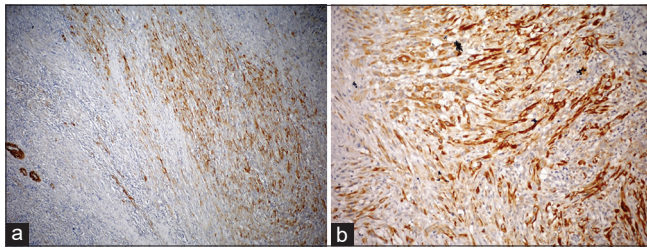


Figure 3: The neoplastic cells are positive for MSA (a) (immunostain, $\times 40$), the neoplastic cells are positive for vimentin (b) (immunostain, $\times 100$)

frequently occurs in the fourth or fifth decade of life (mean age: 40). Grossly, MIFS lesions are multinodular masses with ill-defined margins. Subcutaneous lesions often extend into tendons and ligaments, in addition to dermal involvement.^[12,13]

Benign myxoid lesions such as inflammatory lesions, tenosynovitis, nodular and proliferative fasciitis, inflammatory myofibroblastic tumor, myxoma and ganglion cyst, and malignant lesions such as myxoid malignant fibrous histiocytoma, myxoid liposarcoma, and epithelioid sarcomas are involved in the differential diagnosis. Benign lesions do not exhibit atypical cells containing virocyte-like inclusions in inflammatory and myxoid sites. Although biopsy can be performed before planning surgery, it may be difficult to detect malignancy within the myxoid tissue in needle biopsy, leading to false-positive results. Therefore, the mass should be removed with a large excision after radiological examinations in the case of suspicious differential diagnosis.^[14,15]

Conclusion

These tumors may be confused with benign lesions, especially when originating from any part of the body other than the extremities. Immunohistochemical stains in the diagnosis of MIFS can be used to exclude the lesions in the differential diagnosis, in addition to the basic histological findings. In conclusion, a painless (subcutaneous) mass should be considered in the differential diagnosis of MIFS, regardless of whether it is acral or extra-acral.

Patients' consent

Informed consent was taken from the participant.

Conflict of interest

The authors declared no conflict of interest.

Funding

None.

References

- Martín CG, Ortega MI, Aramburu JA, Fernández-Cañamaque JL. Myxoinflammatory fibroblastic sarcoma of the face. *Am J Dermatopathol* 2012;34:663-5.
- Narm KS, Park IK, Bae MK, Kim GJ. Myxoinflammatory fibroblastic sarcoma in the chest wall. *Korean J Thorac Cardiovasc Surg* 2012;45:65-8.
- Montgomery EA, Devaney KO, Giordano TJ, Weiss SW. Inflammatory myxohyaline tumor of distal extremities with virocyte or Reed-Sternberg-like cells: A distinctive lesion with features simulating inflammatory conditions, Hodgkin's disease, and various sarcomas. *Mod Pathol* 1998;11:384-91.
- Meis-Kindblom JM, Kindblom LG. Acral myxoinflammatory fibroblastic sarcoma: A low-grade tumor of the hands and feet. *Am J Surg Pathol* 1998;22:911-24.
- Michal M. Inflammatory myxoid tumor of the soft parts with bizarre giant cells. *Pathol Res Pract* 1998;194:529-33.
- Kindblom LG, Meis-Kindblom JM. Myxoinflammatory fibroblastic sarcoma. In: Fletcher CD, Unni KK, Mertens F, editors. *Pathology and Genetics of Tumors of the Soft Tissue and Bone*. World Health Organization Classification of Tumours. Vol. 4. Lyon: IARC Press; 2002. p. 96-7.
- Numminen J, Bizaki A, Kujansivu J, Huovinen S, Rautiainen M. Myxoinflammatory fibroblastic sarcoma of the nose: First reported case at an unusual location (nasal dorsum), with a review of the literature. *Ear Nose Throat J* 2016;95:E32-5.
- Mallya V, Singh A, Siraj F, Ramesh V. Myxoinflammatory fibroblastic sarcoma: An uncommon tumour at an unusual site. *Indian J Dermatol* 2014;59:297-8.
- Miettinen M, editor. *Diagnostic Soft Tissue Pathology*. 1st ed. New York: Churchill Livingstone; 2003. p. 196.
- Kobayashi E, Kawai A, Endo MY, Takeda K, Nakatani F, Asona T, *et al.* Myxoinflammatory fibroblastic sarcoma. *J Orthop Sci* 2008;13:566-71.
- Lucas DR. Myxoinflammatory fibroblastic sarcoma: Review and update. *Arch Pathol Lab Med* 2017;141:1503-7.
- Hassanein AM, Atkinson SP, Al-Quran SZ, Jain SM, Reith JD. Acral myxoinflammatory fibroblastic sarcomas: Are they all low-grade neoplasms? *J Cutan Pathol* 2008;35:186-91.
- Pérez-Pérez M, Manzotti C, Mateos MM, González-Cámpora R, Ríos-Martín JJ. Myxoinflammatory fibroblastic sarcoma: A rare case affecting only the dermis. *J Cutan Pathol* 2020;47:414-5.
- Raghavan VH, Satish S, Ravishankar S, Manjunath GV. Myxoinflammatory fibroblastic sarcoma of the thigh: A morphologic diversity. *Avicenna J Med* 2012;2:74-6.
- Ertener O, Tuna B, Akçali Ö, Yörükoğlu K. Myxoinflammatory fibroblastic sarcoma: A case report. *Acta Orthop Traumatol Turc* 2013;47:436-9.