

## EXPERIMENTAL NEPHRITIS IN THE FROG

### I. THE ANATOMICAL EVIDENCE OF DAMAGE\*

By JEAN OLIVER, M.D., AND PEARL SMITH, M.D.

(From the Departments of Pathology of the Medical School of Stanford University, California, and of the Long Island College Hospital School of Medicine, New York)

PLATES 7 TO 9

(Received for publication, April 25, 1930)

In the complex problems which have arisen in the study of nephritis the experimental method has proved a useful adjunct. Many aspects of the disease which can be examined only at the end of long continued processes in man and which, therefore, remain obscure to purely anatomical investigation, become relatively simple when examined during their development by this method which allows freedom of procedure and more rigid control to the investigator.

In one aspect, however, the advance has not been encouraging, and that is the correlation of disturbances in the function of the organ with changes in its anatomical structure. Various reasons are evident for this situation. The normal function of the kidney is far from understood, and this is particularly true of the complex kidney of mammals. A further complicating factor is that the nephritis which develops under experimental conditions is of almost as involved a nature as that found in the disease of man.<sup>1</sup> The first and great advantage of the experi-

\* This investigation has been made with the assistance of a grant from the Committee on Therapeutic Research, Council on Pharmacology and Chemistry, American Medical Association.

<sup>1</sup> An example of this is found in the different interpretations which have been offered for the histogenesis of experimental chronic uranium nephritis in mammals. Dickson (*Arch. Int. Med.*, 1909, **3**, 375; 1912, **9**, 557) believes the chronicity of the lesion to be the result of a vascular lesion; Susuki and Aschoff (*Verhandl. Deut. path. Gesel.*, 1912, **15**, 199) to a hydronephrotic factor, and Oliver (*Journ. Exp. Med.*, 1915, **21**, 425; 1916, **23**, 301) to a direct inflammatory stimulation of the connective tissue.

mental method, namely, the simplification and control of conditions, is not therefore really available in its full extent when mammals are subjected to its procedures.

An analogous situation has been recognized by the physiologists in their work and these difficulties met by modification of the direction of their attack. The work of Richards (1), Bieter and Hirschfelder (2), Marshall (3), and Höber (4), to mention but a few, in which direct methods have been applied to simple kidneys has objectively established a few certain facts and thus removed them from the field of hypothesis where they had so long remained. The application of these newer methods to the study of the abnormal kidney is an obvious step. Direct experimentation, as Richards has termed it, both by visual observation of the living functioning organ and by perfusion of it, a method so brilliantly used by Höber and his pupils, might be used with the simple kidney of the frog in which abnormalities have been produced. It is possible that this might allow of the establishment of a base from which a later extension to the more complicated conditions obtaining in the abnormal mammalian kidney could be taken.

The present investigation is the first of a series of such studies of experimental nephritis in the frog.<sup>2</sup> As a first step, the method of production of the experimental lesions in the frog's kidney is described and the types of nephritis which may be produced in the animal detailed. In subsequent articles changes in the circulatory reactions of kidneys in which an experimental nephritis has been produced will be described and contrasted with those of the normal kidney. The response of the kidney, as tested by the method of perfusion, to damage of limited extent and of controlled nature as it may be produced in the isolated organ will next be given. The final step will be the presentation of a similar functional study of the disease as it exists when produced in the living frog and a correlation of these changes with the anatomical findings in the light of what we have learned with this "artificial" nephritis in the isolated organ.

<sup>2</sup> Four studies preliminary to this series, concerned with certain physiological aspects of our problem have appeared in the *Journal of Experimental Medicine*, 1929, 50, 15; 1929, 50, 601; 1930, 51, 161; and the *American Journal of Physiology*, 1930, 93, 363.

### *Methods*

The animals used were chiefly *R. catesbiana*, since their kidneys are large and show the lesions most satisfactorily.

In our choice of renal poisons we have been guided by past studies of the similar problem in mammals. The list of agents we have used are: corrosive sublimate, potassium bichromate, uranium nitrate, ricin, cantharidin and snake venom. The first three substances have been classified from the lesions which they produce in mammals as tubular poisons, while the last three are reported to affect with more or less specificity the vascular apparatus of the kidney.

The experimental procedure was as follows.

Various amounts of a substance were injected into the dorsal lymph sacs of the frogs and the animals returned to their water tanks. After definite periods of time they were killed and portions of their kidneys fixed in 10 per cent formalin, Orth's fluid, Bensely's mixture, and Kolster's fixative. Sections were stained with hematoxylin and eosin, Van Gieson's mixture, iron hematoxylin, Mallory's connective tissue stain, Weigert's fibrin stain and for the mitochondria by Bensely's and Kolster's methods. In all cases great care was taken to fix the kidney tissue promptly after death. Post mortem change is extremely rapid if the frog lies dead in the tank and the autolytic changes resemble somewhat those which may occur as a result of toxic substances. For this reason frogs found in the morning, which might possibly have died earlier in the night were discarded and dying animals were killed as soon as their condition was detected. An apparent variation was frequently noted in the toxicity of a given substance when administered to different frogs. This we think was the result of diffusion of the substance from the dorsal lymph sac of the frog through the puncture wound into the water of the tank. Such irregularities may be largely avoided by intraperitoneal injection but the possibility of their occurrence must be kept in mind in the comparison of lesions in different animals.

We would call attention to the fact that the frog may suffer from spontaneous lesions of the kidney. These are the result of a general parasitic infection of the animal in which focal lesions develop in the kidney as well as in other organs. These lesions, consisting of circumscribed round areas of necrosis filled with nuclear débris which involve all the tissue cells indiscriminately in the infected focus, may be easily recognized. All frogs which were found to be so infected were discarded.

## EXPERIMENTAL

*The Lesion with "Vascular" Poisons*

We were unable to produce constant lesions in the kidneys of the frogs which had been injected with the so-called vascular poisons. In the case of cantharidin the insolubility of the substance in water requires a solvent, acetic ether, which is even more toxic than the drug. The animals succumbed in a short time to the injection 0.5 cc. and if given in lesser amounts so little cantharidin was administered that no ill effects were noted after repeated injections. Large repeated injections of ricin, totaling 10 cc. of a saturated saline solution in the course of 3 days, produced no ill effects and the kidneys appeared entirely normal. The animals were also resistant to the action of snake venom. Doses which would be enormous for mammals did not kill the frogs, and when death followed repeated injections the kidneys showed no definite or constant effects.

These experiments, on account of their negative findings, are not described in detail but may be summarized by the statement that we were unable to produce lesions with regularity by the use of these substances.

*The Lesion with "Tubular" Poisons**Corrosive Sublimate*

The amount of corrosive sublimate injected into the animal varied from 1 to 7.5 mg. The average weight of the frogs being 500 gm. this equals an average dosage of 8 mg. per kilo. As mentioned before considerable variation in the apparent effect of the drug was noted but these irregularities were avoided by disregarding those animals in which the experiment had failed to damage the kidneys.

As in mammals a striking feature of the action of the sublimate was the damage to the tubular epithelium (Fig. 1).

This was apparent within 18 hours following the injection and in this early period consisted of marked cloudy swelling of the tubular epithelium with occasional necrosis and desquamation. The seat of the lesion was definitely limited to

the broad proximal convoluted segment of the renal tubule, the narrow neck, distal convoluted portion and the collecting tubules remaining essentially normal.<sup>3</sup>

In the mitochondrial preparations the usual evidences of early cellular damage were found. The granules in the involved portion of the tubule were swollen and irregularly distributed in agglutinated clumps and masses. In some necrotic cells these irregular clumps of heavily stained material persisted while in others solution of the substance had occurred so that the dead cell body was free of any granular substance. In these early stages of the damage the batonnets of the distal convoluted tubule stained normally.

In striking contrast to the effects of sublimate on mammals was the early and constant evidences of damage which were observed in the glomeruli.

In many cases these lesions were present in kidneys whose tubules showed little if any abnormalities and they were constantly found in those where the damage was at all severe. The simplest abnormality observed was the deposit of granular material in Bowman's space. This material was in some cases arranged in fibrin-like threads but its staining reaction was not that of typical fibrin. In other cases this material was condensed and deposited on the surface of the glomerular tuft where it formed a thin dense covering which followed the indentations between the capillaries into the central portions of the structure. Such appearances were, however, usually noted in kidneys which were more severely damaged than those which we are at present describing. Beside these lesions in the tubules and glomeruli the interstitial tissue showed a slight edema, and some general hyperemia of the capillaries between the tubules was occasionally present.

In animals which had received the larger doses and which had lived 70 hours the lesions were much further developed and consequently were more severe.

Extensive necrosis of the tubular epithelium was present and the desquamated dead cells filled the lumen of the proximal convoluted tubule. This portion in fact no longer existed except as a space within the membrana propria which was packed solid with granular débris. The damage in such kidneys had also spread both back toward the glomerulus and in the opposite direction, so that examples might be found where the neck and the distal convoluted tubule were also destroyed. The collecting tubules were only slightly altered. In them, however, was found débris, evidently derived from higher reaches of the tubule, and here

---

<sup>3</sup> We have used the terminology of Stewart (5) because of its analogies with that used for the mammalian kidney. Proximal convoluted tubule is synonymous with Segment II, distal tubule with Segment III, and collecting tubule with Segment IV of other writers.

also definitely formed casts were present. They were of the hyaline type as a rule, though some contained granular material. It was a striking finding that such fully formed consolidated casts were found almost only in the distal convoluted tubule and in the excretory ducts and were seldom seen in the proximal portion of the tubule where the active damage was occurring. For this reason in a frontal section through the kidney a peculiar distribution of them was found since they were clustered in those sections of the tubule that lay around the glomeruli in the middle and ventral portions of the kidney.

The glomeruli of such kidneys showed even greater damage than has been described. The same collections of fibrinoid substance in Bowman's space were found but in the tissues of the tuft definite changes were also observed. Intense engorgement with the formation of hyaline thrombi composed of agglutinated red blood cells and scattered areas of edema and even necrosis were present. Patches of nuclear debris were scattered among the loops and occasionally a tuft could be found so severely damaged that hemorrhage had occurred into the capsular space. On the other hand some damaged glomeruli were anemic, and might be found greatly altered and even disrupted without any escape of blood from their capillaries. These glomerular lesions were at times the most striking abnormality found in the kidneys. In the kidney of one animal which had received 1 mg. and was killed on the second day the tubules showed no very definite lesions, yet the glomeruli were severely involved.

In the tubules of the kidneys of animals which showed these severe glomerular lesions beside the hyaline and granular cast mentioned above, red blood cells were occasionally found either still discrete and in varying degrees of disintegration or consolidated into definite blood casts (Fig. 2).

Beginning about 3 or 4 days after the injection of the toxic substance reparative processes could be found in the kidneys.

These consisted of regenerative proliferation of the epithelium of the tubules which had been damaged. In the persisting cells, scattered through the region of the tubule which was most severely involved, and at the junction of this part with portions of the tubule which were relatively undamaged, mitotic figures were frequent. One such source of new formed cells was regularly found in the collecting tubules which were rarely damaged by the toxic agent. Cross sections of these tubules showing marked proliferative changes in the epithelium might be found scattered among the necrotic tubules of kidneys which had been so severely damaged as to show destruction of not only the proximal convoluted tubule but of the distal as well.

The new formed cells could be recognized by their unusual appearance. Their nuclei were large, often twice the size of those of the original tubule cell and were as a rule oval in shape. Their chromatin was increased in amount and stained quite heavily. Such nuclei were both excessive in number and irregularly dis-

tributed so that they formed irregular giant cell-like masses covered with protoplasm which projected irregularly into the lumen of the tubule. From such centers of proliferation the cells spread out over the denuded membrana propria. These new formed cells were found apparently creeping beneath detritis and casts which filled the tubule lumen so that in specimens 14 days old the lining of the tubules was found to be completely restituted, though the new cells could be still distinguished from the regularly arranged lining of the original epithelium.

Repair in the glomeruli seems to be a much slower process. The remains of the early lesions could still be made out after 14 days, a time when the tubular damage had been largely repaired. The more acute process of hyperemia had disappeared from the tuft but granular material and fibrinoid substance was still present in Bowman's space. Very occasionally mitotic figures were found in the tissues of the tuft, but no definite "chronic" lesions such as organization or definite proliferation of the tuft tissues were present.

#### *Potassium Bichromate*

The lesions after potassium bichromate resembled in a general way those following the administration of corrosive sublimate. Certain minor differences were observed, however, particularly in the early phases of the damage or in kidneys that had only been slightly affected. The amount of drug given varied from 0.5 to 5 mg. per animal so that the dosage varied around an average of 5 mg. per kilo.

In the kidneys of frogs which were killed within 24 hours after smaller doses or in animals which succumbed in 2 or 3 days but whose kidneys were but moderately damaged, only the earlier and milder types of degeneration were found in the tubular epithelium. The lumen of the tubule throughout its length was filled with granular detritis, the cells showed a cloudy swelling with the presence of an occasional pycnotic nucleus, but little evidence of frank necrosis was present. This cellular damage, as in the case of corrosive sublimate, was limited to the proximal convoluted tubule.

In kidneys showing such slight lesions, the glomeruli, however, were almost constantly involved. Granular or fibrinoid material in Bowman's space with desquamation of the capsular epithelium, hyaline thrombosis and occasional small areas of necrosis with hemorrhage into the capsular space could be found (Fig. 3). In the interstitial tissue hyperemia was often intense, the capillaries between the tubules being crowded with red blood cells. Only a moderate number of casts of the hyaline type were present in the distal convoluted tubule and in the collecting tubules, though granular material was present throughout the entire renal unit. Occasionally collections of red blood cells still discrete or partially disintegrated could be found in the tubule lumen or were definitely formed into blood casts.

In more severely damaged kidneys the microscopic picture resembled even

more closely that seen after corrosive sublimate, for tubular damage was now equally severe, the entire proximal convoluted portion being necrotic and the tubule transformed into a mass of dead desquamated cells. This damage also spread both into the narrow neck and into the distal convolution. The glomerular lesions, exudation of granular and fibrinoid material, necrosis and hemorrhage, were more pronounced and casts of all sorts were present in the lumina of the tubules (Fig. 4).

Beginning at the third or fourth day regenerative changes in the damaged tubules were apparent. Their course was similar to that seen after sublimate, large irregular masses of epithelium filling the tubule lumen with giant cell-like structures. Mitotic figures were frequent among their large oval nuclei (Fig. 5). Repair was only slight in the glomeruli and in most cases proliferative changes could not be definitely determined.

The lesions after bichromate poisoning therefore differ somewhat from those following the administration of sublimate in that although the glomerular damage was equally intense the tubular lesions were somewhat slower to develop. In the end, however, they became equally severe.

#### *Uranium Nitrate*

After the administration of from 5 to 10 mg. of the uranium nitrate, averaging 15 mg. per kilo, lesions developed resembling those following potassium bichromate more closely than those produced by corrosive sublimate. On account of this similarity they will be only briefly described.

In cases of mild damage or during the first 24 hours of the development of the lesion, the tubules showed only slight evidences of cellular damage such as cloudy swelling and occasional necrosis. The glomeruli were regularly involved by the milder changes which produced an accumulation of protein material in the capsular space (Fig. 6). As the poisoning became more severe or the slighter changes more fully developed, the tubular damage was more pronounced until it equalled that seen with potassium bichromate (Fig. 7). It was only occasionally, however, that the typical picture following corrosive sublimate could be obtained, that is, a complete destruction of the entire proximal convoluted tubule and the replacement of it by masses of dead disintegrating cells. The interstitial lesions of edema and hyperemia, though present, were also less pronounced.

In the severely damaged kidney, the appearance is approximately the common picture seen after all these toxic agents. The glomeruli were engorged, hyaline thrombi were present, small areas of necrosis of the tuft could be seen and hemorrhage into Bowman's space (Fig. 8). In the proximal convoluted portion definite



necrosis with desquamation filled the lumen of the tubule with débris, and casts, both granular and hyaline, were present in the distal convoluted and collecting tubules.

In animals which lived from 4 days to a week the irregular regenerative proliferation of the surviving epithelium in the damaged tubule was very apparent. In one animal which was killed 18 days after the administration of the poison the necrotic material and other evidences of early damage were almost entirely removed, only an occasional cast still persisting in the tubules, yet the abnormal condition of the proximal convoluted tubule was apparent in the excessive number of atypically new formed cells which formed its lining.

#### DISCUSSION

In a general way the lesions produced in the frog's kidney by potassium bichromate, corrosive sublimate and uranium nitrate are similar and resemble those which have been described as occurring in mammals. The significance of the differences observed, however, requires a brief discussion.

Of the tubular apparatus, in the frog as in the mammal, it is the proximal convoluted tubule which suffers most severely. For the latter group this point was first clearly established by Susuki (6) in his studies by means of vital staining. Although such special methods are required for the recognition of this point in the complex mammalian kidney, in the more simply arranged mesonephros of the frog the localization of the damage in the broad proximal convoluted tubule can be easily determined by means of its characteristic morphology and by the situation of this segment in the organ. As in the mammalian kidney, so too in the frog's mesonephros this limitation of the damage to a restricted portion of the tubule is observed only with small or moderate doses of the toxic agent. After the administration of large doses the damage spreads both toward the glomerulus and into the distal convoluted tubule. The straight portion of tubule connecting the two convoluted portions is thus involved as well in the lesion and though it can hardly be considered a loop of Henle, nevertheless its involvement in the spreading lesions is analogous to the fate of that structure under similar conditions in the mammal.

It is corrosive sublimate in the frog as in the mammal which produces the most extreme picture of tubular damage. We might point out, however, that the striking appearances seen after this substance

do not necessarily indicate a lesion of any greater severity than that which follows potassium bichromate or uranium nitrate where the histological picture is less impressive. In both cases the cells are killed but after sublimate the coagulation of the débris into massive blocks of deeply staining material contrasts with the disintegration of the dead cells which occurs after the administration of the other two poisons. The possibility of error in the estimation of the quantitative relation of the damage in the different forms of poisoning is therefore obvious.

In the effect of these "tubular" poisons on the glomeruli of the frog's kidney differences which at first hand may seem to be significant are observed. After all the poisons the glomeruli were regularly and definitely damaged. This damage was of equal degree to that seen in the tubules; in fact observations were recorded where the glomerular lesion was plainly evident in kidneys whose tubules showed very slight if any morphological evidence of involvement. The exudation of protein into Bowman's space in both granular and fibrinoid form, necrosis and thrombosis in the tuft tissues and hemorrhage from ruptured capillaries were regularly present. Such a regularity of striking morphological lesions has not been found in the mammalian kidney after similar treatment. It is a fact of great importance, nevertheless, that such lesions do occur though as a rule they are inconstant in occurrence or so slightly developed as to require some attention for their observation. After corrosive sublimate, both in animals and in fatal poisoning in man, it is not unusual to find protein material exuded into Bowman's space, and there is other evidence that the vessels throughout the kidney have also been damaged. Oertel (7) has emphasized the importance of these changes. Glomerular lesions of slight degree such as pycnosis of the nuclei of the tuft cells and the occurrence in them of hyaline degeneration have been described by Christian and O'Hare (8) as occurring occasionally after uranium poisoning. Furthermore the experiments of Wiesel and Hess (9) have shown that those glomeruli which may appear normal to morphological examination after the administration of uranium nitrate are in fact severely damaged, for a subsequent injection of adrenalin causes their weakened capillaries to burst and produces glomerular hemorrhages throughout the kidney.

It would seem, therefore, that the glomerular lesions which in mammals present only slight or inconstant morphological evidences of damage, are regularly observed, well developed and visible to simple methods of demonstration in the frog's kidney. The differences between the lesions in the two classes of animals is only a quantitative one, for qualitatively they are essentially similar.

The frog's mesonephros is particularly well suited therefore for the study of lesions which remain masked in the complex kidney of mammals. The importance of this point which forms the basis of our entire program of investigation will become increasingly apparent as the results of our investigations of nephritis in the frog by other methods are given. For this reason it is obviously too early a point in our work to discuss either the "nature" of the changes which are observed in these forms of kidney damage, or to attempt a classification of the toxic substances as either "tubular" or "vascular" since but one aspect of the problem, the morphological, has been given. The equally important functional manifestations of the lesions will be next considered.

#### SUMMARY

1. The damage produced by corrosive sublimate, potassium bichromate and uranium nitrate in the frog's kidney is described.
2. The morphological lesions consist of evidences of tubular damage, such as regressive changes in the epithelium, and of damage to the glomeruli ranging from increase in their permeability to gross damage of and hemorrhage from the tuft.
3. The point is emphasized that these lesions differ in their degree rather than in their nature from those found in the mammalian kidney after the administration of the same poisons.
4. The frog's kidney is exceptionally well suited therefore for the study of lesions which though present are masked in the complexities of structure and function of the mammalian kidney.

#### BIBLIOGRAPHY

1. Richards, A. N., *Methods and Results of Direct Investigations of the Function of the Kidney*, Williams and Wilkins, Baltimore, 1929.
2. Bieter, R. N., and Hirschfelder, A. D., *Amer. Journ. Physiol.*, 1924, **68**, 326.

3. Marshall, E. K., Jr., and Crane, M. M., *Amer. Journ. Physiol.*, 1924, **70**, 465.
4. Höber, R., *Klin. Arch.*, 1927, **6**, 671.
5. Stewart, S. G., *Anat. Record*, 1927, **36**, 259.
6. Susuki, T., *Zur Morphologie der Nierensekretion unter physiologischen und pathologischen Bedingungen*, Jena, 1912.
7. Oertel, H., *The Anatomic Histological Processes of Bright's Disease*, W. B. Saunders Co., Philadelphia and London, 1910.
8. Christian H., and O'Hare, J. P., *Journ. Med. Research*, 1913, **28**, 227.
9. Wiesel, J., and Hess, L., *Wien. klin. Woch.*, 1914, **27**, 588.

## EXPLANATION OF PLATES

Unless otherwise stated the sections of kidney were stained with Delafield's hematoxylin and eosine.

## PLATE 7

FIG. 1. Kidney from an animal killed 48 hours after the injection of 5 mg. of corrosive sublimate. The section shows the central and dorsal zones (Stewart) of the kidney, the glomeruli and distal convoluted tubules lying in the former (upper half of section) and the broad proximal convoluted portions in the latter (lower portion of section). There is some granular material in the capsular spaces of the glomeruli. The cells of the proximal segment of the tubule are mostly necrotic and desquamated. Clustered around the glomeruli, the distal convoluted portions still show nuclear staining as do many of the straight portions which connect the two convoluted segments. 130×.

FIG. 7. Section shows the junction of the central and dorsal zones of the kidney of a frog which was killed 72 hours after the injection of 5 mg. of uranium nitrate. The capsular spaces of the glomeruli are filled with granular débris. There is widespread necrosis and desquamation of the epithelium of the proximal convoluted tubule in the lower part of the section, and somewhat less pronounced but similar lesions in the distal portion above. 130×.

## PLATE 8

FIG. 2. The central zone of a kidney from an animal killed 72 hours after the injection of 1 mg. of corrosive sublimate. The section shows the glomeruli and surrounding distal convoluted segments. Although the epithelium of these portions is fairly well preserved many casts composed of disintegrated and agglomerated red blood cells are seen in their lumina. 120×.

FIG. 3. The junction of the central and ventral zones of the kidney of a frog killed 48 hours after the injection of 5 mg. of potassium bichromate. Lighter areas of necrosis containing nuclear débris are seen in the greatly swollen glomeruli. In spite of this glomerular damage the sections of tubules in the lower left corner, which are the terminal portions of the proximal convoluted tubule, show no definite lesions. 140×.

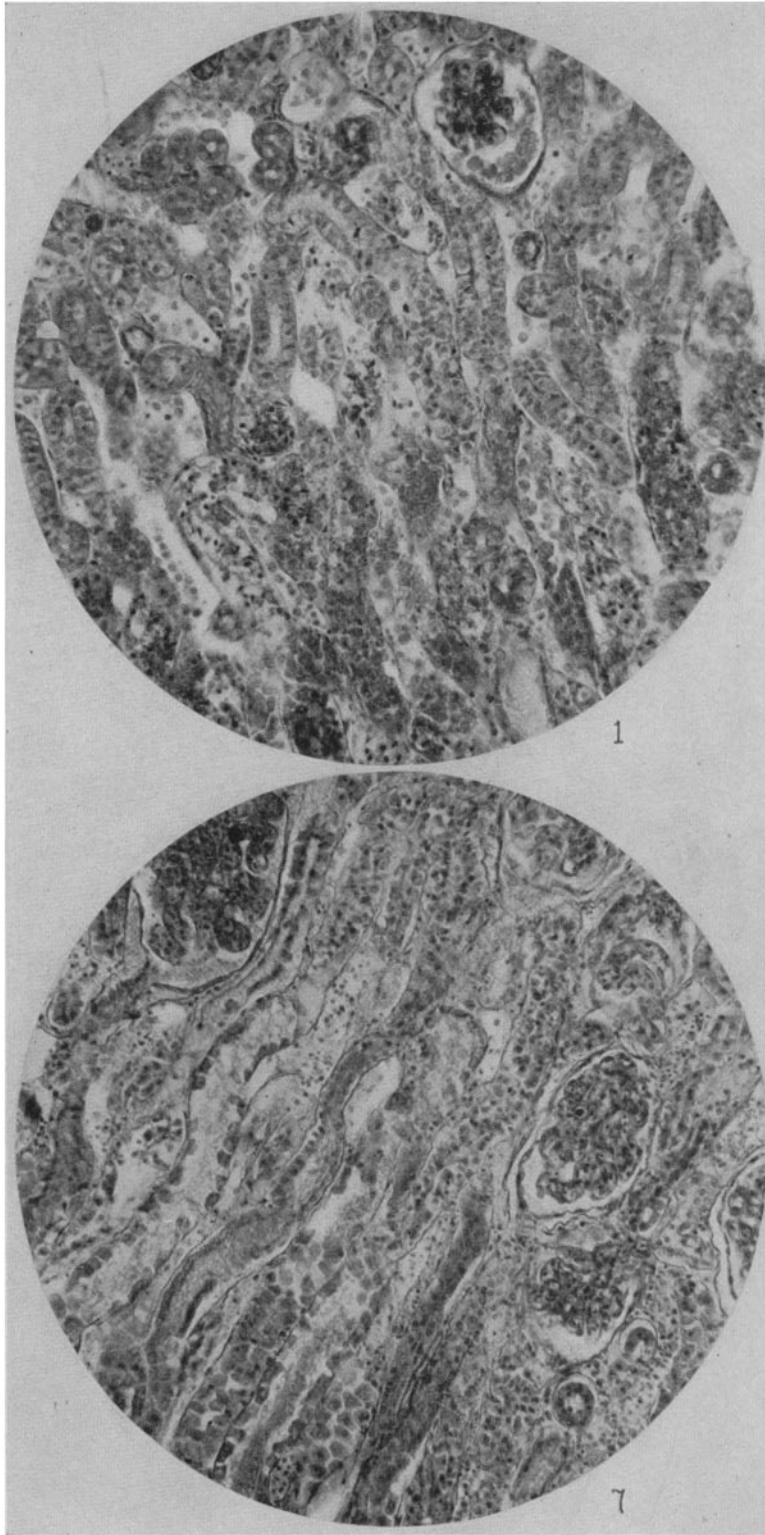
FIG. 4. Kidney of a frog killed 72 hours after the injection of 2 mg. of potassium bichromate. The section is stained with Mallory's connective tissue stain. Only a portion of the central zone of the kidney is shown. In this zone the distal convoluted tubules are filled with hyaline casts (deep blue). Covering the glomerular tuft and extending into it is a layer of fibrinoid material, which also stains deep blue rather than red as would true fibrin. 170 $\times$ .

## PLATE 9

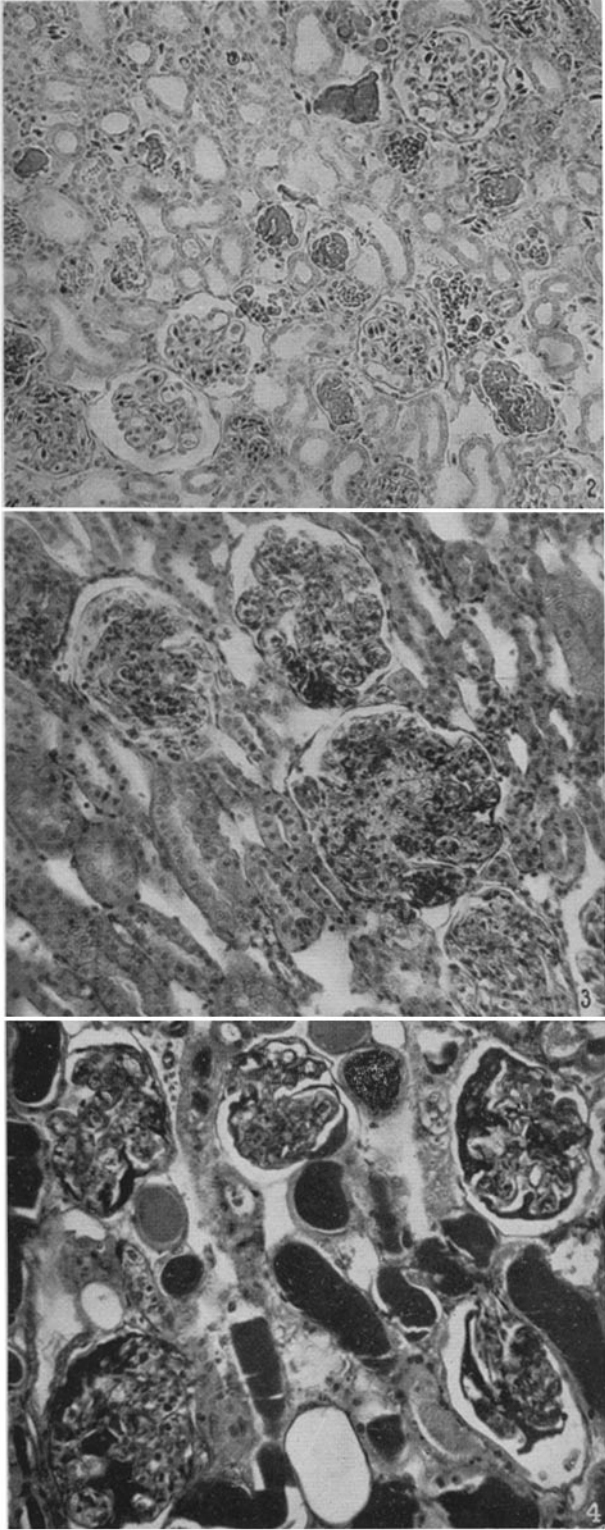
FIG. 5. Section through the dorsal zone of a kidney of a frog which had been killed 120 hours after the injection of 5 mg. of potassium bichromate. Stained with iron hematoxylin after formalin fixation, a method which does not preserve the granular elements of epithelium. The lining of the proximal convoluted tubule, the only segment shown in the section, is composed of an excessive number of large regenerated cells whose nuclei are oval, and irregular in size, shape and distribution. A mitotic figure is seen in one of the upper cross sections. 500 $\times$ .

FIG. 6. Section passing through the junction of the central and dorsal zones of a kidney from an animal which had been killed 72 hours after the administration of 5 mg. of uranium nitrate. The capsular space of all the glomeruli is filled with granular exudate. The cells of the distal convoluted tubules show moderate damage, but much less than the proximal convoluted segments which are not shown in the figure. 140 $\times$ .

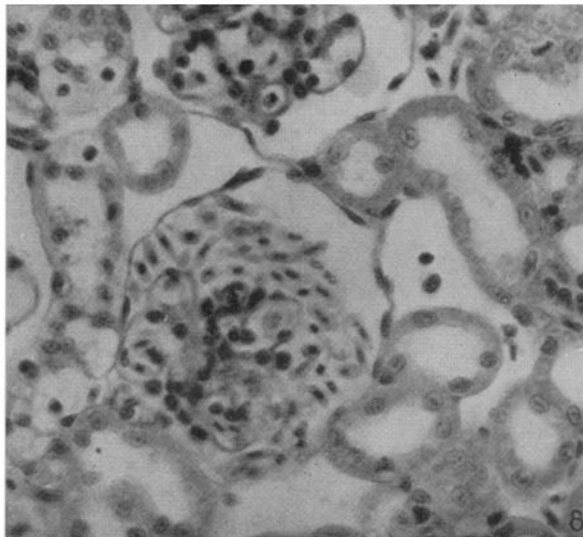
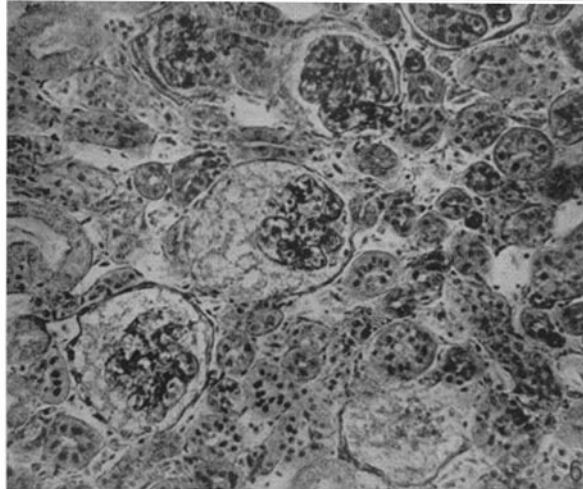
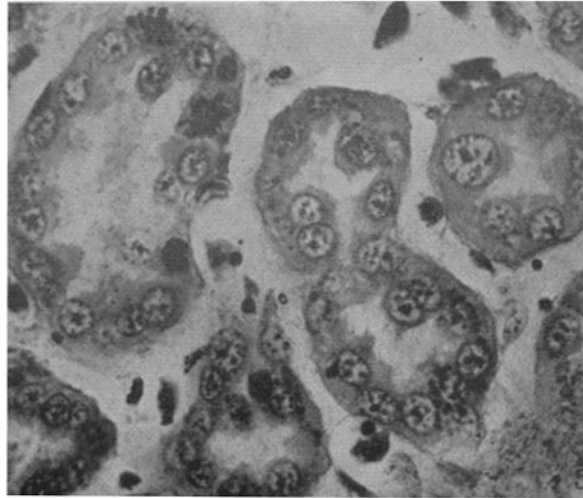
FIG. 8. Section shows a small portion of the central zone of a kidney from a frog killed 24 hours after the injection of 8 mg. of uranium nitrate. The sections through the distal convoluted tubules show them to be apparently normal. In the glomerular space is a recent hemorrhage from the tuft. The nucleated red blood cells are still well preserved. 300 $\times$ .



(Oliver and Smith: Experimental nephritis in the frog. I)



(Oliver and Smith: Experimental nephritis in the frog. I)



(Oliver and Smith: Experimental nephritis in the frog. I)