



## Case report

# Delayed presentation of retained acrylic intraocular lens (IOL) fragment after uncomplicated cataract surgery



Cara E. Capitena, Kevin Gamett, Mina B. Pantcheva\*

University of Colorado School of Medicine, Department of Ophthalmology, Denver, CO 80045, USA

## ARTICLE INFO

*Article history:*

Received 25 January 2016

Accepted 11 May 2016

Available online 13 May 2016

*Keywords:*

Haptic fragment

Routine phacoemulsification

## ABSTRACT

**Purpose:** To report a case of delayed presentation of a severed acrylic single-piece intraocular lens (IOL) haptic fragment causing corneal edema after uneventful phacoemulsification surgery.

**Observations:** An 85-year-old male presented with inferior corneal decompensation six months after a reportedly uneventful phacoemulsification in his left eye. A distal haptic fragment of an acrylic single-piece posterior chamber intraocular lens was found in the inferior anterior chamber angle. Intraoperative examination revealed that the dislocated fragment originated from the temporal haptic, the remainder of which was adherent to the anterior surface of the capsular bag. The clipped edge of the haptic fragment showed a clean, flat surface, suggesting it was severed by a sharp object. The findings were considered consistent with cutting of the fragment during implantation presumably from improper lens loading, improper implantation technique, or defective implantation devices.

**Conclusions and Importance:** This is the first case report of a foldable acrylic intraocular lens severed during routine uncomplicated cataract surgery that was not noted at the time of the surgery or in the immediate postoperative period. Delayed presentation of severed IOL fragments should be considered in cases of late onset corneal edema post-operatively, when other causes have been ruled out. Careful implantation technique and thorough examination of the intraocular lens after implantation to assess for lens damage intraoperatively is essential to avoid such rare complications.

© 2016 The Authors. Published by Elsevier Inc. This is an open access article under the CC BY-NC-ND license (<http://creativecommons.org/licenses/by-nc-nd/4.0/>).

## 1. Introduction

Dislocated intraocular lens (IOL) fragments, either fractured or deliberately cut, such as during IOL exchange, are known to cause corneal decompensation secondary to endothelial cell loss [1–4]. These fractures can occur with trauma, as has been reported with single-piece poly(methyl methacrylate) (PMMA) IOLs [3,5–8]. However, they have also been reported to occur during implantation. In 2010, a video case was presented of a three-piece IOL which haptic was pulled free from the optic during implantation [9]. Three-piece lenses have also been reported to have non-traumatic late-onset haptic disinsertion – a complication unique to these lenses thus far [10].

To date, there have been several case reports of corneal decompensation secondary to retained acrylic IOL fragments, which were deliberately cut during IOL exchange [2,3]. Further, there have been two cases reported of acrylic IOLs being damaged

during implantation; however, in both cases the complication was recognized immediately and appropriate steps were taken to address them. There have been no reports of delayed presentation of an acrylic IOL haptic being severed during uncomplicated surgery. We report a case of delayed anterior chamber inflammation and corneal decompensation secondary to a dislocated haptic fragment from a foldable acrylic posterior chamber IOL following a routine, uncomplicated IOL implantation. The patient provided written consent for his case and photographs to be published.

## 2. Case report

An 85-year-old male presented to our clinic with nonspecific complaints of left ocular irritation, pain, and blurring of vision. He had undergone phacoemulsification with implantation of a posterior chamber IOL in that eye six months earlier at another facility. According to the surgeon, there were no complications during surgery, and his immediate postoperative course had been unremarkable. Two months after the surgery, the patient began to experience left eye irritation, which persisted and worsened over

\* Corresponding author. University of Colorado School of Medicine, Department of Ophthalmology, 1675 Aurora Court, F731, Denver, CO 80045, USA.

E-mail address: [Mina.Pantcheva@ucdenver.edu](mailto:Mina.Pantcheva@ucdenver.edu) (M.B. Pantcheva).

the subsequent months. He then began to notice a decrease in vision, and the quality of his pain became more deep and aching. The patient visited our institution six months after his cataract surgery.

On initial examination, his best corrected vision was noted to be 20/20 in the right eye and 20/40 (pinhole to 20/30) in the left eye. Slit lamp examination of the left eye revealed conjunctival injection, inferior corneal edema extending into the visual axis, inferior Descemet's folds, and trace cells in the anterior chamber. An IOL haptic was noted in the inferior anterior chamber angle lying against the iris and in contact with the corneal endothelium (Fig. 1). The remainder of the slit lamp examination, including dilated fundoscopic examination was normal. By ultrasound biomicroscopy, the haptic fragment was located in the inferior angle but did not appear to be contiguous with the remainder of the IOL, which was noted to be within the posterior chamber, slightly decentered, with no iris touch. Gonioscopy revealed an IOL haptic fragment situated within the inferior aspect of an otherwise open angle. The surrounding iris tissue appeared undisturbed.

The IOL was an AcrySof IQ model SN60WF (Alcon Labs, Fort Worth, TX) hydrophobic acrylic single-piece posterior chamber intraocular lens. The IOL was delivered using the Monarch delivery system. No abnormality of the IOL was noticed at the time of surgery per surgeon's report, or in the immediate postoperative period. The lens fragment was not noted in the anterior chamber at his routine one month post-operative visit.

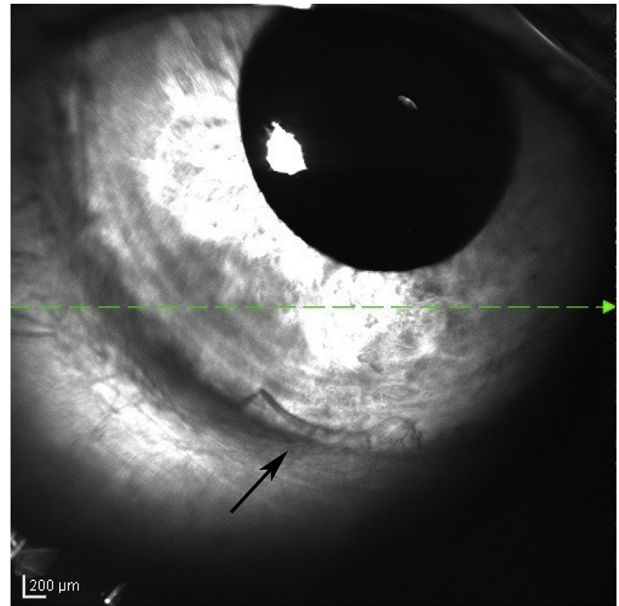
The decision was made to surgically remove the IOL fragment and examine the IOL position. Intra-operatively, the IOL fragment was confirmed to be loose as it shifted position when the patient was supine. The fragment was removed using micro-forceps, and the remainder of the IOL was then examined using an endoscope probe. The nasal haptic was noted to be within the capsular bag; however, the cut temporal haptic was dislocated out of the capsular bag and fibrosed to the anterior aspect of the anterior capsule. The IOL was slightly decentered but stable and therefore was not exchanged. The site of haptic fracture was approximately half the distance between the optic-haptic junction and the distal tip of the haptic. A scratch was also noted on the IOL optic in the mid-periphery near the temporal haptic. Examination of the fragmented edge under the microscope after removal revealed a clean, sharp, straight-cut edge (Fig. 2).

Post-operatively, the patient's corneal edema improved and topical steroids were tapered as indicated. At his one-month postoperative appointment, his vision had returned to 20/20 with trace residual inferior corneal edema. The patient has since moved out of state and therefore no long-term follow-up or testing is available.

### 3. Discussion

Hydrophobic foldable acrylic materials are made of a copolymer of phenylethyl acrylate and phenylethyl methacrylate, cross-linked with butanediol diacrylate, with the purpose of making them foldable and durable. They can be folded, pushed, and pulled, always regaining their original shape, which makes them much more pliable and less prone to breakage than their predecessors. However, acrylic lenses have been shown to be extremely delicate and susceptible to structural damage when improperly manipulated [11,12].

The appearance of the cut edge of the haptic fragment in this case implies a sharp cutting surface was at fault. Theoretically, clipping of a haptic can occur secondary to improper lens folding, although one would expect to find a less clean, sharp edge if the IOL was damaged by a tearing mechanism within the injector. Alternatively, during implantation, the edge of a reusable plunger, if not



**Fig. 1. Optical Coherence Tomography (OCT) image.** OCT image with arrow pointing to the haptic fragment in the inferior anterior chamber. OCT imaging was used for photographic imaging here because it provided the best image through the patient's corneal edema.

properly maintained, could serve as a cutting edge as the trailing haptic is inserted. The scratch noted on the IOL optic adjacent to the cut haptic suggests improper manipulation either during IOL loading, or during release of the IOL from the plunger, or a defective surgical implantation device.

Our patient developed mild intraocular inflammation and corneal edema after his cataract surgery. Based on the patient's history and timeline of symptoms, it is possible that the haptic fragment was initially located within the capsular bag, along with the remainder of the IOL, or in the sulcus, and then later migrated into the anterior chamber. Thus, this complication remained unrecognized for several months.

### 4. Conclusions

IOL haptic fracture and fragment dislocation into the anterior chamber is a rare complication of cataract surgery. Since the



**Fig. 2. Intraoperative image.** Image of the haptic fragment taken during surgery immediately after removal from the eye.

transition to acrylic intraocular lenses, it has become even less common and until now has only been reported with retained fragments after IOL exchange. It should be nevertheless considered, especially in cases of late onset corneal edema post-operatively when other causes have been ruled out. Careful implantation technique and thorough examination of the intraocular lens after implantation to assess for lens damage intraoperatively is essential.

This case also highlights the advantage of gonioscopic evaluation for foreign bodies, including haptic fragments, in cases of isolated corneal edema. Ultrasound biomicroscopy is helpful in identifying haptic fragments that cannot be readily located as well as for evaluating the IOL position. Further, we would like to emphasize the utility of the endoscopic probe for thorough and direct intraoperative visualization of the IOL, its haptics, and their positions relative to the iris and ciliary body.

#### Financial support and conflicts of interest

None of the authors have any financial support or financial or proprietary interests to disclose.

#### References

- [1] H. Eleftheriadis, D.N. Sahu, B. Willekens, G.F. Vrensen, C.S. Liu, Corneal decompensation and graft failure secondary to a broken posterior chamber poly(methyl methacrylate) intraocular lens haptic, *J. Cataract. Refract Surg.* 27 (2001) 2047–2050, [http://dx.doi.org/10.1016/S0886-3350\(01\)00986-5](http://dx.doi.org/10.1016/S0886-3350(01)00986-5).
- [2] N.S. Gokhale, Late corneal edema due to retained foldable lens fragment, *Indian J. Ophthalmol.* 57 (2009) 230–231, <http://dx.doi.org/10.4103/0301-4738.49401>.
- [3] R.S. Hoffman, I.H. Fine, M. Packer, Retained IOL fragment and corneal decompensation after pseudophakic IOL exchange, *J. Cataract. Refract Surg.* 30 (2004) 1362–1365, <http://dx.doi.org/10.1016/j.jcrs.2003.08.015>.
- [4] C. Weickert, G. Fuhrmann, H. Bleckmann, Spontanbruch einer implantierten Vorderkammerlinse, *Ophthalmologe* 89 (1992) 346–348.
- [5] S. Das, M.D. Patil, P. Garg, Traumatic fracture of posterior chamber intraocular lens, *J. Cataract. Refract Surg.* 33 (2007) 2151–2152, <http://dx.doi.org/10.1016/j.jcrs.2007.07.054>.
- [6] I. Çaça, K. Unlü, S. Ari, I. Akşit, Spontaneous fracture of an implanted posterior chamber intraocular lens, *Eur. J. Ophthalmol.* 15 (2005) 507–509.
- [7] J.N.P. Kirkpatrick, S.D. Cook, Broken intraocular lens during cataract surgery, *Br. J. Ophthalmol.* 76 (1992) 509, <http://dx.doi.org/10.1136/bjo.76.8.509>.
- [8] J.R. Ainsworth, A.F. Spencer, Haptic breakage in one-piece poly(methyl methacrylate) intraocular lenses, *J. Cataract. Refract Surg.* 17 (1991) 863–864, [http://dx.doi.org/10.1016/S0886-3350\(13\)80430-0](http://dx.doi.org/10.1016/S0886-3350(13)80430-0).
- [9] Biswas P. Intraocular Lenses in Distress. Online Video. YouTube. Posted: 10 January 2014. Date accessed: 22 April 2016.
- [10] J.M. Solano, K.H. Baratz, M.A. Mahr, J.C. Erie, Late spontaneous haptic disinsertion from a three-piece intraocular lens, *Am. J. Ophthalmol.* 143 (2007) 521–522, <http://dx.doi.org/10.1016/j.ajo.2006.10.036>.
- [11] M.P. Vrabec, J.C. Syverud, C.J. Burgess, Forceps-induced scratching of a foldable acrylic intraocular lens, *Arch. Ophthalmol.* 114 (1996) 777, <http://dx.doi.org/10.1001/archophth.1996.01100130769039>.
- [12] D.R. Pfister, Stress fractures after folding an acrylic intraocular lens, *Am. J. Ophthalmol.* 121 (1996) 572–574, [http://dx.doi.org/10.1016/S0002-9394\(14\)75435-2](http://dx.doi.org/10.1016/S0002-9394(14)75435-2).