

## CASE REPORT

# Isolated duodenal injury presenting as Fournier's gangrene: A case report

Tuhin Shah  | Brikha Raj Joshi | Abhijeet Kumar | Ganesh Simkhada | Rakesh Kumar Gupta

Department of Surgery, B P Koirala  
Institute of Health Sciences, Dharan, Nepal

**Correspondence**

Tuhin Shah, Department of Surgery, B  
P Koirala Institute of Health Sciences,  
Dharan, Nepal.  
Email: dr.tuhinshah@gmail.com

**Abstract**

Isolated duodenal injury is rare as they are usually associated with other visceral injuries. Diagnosis of a duodenal injury is difficult, and its management is challenging. Hence, it is important to timely recognize such injuries for better outcome.

**KEYWORDS**

duodenal injury, duodenorrhaphy, Fournier's gangrene, triple tube decompression

## 1 | INTRODUCTION

Blunt duodenal injury is a uncommon reported injury and associated with significant morbidity and mortality. The evidence of an isolated traumatic duodenal lesion is uncommon. Injury to adjacent abdominal organs is usually seen with duodenal trauma due to its retroperitoneal location. Due to its location, bilious drainage, and surrounding anatomic structures, diagnosis and management are difficult and time-consuming with occasional poor outcome and lengthier treatment, while necrotizing fasciitis is a toxic infective complication, which rapidly spreads in the subcutaneous tissues that may require multiple debridement procedures and has a poor cosmetic result. Here, we describe a case of duodenal perforation after a fall injury, which initially presented as Fournier's gangrene.

Duodenal injury is a rare and infrequent and accounts for about 3-5% of abdominal trauma, and it can be due to either penetrating or blunt trauma. It can be associated with significant morbidity (30%-60%) and mortality (6%-25%).<sup>1</sup> Necrotizing fasciitis is an infection of the skin and subcutaneous tissues, which does not penetrate below the muscle fascial layer. It can spread quickly with devastating and debilitating outcome resulting in a poor cosmetic result.

## 2 | CASE DESCRIPTION

A 62-year-old man presented to the emergency room 5 days after a fall injury—from a hill side while going for farming—with pain and swelling in right lower abdominal, inguinal region, and scrotum. He did not receive any treatment since the fall till the time he arrived to our hospital, except for some painkillers in the last couple of days. On examination, the patient was conscious and afebrile, and vital signs were normal. Systemic examination revealed mild tenderness in the right lower abdomen with no abdominal distension, and per-rectal examination revealed no positive findings, but scrotal erythema, edema, and crepitus were present along with patchy gangrenous skin changes in scrotum, and absent peritoneal signs. WBC count was 9100/mm<sup>3</sup> with 87% neutrophils. Serum amylase was normal. Plain thoraco-abdominal radiographs were normal without free gas under diaphragm. Ultrasound of the abdomen and scrotum showed thickened and inflamed scrotal wall extending to lower abdominal wall with few air pockets within. The testes were normal. No abdominal organ injury was reported, and no collection was noted in the abdomen. A CT scan could not be done because of the financial constraints of the patient. A preoperative

This is an open access article under the terms of the Creative Commons Attribution NonCommercial NoDerivs License, which permits use and distribution in any medium, provided the original work is properly cited, the use is non commercial and no modifications or adaptations are made.

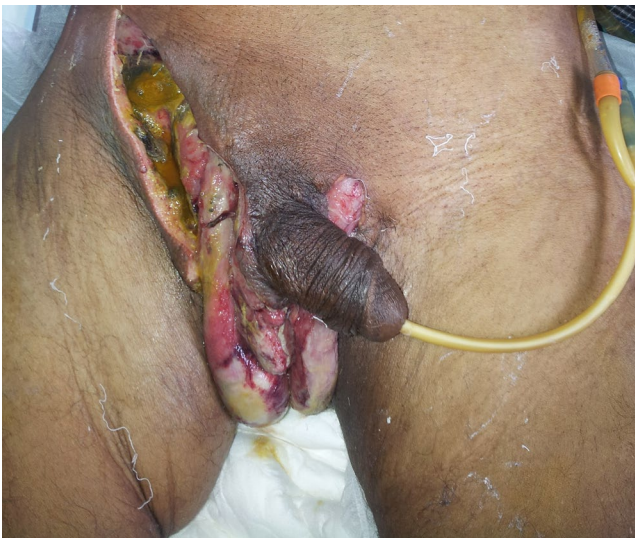© 2021 The Authors. *Clinical Case Reports* published by John Wiley & Sons Ltd.

diagnosis of Fournier's gangrene was made. Wound debridement under GA was planned, and the patient was shifted to the operation room. During the procedure, some bilious content was seen at the wound site—the right inguinal region (Figure 1), prompting an underlying bowel injury for which exploratory laparotomy, was performed at the same sitting. There was some biliary contamination of the peritoneal cavity, and on exploring, there was an inflammatory swelling at the area of the duodenum with slight omental localization. Since no bowel injury was obvious, lesser sac was opened and kockerization of the duodenum was done, which revealed a perforation of 3 cm in third part of retroperitoneal duodenum (Figure 2), which was more than 50% circumference with bilious collection in retroperitoneal space tracking down to right iliac fossa and groin. Rest of the bowel and viscera were normal.

A thorough wash of the peritoneal cavity with duodenorrhaphy was done in two layers with 3-0 polyglactin and silk sutures. (Figure 3) A naso-gastric tube, reverse tube duodenostomy through proximal jejunum, and feeding jejunostomy with closed abdominal drain placed in the right para-colic gutter (Figure 4). He was provided the standard postoperative care, and he was started on enteral feeds through the feeding jejunostomy on day 4. He was discharged on day 17 and is well on follow-up.

### 3 | DISCUSSION

Necrotizing fasciitis is a severe soft tissue infection, which involves the skin and subcutaneous tissues. NF usually results from a complication of a trivial soft tissue infection, or it can present itself after trauma or a surgical procedure. Meleney was the first person to describe the features of

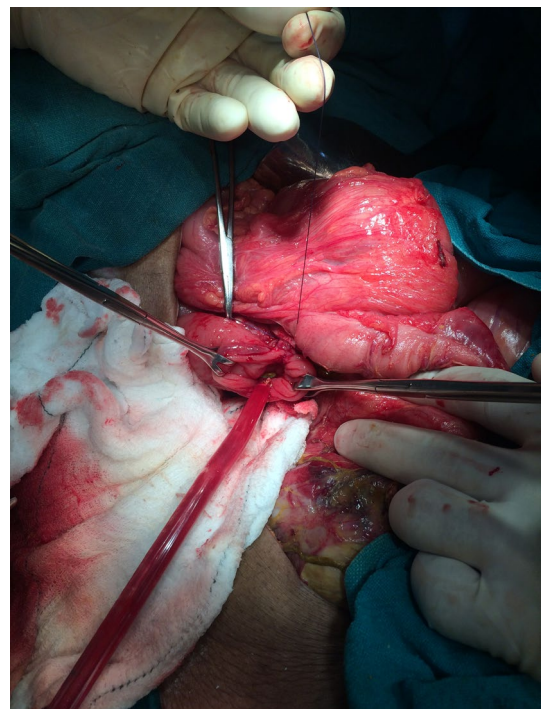


**FIGURE 1** Bilious content seen in right inguinal region during wound debridement for Fournier's gangrene

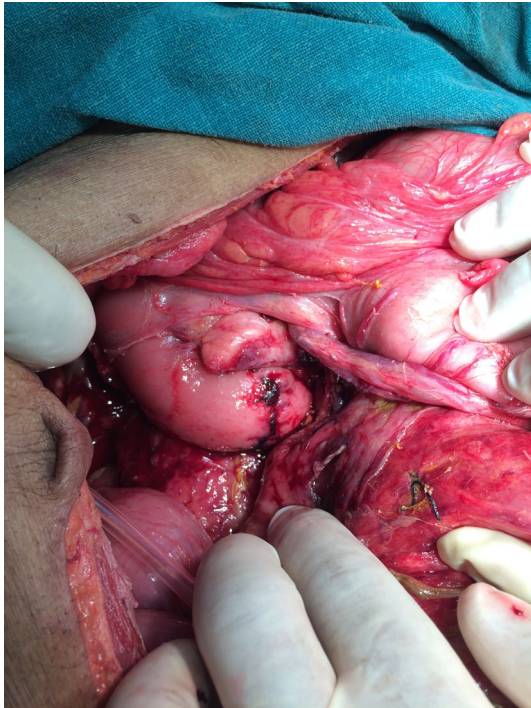
necrotizing soft tissue infection that could spread along the fascial planes with characteristic sparing of the underlying muscle, with or without involvement of the overlying skin.<sup>2</sup> In NF, the initial subcutaneous spread phase often spares the skin from any damage, and as it progresses, bacterial invasion of the perforating cutaneous blood vessels leads to thrombosis and skin ischemia.<sup>3</sup> The signs and symptoms include high fever, localized swelling, erythema, edema of and around the compromised skin, discoloration, blisters or bulla formation, necrosis, and crepitus with or without subcutaneous gas appearance. However, they are not all specific for NF. Although imaging studies are less helpful, magnetic resonance imaging and laboratory findings such as leukocytosis, acidosis, electrolyte abnormalities, coagulopathy, and anemia may help in diagnosis. Sometimes subcutaneous emphysema can be seen on X-ray and the CT scan may reveal signs of NF such as gas bubbles, air fluid level, and fascial swelling.

When NF is suspected, exploration of the necrotic area is essential. Surgical debridement must be performed from distal to proximal until vital tissue is found, and intravenous fluids and broad-spectrum antibiotics should be used till the patient is stabilized.<sup>4</sup>

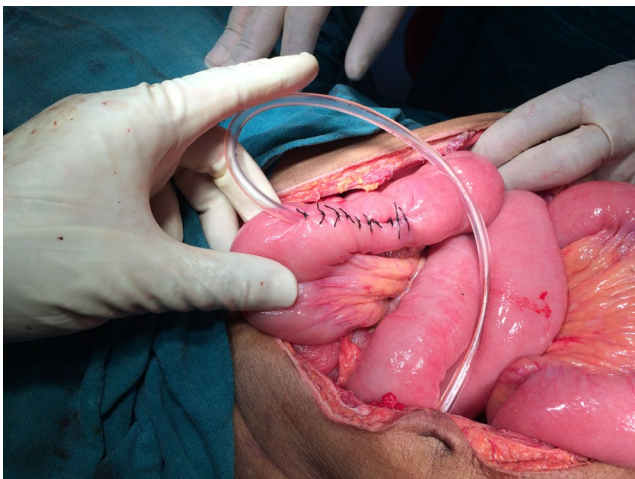
Various cases of NF of the abdominal wall have also been reported after procedures like laparoscopic vaginal hysterectomy, colon perforation, and even after elective herniorrhaphy.<sup>5-7</sup> Blunt injury of the duodenum is less common and more difficult to diagnose than penetrating duodenal injury, and it may occur in isolation or in association with other viscera like pancreas.<sup>8</sup> On an average, one to four other abdominal organ injuries can be associated with duodenal trauma,



**FIGURE 2** Duodenal perforation



**FIGURE 3** Duodenal perforation repaired in two layers



**FIGURE 4** Feeding jejunostomy for early enteral feeding

which makes an isolated duodenal injury rare.<sup>9</sup> In cases of retroperitoneal duodenal perforations, the majority of the patients present with only mild upper abdominal tenderness at first, followed with a progressive rise in temperature, tachycardia, and occasionally vomiting. Over time as the duodenal contents start to leak into the peritoneal cavity, the features of peritonitis can develop. If these contents spill into the lesser sac, they can become walled off and localized.<sup>10</sup> Our patient had a retroperitoneal perforation of the duodenum, with a leak of the bilious content in the retroperitoneum, which tracked retroperitoneally to the right inguinal region and made itself

evident during the wound debridement for NF. Following which an exploratory laparotomy was done with subsequent repair of the perforated duodenum. Furthermore, there was no associated damage or necrotic injury to other retroperitoneal structures including the colon, kidney, or ureter.

Duodenal injury is infrequent, but it presents as a challenge to the surgeon and failure to manage it adequately and timely can result in devastating complications. Since a large volume of digestive fluid passes through the duodenum and because of its challenging anatomic location and relations, traumatic injuries to the duodenum can result in severe fluid loss and electrolyte imbalance especially with a delay in the diagnosis as it is retroperitoneally situated. Also, since no ideal technique of repair of the injured duodenum is acknowledged which can prevent the possibility of anastomotic leak, a lot of options are available, which may vary from surgeon to surgeon. Sometimes the patient's presentation can help make the decision for the treating surgeon from the various operative choices. Also, an isolated duodenal injury is uncommon; therefore, there are other associated injuries involved to address in the course of treatment. Options are limited if the patient presents late or in sepsis. This was evident in our case.

Duodenal perforation is also associated with a leak of amylase and other digestive enzymes.<sup>11</sup> However, an increase in serum amylase does not confirm duodenal injury and a normal serum amylase level does not exclude it either. Upper gastrointestinal radiological studies and computed tomography can confirm the diagnosis of blunt duodenal trauma, while exploratory laparotomy remains the ultimate diagnostic test.<sup>8</sup> In our case, we were not able to diagnose preoperatively due absence of CT scan reports for various reasons; however, we were fortunate enough to spot it intraoperatively and manage adequately.

A method of repair with simple suturing and duodenal decompression by triple tube technique, which was first described by Stone and Fabian.<sup>12</sup> In the triple tube technique, a gastrostomy tube for decompression of the stomach, a reverse duodenostomy tube for duodenal decompression, and an antegrade jejunostomy tube for enteral feeding is placed. For reverse tube duodenostomy, the tube is passed through the proximal jejunum and guided into the second part of duodenum. This triple tube technique is fast, needs basic surgical experience, and provides a route for early enteral feeding avoiding the need for intravenous nutrition. Therefore, making it a cost-effective option with lesser morbidity for managing such patients.

In another study, “damage control surgery” in the form of polypropylene mesh laparostomy after duodenorrhaphy, tube gastrostomy, reverse tube duodenostomy, and a feeding jejunostomy was performed. Salvage procedures like quick “damage control” with delayed definitive surgery, Foley's catheter duodenostomy, and duodenal

decompression by quadruple tube technique are also reported.<sup>13-15</sup> Another option to manage such patients could have been a controlled duodenal fistula following peritoneal lavage. But, in triple tube decompression with a feeding jejunostomy in place helps in early enteral feeding and avoids the need for more expensive total parenteral nutrition and its complications.<sup>16</sup>

We also approached similarly in our patient and performed duodenorrhaphy and duodenal decompression with double tube and naso-gastric tube drain instead of a tube gastrostomy with good results. The ability to start early enteral feed was a boost for early recovery for the patient compared with the more expensive TPN.

## 4 | CONCLUSION

High suspicion is necessary for early diagnosis of duodenal trauma, and CT scan should be performed. In most cases, primary repair of duodenum can be achieved with duodenal decompression via triple tube technique to decrease risk of duodenal fistula. However, we did a duodenorrhaphy and duodenal decompression with double tube and naso-gastric tube drain with good results.

## CONFLICT OF INTEREST

None declared.

## AUTHOR CONTRIBUTIONS

TS and RKG: participated in study conception and design. TS and BRJ: involved in acquisition of data and analyzed and interpreted the data. TS, AK, GS, and RKG: drafted the manuscript and performed critical revision.

## CONSENT STATEMENT

Published with written consent of the patient.

## DATA AVAILABILITY STATEMENT

Data sharing is not applicable to this article as no datasets were generated or analyzed during the current study.

## ORCID

Tuhin Shah  <https://orcid.org/0000-0002-1184-2890>

## REFERENCES

- Pandey S, Niranjana A, Mishra S, et al. Retrospective analysis of duodenal injuries: a comprehensive overview. *Saudi J Gastroenterol*. 2011;17(2):142-144.
- Meleney FL. Hemolytic streptococcus gangrene. *Arch Surg*. 1924;9(2):317-364.
- Wong CH, Wang YS. The diagnosis of necrotizing fasciitis. *Curr Opin Infect Dis*. 2005;18(2):101-106.
- Kihiczak GG, Schwartz RA, Kapila R. Necrotizing fasciitis: a deadly infection. *J Eur Acad Dermatol Venereol*. 2006;20(4):365-369.
- Golshani S, Simons AJ, Der R, Ortega AE. Necrotizing fasciitis following laparoscopic surgery. Case report and review of the literature. *Surg Endosc*. 1996;10(7):751-754.
- Tsai HL, Liu CS, Chang JW, Wei CF, Lin JT, Chin TW. Severe necrotizing fasciitis of the abdominal wall secondary to colon perforation in a child. *J Chin Med Assoc*. 2008;71(5):259-261.
- Miller AT, Byrn JC, Divino CM, Weber KJ. Eikenella corrodens causing necrotizing fasciitis after an elective inguinal hernia repair in an adult: a case report and literature review. *Am Surg*. 2007;73(9):876-879.
- Degiannis E, Boffard K. Duodenal injuries. *Br J Surg*. 2000;87(11):1473-1479.
- Velmahos GC, Constantinou C, Kasotakis G. Safety of repair for severe duodenal injuries. *World J Surg*. 2008;32:7-12.
- Carrillo EH, Richardson JD, Miller FB. Evolution in the management of duodenal injuries. *J Trauma*. 1996;40:1037-1046.
- Levison MA, Peterson SR, Sheldon GF, Trunkey DD. Duodenal trauma: experience of a trauma center. *J Trauma*. 1984;24:475-480.
- Stone HH, Fabian TC. Management of duodenal wounds. *J Trauma*. 1979;19:334-339.
- Rickard MJ, Brohi K, Bautz PC. Pancreatic and duodenal injuries: keep it simple. *ANZ J Surg*. 2005;75:581-586.
- van Ginhoven T, Schepers T, Obertop H, van Eijck CH. Delayed closure of complex duodenal injuries by a Foley balloon catheter duodenostomy. *Dig Surg*. 2006;23:150-153.
- Crippa S, Falconi M, Bettini R, et al. Isolated blunt duodenal trauma: delayed diagnosis and favorable outcome with "quadruple tube" decompression. *JOP*. 2007;8:617-620.
- Bhattacharjee HK, Misra MC, Kumar S, Bansal VK. Duodenal perforation following blunt abdominal trauma. *J Emerg Trauma Shock*. 2011;4(4):514-517.

**How to cite this article:** Shah T, Raj Joshi B, Kumar A, Simkhada G, Kumar Gupta R. Isolated duodenal injury presenting as Fournier's gangrene: A case report. *Clin Case Rep*. 2021;9:e04232. <https://doi.org/10.1002/ccr3.4232>