

Review Article

Management of Primary Brainstem Hemorrhage: A Review of Outcome Prediction, Surgical Treatment, and Animal Model

Peng Chen,¹ Haijun Yao,² Xiaoyong Tang,¹ Yanglingxi Wang,¹ Qingtao Zhang,¹ Yang Liu,¹ Jin Hu ,² and Yongbing Deng ¹

¹Department of Neurosurgery, Chongqing Emergency Medical Center, Chongqing University Central Hospital, Chongqing, China

²Department of Neurosurgery & Neurocritical Care, Hua Shan Hospital Affiliated to Fudan University, Shanghai, China

Correspondence should be addressed to Jin Hu; hujin_dana@126.com and Yongbing Deng; 1422495819@qq.com

Received 5 April 2022; Accepted 4 May 2022; Published 12 July 2022

Academic Editor: Zhongjie Shi

Copyright © 2022 Peng Chen et al. This is an open access article distributed under the Creative Commons Attribution License, which permits unrestricted use, distribution, and reproduction in any medium, provided the original work is properly cited.

Primary brainstem hemorrhage (PBH) has the worst prognosis of all types of intracerebral hemorrhage. Currently, the management of PBH is controversial. Hematoma classification, scoring systems, and electrophysiological monitoring are critical for predicting the outcome of PBH. Surgery may be an effective treatment for PBH. Clinical studies have emphasized the importance of animal models for understanding the pathogenesis and pathological mechanisms of PBH. In this study, combined with recent studies, the outcome prediction, surgical treatment, and animal models of PBH were reviewed.

1. Introduction

The brainstem is located deep in the skull and is small in size and includes the midbrain, pons, and medulla oblongata. The brainstem is mainly composed of nerve nuclei, ascending and descending tracts, and reticular structures. The brain stem is the center that regulates vital functions such as breathing, heart rate, blood pressure, and body temperature. Primary brainstem hemorrhage (PBH) is a spontaneous brainstem hemorrhage associated with hypertension, not associated with cavernous hemangioma, arteriovenous malformation, and other diseases. PBH accounts for 6-10% of intracerebral hemorrhages, with an incidence of approximately 2-4/100,000 per year, with approximately 60-80% of PBH occurring in the pontine region [1]. Its clinical characteristics are sudden onset, rapid neurological deterioration, bleak prognosis, and high mortality (30-90%) [2-5]. PBH most commonly occurs in the age of 40-60 years old, showing trends toward younger age. The incidence is higher in men than in women, and the main risk factor is hypertension; other related factors include anticoagulant therapy, amyloidosis, etc. [1, 5-7].

We reviewed the recent research results of outcome prediction, surgical treatment, and animal model of PBH.

2. Outcome Prediction

Since primary brainstem hemorrhage (PBH) has the worst prognosis of all types of ICH, previous studies have investigated prognostic factors such as age, coma, blood glucose, GCS, hemorrhage size, location, and extent of hemorrhage. We will elaborate on prognostic prediction from hematoma classification, scoring system, electrophysiological monitoring, etc.

2.1. Hematoma Classification. At present, there is no standard for the classification of PBH in clinical practice. According to the anatomical region, it can be divided into the midbrain type, pontine type, and medulla oblongata type PBH. Medulla oblongata type is the most serious type and may cause ataxic respiration and rapid death [8].

Various classifications were established based on CT images of the anatomical area and direction of expansion of the hematoma. In 1986, Russell et al. classified pontine hemorrhage into three types: central pontine hematoma, dorsolateral tegmental hematoma, and pontine basal hematoma [9]. Based on CT findings, Chung and Park divided pontine hemorrhage into four types: massive, bilateral tegmental, basal-tegmental, and small unilateral tegmental, with survival rates of 7.1%,

14.3%, 26.1%, and 94.1%, respectively [10]. In 2012, Nishizaki et al. combined the previous classification of hematomas with some modifications and classified them into four types, giant, covered to the base, laterally oval, and small unilateral [11]. Wessels et al. reviewed the clinical data of patients with primary pontine hemorrhage and classified into three new types regardless of unilateralism or bilateralism: dorsal, ventral, and massive [5]. It was demonstrated that small amounts of dorsal hemorrhage had a good prognosis, and patients with ventral and massive hematoma has higher mortality [12, 13].

The second affiliated hospital of Zhejiang University School of Medicine in China introduced four types of hematoma classification based on the maximum cross-section of CT and showed the surgical treatment according to different classifications. Type 0 was the hematoma located in the cistern or fourth ventricle, compressed the brainstem, not damage it. Type 1 was the hematoma expanding in half of the brainstem without crossing the midline. Type 2 was the hematoma crossed the midline of the brainstem but does not cross the 3/4 boundary in another side. Type 3 was the hematoma crosses 3/4 of the brainstem. Types 2 and 3 could also be divided into three subtypes including ventral, dorsal, and central [14].

Depending on the classification of hematoma, previous studies have shown that the location and volume of the hematoma are most associated with outcome. Unilateral tegmental hematoma has a good prognosis, while bilateral and ventral massive hematomas have the worst prognosis [2]. Classification of brainstem hematoma is presented in Figure 1.

2.2. Scoring System. A large number of previous studies have found that predictors of PBH include GCS at admission, location and volume of hematoma, hydrocephalus, disturbance of consciousness, and age. Comprehensive scoring system can play an important role in the management of patients with PBH [12, 15–17].

The intracerebral hemorrhage (ICH) scoring has been used to evaluate PBH [18]. Due to the entirely differences of grading of hematoma volume, complex anatomical structures, and blood supply system, the supratentorial ICH scoring system could not be applied to PBH directly and should be modified appropriately [19]. In 2015, Meguro et al. proposed an innovative grading scale (primary pontine hemorrhage) that predicted 30-day mortality of 101 patients with pontine hemorrhage [20]. However, the scoring system, which defined GCS, light reflex, and blood glucose as variables that could influence the search for independent factors, was not externally validated. To address this issue, in 2017, Huang et al. established and validated a comparative scoring system to predict 30-day mortality and 90-day outcome. According to the hematoma volume and GCS score, the hematoma volume is less than 5 mL as 0, 5-10 mL as 1, greater than 10 mL as 2, GCS 8-15 as 0, GCS 5-7 as 1, and GCS 3-4 as 2. The 30-day mortality rates for patients with a total score of 0, 1, 2, 3, and 4 were 2.7%, 31.6%, 42.7%, 81.8%, and 100%, respectively [16]. So far, this was the largest population-based and best evidence score research including 171 patients. The development of scoring system of brainstem hemorrhage is shown in Figure 2.

Significantly, GCS and hematoma volume were the two most influential predictors in scoring system. Future research

required abundant samples to establish more accurate scoring system by combining radiographic and laboratory information. Moreover, in addition to the prediction of mortality and functional recovery, the advanced scoring system was responsible in stratification management of therapeutic strategy and surgery indication [21].

2.3. Electrophysiological Monitoring. MRI and CT imaging cannot convey complete information on the function of corticospinal tract and sensory pathways. Electrophysiological monitoring was widely used in patients of stroke and was recognized important tool in terms of predicting prognosis after stroke [22]. There was little literature that was available on the utilization of electrophysiological monitoring to predict outcome and guidance therapeutic strategy in patients with PBH.

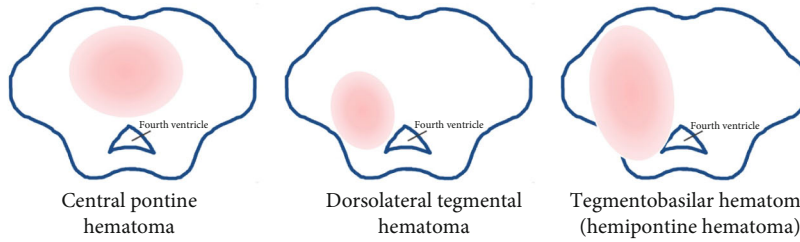
Electroencephalography (EEG) is widely used for electrophysiological monitoring in clinical practice. Stimulation of the reticular structure always induces EEG changes, and it is difficult to accurately record brainstem functional EEG from scalp monitors alone. Therefore, the application of EEG is mainly in the diagnosis of brainstem death, and the role of EEG in brainstem monitoring remains controversial. Chen et al. found that quantitative EEG variables $((\delta + \theta)/(\alpha + \beta))$ ratio, DTABR) were effective in predicting clinical outcomes of 90-day mortality in 31 PBH patients, whereas transcranial Doppler (TCD) was not. It was the first research to verify the importance of quantitative electroencephalogram examination in evaluating prognosis of PBH [23].

Electrophysiological monitoring techniques including somatosensory evoked potentials (SEPs), brainstem auditory evoked potentials (BAEPs), and motor evoked potentials (MEPs) were available to monitor the functional integrity of the pathways passing through the brainstem and provide real-time information to support brainstem surgery [24]. In addition to diagnosing brain death, electrophysiological monitoring parameters have also been considered to be associated with functional recovery after ICH. Chao et al. reported a case with delayed trigeminal motor denervation resulting in developing progressive atrophy of the right temporalis and masseter muscles after pontine hemorrhage, which was consistent with electromyography monitoring results [25]. Kim et al. also reported a case with profound hearing loss on the pure-tone audiogram after pontine intracranial hemorrhage, which was predicted by abnormal brainstem auditory evoked potentials [26]. Seong et al. confirmed that compared with hematoma volume and transverse diameter, combined MEPs and SEPs was a reliable and useful tool for predict outcome of functional recovery (global disability, gait ability, and trunk stability in sitting posture) after primary pontine hemorrhage [27]. The mortality and disability rates of PBH are high, and multimodal electrophysiological monitoring is recommended to explore and analyze the relationship between massive parameters and potential prognosis.

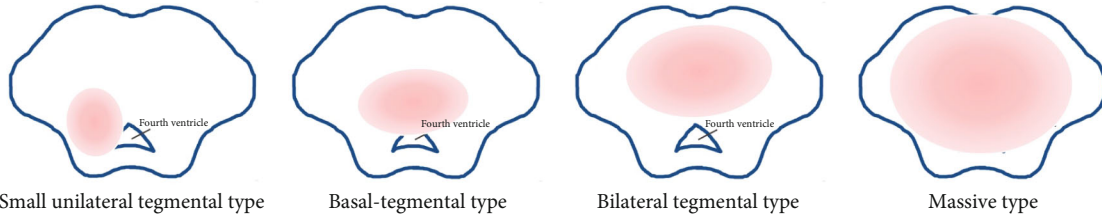
3. Surgical Treatment

PBH was critical; therapeutic principles included maintain the stability of vital signs, reduce primary damage, prevent secondary damage, and restore neurological function and

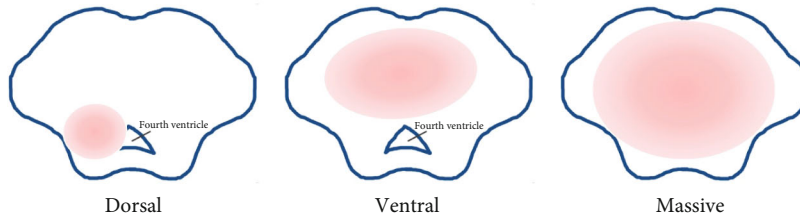
Russell B, *neurosurgery*, 1986.



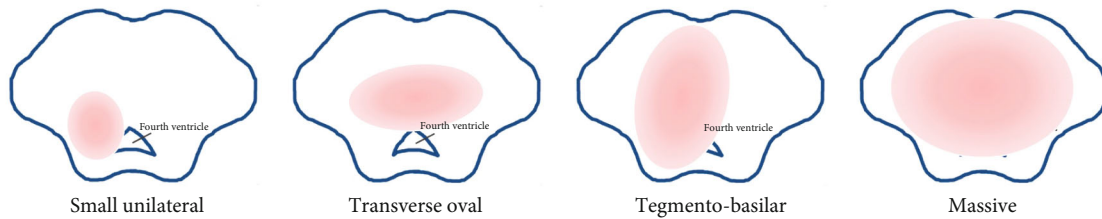
Chung CS, *neurology*, 1992.



Wessels T, *american journal of neuroradiology*, 2004.



Nishizaki T, *open journal of modern neurosurgery*, 2012.



Liu F, *chinese journal of neurosurgery*, 2019.

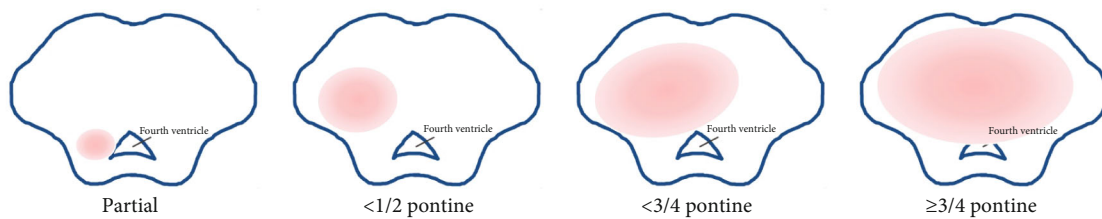


FIGURE 1: Classification of brainstem hematoma.

structure to the greatest extent. The conservative management strategy of PBH mainly referred to strategy of ICH [28], including management of blood pressure, blood glucose, temperature, coagulopathy and treatment of intracranial hypertension, epilepsy, deep venous thrombosis, and other complications [29–31].

Surgical treatment of PBH is controversial. Brainstem hemorrhage has been excluded from previous trials such as STICH and MISTIE, and there is no clear evidence of the effectiveness of surgery for PBH. The purpose of surgical treatment is to remove or reduce the hematoma, decompress

the brainstem, prevent secondary damage, and be sensitive to the brainstem. Next, we will elaborate it from the aspects of surgical perspective, indication, and option.

3.1. Surgical Perspective. There were significant differences in the perspective of life between east and west culture, so there were obvious different therapeutic strategies of PBH in different countries. It was generally believed that in European and American countries, severe disability or vegetative state was a high mental and economic burden for patients themselves and their families, and it was

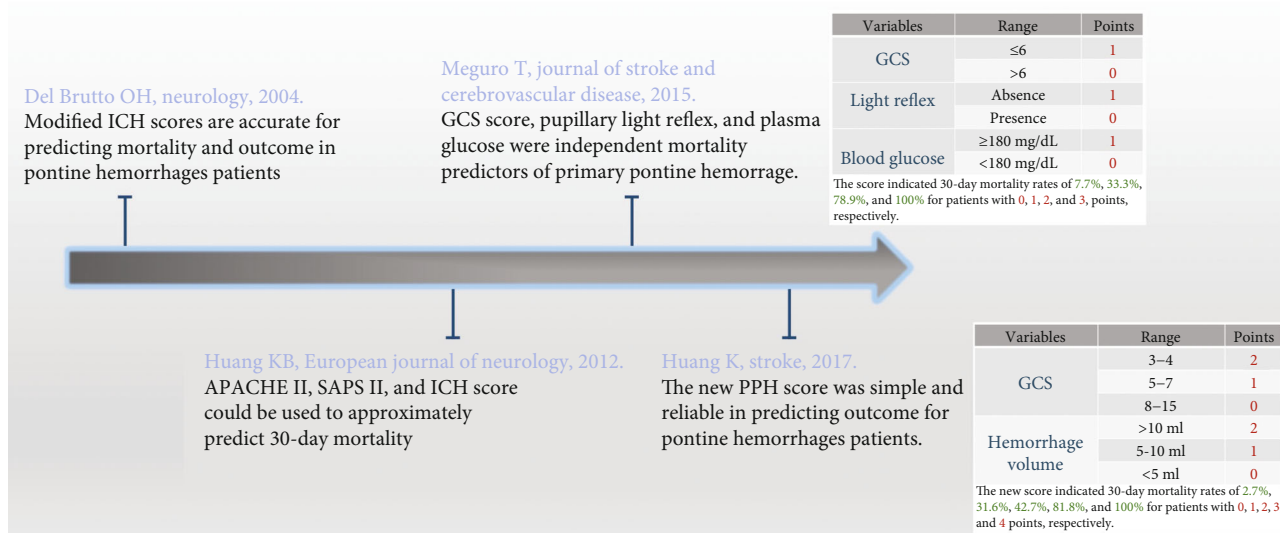


FIGURE 2: Diagram illustrated development of scoring system of brainstem hemorrhage.

difficult to accept the reality of poor prognosis. As a result, western countries hold negative opinion on surgical treatment for brainstem hemorrhage. Moreover, the relevant guidelines did not recommend surgical treatment for brainstem hemorrhage.

In countries represented by China, Japan, and South Korea, the concept of “filial piety” plays an active and unique role in family interactions. Most PBH patients are in a coma, and the treatment strategy is mostly determined by the patient’s spouse and children. When families decide on treatment options, Chinese families are more likely to opt for surgery even if they are told the expected outcome is poor. Under this circumstance, Chinese doctors have performed a large number of surgical treatments for PBH and have summarized and accumulated a lot of experience in surgical selection, monitoring methods, complications, and medical assistance.

3.2. Surgical Indication. Analysis of outcome prediction for surgical patients with primary pontine hemorrhage, Tao et al. demonstrated that younger age (less than 65y), smaller hematoma (less than 5 mL) without rostrocaudal extension, unilateral hemorrhage, and higher GCS (6–8) could benefit from surgery [21]. The surgical indication was proposed by Shrestha et al. included the mass hematoma volume more than 5 mL, GCS less than 8, and progressive neurological deterioration, especially with extremely unstable basic vital signs on long-term ventilator usage [32]. According to the scoring system for brainstem hemorrhage established by Huang et al., the score of 4 was contraindicated, and patients with the score of 2 to 3 could benefit from surgical treatment. However, based on the current limited evidence, this conclusion would carry out further verification [16]. A review of 10 cohort studies showed that the surgical group included age of 45–65 years, unconscious, GCS was 3 to 8, and the hematoma volume of about 8 mL. It was revealed that elder and comatose in PBH patients were not contraindicated for surgery, and patients in the surgery group

required a lower mortality rate and better outcome compared with conservative management [33].

The principles of supratentorial ICH surgery cannot be directly applied to PBH due to differences in anatomy and blood supply systems. In a study of 46 patients with PBH, Lan et al. found that in the early surgery group (≤6h), 20 patients who underwent surgery had better neurological recovery [34]. However, Chen et al. summarized the experience of 52 cases of PBH in a single center and proposed that the optimal surgical time was 12 to 48 hours by microsurgery [35]. The recommended treatment time of the Chinese clinical nerve repair PBH treatment guidelines is 6–24 hours after bleeding, and the bleeding volume is greater than 5 mL, or the diameter of the hematoma is greater than 2 cm. For patients with blood loss less than 3 mL and no obvious ventricular dilatation or disturbance of consciousness, surgery is not recommended. Surgery is also not recommended for patients with bleeding greater than 15 mL, severe irreversible damage source, and extremely unstable basic vital signs [1].

3.3. Surgical Option. Surgical option for PBH included minimally invasive hematoma puncture and drainage, craniotomy hematoma clearance, endoscopic hematoma clearance, etc.

3.3.1. Minimally Invasive Surgery. Takahama et al. have firstly performed the surgery of stereotactic brainstem hematoma puncture and drainage in 1989 [36]. This minimally invasive surgery could reduce the damage of the important structure of the brainstem as far as possible. It has the characteristics of simple operation, short operation time, and minimally invasive craniopuncture combined with urokinase or rtPA infusion. It was found that a slightly lower mortality rate in the hematoma aspiration group than the microscopic surgery group (24.4% versus 31.6%, $P = 0.162$) by Zheng et al. Because of less surgical trauma and shorter operation time, it indicated that hematoma aspiration may be suitable for older patients [33]. The most critical technique for the puncture operation

was precision. The common stereotactic methods included the use of frame technology, frameless technology, neuronavigation system, and surgical robot; those greatly improved the accuracy of puncture.

3D-printed technology has been successfully applied in medical fields such as intraoperative navigation [37]. Wang et al. applied 3D printing navigation for puncture and drainage of PBH in 2020 and found that the actual puncture target was accurately positioned in the hematoma in 7 cases, and the effect was satisfactory. 3D printing-assisted hematoma puncture and drainage offers an innovative and promising approach for surgical treatment of PBH [38].

At present, mixed reality technology was utilized to construct three-dimensional model of hematoma, puncture trajectory, and anatomical structures with holographic images. Operators could obtain real and virtual image information at the same time by wearing special equipment and interacted with model in the display environment according to their own commands. The technology provided operators with immersive feeling that difficult to fully express through photos or videos or even AR technology. We have performed minimally invasive puncture and drainage in patients with PBH by mixed reality holographic navigation technology and concluded that it was feasible to become an innovative, effective, and safe solution [39].

3.3.2. Craniotomy Surgery. In 1998, Hong et al. in South Korea firstly performed craniotomy hematoma clearance in PBH, and craniotomy hematoma clearance has become an important method for PBH [40]. The advantages of microscopic craniotomy hematoma removal are the maximum hematoma removal under direct vision, clear hemostasis surgery, removal of the fourth ventricle hematoma, and avoidance of cerebrospinal fluid circulation disorders and secondary hydrocephalus. Microsurgery requires high electrophysiological monitoring and surgical skills. Use a microaspirator to absorb the hematoma as much as possible, avoiding damage to normal brainstem tissue and function. Hemostatic gauze should be applied gently to stop bleeding. If bipolar coagulation is performed, it needs to be performed at the same time as flushing water to reduce temperature and thermal damage to the brainstem.

Ichimura performed surgery on 5 patients with mild brainstem hemorrhage, and adopted different surgical positions and approaches according to hematoma location in brainstem. Postoperative consciousness, motor performance, and mRS grades were improvement in all cases [41]. Chen et al. performed neuronavigation-assisted microsurgery on 52 patients with PBH and indicated that in patients with hemorrhage volume less than 10 mL, microsurgery was very rapid, effective, and safe [35]. Previous studies indicated avoid damaging to the brainstem, the craniotomy approach was very important; the craniotomy approach was very important. With the widening knowledge of safe approaches and entry zones for the brainstem, surgical craniotomy, training, and research in brainstem promised to become more precise and attractive [42–44].

3.3.3. Endoscopic Surgery. In 2003, Takimoto et al. firstly introduced a new method that with the aid of neuroendo-

scopy to evacuate pontine hemorrhage and provide another surgical option [45]. It was challenged to approach ventrally located brainstem hematoma by traditional transcranial approaches. As a result of its development and advantages such as the natural surgical corridor, direct visualization, adequate exposure of structure, and minimal brain or vascular retraction, endoscopic endonasal approach technology may become a feasible alternative to treat ventral brainstem hematoma [46].

Liu et al. and Topczewski et al. reported evacuation of ventral hematoma in the brainstem through endoscopic endonasal approach assisted by intraoperative electrophysiological monitoring, and neuronavigation system achieved good results [47, 48]. However, this procedure required a longer learning curve for surgeons and was lack of high-quality evidence and enough experience to support. Therefore, it was necessary to verify the safety and feasibility of surgery in large clinical samples.

4. Animal Model

With low incidence of PBH, it was difficult to perform a large clinical sample research. The plight clinical research emphasized that animal model of PBH was important to understand the pathogenesis and pathological mechanism and provide reference to surgical timing, surgical approaches, etc. At present, the common PBH animal models were mainly constructed by rabbits and rats, and the construction methods were mainly stereotactic injection of collagenase (type VII) or autologous blood.

In 2005, Jin et al. used long-eared Japanese rabbit to construct brainstem hemorrhage model at the level of inferior colliculus by injecting 0.1 mL of its own blood into the brainstem. According to cerebrospinal fluid circulation disorder through hematoma compressing in aqueduct of midbrain, the pressure of lateral cerebral ventricle was increased [49]. It was found that the more PBH model was established in rats gradually. Lekic et al. stereotactically infused 0.15 units of collagenase (type VII) into the ventral pontine tegmentum of the rats to build model. Collagenase was used to simulate the procedure that specifically degrading the collagen components of intercellular matrix and basement membrane of vascular endothelial cells, which was closer to the pathological procedure of spontaneous intracerebral hemorrhage. This new PBH rat model demonstrated neurological deficits and brain edema and was used to test treatment strategies for PBH [50, 51]. Guo et al. also established a PBH model in rats by stereotactic injecting type VII collagenase to observe the pathological procedure of secondary injury caused by iron overload and concluded that administration of deferoxamine had limited therapeutic effects on collagenase-induced brainstem hemorrhage in rats [52, 53].

A rat model was established by stereotactically injecting 30 μ L of autologous whole blood from the central caudal artery at a constant rate of 5 μ L/min with a microinfusion pump. Brain edema, white matter damage, and neurological deficits due to stable hematomas in this new model are helpful for future studies of pathophysiological mechanisms and evaluation of new treatments [54]. Recently, Tang et al.

provided a protocol to establish a massive pontine hemorrhage model in a rat. Firstly, 100 μL of autologous blood from the tail vein was acquired and stereotactically injected only 10 μL into the pontine. Secondly, the syringe was left in position for 20 min to prevent blood from flowing into the subarachnoid space. Thirdly, restart injection at the same speed of 1 $\mu\text{L}/\text{min}$ until the residual blood has been injected completely. It was concluded that the symptoms of this model were in line with patients with massive pontine hemorrhage [55]. Shrestha et al. provided a reliable and reproducible model for rat brainstem hemorrhage and summarized key points to success in modeling, such as stereotactic location, blood volume (twice injection, more than 60 μL), anesthesia, head positioning, autologous blood coagulation, needle deviation, brain shift, and back-leakage [56].

5. Conclusion

In conclusion, PBH is clinically characterized by low morbidity, high mortality, and poor prognosis. Currently, there are different hematoma classifications for PBH in clinical practice. The results showed that unilateral tegmental hematoma had a good prognosis, while bilateral and ventral massive hematomas had the worst prognosis. GCS and hematoma volume were the two most influential predictors in the scoring system. Multimodal electrophysiological monitoring, such as SEPs and MEPs, is recommended to explore and analyze potential prognoses. Surgical treatment of PBH is controversial. There are significant differences in the perspectives on surgical treatment between Eastern and Western cultures, and there are significant differences in recommended strategies. At present, studies have confirmed that surgical options such as stereotactic hematoma puncture and drainage, craniotomy hematoma removal, and endoscopic hematoma removal can benefit appropriate patients, but high-quality evidence and sufficient empirical support are still lacking. Dilemma clinical studies have emphasized that PBH animal models provide important reference for understanding its pathogenesis and pathological mechanisms, as well as treatment.

Data Availability

Data was provided in the manuscript.

Conflicts of Interest

The authors declare that they have no conflicts of interest.

Acknowledgments

This study was financially supported by the Medical Research Project of Science and Technology Bureau Joint Health Commission, Chongqing, China (2020MSXM078).

References

- [1] L. Chen, T. Chen, G. Mao et al., "Clinical neurorestorative therapeutic guideline for brainstem hemorrhage," *Journal of Neurorestoratology*, vol. 8, no. 4, pp. 232–240, 2020.
- [2] S. S. Wang, Y. Yang, J. Velz et al., "Management of brainstem haemorrhages," *Swiss Medical Weekly*, vol. 149, article w20062, 2019.
- [3] R. Behrouz, "Prognostic factors in pontine haemorrhage: a systematic review," *European Stroke Journal*, vol. 3, no. 2, pp. 101–109, 2018.
- [4] K. Balci, T. Asil, M. Kerimoglu, Y. Celik, and U. Utku, "Clinical and neuroradiological predictors of mortality in patients with primary pontine hemorrhage," *Clinical Neurology and Neurosurgery*, vol. 108, no. 1, pp. 36–39, 2005.
- [5] T. Wessels, W. Moller-Hartmann, J. Noth, and C. Klotzsch, "CT findings and clinical features as markers for patient outcome in primary pontine hemorrhage," *AJNR American Journal of Neuroradiology*, vol. 25, no. 2, pp. 257–260, 2004.
- [6] D. Chen, Y. Tang, H. Nie et al., "Primary brainstem hemorrhage: a review of prognostic factors and surgical management," *Frontiers in Neurology*, vol. 12, article 727962, 2021.
- [7] C. J. van Asch, M. J. Luitse, G. J. Rinkel, I. van der Tweel, A. Algra, and C. J. Klijn, "Incidence, case fatality, and functional outcome of intracerebral haemorrhage over time, according to age, sex, and ethnic origin: a systematic review and meta-analysis," *The Lancet Neurology*, vol. 9, no. 2, pp. 167–176, 2010.
- [8] H. M. Kwon, J. M. Park, J. Y. Lee, and B. W. Yoon, "Primary medullary hemorrhage associated with hypertension," *Journal of Clinical Neurology*, vol. 1, no. 2, pp. 177–179, 2005.
- [9] B. Russell, S. S. Rengachary, and D. McGregor, "Primary pontine hematoma presenting as a cerebellopontine angle mass," *Neurosurgery*, vol. 19, no. 1, pp. 129–133, 1986.
- [10] C. S. Chung and C. H. Park, "Primary pontine hemorrhage: a new CT classification," *Neurology*, vol. 42, no. 4, pp. 830–834, 1992.
- [11] T. Nishizaki, N. Ikeda, S. Nakano, T. Sakakura, M. Abiko, and T. Okamura, "Factors determining the outcome of pontine hemorrhage in the absence of surgical intervention," *Open Journal of Modern Neurosurgery*, vol. 2, no. 2, pp. 17–20, 2012.
- [12] Z. Ye, X. Huang, Z. Han et al., "Three-year prognosis of first-ever primary pontine hemorrhage in a hospital-based registry," *Journal of Clinical Neuroscience*, vol. 22, no. 7, pp. 1133–1138, 2015.
- [13] J. H. Jang, Y. G. Song, and Y. Z. Kim, "Predictors of 30-day mortality and 90-day functional recovery after primary pontine hemorrhage," *Journal of Korean Medical Science*, vol. 26, no. 1, pp. 100–107, 2011.
- [14] F. Liu, Z. F. Wang, and X. B. Yu, "Efficiency and influence factors of stereotactic precision aspiration in the treatment of primary brainstem hemorrhage," *Chinese Journal of Neurosurgery*, vol. 35, no. 11, pp. 1094–1098, 2019.
- [15] A. Morotti, M. J. Jessel, H. B. Brouwers et al., "CT angiography spot sign, hematoma expansion, and outcome in primary pontine intracerebral hemorrhage," *Neurocritical Care*, vol. 25, no. 1, pp. 79–85, 2016.
- [16] K. Huang, Z. Ji, L. Sun et al., "Development and validation of a grading scale for primary pontine hemorrhage," *Stroke*, vol. 48, no. 1, pp. 63–69, 2017.
- [17] H. Matsukawa, M. Shinoda, M. Fujii, O. Takahashi, and A. Murakata, "Risk factors for mortality in patients with non-traumatic pontine hemorrhage," *Acta Neurologica Scandinavica*, vol. 131, no. 4, pp. 240–245, 2015.
- [18] O. H. Del Brutto and X. Campos, "Validation of intracerebral hemorrhage scores for patients with pontine hemorrhage," *Neurology*, vol. 62, no. 3, pp. 515–516, 2004.

- [19] K. B. Huang, Z. Ji, Y. M. Wu, S. N. Wang, Z. Z. Lin, and S. Y. Pan, "The prediction of 30-day mortality in patients with primary pontine hemorrhage: a scoring system comparison," *European Journal of Neurology*, vol. 19, no. 9, pp. 1245–1250, 2012.
- [20] T. Meguro, K. Kuwahara, Y. Tomita et al., "Primary pontine hemorrhage in the acute stage: clinical features and a proposed new simple scoring system," *Journal of Stroke and Cerebrovascular Diseases*, vol. 24, no. 4, pp. 860–865, 2015.
- [21] C. Tao, H. Li, J. Wang, and C. You, "Predictors of surgical results in patients with primary pontine hemorrhage," *Turkish Neurosurgery*, vol. 26, no. 1, pp. 77–83, 2016.
- [22] S. Y. Lee, J. Y. Lim, E. K. Kang, M. K. Han, H. J. Bae, and N. J. Paik, "Prediction of good functional recovery after stroke based on combined motor and somatosensory evoked potential findings," *Journal of Rehabilitation Medicine*, vol. 42, no. 1, pp. 16–20, 2010.
- [23] Y. Chen, L. Wang, J. Zhang et al., "Monitoring of patients with brainstem hemorrhage: a simultaneous study of quantitative electroencephalography and transcranial Doppler," *Clinical Neurophysiology*, vol. 132, no. 4, pp. 946–952, 2021.
- [24] V. Deletis and I. Fernandez-Conejero, "Intraoperative monitoring and mapping of the functional integrity of the brainstem," *Journal of Clinical Neurology*, vol. 12, no. 3, pp. 262–273, 2016.
- [25] L. C. Chao, A. R. Abbasali Tailor, C. H. Chen, and J. S. Lee, "Delayed trigeminal motor denervation after pontine hemorrhage," *Journal of Stroke and Cerebrovascular Diseases*, vol. 24, no. 9, pp. e261–e263, 2015.
- [26] S. K. Kim, A. R. Kim, J. Y. Kim, and D. Y. Kim, "A long-term follow-up of pontine hemorrhage with hearing loss," *Annals of Rehabilitation Medicine*, vol. 39, no. 4, pp. 634–639, 2015.
- [27] J. W. Seong, M. H. Kim, H. K. Shin, H. D. Lee, J. B. Park, and D. S. Yang, "Usefulness of the combined motor evoked and somatosensory evoked potentials for the predictive index of functional recovery after primary pontine hemorrhage," *Annals of Rehabilitation Medicine*, vol. 38, no. 1, pp. 13–18, 2014.
- [28] J. C. Hemphill 3rd, S. M. Greenberg, C. S. Anderson et al., "Guidelines for the management of spontaneous intracerebral hemorrhage," *Stroke*, vol. 46, no. 7, pp. 2032–2060, 2015.
- [29] C. S. Anderson, E. Heeley, Y. Huang et al., "Rapid blood-pressure lowering in patients with acute intracerebral hemorrhage," *The New England Journal of Medicine*, vol. 368, no. 25, pp. 2355–2365, 2013.
- [30] A. I. Qureshi, Y. Y. Palesch, W. G. Barsan et al., "Intensive blood-pressure lowering in patients with acute cerebral hemorrhage," *The New England Journal of Medicine*, vol. 375, no. 11, pp. 1033–1043, 2016.
- [31] G. Boulouis, A. Morotti, J. N. Goldstein, and A. Charidimou, "Intensive blood pressure lowering in patients with acute intracerebral haemorrhage: clinical outcomes and haemorrhage expansion. Systematic review and meta-analysis of randomised trials," *Journal of Neurology, Neurosurgery, and Psychiatry*, vol. 88, no. 4, pp. 339–345, 2017.
- [32] B. K. Shrestha, L. Ma, Z. Lan, H. Li, and C. You, "Surgical management of spontaneous hypertensive brainstem hemorrhage," *Interdisciplinary Neurosurgery*, vol. 2, no. 3, pp. 145–148, 2015.
- [33] W. J. Zheng, S. W. Shi, and J. Gong, "The truths behind the statistics of surgical treatment for hypertensive brainstem hemorrhage in China: a review," *Neurosurgical Review*, vol. 45, pp. 1195–1204, 2022.
- [34] Z. Lan, S. A. Richard, L. Hao, M. Chen, and C. You, "Spontaneous hypertensive brainstem hemorrhage: does surgery benefit the severe cases?," *Interdisciplinary Neurosurgery*, vol. 15, pp. 66–70, 2019.
- [35] L. H. Chen, F. J. Li, H. T. Zhang, W. J. Chen, K. Sun, and R. X. Xu, "The microsurgical treatment for primary hypertensive brainstem hemorrhage: experience with 52 patients," *Asian Journal of Surgery*, vol. 44, no. 1, pp. 123–130, 2021.
- [36] H. Takahama, K. Morii, M. Sato, K. Sekiguchi, and S. Sato, "Stereotactic aspiration in hypertensive pontine hemorrhage: comparative study with conservative therapy," *No Shinkei Geka Neurological Surgery*, vol. 17, no. 8, pp. 733–739, 1989.
- [37] K. Li, X. Ding, Q. Wang et al., "Low-cost, accurate, effective treatment of hypertensive cerebral hemorrhage with three-dimensional printing technology," *Frontiers in Neurology*, vol. 12, article 608403, 2021.
- [38] Q. Wang, W. Guo, Y. Liu et al., "Application of a 3D-printed navigation mold in puncture drainage for brainstem hemorrhage," *The Journal of surgical research*, vol. 245, pp. 99–106, 2020.
- [39] C. Peng, L. Yang, W. Yi et al., "Application of fused reality holographic image and navigation technology in the puncture treatment of hypertensive intracerebral hemorrhage," *Frontiers in Neuroscience*, vol. 16, article 850179, 2022.
- [40] J. T. Hong, S. J. Choi, D. K. Kye, C. K. Park, S. W. Lee, and J. K. Kang, "Surgical outcome of hypertensive pontine hemorrhages: experience of 13 cases," *Journal of Korean Neurosurgical Society*, vol. 27, no. 1, pp. 59–65, 1998.
- [41] S. Ichimura, H. Bertalanffy, M. Nakaya et al., "Surgical treatment for primary brainstem hemorrhage to improve postoperative functional outcomes," *World Neurosurgery*, vol. 120, pp. e1289–e1294, 2018.
- [42] Y. Yang, B. van Niftrik, X. Ma et al., "Analysis of safe entry zones into the brainstem," *Neurosurgical Review*, vol. 42, no. 3, pp. 721–729, 2019.
- [43] A. Tayebi Meybodi, B. K. Hendricks, A. J. Witten, J. Hartman, S. B. Tomlinson, and A. A. Cohen-Gadol, "Virtual exploration of safe entry zones in the brainstem: comprehensive definition and analysis of the operative approach," *World Neurosurgery*, vol. 140, pp. 499–508, 2020.
- [44] J. L. Serrato-Avila, J. A. Archila, M. D. da Costa et al., "Three-dimensional quantitative analysis of the brainstem safe entry zones based on internal structures," *World Neurosurgery*, vol. 158, pp. e64–e74, 2022.
- [45] H. Takimoto, K. Iwaisako, S. Kubo, K. Yamanaka, J. Karasawa, and T. Yoshimine, "Transaqueductal aspiration of pontine hemorrhage with the aid of a neuroendoscope. Technical note," *Journal of Neurosurgery*, vol. 98, no. 4, pp. 917–919, 2003.
- [46] W. I. Essayed, H. Singh, G. Lapadula, G. J. Almodovar-Mercado, V. K. Anand, and T. H. Schwartz, "Endoscopic endonasal approach to the ventral brainstem: anatomical feasibility and surgical limitations," *Journal of Neurosurgery*, vol. 127, no. 5, pp. 1139–1146, 2017.
- [47] B. Liu, T. Zheng, Y. Mao, K. Bian, S. He, and W. Lv, "Endoscopic endonasal transclival approach to spontaneous hypertensive brainstem hemorrhage," *The Journal of craniofacial surgery*, vol. 31, no. 5, pp. e503–e506, 2020.

- [48] T. E. Topczewski, A. D. Somma, D. Culebras et al., “Endoscopic endonasal surgery to treat intrinsic brainstem lesions: correlation between anatomy and surgery,” *Rhinology*, vol. 59, no. 2, pp. 191–204, 2020.
- [49] X. L. Jin, Y. Zheng, H. M. Shen et al., “Analysis of the mechanisms of rabbit’s brainstem hemorrhage complicated with irritable changes in the alvine mucous membrane,” *World journal of gastroenterology.*, vol. 11, no. 11, pp. 1610–1615, 2005.
- [50] T. Lekic, J. Tang, and J. H. Zhang, “A rat model of pontine hemorrhage,” *Acta neurochirurgica Supplement.*, vol. 105, pp. 135–137, 2008.
- [51] T. Lekic, W. Rolland, A. Manaenko et al., “Evaluation of the hematoma consequences, neurobehavioral profiles, and histopathology in a rat model of pontine hemorrhage,” *Journal of Neurosurgery*, vol. 118, no. 2, pp. 465–477, 2013.
- [52] X. Guo, L. Ma, H. Li et al., “Brainstem iron overload and injury in a rat model of brainstem hemorrhage,” *Journal of Stroke and Cerebrovascular Diseases*, vol. 29, no. 8, article 104956, 2020.
- [53] X. Guo, X. Qi, H. Li et al., “Deferoxamine alleviates iron overload and brain injury in a rat model of brainstem hemorrhage,” *World Neurosurgery*, vol. 128, pp. e895–e904, 2019.
- [54] C. Tao, R. Zhang, X. Hu et al., “A novel brainstem hemorrhage model by autologous blood infusion in rat: white matter injury, magnetic resonance imaging, and neurobehavioral features,” *Journal of Stroke and Cerebrovascular Diseases*, vol. 25, no. 5, pp. 1102–1109, 2016.
- [55] X. Tang, L. Wu, M. Luo, Z. Qiu, and Y. Jiang, “Massive pontine hemorrhage by dual injection of autologous blood,” *Journal of Visualized Experiments*, vol. 171, no. 171, 2021.
- [56] B. K. Shrestha, X. Guo, L. Ma et al., “Rat brainstem hemorrhage model: key points to success in modeling,” *World Neurosurgery*, vol. 117, pp. e106–e116, 2018.