

# Rare Presentation of Ulnar Nerve Palsy in Closed Both Bone Forearm Fracture in Pediatric Population

Rajan Toor<sup>1</sup>, Nicholas Antao<sup>1</sup>, Nitin Ghag<sup>1</sup>

## Learning Point of the Article:

Orthopedic surgeons should never miss detailed early neurological examination in patients with both bone forearm fracture

## Abstract

**Introduction:** Ulnar nerve injury in closed both bone forearm fracture is rare. Most nerve injuries are neuropraxia and rarely the nerve is trapped or is transected. Most of the time recovery is spontaneous but sometimes requires surgical exploration. We are reporting a case of a 14-year-old boy with closed both bone forearm fracture with ulnar nerve palsy due to entrapment and laceration between ulnar bone fracture fragment.

**Case Report:** A 14-year-old boy presented in emergency department elsewhere with a left forearm closed injury due to fall while playing where he was diagnosed with both bone forearm shaft fracture with ulnar nerve palsy and was given an above elbow slab. After 3 days, the patient presented to our outpatient department (OPD) with completely absent sensation over little finger, ulnar aspect of ring finger, and ulnar clawing. No signs of compartment syndrome in the form of tense swelling or stretch pain were seen. There was a suspected ulnar nerve injury for which patient was admitted and posted for fracture fixation and exploration of the nerve in emergency which showed lacerated ulnar nerve trapped in fracture fragment. Open reduction and internal fixation with ulnar plating and radius titanium elastic nailing was done by orthopedic surgeon while ulnar nerve neurolysis and micro repair was subsequently done by plastic surgeon. There was no neurological recovery immediately post-operatively. Patient was discharged after 48 h and called for regular follow-up in OPD to assess fracture union and neurological recovery. There was gradual neurological recovery over the period of time. Complete motor and sensory recovery took place in 4 months.

**Conclusion:** Ulnar nerve injury associated with close both bone forearm fracture is uncommon. They are usually associated with a contusion for which the treatment is basically conservative. Immediate nerve exploration and fracture fixation should be reserved for suspicious nerve laceration or entrapment within displaced fracture fragments on radiographs. This prevents delay and also avoids nerve sequelae to occur. Hence, high index of suspicion and complete neurological examination of the patient at first presentation is important to recognize and diagnose the type of nerve lesion early to decide upon the plan of management.

**Keywords:** Ulnar nerve palsy, both bone forearm fracture, ulnar plating and radius titanium elastic nailing, neurolysis

## Introduction

Among all fractures in pediatric population, both bone forearm fracture accounts for 30–40% [1]. Nerve injuries are a known complication in these fractures, median nerve being the commonest while ulnar nerve injury is rare [2, 3]. The incidence of neurologic injury with both bone forearm fracture was found to be 15.6%, from which distal physal fractures accounted for

37% [4]. We have found around 15 published case reports shown in (Table 1). In the literature, exact incidence of these nerve injuries has not been mentioned. Mechanism of injury include direct contusion from the displaced fragment, traction injury while attempting closed reduction, entrapment of nerve at the fracture site, acute compartment syndrome, delayed nerve palsy due to nerve getting adhered to scar tissue. The most common

Access this article online

Website:  
www.jocr.co.in

DOI:  
10.13107/jocr.2021.v11.i09.2418

## Author's Photo Gallery



Dr. Rajan Toor



Dr. Nicholas Antao



Dr. Nitin Ghag

<sup>1</sup>Department of Orthopedics, Holy Spirit Hospital, Mahakali Caves Road, Andheri (E), Mumbai, Maharashtra, India.

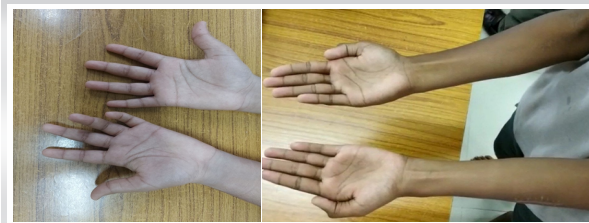
### Address of Correspondence:

Dr. Rajan Toor,  
Department of Orthopedics, Holy Spirit Hospital, Mahakali Caves Road, Andheri (E), Mumbai - 400 093, Maharashtra, India.  
E-mail: dr.rajantoor@gmail.com

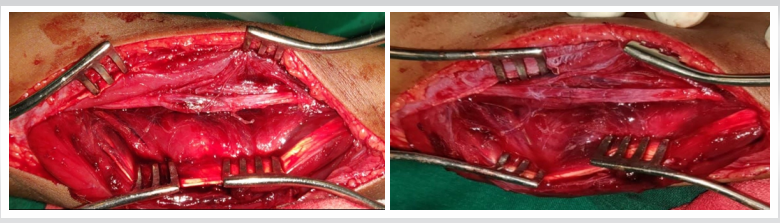
Submitted: 07/06/2021; Review: 15/06/2021; Accepted: July 2021; Published: September 2021

DOI:10.13107/jocr.2021.v11.i09.2418

This is an open access journal, and articles are distributed under the terms of the Creative Commons Attribution-NonCommercial-ShareAlike 4.0 License <https://creativecommons.org/licenses/by-nc-sa/4.0/>, which allows others to remix, tweak, and build upon the work non-commercially, as long as appropriate credit is given and the new creations are licensed under the identical terms



**Figure 1:** (a) Pre-op Ulnar hand clawing. (b) Post-op complete neurological recovery.

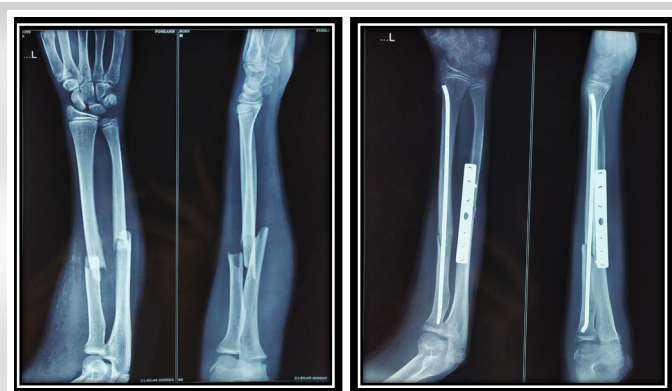


**Figure 2:** (a) Ulnar nerve entrapment and laceration. (b) Ulnar nerve neurolysis.

pathophysiology is neuropraxia while laceration and transection occur rarely [1]. Mostly recovery is spontaneous but sometimes surgical exploration of the nerve during fracture fixation may be required in cases of worsening neuropraxia or suspected nerve entrapment and laceration at the fracture site [5]. Before any manipulative reduction of forearm fractures in children, a proper neurologic examination should be done to identify the type of nerve damage and plan its management [6, 7]. Here, we are reporting a case of a 14-year-old boy with closed both bone forearm shaft displaced fracture with ulnar nerve palsy due to laceration following entrapment between fracture fragments.

### Case Report

A 14-year-old boy presented in emergency department elsewhere with left forearm closed injury due to fall while playing where he was diagnosed with both bone forearm shaft fracture shown in Fig. 1a with ulnar nerve palsy and was given an above elbow slab. After 3 days, the patient presented to our outpatient department (OPD) with completely absent sensation over the little finger, ulnar aspect of the ring finger, and ulnar clawing shown in Fig. 2a. No signs of compartment syndrome in the form of tense swelling or stretch pain was seen. There was a suspected ulnar nerve injury for which the patient was admitted and posted for fracture fixation and exploration of the nerve under anesthesia. Exposure was done using volar approach which showed longitudinal laceration (1–1.5 cm) with partial transection of ulnar nerve trapped in proximal ulnar fracture fragment at same level of fracture shown in Fig. 3a. Open reduction and internal fixation with ulnar plating and



**Figure 3:** (a) Pre-op X-ray showing both bone forearm fracture (b) Post-op X-ray showing ulna plating and radius nailing.

radius titanium elastic nailing was done by orthopedic surgeon shown in Fig. 1b while ulnar nerve neurolysis and epineural repair using 8-0 ethilon as shown in Fig. 3b was subsequently done by plastic surgeon. Wound was closed in layers over the drain and volar slab was applied. The patient was discharged after 48hrs and called for regular follow-up in OPD to assess fracture union and neurological recovery. The patient was kept in volar slab for 6 weeks and thereafter ulnar claw splint for 6 weeks. Physiotherapy was started after 6 weeks post-operatively. There was no neurological recovery immediate post-operatively. There was gradual neurological recovery over the period of time demonstrated by progressive Tinel's sign. Complete motor and sensory recovery took place in 4 months as shown in Fig. 2b.

### Discussion

Most of the pediatric closed both bone forearm fractures are conservatively managed with closed reduction and casting. Surgical intervention is done in open fractures, failed or unstable reductions, segmental fractures, neurovascular injuries, and skeletally mature individuals [8]. Ulnar nerve injury in closed both bone forearm fractures is a rare entity [9]. Till date around 15 cases have been documented in the literature as shown in (Table 1).

Anatomically the ulnar nerve runs parallel to the flexor digitorum profundus muscle deep to flexor carpi ulnaris muscle on the forearm protected by the surrounding muscle and is therefore rarely contused directly by an external force. However, the nerve being close to the ulna at middle and distal thirds; any significant angulation and displacement with a bone spike can directly injure the nerve [10]. Certain specific fracture patterns such as apex volar angulation, a proximal ulnar oblique fragment at the middle to the distal third of the forearm (as seen in this case), or those with significant displacement has been associated with ulnar nerve injury [5]. Mechanisms such as direct contusion from the displaced fracture or persistent direct pressure from an unreduced fracture are responsible for nerve injury at the time of fracture [11]. In our reported case, ulnar nerve palsy occurred due to entrapment within fracture fragments as shown in (Fig. 3a).

Complete neurological assessment on the first presentation is very important to diagnose the type of nerve injury and to

Table 1: Summary of the reported cases of ulnar nerve palsy after closed forearm both-bone fracture [14]

Author (year)	Patient	Management	Findings and outcome
Ekiz et al. (2017)	13-year-old boy	Closed reduction and elastic nailing Highlights the use of ultrasound	Spontaneous recovery after 3 months
Shwartzmann et al. (2016)	17-year-old boy	Ulnar sensory deficit presents initially; open repair and plate fixation	Ulnar nerve laceration Outcome not mentioned
Amit et al. (2013)	Child, unspecified	Closed reduction	Spontaneous, almost full recovery after 3 months
Shimbashi et al. (2013)	Article in Japanese	Article in Japanese	Article in Japanese
Küçük et al. (2012)	8-year-old boy	Closed reduction. Surgical release of the ulnar nerve after 3 months	Ulnar nerve entrapped in the callus Outcome unknown
Suganuma et al. (2012)	12-year-old girl	Closed reduction and elastic Neurolysis 9 weeks later	No motor dysfunction after 6 months
Lu et al. (2007)	14-year-old boy	Closed reduction with percutaneous pinning of a distal radius fracture	Spontaneous full recovery after 16 weeks
Hirasawa et al. (2004)	13-year-old girl	Closed reduction and casting. Surgical exploration and neurolysis after 3 months	Ulnar nerve entrapped at fracture site. Full recovery in 4 months
Neiman et al. (1998)	2 patients, unspecified	Ulnar palsy before reduction. Treated by closed reduction in both patients	Spontaneous recovery after 20 weeks in both patients
Stahl et al. (1997)	10-year-old boy	Neurapraxia on presentation. Closed reduction and casting. Neurolysis under the 2operating microscope 10 weeks after reduction	Nerve entrapped in hypertrophic scar Complete sensory recovery and partial motor recovery after 1 year
	15-year-old boy	Closed reduction and casting. Neurapraxia next day. Minimal internal neurolysis was performed 4 months later	Nerve partially kinked by scar. Full recovery within 1 month of surgery
	9-year-old boy	Palsy at presentation. Open reduction after failure of closed reduction and nerve repair	Nerve entrapped in bony spike and partially lacerated. Full recovery after 6 months
Torpey et al. (1996)	15-year-old girl	Ulnar palsy at presentation. Surgical exploration of the ulnar nerve and fracture fixation by plates and screws	Almost complete nerve laceration. Persistent anesthesia, muscle atrophy, and weakness in the ulnar nerve distribution after 2 years.
Zain-ur-Rehman (2020)	14-year-old boy	Open reduction and internal fixation of the fracture with release of the nerve from bone spike	Ulnar nerve was found trapped on a spike of the ulna Full recovery after 5 months



decide about the plan of care. Treatment can vary from conservative observation of the neuropraxia to nerve exploration and repair for nerve transection or laceration. Stavarakakis et al. [12] recommended nerve exploration for post manipulation nerve palsy, worsening nerve injuries, and those not showing any improvement after 20 weeks of injury. Anatomical fracture fixation is essential for favorable functional outcome after the injury [8]. Similar to our study, Hirasawa et al. [13] showed in their study that complete neurological recovery was achieved at 4 months' post-surgery. Dalhin et al. [6] concluded that a meticulous neurological examination should be made in all forearm fractures in adults and in children pre-operatively and post-operatively. M Zain-ur-Rehman et al. [7] said that it is important to evaluate the patient neurologically before any procedure or manipulation and manage same according to the type of lesion. The injured nerve should be explored at the time of open repositioning and plating of the fracture.

We feel that there is a tendency to look only at the x-rays of the fractured limb and miss complete neurological examination at the time of initial presentation. Also in pediatric population, patients may not be able to tell about sensory loss and motor

deficit. Missing neurological injury at initial assessment likely has chances of long-term sequelae [4].

## Conclusion

Ulnar nerve injury associated with close both bone forearm fracture is uncommon. When the nerve is injured, it is usually a contusion injury for which the treatment is conservative. Immediate nerve exploration and fracture fixation should be performed upon suspicion of nerve laceration or entrapment with displaced fracture fragments on radiographs. This prevents delay and also avoids nerve sequelae to occur. Hence, it is important to have a high index of suspicion to recognize and diagnose the type of nerve lesion early with thorough neurological assessment to decide upon the plan of management and get optimum results.

## Clinical Message

Early complete neurological examination in a patient with both bone forearm fracture is very important to prevent missing the rare ulnar nerve injury.

**Declaration of patient consent:** The authors certify that they have obtained all appropriate patient consent forms. In the form, the patient's parents have given their consent for patient images and other clinical information to be reported in the journal. The patient's parents understand that his names and initials will not be published and due efforts will be made to conceal their identity, but anonymity cannot be guaranteed.

**Conflict of interest:** Nil **Source of support:** None

## References

- Jones K, Weiner DS. The management of forearm fractures in children: A plea for conservatism. *J Pediatr Orthop* 1999;19:811-5.
- Torpey BM, Pess GM, Kircher MT, Faierman E, Absatz MG. Case report: Ulnar nerve laceration in a closed both bone forearm fracture. *J Orthop Trauma* 1996;10:131-4.
- Neiman R, Maiocco B, Deeney VF. Ulnar nerve injury after closed forearm fractures in children. *J Pediatr Orthop* 1998;18:683-5.
- Bell CJ, Viswanathan S, Dass S, Donald G. The incidence of neurologic injury in paediatric forearm fractures requiring manipulation. *J Pediatr Orthop B* 2010;19:294-7.
- Federer AE, Murphy JS, Calandruccio JH, Devito DP, Kozin SH, Slappey GS, et al. Ulnar nerve injury in pediatric midshaft forearm fractures: A case series. *J Orthop Trauma* 2018;32:e359-65.
- Dahlin LB, D ppe H. Injuries to the nerves associated with fractured forearms in children. *Scand J Plast Reconstr Surg Hand Surg* 2007;41:207-10.
- Zain-ur-Rehman M, Butt AJ, Khan AM, AlKhalfan Y. Ulnar nerve palsy following a closed fracture of shaft of radius and ulna in a child. *Int J Case Rep Orthop* 2020;2:18-20.
- Vopat ML, Kane PM, Christino MA, Truntzer J, McClure P, Katarincic J, et al. Treatment of diaphyseal forearm fractures in children. *Orthop Rev (Pavia)* 2014;6:5325.
- Suganuma S, Tada K, Hayashi H, Segawa T, Tsuchiya H. Ulnar nerve palsy associated with closed midshaft forearm fractures. *Orthopedics* 2012;35:1680-3.
- Clarke AC, Spencer RF. Ulnar nerve palsy following fractures of the distal radius: Clinical and anatomical studies. *J Hand Surg Br* 1991;16:438-40.
- Schwartzmann CR, Ruschel PH, Huyer RG. Ulnar nerve paralysis after forearm bone fracture. *Rev Bras Ortop* 2016;51:475-7.
- Stavarakakis IM, Daskalakis II, Magarakis GE, Christoforakis Z, Katsafarou MS. Ulnar nerve injuries post closed forearm fractures in paediatric population: A review of the literature. *Clin Med Insights Pediatr* 2019;13:117955651984187.
- Hirasawa H, Sakai A, Toba N, Kamiuttanai M, Nakamura T, Tanaka K. Bony entrapment of ulnar nerve after closed forearm fracture: A case report. *J Orthop Surg (Hong Kong)* 2004;12:122-5.
- Hamdan MQ, Haddad BI, Hawa A, Abdelhamid SS. Ulnar nerve palsy as a complication of closed both-bone forearm fracture in a pediatric patient: A case report. *Int Med Case Rep J* 2019;12:79-84.



**Conflict of Interest:** Nil

**Source of Support:** Nil

**Consent:** The authors confirm that informed consent was obtained from the patient for publication of this case report

#### How to Cite this Article

Toor R, Antao N, Ghag N. Rare Presentation of Ulnar Nerve Palsy in Closed Both Bone Forearm Fracture in Pediatric Population. Journal of Orthopaedic Case Reports 2021 September;11(9):62-66.

