

[Orthopaedics]



Cervical Spine Injuries and the Return to Football

Joseph S. Torg, MD

Background: The literature dealing with the diagnosis and treatment of cervical spine injuries is considerable. Absent, however, are comprehensive criteria or guidelines for permitting or prohibiting return to collision activities such as tackle football.

Objective: The purpose of this report is to describe developmental and posttraumatic conditions of the cervical spine as presenting (1) no contraindication, (2) relative contraindication, or (3) an absolute contraindication to continued participation in tackle football and other contact activities.

Study Design: Systematic review.

Methods: Analysis of data compiled from more than 1200 cervical spine injuries documented by the National Football Head and Neck Registry, in addition to a review of the limited published literature, plus an understanding of the recognized axial load injury mechanism and extensive anecdotal experience.

Conclusion: The one overriding principle regarding the return to football or, for that matter, any collision activity is that the individual be asymptomatic, pain-free, and neurologically intact and have full strength and full range of cervical motion.

Keywords: football injuries; cervical spine injuries; cervical cord neurapraxia; return to play criteria

The literature dealing with the diagnosis and treatment of cervical spine injuries is considerable. Absent, however, are comprehensive criteria or guidelines for permitting or prohibiting return to collision activities such as tackle football. The purpose of this report is to describe developmental and posttraumatic conditions of the cervical spine as presenting (1) no contraindication, (2) relative contraindication, or (3) an absolute contraindication to continued participation. For the purpose of this discussion, the following guidelines are used: First, *no contraindication* is a condition where no recognized risk factors are documented in the literature or known on the basis of anecdotal experience; second, *relative contraindication* is a condition where permitting return to play is predicated on less-than-unequivocally substantiated data regarding risk, as documented in the literature or by anecdotal experience; and, finally, an *absolute contraindication* is a condition in which recognized risk factors are documented in the literature or known on the basis of experience.

The structure and mechanics of the cervical spine enable it to perform 2 important functions: First, it supports and permits

multiplan motion of the head; second, it serves as a protective conduit for the spinal cord and cervical nerve roots. Any condition that impedes or prevents the performance of these functions constitutes a contraindication to participation in contact sports.

The one overriding principle regarding the return to football or, for that matter, any collision activity is that the individual be neurologically intact, asymptomatic, and pain-free and have full strength and a full range of cervical motion.

The following criteria for return to contact activities in the presence of cervical spine abnormalities or postinjury are intended as guidelines only. Owing to a lack of creditable scientific evidence, they are for the most part predicated on anecdotal experience at best.

NERVE ROOT-BRACHIAL PLEXUS INJURY

The most common cervical problems are the pinch-stretch injuries to the nerve roots and the brachial plexus. Neurapraxia, the mildest form of injury, represents a reversible aberration of axonal function, with complete recovery occurring almost

From the Department of Orthopedic Surgery, Temple University School of Medicine, Philadelphia, Pennsylvania

Address correspondence to Joseph S. Torg, MD, Temple University Hospital, 3401 North Broad Street, Philadelphia, PA 19140 (e-mail: Joseph.torg@tuhs.temple.edu).

No potential conflict of interest declared.

DOI: 10.1177/1941738109343161

© 2009 The Author(s)

immediately or within 2 weeks. Axonotmesis involves disruption of the axon and myelin sheath, with the epineurium remaining intact and with Wallerian degeneration occurring distal to the point of injury. Functional recovery may occur, but it can be incomplete and unpredictable. The most severe injury, neurotmesis, is rarely seen in athletes, and it results in complete disruption of the nerve.^{5,6}

The “burner” or “stinger” results from either of 2 distinct injury patterns: traction to the brachial plexus or compression of the cervical nerve roots. Brachial plexus injuries are typically traction neurapraxias occurring in younger athletes as a result of shoulder depression and lateral neck flexion away from the side of injury. Cervical root injuries typically occur in older players. They are hyperextension injuries, and they are associated with degenerative disk changes, often in combination with developmental cervical stenosis.

Brachial plexus injuries are more likely to occur in younger patients; they are traction injuries resulting from lateral neck flexion (away from the involved area) and shoulder depression (to the side of involvement). Neck pain can be present but is usually not a prominent feature. When pain is present, cervical spine roentgenograms are necessary. Pain and paresthesias involving the arm and the shoulder are typically transient. On examination, a Spurling’s test result is negative. Weakness typically involves the deltoid, the spinati, and the biceps and might not be initially evident on clinical examination, thereby making a follow-up visit necessary. The key to the nature of this lesion is its short duration and the presence of a full, pain-free range of neck motion. Although the majority of these injuries are short-lived, they are worrisome because of the occasional plexus axonotmesis that occurs. The youngster whose paresthesia completely abates, who demonstrates full muscle strength in the intrinsic muscles of the shoulder and upper extremities, and who, most important, has a full, pain-free range of cervical motion may return to his or her activity.

Root lesions result from compression of the nerve root or dorsal root ganglion in the intervertebral foramen. They are generally associated with radiologic evidence of cervical disk disease and developmental stenosis, and they usually occur when the player reaches the college or professional level. Hyperextension with lateral neck flexion is the common mechanism of injury. Neck pain and a decreased cervical range of motion may be present. Spurling’s test result is positive. Plain roentgenographic findings may be normal or demonstrate loss of normal cervical lordosis and the changes of degenerative disk disease. MRI is indicated in patients with a persistent neurologic deficit and prolonged or recurrent symptoms, and it will demonstrate either acute disk herniation or degenerative disk disease with asymmetrical disk bulging. Older patients often have developmental spinal stenosis, degenerative disk disease, and asymmetrical disk bulging that results in root irritation with cervical hyperextension.⁸

Persistence of paresthesia, weakness, or limitation of cervical motion requires that the individual be protected from further exposure. Persistent or recurrent episodes require a complete

neurologic and roentgenographic/imaging workup. If routine roentgenographic films of the cervical spine are negative and a preganglionic root lesion is suspected, then MRI, plain myelography, or CT myelography should be considered. Disk herniation, foraminal narrowing, and extradural intraspinal masses should be considered in the differential diagnosis. A complete electromyographic examination may be helpful, including nerve conduction studies and a needle electrode examination. These studies should be delayed for 3 to 4 weeks from the time of the initial injury. Nerve conduction studies should include routine conduction as well as sensory nerve action potential evaluations. Electrode evaluation of the cervical spine musculature will differentiate preganglionic root injuries and plexus disorders.¹⁶

Electrodiagnostic studies may be helpful but are not mandatory in the management of burners secondary to brachial plexus injury. Although there is no correlation between initial physical findings and the results of electrodiagnostic testing, evidence of muscular weakness 72 hours after the injury does correlate with positive electromyographic results. Electromyographic changes continue to appear long after weakness has clinically resolved; therefore, abnormal electromyographic findings should not be used as a criterion for exclusion from athletic participation.²

Criteria for return to athletic participation include absence of symptoms, normal strength, and painless full range of motion of the cervical spine. Players who experience 1 or more burners should wear appropriate neck rolls or cowboy collars to prevent extreme hyperextension and lateral bending of the cervical spine. A year-round muscle-strengthening program for the neck and shoulder will aid in the prevention of the burner syndrome.

ACUTE CERVICAL SPRAIN SYNDROME

An acute cervical sprain is a collision injury frequently seen in contact sports. The patient complains of having “jammed” his or her neck, with subsequent pain localized to the cervical area. The patient characteristically presents with limitation of cervical spine motion but without radiation of pain or paresthesia. Neurologic examination is negative and roentgenograms are normal.

Stable cervical sprains and strains eventually resolve with or without treatment. The presence of a serious injury should initially be ruled out by performing a thorough neurologic examination and determining the range of cervical motion. Range of motion is evaluated by having the athletes perform the following actions: actively nod their head, touch their chin to their chest, maximally extend their neck, touch their chin to their left shoulder and then to their right shoulder, touch their left ear to their left shoulder and then their right ear to their right shoulder. If the patient is unwilling or unable to actively perform these maneuvers while standing erect, proceed no further. The athlete with weakness, persistent paresthesia, or less than a full, pain-free range of cervical motion should be protected and

Table 1. Congenital conditions: contraindication to return to athletic activity.

Congenital Condition	Contraindication		
	None	Relative	Absolute
Odontoid agenesis			×
Odontoid hypoplasia			×
Os odontoideum			×
Spina bifida occulta	×		
Atlanto-occipital fusion			×
Klippel-Feil anomaly			
Type I: mass fusion of the cervical and upper thoracic vertebrae			×
Type II: fusion of only 1 or 2 interspaces at C3 and below with full cervical range of motion and no occipitocervical abnormalities, instability, disk disease, or degenerative changes	×		

excluded from activity. Subsequent evaluation should include appropriate roentgenographic studies, including flexion and extension views to demonstrate fractures or instability.

In general, treatment of athletes with cervical sprains should be tailored to the severity of the injury. Immobilizing the neck in a soft collar and using analgesics and anti-inflammatory agents until there is a full, spasm-free range of neck motion is appropriate. Individuals with a history of collision injury, pain, and limited cervical motion should have routine cervical spine roentgenograms. Also, lateral flexion and extension roentgenograms are indicated after the acute symptoms have subsided. Marked limitation of cervical motion, persistent pain, or radicular symptoms or findings may require MRI to rule out intervertebral disk injury.^{3,12,13}

Congenital Conditions

This section reviews 4 congenital conditions specific to contraindication and return to play: odontoid anomalies, spina bifida occulta, atlanto-occipital fusion, and Klippel-Feil anomaly. See Table 1 for summary.

Odontoid anomalies. The presence of odontoid agenesis, odontoid hypoplasia, or os odontoideum is an absolute contraindication to participation in contact activities.¹²

Spina bifida occulta. Spina bifida occulta is a rare incidental roentgenographic finding that presents no contraindication.¹²

Atlanto-occipital fusion. Atlanto-occipital fusion, as an isolated entity or coexisting with other abnormalities, constitutes an absolute contraindication.¹²

Klippel-Feil anomaly. This eponym is applied to congenital fusion of 2 or more cervical vertebrae. The variety of

abnormalities can be divided into 2 groups: type I, mass fusion of the cervical and upper thoracic vertebrae; type II, fusion of only 1 or 2 interspaces. The type I lesion constitutes an absolute contraindication because of the marked alteration in spinal mechanics, possibly predisposing to injury or degenerative changes. The type II lesion—with associated limited motion and/or associated occipitocervical anomalies instability, disk disease, or degenerative changes—also constitutes an absolute contraindication. Type II lesions involving fusion of 1 or 2 interspaces at C3 and below—in an individual with full cervical range of motion and an absence of occipital cervical anomalies, instability, disk disease, and degenerative changes—present no contraindication.¹⁰

CERVICAL CORD NEURAPRAXIA

The clinical picture of cervical cord neurapraxia, with or without transient quadriplegia, characteristically involves an athlete who sustains an acute transient neurologic episode of cervical cord origin with sensory changes that may be associated with motor paresis involving both arms, both legs, or all 4 extremities after forced hyperextension, hyperflexion, or axial loading of the cervical spine. Sensory changes include burning pain, numbness, tingling, or loss of sensation; motor changes consist of weakness or complete paralysis. The episodes are transient, and complete recovery usually occurs in 10 to 15 minutes, although in some cases, gradual resolution does not occur for 36 to 48 hours. Except for burning paresthesia, neck pain is not present at the time of injury. There is complete return of motor function and full, pain-free cervical motion. Routine roentgenograms of the cervical spine show no evidence of fracture or dislocation, but a demonstrable degree of cervical spinal stenosis is present. The association of developmental narrowing of the cervical canal with cervical cord neurapraxia

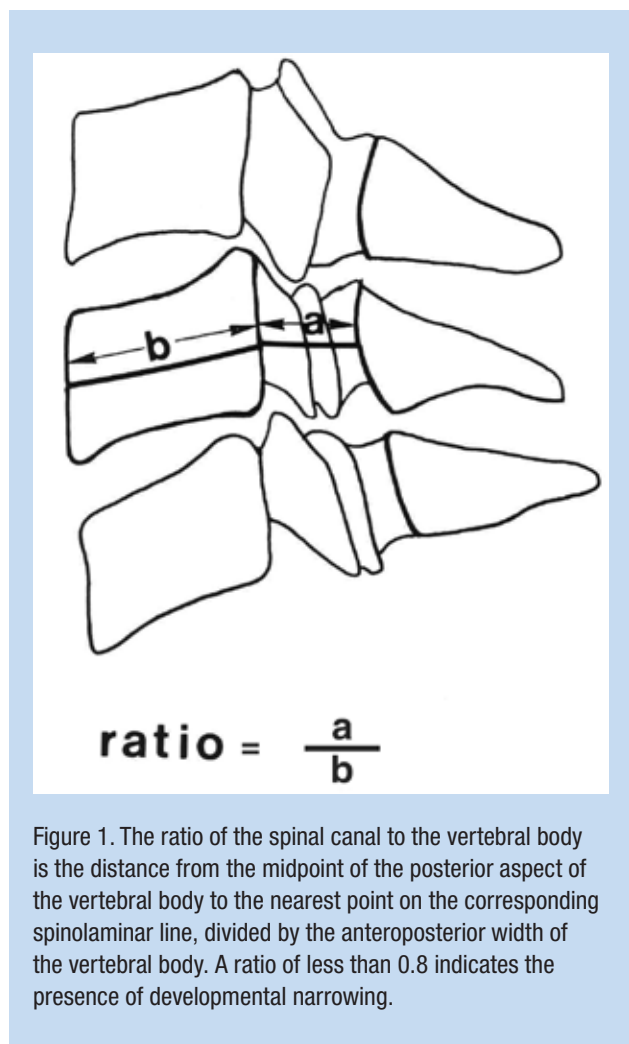


Figure 1. The ratio of the spinal canal to the vertebral body is the distance from the midpoint of the posterior aspect of the vertebral body to the nearest point on the corresponding spinolaminar line, divided by the anteroposterior width of the vertebral body. A ratio of less than 0.8 indicates the presence of developmental narrowing.

and transient quadriplegia has been well defined.⁹ Narrowing or stenosis is defined as a cervical segment with 1 or more vertebra having a canal-body ratio of 0.8 or less and is predicated on the fact that 95% of all reported clinical cases have fallen below this value at 1 or more levels (Figure 1).^{3,11,14,19}

The presence of a canal-vertebral body ratio of 0.8 or less is no contraindication to participation in contact activities in asymptomatic individuals.

In those with a ratio of 0.8 or less who experience motor and/or sensory manifestations of cervical cord neurapraxia, there is a relative contraindication to return to contact activities. In instances where there is associated intervertebral disk disease and/or degenerative changes or cord deformation, each case must be evaluated on an individual basis.

Absolute contraindications to continued participation apply to those who experience a documented episode of cervical cord neurapraxia associated with any of the following: ligamentous instability, MRI evidence of cord defects or swelling, symptoms or positive neurological findings lasting more than 36 hours, or more than 1 recurrence (see Table 2 for overview).

Cervical cord neurapraxia is neither associated with, nor does it presage, permanent neurologic sequelae. In one series of 110 reported cases, 60% returned to play and, of those, 56% had a recurrence. The problem, therefore, is not permanent neurologic injury but the recurrence of the sensory and/or motor manifestations of cervical cord neurapraxia, which are predictable. Based on the findings that narrowing of the canal is a causative factor, the recurrence rates and canal diameter data were analyzed and correlated. Graphic plots were constructed using logistic regression analysis for the percentage risk of recurrence versus the disk-level canal diameter and the ratio of the spinal canal to the vertebral body. The plots demonstrated a strong inverse correlation between the risk of recurrence and the disk-level canal diameter and the ratio of the spinal canal to the vertebral body. Thus, the risk of recurrence is predictable, and using these graphs, one can accurately counsel the athlete and his or her parents regarding a return-to-play decision (Figure 2).^{11,15}

Herzog and colleagues⁷ have pointed out that even though the canal-vertebral body ratio has a high sensitivity for detecting cervical spinal stenosis, it had a poor positive predictable value in a group of professional football players because their large vertebral bodies increased the denominator of the equation, thus lowering the ratio for individuals with minimal absolute narrowing of the canal. Of note, there is 1 reported case in the literature of a professional football player with a partial cervical cord injury who had congenital stenosis.⁴

Spear Tackler's Spine

Of note is the subset of football players identified as demonstrating **all of the following**: (1) a developmental narrowing (stenosis) of the cervical canal, (2) a persistent straightening or reversal of the normal cervical lordotic curve on erect lateral roentgenograms obtained in the neutral position, (3) concomitant preexisting posttraumatic roentgenographic abnormalities of the cervical spine, and (4) documentation of having employed spear-tackling techniques. Spear tackler's spine is a clinical entity that constitutes an absolute contraindication to participation in tackle football and other collision activities that expose the cervical spine to axial energy inputs.¹⁷

TRAUMATIC CONDITIONS

The following 2 sections review traumatic conditions regarding the upper cervical spine (C1-C2) and the middle and lower cervical spine with regard to return to athletic activity (Tables 3 and 4).

Traumatic Conditions of the Upper Cervical Spine: C1-C2

Lesions with any degree of occipital or atlanto-axial instability portend a potentially grave prognosis. Thus, any injury involving C1-C2 that involves ligamentous laxity is an absolute

Table 2. Developmental conditions: contraindication to return to athletic activity.

Developmental Condition	Contraindication		
	None	Relative	Absolute
Stenosis of the cervical spinal canal (ie, 1 or more vertebrae with a canal-vertebral body ratio < 0.8)			
... and no other symptoms	×		
... and motor or sensory manifestations of cervical cord neurapraxia		×	
... and documented episode of cervical cord neurapraxia associated with ligamentous instability, MRI evidence of neurologic damage lasting longer than 36 hours, or multiple recurrences			×
Spear tackler's spine: developmental stenosis of the cervical canal; persistent straightening or reversal of the normal cervical lordotic curve; preexisting posttraumatic roentgenographic abnormalities of the cervical spine; a history of prior root or cord neurapraxia; and documentation of the patient's using the spear-tackling technique			×

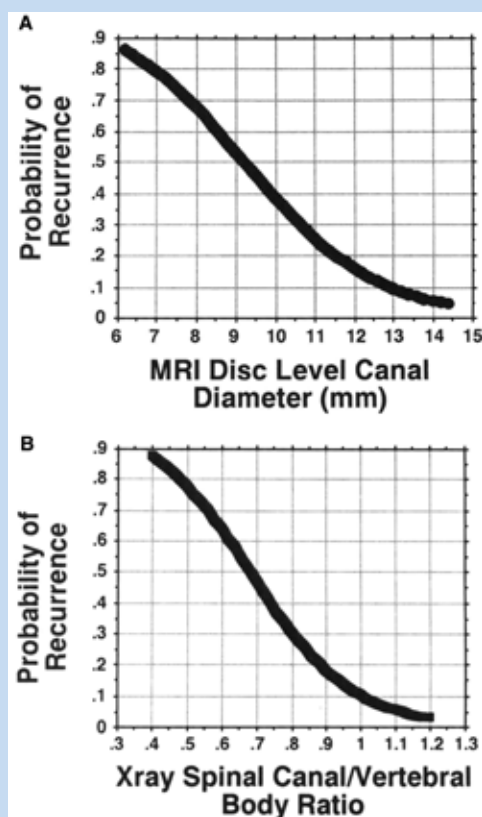


Figure 2. Graphs developed using regression analysis in which the risk of recurrence can be plotted as a function of the disk-level diameter measured on MRI (A) and the spinal canal–vertebral body ratio calculated on the basis of roentgenograms (B). The construction of these plots is based on the result that increased risk of recurrence is inversely correlated with canal diameter. Future patients with cervical cord neurapraxia can be counseled regarding their individual risks of recurrence based on the size of their spinal canals.

contraindication to further participation. Healed nondisplaced Jefferson fractures, healed type I and type II odontoid fractures, and healed lateral mass fractures of C2 constitute relative contraindications, providing that the patient is pain-free, has a full range of cervical motion, and displays no neurological findings.

Because of the uncertainty surround the results of cervical fusion, the gracile configuration of C1, and the importance of the alar and transverse odontoid ligaments, fusion for instability of the upper segment constitutes an absolute contraindication regardless of how successful the fusion appears reontgenographically.^{12,20}

Traumatic Conditions of the Middle and Lower Cervical Spine

Ligamentous injuries. Lateral roentgenograms that demonstrate more than 3.5 mm of horizontal displacement of either one vertebra in relationship to another or more than 11° of rotation than either adjacent vertebra represent an absolute contraindication. With regard to lesser degrees of displacement and rotation, further participation enters the realm of trial by battle, and these situations can be considered relative contraindications depending on such factors as level of performance, physical habitus, and position played.

Fractures. An acute fracture of either the body or posterior elements with or without associated ligamentous laxity constitutes an absolute contraindication.

The following healed stable fractures, in an asymptomatic patient who is neurologically normal and has a full range of cervical motion, present no contraindication to participation in contact activities: (1) stable compression fractures of the vertebral body without a sagittal component on anteroposterior roentgenogram and without involvement of the ligamentous or posterior bony structures; (2) a healed stable end plate fracture without a sagittal component on anteroposterior

Table 3. Traumatic and ligamentous injuries of the upper and middle/lower cervical spine: contraindication to return to athletic activity.

Upper Cervical Spine: Traumatic Injuries	Contraindication		
	None	Relative	Absolute
Almost all injuries of C1-C2 that involve fracture or ligamentous laxity			×
Healed nondisplaced Jefferson fractures in patients who are also pain free, have full range of cervical motion, and no evidence of neurologic injury		×	
Healed type I and type II odontoid fractures in patients who are also pain-free and have full range of cervical motion and no evidence of neurologic injury		×	
Healed lateral mass fractures of C2 in patients who are pain-free, have full range of cervical motion, and have no evidence of neurologic injury		×	
Middle and Lower Cervical Spine: Ligamentous Injuries			
> 3.5 mm of horizontal displacement of either vertebra in relation to the other			×
< 3.5 mm of horizontal displacement of either vertebra in relation to the other and depending on the patient's level of performances, physical habits, and position played		×	
> 11° of rotation of either adjacent vertebra			×
< 11° of rotation of either adjacent vertebra and depending on the patient's level of performance, physical habits, and position played		×	

Table 4. Fractures: contraindication to return to athletic activity.

Fracture	Contraindication		
	None	Relative	Absolute
Healed stable compression fractures of the vertebra body in an asymptomatic patient with no evidence of neurologic injury and full, pain-free range of cervical motion. These fractures can settle and cause increased deformity. Patients with this type of fracture should be carefully observed.	×		
Healed stable end plate fractures without involvement of the ligamentous or posterior bony structures in asymptomatic patients with no evidence of neurologic injury and full, pain-free range of cervical motion	×		
Healed stable spinous process "clay shoveler" fractures in an asymptomatic patient with no evidence of neurologic injury and full, pain-free range of cervical motion	×		
Healed stable fractures involving the elements of the posterior neural ring in asymptomatic patients with no evidence of neurologic injury and full, pain-free range of cervical motion. Because a rigid ring cannot break in one location, healing of paired fractures of the ring must be evident on roentgenographic and imaging studies.		×	
Acute fractures of the vertebral body or posterior bony structures with or without associated ligamentous laxity			×
Vertebral body fractures with evidence of a sagittal component on anteroposterior radiographs			×
Vertebral body fractures with or without displacement with associated posterior arch fractures or ligamentous laxity			×
Comminuted vertebral body fractures with displacement into the spinal canal			×
Any healed fracture of the vertebral body or the posterior bony structures in patients with associated pain, evidence of neurologic injury, and limitation of cervical motion			×
Healed displaced fractures involving the lateral masses with resulting facet incongruity			×

Table 5. Intervertebral disk injuries: contraindication to return to athletic activity.

Injury	Contraindication		
	None	Relative	Absolute
Healed anterior or lateral disk herniation that is treated conservatively in patients who are asymptomatic, have no evidence of neurologic injury, and have full, pain-free range of cervical motion	×		
Lateral or central disk herniation that has been treated with intervertebral discectomy and interbody fusion in patients who have a solid fusion, are asymptomatic, have no evidence of neurologic injury, and have full, pain-free range of cervical motion	×		
Acute or chronic cervical disk herniation in patients with associated neurologic findings, pain, or significant limitation of cervical motion			×

roentgenograms or involvement of the posterior or bony ligamentous structure; and (3) healed spinous process “clay shoveler” fractures.

Relative contraindications apply to the following healed stable fractures in individuals who are asymptomatic, neurologically normal, and have a full, pain-free range of cervical motion: (1) stable displaced vertebral body compression fractures without a sagittal component on anteroposterior roentgenograms and (2) healed stable fractures involving the elements of the posterior neural ring in individuals who are asymptomatic, neurologically normal, and have a full, pain-free range of cervical motion.

An absolute contraindication to further participation in contact activities exists in the presence of the following fractures: (1) vertebral body fracture with a sagittal component; (2) fracture of the vertebral body with or without displacement with associated posterior arch fractures and/or ligamentous laxity; (3) comminuted fractures of the vertebral body with displacement into the spinal canal; (4) any healed fracture of the vertebral body or posterior components with associated pain, neurological findings, and limitation of normal cervical; and (5) healed displaced fractures involving the lateral masses with resulting facet incongruity.^{12,18}

INTERVERTEBRAL DISK INJURIES

Acute herniation of a cervical intervertebral disk, associated with neurologic findings and occurring as an isolated entity, is rare in the athlete. In one study, 75 first-year football recruits had roentgenograms of their cervical spines after playing football in high school but before playing in college; of them, 32% had 1 or more of the following: occult fracture, vertebral body compression fracture, intervertebral disk space narrowing, or other degenerative changes.¹ Of this group, only 13% admitted to a positive history of neck symptoms. The development of early degenerative changes or intervertebral disk space narrowing in this group was attributed to the effect of repetitive loading on

the cervical spine as a result of head impact from blocking and tackling.

Acute and chronic cervical intervertebral disk injury without frank herniation or neurologic findings occurs with considerable frequency in the athlete. Neck pain and limited cervical spine motion are associated with a history of injury. Roentgenograms may demonstrate disk space narrowing and marginal osteophytes. MRI frequently demonstrates disk bulge without herniation. In general, management is conservative: permission to engage in activity is withheld until the youngster (1) is asymptomatic and neurologically negative and (2) has full strength and a full range of cervical motion. There is no contraindication to participation in contact activities for (1) an athlete with a healed anterior or lateral disk herniation treated conservatively or (2) an athlete requiring an intervertebral discectomy and interbody fusion for a lateral or central herniation who has a solid fusion, is asymptomatic and neurologically negative, and has a full, pain-free range of cervical motion.

A relative contraindication exists for those with conservatively or surgically treated disk disease with residual facet instability.

An absolute contraindication exists in the following situations: (1) acute central disk and (2) acute or chronic disk herniation with associated neurological findings, pain, and/or significant limitation of cervical motion (Table 5).

STATUS POSTCERVICAL SPINE FUSION

A stable 1-level anterior or posterior fusion in a patient who is asymptomatic, neurologically normal, and pain-free and has a normal range of cervical motion presents no contraindication. A stable 2- or 3-level fusion patient who is asymptomatic, neurologically normal, and pain-free and who has full range of cervical motion presents a relative contraindication, whereas a 4-level (or more) anterior or posterior fusion presents an absolute contraindication (Table 6).

Table 6. Status following cervical spine fusion: contraindication to return to athletic activity.

Status	Contraindication		
	None	Relative	Absolute
Stable single-level anterior or posterior fusion in patients who are asymptomatic, have no evidence of neurologic injury, and have full, pain-free range of cervical motion	×		
Stable 2- or 3-level fusion in patients who are asymptomatic, have no evidence of neurologic injury, and have full, pain-free range of cervical motion		×	
Anterior or posterior fusion of 4 or more levels. Because of the increased stresses at the articulations of the adjacent vertebrae and the propensity for the development of degenerative changes at these levels, these patients (with only rare exceptions) should not be permitted to return to athletic activity.			×
Any fusion for instability of C1 regardless of roentgenographic evidence of successful fusion			×

NATA Members: Receive 3 free CEUs each year when you subscribe to *Sports Health* and take and pass the related online quizzes! Not a subscriber? Not a member? The Sports Health–related quizzes are also available for purchase. For more information and to take the quiz for this article, visit www.nata.org/sportshealthquizzes.

REFERENCES

- Albright JP, Moses JM, Feldich HG, et al. Non-fatal cervical spine injuries in interscholastic football. *JAMA*. 1976;236:1243-1245.
- Bergfeld JA. Brachial plexus injury in sports. *Orthop Clin North Am*. 1988;12:743-744.
- Boden BP, Tacchetti RL, Cantu RC, et al. Catastrophic cervical spine injuries in high school and college football players. *Am J Sports Med*. 2006;34:1223-1239.
- Brigham CD, Adamson TE. Permanent partial cervical spinal cord injury in a professional football player who had only congenital stenosis. *J Bone Joint Surg Am*. 2003;85:1553-1556.
- Clancy WG. Brachial plexus and upper extremity peripheral nerve injuries. In: Torg JS, ed. *Athletic Injuries to the Head, Neck, and Face*. Philadelphia, PA: Lea & Febiger; 1982:215-220.
- Clancy WG, Brand RL, Bergfeld JA. Upper trunk brachial plexus injuries in contact sports. *Am J Sports Med*. 1977;5:209-214.
- Herzog RJ, Wiens JJ, Dillingham MF, Sontag MJ. Normal cervical spine morphometry and cervical spinal stenosis asymptomatic professional football players. *Spine*. 1991;16:S178-S186.
- Levitz CL, Reilly PJ, Torg JS. The pathomechanics of recurrent cervical nerve root neurapraxia: the chronic burner syndrome. *Am J Sports Med*. 1997;25:73-76.
- Pavlov H, Torg JS, Robie B, Jahre C. Cervical spinal stenosis: determination with vertebral body ratio method. *Radiology*. 1987;164:771-775.
- Pizzutillo PD. Klippel-Feil syndrome. In: Cervical Spine Research Society Editorial Committee, ed. *The Cervical Spine*. 2nd ed. Philadelphia, PA: JB Lippincott; 1987:258-271.
- Torg JS, Corcoran TA, Thibault LE, et al. Cervical cord neurapraxia: classification, pathomechanics, morbidity, and management guidelines. *J Neurosurg*. 1997;87:843-850.
- Torg JS, Glasgow SG. Criteria for return to contact activities after cervical spine injury. In: Torg JS, ed. *Athletic Injuries to the Head, Neck and Face*. 2nd ed. St. Louis, MO: Mosby; 1991.
- Torg JS, Guille JT, Jaffe S. Current concepts review: injuries to the cervical spine in American football players. *J Bone Joint Surg Am*. 2002;84:112-122.
- Torg JS, Naranja RJ, Palov H, et al. The relationship of developmental narrowing of the cervical spinal canal to football injuries resulting in reversible and irreversible cord injury: an epidemiologic study. *J Bone Joint Surg Am*. 1996;78:1308-1314.
- Torg JS, Pavlov H, Gennario SE, et al. Neurapraxia of the cervical spinal cord with transient quadriplegia. *J Bone Joint Surg Am*. 1986;68:1354-1370.
- Torg JS, Reilly PJ. Injuries to the cervical nerve roots and brachial plexus in athletes. *Curr Opin Orthop*. 1994;5:79-84.
- Torg JS, Sennett BS, Pavlov H, et al. Spear tackler's spine. *Am J Sports Med*. 1993;21:640-649.
- Torg JS, Sennett B, Vegso JJ, Pavlov H. Axial loading injuries to the middle cervical spine segment: an analysis and classification of twenty-five cases. *Am J Sports Med*. 1991;19:6-20.
- Torg JS, Thibault L, Sennett B, et al. The pathomechanics and pathophysiology of reversible, incompletely reversible and irreversible cervical spine cord injury. *Clin Orthop*. 1995;321:259-269.
- Torg JS, Vegso JJ, O'Neill J, Sennett B. The epidemiologic, pathologic, biomechanical and cinematographic analysis of football-induced cervical spine trauma. *Am J Sports Med*. 1990;18:50-57.

For reprints and permissions queries, please visit SAGE's Web site at <http://www.sagepub.com/journalsPermissions.nav>.