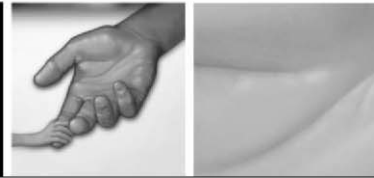



Since January 2020 Elsevier has created a COVID-19 resource centre with free information in English and Mandarin on the novel coronavirus COVID-19. The COVID-19 resource centre is hosted on Elsevier Connect, the company's public news and information website.

Elsevier hereby grants permission to make all its COVID-19-related research that is available on the COVID-19 resource centre - including this research content - immediately available in PubMed Central and other publicly funded repositories, such as the WHO COVID database with rights for unrestricted research re-use and analyses in any form or by any means with acknowledgement of the original source. These permissions are granted for free by Elsevier for as long as the COVID-19 resource centre remains active.

# Chapter 52



## Otolaryngologic Disorders

William P. Potsic and Ralph F. Wetmore

### EAR

#### Anatomy

The ear is divided into three anatomic and functional areas: the external ear, the middle ear, and the inner ear. The external ear consists of the auricle, external auditory canal, and the lateral surface of the tympanic membrane. The auricle is a complex fibroelastic skeleton that is covered by skin and subcutaneous tissue that directs sound into the external ear canal.

The external auditory canal is oval with the long axis in the superior to inferior direction. In neonates, the external canal is almost entirely supported by soft, collapsible cartilage. As the temporal bone grows over several years, the bony portion of the canal enlarges to comprise the inner one third, leaving the outer two thirds supported by firm cartilage. Hair and cerumen glands are present in the outer two thirds of the external canal. The ear canal is lined by skin that is continuous with the lateral surface of the tympanic membrane, and it is innervated by cranial nerves V, VII, and X and cervical nerve III.

The tympanic membrane separates the external ear canal from the middle ear. It has three layers: an outer layer of skin; a middle layer of fibrous tissue that is attached to the malleus, the most lateral middle ear ossicle; and an inner layer of mucosa that is continuous with the mucosa lining the middle ear. The fibrous layer is also attached to a thick fibrous annulus that anchors it to the temporal bone.

The middle ear is an air-filled space within the temporal bone of the skull that is lined by ciliated, columnar respiratory epithelium. The middle ear communicates with the mastoid air cell system posteriorly and is lined by the same mucosa. It also communicates with the nasopharynx anteriorly through the eustachian tube. The mucociliary transport system of the middle ear moves mucus and debris into the nasopharynx, where it is swallowed. Secretory cells are not evenly distributed throughout the middle ear and mastoid complex and are more numerous anteriorly near the eustachian tube.

Three ossicles are present in the middle ear—the malleus, incus, and stapes—that transmit sound from the

vibrating tympanic membrane to the stapes footplate. Stapes movement creates a fluid wave in the inner ear that travels to the round window membrane and is dissipated by reciprocal motion to the stapes.

There are two striated muscles in the middle ear. The tensor tympani muscle lies along the side of the eustachian tube, and its tendon attaches to the medial surface of the malleus. The stapedius muscle lies along the vertical portion of the facial nerve in the posterosuperior part of the middle ear. Its tendon attaches to the head of the stapes. These muscles stiffen the ossicular chain in the presence of sustained loud noise.

The facial nerve traverses the middle ear with its horizontal portion lying superior to the stapes. Posterior to the stapes, the facial nerve turns inferiorly in a vertical fashion to exit the stylomastoid foramen deep to the tip of the mastoid. The chorda tympani nerve is a branch of the facial nerve that innervates taste to the anterior two thirds of the tongue. It exits the facial nerve in the vertical segment and passes under the posterosuperior surface of the tympanic membrane, crossing the middle ear lateral to the long process of the incus and medial to the malleus. The facial nerve lies within a protective bony canal throughout its course in the middle ear. However, the bony canal may be absent (in the horizontal portion) in as many as 30% of patients. Cranial nerve IX supplies sensation to the floor of the middle ear.

The inner ear consists of the cochlea, semicircular canals, and vestibule. The cochlea is a coiled fluid-filled tube consisting of  $2\frac{3}{4}$  turns surrounded by dense bone. It contains the membranes that support the organ of Corti and has hair cells that detect the fluid wave from vibration of the stapes footplate. The hair cells create the neural impulses that are transmitted from the auditory nerve (cranial nerve VIII) to the brain, providing the sensation of hearing.

The three paired semicircular canals (horizontal, superior, and inferior) are also fluid-filled tubes surrounded by dense bone. The semicircular canals each have a hair cell-containing structure (the ampulla) that detects motion. The utricle and saccule of the vestibule also have hair cell structures that detect acceleration.<sup>26</sup>

## Embryology

The external ear develops during the sixth week of gestation and is completely developed by the 20th week. Six hillocks fuse to form the basic units of the pinna. Defects in the fusion of the hillocks lead to preauricular tags and sinuses. The external auditory canal develops from the first pharyngeal cleft. A solid epithelial plug forms during the beginning of the third month of gestation and canalizes in the seventh month to form the external auditory canal.

The middle ear canal develops from the first pharyngeal pouch. The ossicles develop from the first and second pharyngeal arches. The inner ear arises from neuroectodermal tissue within the otic placode that forms the otic pit.<sup>26</sup>

Any combination of anomalies may occur. Abnormalities of the development of the ear may create anomalies of the pinna, external auditory canal, middle ear structures, and inner ear. One of the anomalies that involves the external and middle ear is aural atresia (absence of the external auditory canal). Absence of the external canal may occur with a deformed or normal external ear. The ossicles may be deformed and are usually fused to each other as well as the bony plate representing the undeveloped tympanic membrane. The facial nerve may also be altered in its course through the temporal bone. Reconstruction of the atretic canal, removal of the bony tympanic plate, release of the fused ossicles, and reconstruction of a new eardrum is a complex surgical procedure that may improve hearing. Rarely there is incomplete development of the inner ear structures. The most common of these is dysplasia of the cochlea, and it may vary in severity. Dysplasia causes sensorineural hearing loss.<sup>6,14</sup>

## Examination

The examination of the ear should always start with inspection of the outer ear and surrounding structures. Deformities of the outer ear structure may suggest the presence of other anomalies, such as a first branchial cleft sinus. A first branchial cleft sinus usually presents below the ear lobe near the angle of the jaw. The sinus tract may connect to the ear canal or, rarely, the middle ear.

The external auditory canal and tympanic membrane are best examined with a hand-held otoscope with a bright fiberoptic light source. The largest speculum that comfortably fits in the external canal should be used to maximize visualization and minimize pain. A very small speculum may be inserted deeply, but it might lacerate the ear canal as well as limit visibility of the tympanic membrane. The otoscope permits visualization of the ear canal and tympanic membrane. A translucent tympanic membrane will also permit visualization of the contents of the middle ear.

Cerumen may be encountered in the ear canal that obstructs the view of the tympanic membrane. Removal of cerumen may be performed by using an operating otoscope head and an ear curet. However, the use of a headlight such as the Lumiview (Welch Allyn, Skaneateles, NY) or operating microscope permits the use of both hands and superior visualization. Care

should be taken to secure the child to prevent sudden movement, and the ear curet should be used gently to avoid causing pain and a laceration of the ear canal.

Examination of a child with an apparent or suspected ear condition often requires objective assessment of hearing by audiometry. Current technology and expertise makes it possible to test a child at any age.

Behavioral audiometry can usually be accurately performed for a child who is older than 6 months of age by sound-field testing. Older children are presented with a tone through insert earphones and a range of frequencies between 250 and 8000 Hz for ear-specific testing. The hearing thresholds are recorded at each presented frequency; and this represents the air conduction threshold. The sound has to traverse the ear canal, tympanic membrane, and middle ear. The inner ear must respond by creating electrical impulses that are transmitted to the brain. Normal thresholds are less than 20 dB for children.

Bone conduction thresholds test the sensorineural component of hearing. A bone oscillator is used to test a range of frequencies by vibrating the skull, which stimulates the inner ear, directly bypassing the external and middle ear. Normally, air conduction thresholds require less energy than bone conduction thresholds. If bone conduction thresholds require less sound intensity than air conduction to be heard, the child has a conductive hearing loss. If air conduction and bone conduction thresholds are elevated but the same, the child has a sensorineural hearing loss. Most sensorineural hearing loss in children is a result of hair cell dysfunction in the organ of Corti. Hearing loss may be conductive, sensorineural, or mixed. Electrophysical tests such as brainstem auditory evoked response and sound emission tests that measure the intrinsic sounds from the inner ear (otoacoustic emissions) may be employed in young infants and children who cannot participate in behavioral audiometry. A mechanical test of tympanic membrane compliance (tympanometry) may also be used for audiometric assessment. All of these tools are employed by pediatric audiologists.<sup>23</sup>

For purposes of describing hearing loss, a threshold between 20 and 40 dB is considered mild, 40 to 65 dB is moderate, 55 to 70 dB is moderately severe, 70 to 90 dB is severe, and greater than 90 dB is profound. Four of 1000 children are born with a hearing loss, and 1 of those children is born with a severe to profound hearing loss.

Conductive hearing loss may be corrected with otologic surgery. Hearing aids and FM systems may be helpful to children with both conductive and sensorineural hearing loss. Assistance may be needed through auditory training, speech language therapy, and education to maximally develop communication skills. When a child has a sensorineural hearing loss that is too severe to be helped with hearing aids, a cochlear implant may be considered.

A cochlear implant is an electrical device that is implanted under the scalp behind the ear. Its processor converts sound to electrical impulses. A cable travels through the mastoid and facial recess to reach the middle ear, and the electrode array is inserted into the scala tympani of the cochlea through an opening that is made in the cochlea.

Cochlear implants stimulate the neural elements of the cochlea directly and bypass the hair cells. Because the vast majority of sensorineural hearing loss in children is due to hair cell dysfunction, nearly all children get sound perception from a cochlear implant. Rare conditions such as an absent auditory nerve or an absent cochlea preclude the use of a cochlear implant.

A multidisciplinary evaluation by a cochlear implant team is required to evaluate a child and determine family expectations before performing a cochlear implant. A temporal bone computed tomographic (CT) scan and/or magnetic resonance imaging (MRI) is performed to assess the cochlea and auditory nerves.

Children who are born deaf and are younger than the age of 3 years, as well as children who have already developed communication skills, language, and speech before losing their hearing, derive the greatest benefit from cochlear implants. Cochlear implantation is approved for children 12 months of age or older by the U.S. Food and Drug Administration. After a cochlear implant is performed, considerable auditory oral training is required to maximize a child's benefit to develop skills of audition, speech, and language. A child who has been deaf and without sound perception for several years is expected to benefit to a lesser degree.<sup>33</sup>

### Otitis Media with Effusion and Inflammatory Disorders

Otitis media with effusion is the most common chronic condition of the ear during childhood. All children are born with small eustachian tubes that may at times be unable to clear mucus that is secreted in the mastoid and middle ear.

Fluid may develop in the middle ear during an upper respiratory infection. It usually clears within a few weeks as the upper respiratory tract infection resolves. Children with craniofacial anomalies such as cleft palate and Down syndrome are also prone to middle ear effusions; there is no medication that is consistently effective in resolving such effusions.

Persistent effusion may cause a conductive hearing loss in the range of 20 to 40 dB. A middle ear effusion may also function as a culture medium and predispose children to recurrent acute suppurative otitis media (ASOM).

When fluid persists in the middle ear for 3 to 4 months, causing a hearing loss or is associated with ASOM, myringotomy and tympanostomy tube placement is helpful to resolve the hearing loss and reduce the frequency and severity of infection.

Myringotomy and placement of a tube is performed under general anesthesia using an operating microscope. A small incision is made in any quadrant of the tympanic membrane except the posterosuperior quadrant, where there would be risk of injuring the ossicles. The mucus is suctioned from the ear, and a Silastic tube is placed in the myringotomy to provide prolonged ventilation of the middle ear. The tube will usually be extruded and the tympanostomy will heal in 6 months to 1 year. When the

ear is no longer ventilated by a tube, the eustachian tube must ventilate the middle ear. If fluid recurs and persists, a repeat procedure may be needed. Most children grow out of this problem as their eustachian tube grows. Occasionally, adenoid tissue in the nasopharynx may contribute to the persistence of middle ear effusion and may also be removed at the time that a tube is placed. Children who have had multiple sets of tubes are candidates for adenoidectomy.

### Acute Suppurative Otitis Media

Acute suppurative otitis media is the most common infection of childhood except for acute upper respiratory tract infections. It is the most common condition for which children seek medical care from their primary care physician. Usual pathogens causing ASOM include *Streptococcus pneumoniae*, *Haemophilus influenzae*, and *Moraxella catarrhalis*.<sup>25</sup>

Acute suppurative otitis media usually causes severe deep ear pain, fever, and a conductive hearing loss in the affected ear. The purulence in the middle ear is also present in the mastoid air cells because they are connected.

ASOM is treated with broad-spectrum oral antibiotics; however, there is growing concern that indiscriminate use of antibiotics may result in antibiotic resistance. For this reason, accurate diagnosis by otoscopy should be made before initiating a course of antibiotics.

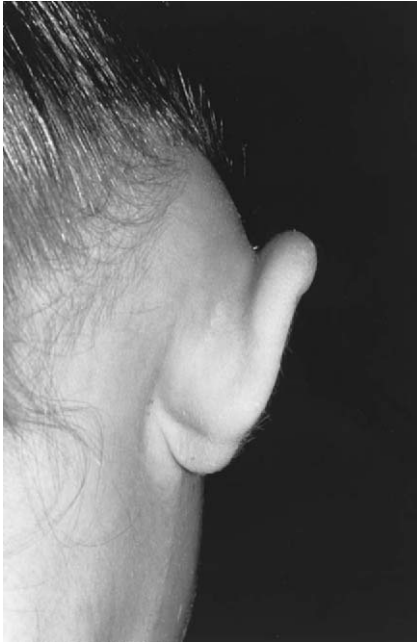Occasionally, ASOM does not respond as expected to standard antibiotic therapy. When this occurs, culture and sensitivity testing can be obtained by tympanocentesis. After sterilizing the ear canal with alcohol, a 22-gauge spinal needle can be placed through the posterior or anterior inferior quadrant of the tympanic membrane and fluid can be aspirated with a small syringe.

Complications of ASOM are uncommon if appropriate antibiotic therapy is used. The conductive hearing loss resolves as the middle ear effusion clears. However, infection may necrose the tympanic membrane, causing a spontaneous perforation. Small perforations usually heal in less than 7 days, but larger perforations may persist, cause a conductive hearing loss, and require a tympanoplasty for closure. The ossicular chain may also be disrupted by necrosis of the long process of the incus requiring ossicular reconstruction to restore hearing.

Acute coalescent mastoiditis occurs when infection erodes the bony mastoid cortex and destroys bony septa within the mastoid. A subperiosteal abscess may also be present. There is usually postauricular erythema and edema over the mastoid area. The auricle is displaced laterally and forward (Fig. 52-1). Otoscopy reveals forward displacement of the posterior superior skin of the ear canal.

In addition to antibiotics, treatment should include a wide field myringotomy from the anterior inferior quadrant to the posterior inferior quadrant, a tympanostomy tube placement for middle ear drainage, and a postauricular mastoidectomy to drain the subperiosteal abscess and the mastoid.

Facial nerve paralysis may occur from inflammation of that portion of the facial nerve that is exposed in the



**Figure 52-1** Acute mastoiditis. Extension of the acute inflammatory process from the middle ear and mastoid air cell systems to the overlying soft tissues displaces the auricle in an inferior and lateral direction from the side of the head. Fluctuance may be palpated over the mastoid cortex, and a defect in the cortical bone can frequently be appreciated. Surgical drainage with mastoidectomy is required.

middle ear during ASOM. Treatment with parenteral antibiotics, ototopical antibiotic drops applied in the ear canal, and a wide field myringotomy and tympanostomy tube placement almost always result in complete recovery of facial function. Facial nerve recovery may take a few weeks to several months.

Intracranial complications of ASOM may include meningitis, epidural abscess, brain abscess, otitic hydrocephalus, and lateral sinus thrombosis. Meningitis is the most common intracranial complication of ASOM and may be associated with profound sensorineural hearing loss and loss of vestibular function. Treatment of the intracranial complications of ASOM is focused on appropriate treatment of the intracranial process, in addition to a wide field myringotomy and tympanostomy tube placement in the affected ear.<sup>2</sup>

### Chronic Otitis Media

*Chronic otitis media* is a descriptive term that refers to a persistent perforation of the tympanic membrane or the presence of a cholesteatoma of the middle ear. A cholesteatoma is a squamous epithelial-lined cyst that may be congenital or acquired. Congenital cholesteatomas are caused by epithelial rests that persist in the middle ear during temporal bone development. They present behind an intact tympanic membrane and appear as a white, smooth mass in the middle ear. They expand over time and are filled with squamous debris and may erode the ossicular chain and extend into the mastoid.

Acquired cholesteatoma develops from skin entering the middle ear after a tympanic membrane perforation or a retraction pocket from eustachian tube dysfunction.

Cholesteatomas are usually painless, cause a conductive hearing loss, and, in acquired cases, often present as otorrhea. The otorrhea should be treated with ototopical antibiotic eardrops, but the only treatment of cholesteatomas is complete surgical excision by tympanomastoid surgery and ossicular reconstruction.<sup>27</sup>[pp 18-59] The potential complications of cholesteatomas are the same as those for ASOM.

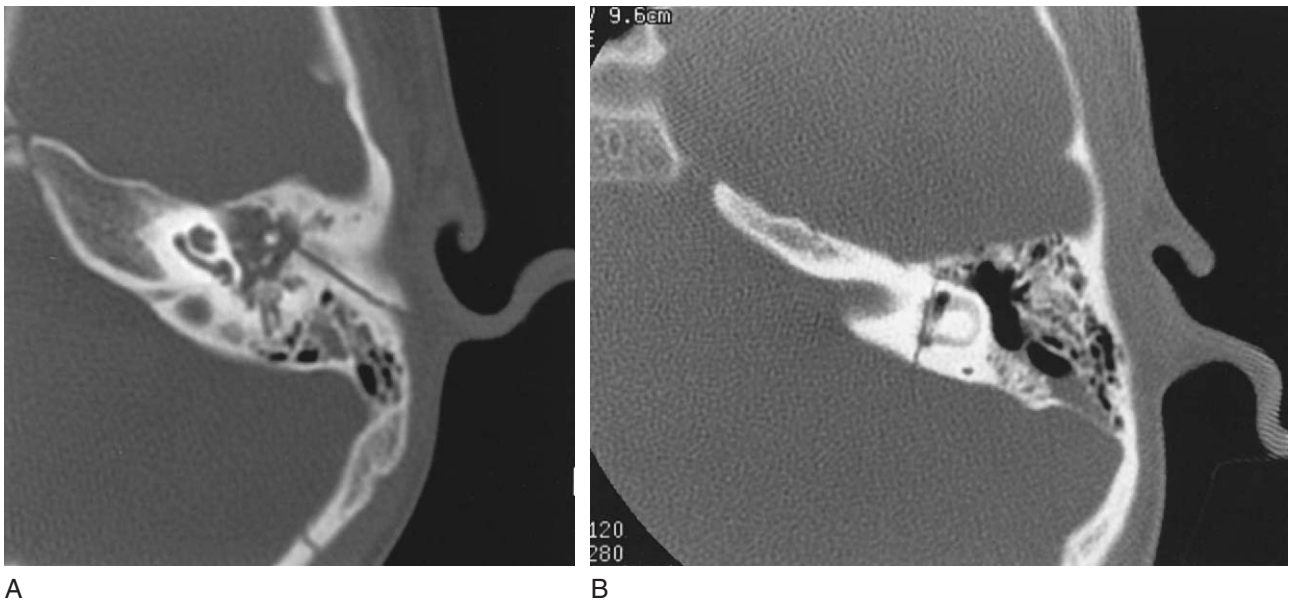
### Trauma

Objects stuck deeply into the ear canal such as a cotton-tipped applicator may perforate the tympanic membrane. This usually causes acute pain, bleeding, and a conductive hearing loss. If the ossicular chain is not disrupted, the vast majority of these perforations will heal spontaneously in about 2 weeks. If the tympanic membrane is perforated and the middle ear is contaminated with water, oral antibiotics should be given.

Lacerations of the auricle should be cleaned to prevent tattooing and repaired by careful approximation of the skin and soft tissue to restore the contours of the ear. The cartilage itself does not usually need to be sutured. Partially or totally avulsed tissue should be replaced. If necrosis of tissue occurs, it can be débrided as needed. In severe injuries of the auricle, oral antibiotic treatment is helpful to prevent chondritis and loss of the cartilage framework.

Blunt trauma to the ear is commonly seen in wrestlers, in children with poor neuromuscular tone, or in children with self-injurious behaviors. Blood or serum collects between the periosteum and the auricular cartilage. If the cartilage is fractured, the collection may occur on both sides of the ear. Evacuation of the collection is required to restore the contours of the ear, prevent infection, and prevent scarring with formation of a “cauliflower ear.” Aspiration of the fluid and placement of a mastoid dressing for compression may be tried but is most often unsuccessful. Incision and drainage provides for complete evacuation of the blood or serum. Cotton dental rolls placed in each side of the auricle and held in place with bolster mattress sutures is the most effective management. The dental rolls should be left in place for 7 to 10 days while the patient also continues with a course of oral antibiotics. No outer dressing is required.<sup>27</sup>[pp 106-109]

Blunt head trauma may disrupt the inner ear membranes causing sensorineural hearing loss and vertigo. No treatment is required, and the injury and symptoms may resolve spontaneously, but the sensorineural hearing loss may persist. Severe head trauma may cause fracture of the temporal bone of the skull. Temporal bone fractures can be classified as longitudinal, transverse, or mixed (Fig. 52-2) but are often complex and do not neatly fit into one category or another. A high-resolution, thin section CT scan of the temporal bone will define the extent of the fracture. The middle ear and mastoid are filled with blood when a fracture is present. The blood causes a conductive hearing loss that resolves when the ear clears.



**Figure 52-2** A, Longitudinal temporal bone fracture. These fractures run parallel to the petrous pyramid. The otic capsule is generally not affected by the fracture lines. Balance, hearing, and facial function are generally preserved. B, Transverse temporal bone fracture. These fractures generally extend through the cochlea and facial canal and result in deafness, vertigo, and facial nerve paralysis of immediate onset. Facial nerve exploration with repair should always be considered in these cases.

Otoscopic evaluation of a child with a temporal bone fracture may reveal a laceration of the ear canal and tympanic membrane. Blood is usually present in the ear canal, and the tympanic membrane appears to be dark blue because the middle ear is filled with blood. There is often ecchymosis of the mastoid area (Battle's sign).

It is important during evaluation of a skull and temporal bone fracture to note and record the function of the facial nerve if the patient is not unconscious. Facial nerve paralysis may be immediate or delayed in onset. Delayed facial nerve paralysis has a good prognosis for spontaneous recovery. Immediate facial paralysis may indicate disruption of the nerve or compression by bone fragments. Immediate facial nerve paralysis requires exploration and repair once the patient is stable and sufficiently recovered from any associated trauma. The facial nerve should be decompressed in the mastoid, middle ear, and middle cranial fossa. Bone chips impinging on the nerve should be removed, and the nerve should be sutured or grafted if needed. All patients with temporal bone fractures should have an audiogram once their condition has stabilized. If the fracture disarticulates the ossicles, a conductive hearing loss will persist after the blood has cleared from the middle ear and mastoid.

Fractures of the temporal bone may transverse the cochlea and vestibular apparatus. These fractures usually cause a severe sensorineural hearing loss and loss of vestibular function on the affected side. A concussive injury of the cochlea may also simultaneously be present in the opposite ear in severe head trauma.

Temporal bone fractures may permit leakage of cerebrospinal fluid (CSF) into the middle ear and mastoid. CSF may also drain through the lacerated tympanic

membrane, causing CSF otorrhea. These leaks usually stop spontaneously, but persistent CSF otorrhea may require a lumbar drain to reduce the pressure and permit healing. Rarely, tympanomastoid exploration is required to close the leak. Persistent CSF leaks in the ear are associated with meningitis.

## Tumors

Benign and malignant tumors of the ear are rare. Glomus tympanicum tumors and neuromas of the facial nerve may present in the middle ear. Also, eosinophilic granuloma and rhabdomyosarcoma may involve the structures of the temporal bone.<sup>5,13</sup>

## NOSE

### Anatomy

The nose can be divided into three anatomic sections. The bony vault is the immobile portion of the nose. It consists of the paired nasal bones, the frontal process of the maxillary bone, and the nasal process of the frontal bone. The cartilaginous vault is supported by the upper lateral cartilages and the cartilaginous nasal septum. The nasal lobule is supported by the lower lateral cartilages and the cartilaginous septum. The nasal septum is formed by the quadrilateral cartilage anteriorly. The posterior septum is composed of bone from the vomer, perpendicular plate of the ethmoid, nasal crest of the maxillary bone, and palatine bone.

Both the internal and external carotid artery systems supply blood to the nose. The roof and lateral wall of the internal nasal cavity are supplied by the anterior and posterior ethmoidal arteries, sphenopalatine artery, and greater palatine artery. The septum is supplied by the anterior and posterior ethmoidal arteries, palatine artery, and the superior labial artery. The convergence of these vessels in the anterior segment of the nose is referred to as Kiesselbach's plexus or Little's area. Venous drainage is accomplished mainly by the ophthalmic, anterior facial, and sphenopalatine veins.

The olfactory bulb is positioned high in the roof of the nasal cavity and is responsible for the sense of smell. Sensory information is transported by nerves that penetrate the cribriform plate and traverse cranial nerve I (the olfactory nerve) to the brain. Smell is also an important component of what is perceived as taste.

Bony projections, turbinates, form the lateral nasal wall and significantly increase the surface area of the nose, allowing for more efficient humidification and warming of the air to 36°C. Three turbinates are usually present (i.e., inferior, middle, and superior). A supreme turbinate, which is essentially a flap of mucosa, is occasionally present. The turbinates contribute to the turbulent airflow that creates approximately 50% of the total airflow resistance to the lungs.

Cleaning of air is accomplished through the nasal hairs (vibrissae) and the mucosal surface. Anteriorly, the nose is lined with stratified squamous epithelium, which changes to respiratory epithelium immediately anterior to the turbinates. Trapped debris is transported in a posterior direction into the nasopharynx by a mucociliary transport mechanism.

Speech is affected by nasal anatomy and pathologic conditions. Hyponasality from nasal obstruction or hypernasality from an excessive air leak can affect voice quality and intelligibility of speech.

## Embryology

The nose serves as a drainage port for the paranasal sinuses. The meati are spaces between the lateral aspect of the nasal turbinates and the medial aspects of the lateral nasal wall. Each meatus is named for the turbinate that surrounds it. The maxillary, frontal, and anterior ethmoidal sinuses drain into the middle meatus. The posterior ethmoidal sinuses drain into the superior meatus. The sphenoidal sinus drains into an area known as the sphenothmoidal recess that is located posterior and superior to the superior turbinate. The nasolacrimal duct drains into the inferior meatus.

The nasal cavities develop from the nasal pits in the 4-week embryo. These pits deepen and move medially to form the nasal cavity. The oronasal membrane that separates the nose from the mouth resolves in the seventh week to permit communication between the nose and nasopharynx.

The paranasal sinuses develop from an outpouching of the lateral nasal walls during the third and fourth months of development. The maxillary and ethmoidal sinuses are present at birth. The frontal and sphenoidal sinuses begin to develop several years after birth. The frontal

sinus begins to develop at 7 years of age but is not fully aerated until adulthood.<sup>1</sup>

## Inflammatory Conditions

Viral rhinosinusitis (the common cold) accounts for the majority of nose and sinus infections. It is caused by many strains of viruses and is a self-limited infection. Symptoms of fever, nasal congestion, headache, and clear rhinorrhea usually resolve over 5 to 7 days. Treatment is symptomatic.

## Bacterial Rhinosinusitis

Acute bacterial rhinosinusitis may often follow an acute viral upper respiratory tract infection. The most common bacteria causing rhinosinusitis are *Streptococcus pneumoniae*, *Haemophilus influenzae*, and *Moraxella catarrhalis*. Acute rhinosinusitis causes malaise, headache, and nasal congestion. There may also be pain localized to the sinus region or pain on palpation over the maxillary or frontal sinuses. Chronic sinus infection may persist after the acute phase and symptoms often last longer than 30 days.

The "gold standard" for diagnosing sinusitis is a CT of the sinuses, but a thorough history and nasal examination is usually sufficient to diagnose acute rhinosinusitis. The nasal cavity can be visualized by using a large speculum on an otoscopic head. The posterior nasal cavity can be visualized with either a straight rod endoscope or a flexible fiberoptic nasopharyngoscope.

The treatment of rhinosinusitis includes oral antibiotics, short-term use of topical nasal decongestants (e.g., oxymethazoline), and saline nasal sprays. Topical nasal corticosteroid sprays may be helpful for the treatment of chronic sinusitis.

Chronic sinusitis in a child may be exacerbated by gastroesophageal reflux disease, immunodeficiencies, mucociliary dysfunction, and, more commonly, upper respiratory allergy. These predisposing conditions should be managed while treating the sinus infection. If the signs and symptoms of chronic sinus infection persist, a sinus CT is required to evaluate the condition of the sinus mucosa and the drainage pathways. Endoscopic sinus surgery may be necessary to open the involved sinuses to provide drainage.

Chronic inflammation of the nasal and sinus mucosa may lead to nasal and sinus polyp formation that chronically obstructs the nose and sinuses. Antrochoanal polyps are large polyps that originate from the walls of the maxillary sinus and extend through the nasal cavity into the nasopharynx. Nasal polyps may be removed endoscopically, but a large antrochoanal polyp may require removal through an open maxillary sinus procedure. Nasal polyps in a child should always prompt an evaluation for cystic fibrosis.

## Complications of Sinusitis

The sinuses surround the orbit so a common complication of acute rhinosinusitis in children is orbital cellulitis

with erythema and edema of the eyelids. Chemosis (edema of the ocular conjunctiva) is usually absent. However, if a periorbital subperiosteal abscess forms adjacent to an infected sinus, there may be proptosis, chemosis, ophthalmoplegia, and loss of vision. Infection in the ethmoidal sinuses most commonly results in this complication. Subperiosteal periorbital abscess is demonstrated best by sinus CT. Initial treatment should include intravenous antibiotics. Endoscopic or external drainage may be required in some cases.

Intracranial complications of sinusitis include cerebritis, cavernous sinus thrombosis, as well as epidural, subdural, and brain abscess. Treatment of intracranial complications or impending intracranial complications requires surgical drainage of the involved sinus and concurrent treatment of the intracranial lesion by a neurosurgeon.<sup>30</sup>

### Fungal Sinusitis

Fungal sinusitis may occur in immunocompromised children, specifically severe diabetics, children undergoing chemotherapy, and bone marrow transplant recipients. The treatment of fungal sinusitis involves surgical drainage and intravenous antifungal agents.

However, a chronic form of fungal sinusitis is allergic fungal sinusitis. These patients usually have other signs of allergy, such as asthma. The treatment of this condition is corticosteroids and débridement of the involved sinuses. The diagnosis is made by sinus CT findings and the presence of eosinophils as well as fungi in the sinus secretions that are removed at the time of surgery.<sup>11</sup>

### Congenital Malformations

#### Pyriform Aperture Stenosis

Congenital stenosis of the anterior bony aperture causes partial nasal obstruction that may be severe enough to cause difficulty feeding, respiratory distress, and failure to thrive. Anterior rhinoscopy demonstrates a very constricted nasal opening bilaterally. CT of the nose shows marked narrowing of the pyriform aperture.

Neonates are obligate nasal breathers, and severe stenosis must be surgically corrected. Because the stenotic segment is very anterior and the remainder of the nasal cavity is normal, removal of the constricting bone with drills is done through a sublabial approach. The nasal openings are stented with 3.0-mm endotracheal tube stents that are sutured in place and removed after a few days.

#### Choanal Atresia

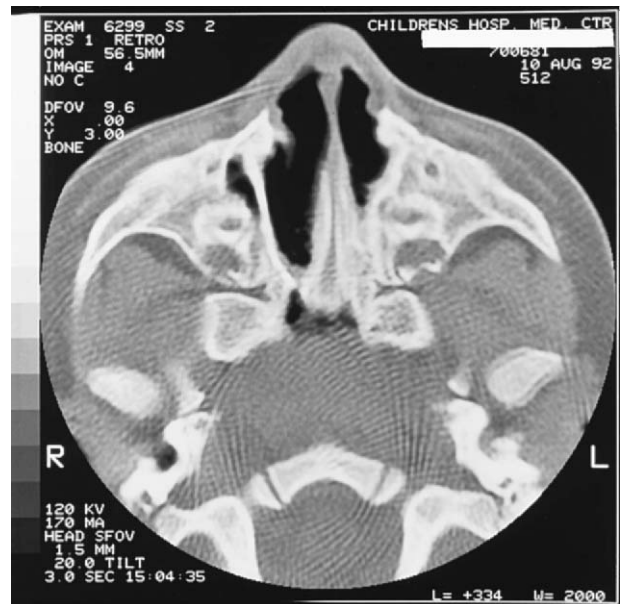Choanal atresia may be unilateral or bilateral. The obstructing tissue is usually a bony plate, but a few cases will have only membranous atresia. Unilateral choanal atresia presents as chronic unilateral rhinorrhea. There is no significant respiratory distress. Because neonates are obligate nose breathers, bilateral choanal atresia is associated with severe respiratory distress, difficulty feeding, and failure to thrive. The diagnosis is suspected if catheters cannot be passed through the nose and into the pharynx.

The obstruction may be visualized with a narrow flexible nasopharyngoscope after the nasal cavity has been suctioned of mucus and the nasal mucosa has been constricted with a nasal decongestant (e.g., oxymetazoline). The diagnosis is best made with CT of the nasal cavity. CT will demonstrate the atresia, define the tissue (bony or membranous), and show the configuration of the entire nasal cavity.

Choanal atresia may be successfully treated by removing the obstructing tissue transnasally. Curets, bone punches, and drills may all be effective to remove the atresia plate. However, when the bony plate is very thick and there is an extremely narrow posterior nasal cavity, a transpalatal repair is more direct. A transpalatal repair provides better access for more effective removal of the bony plate and posterior septum (Fig. 52-3). Stents fashioned from endotracheal tubes are placed and secured with sutures to the septum. They are removed in several weeks. The stents must be moistened with saline and suctioned several times daily to prevent mucus plugging and acute respiratory distress. Transpalatal repair of choanal atresia has a lower incidence of restenosis.<sup>27</sup>[pp 196-205]

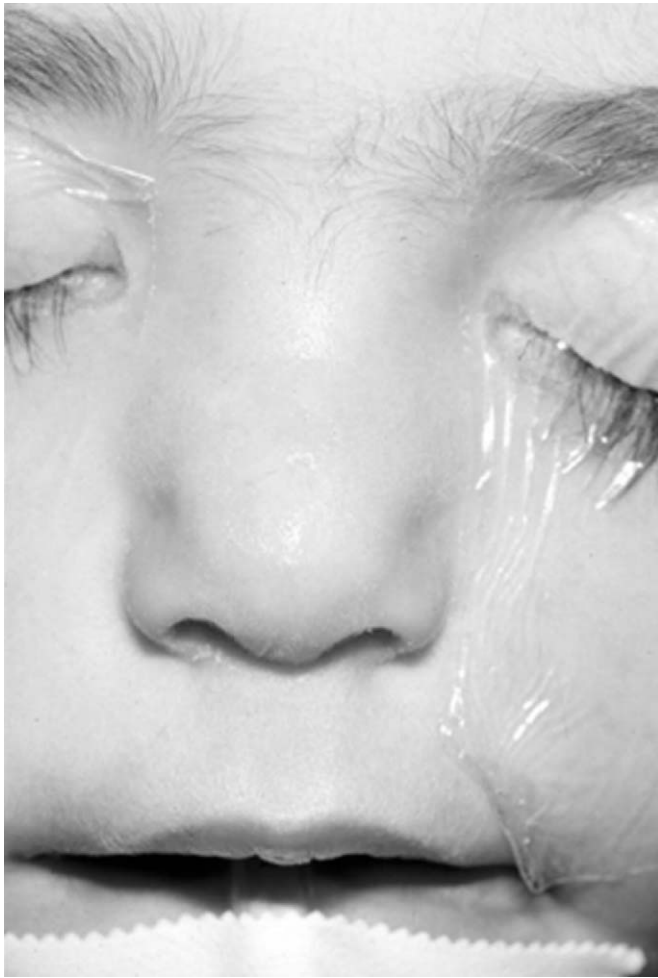#### Nasal Dermoid

Nasal dermoid cysts or sinuses present in the midline of the nasal dorsum (Fig. 52-4). They usually appear as a round bump or a pit with hair present in the pit (Fig. 52-5). They also may become infected. Nasal dermoid sinuses may extend through the nasal bones into the nasofrontal area and have an intracranial component. Both CT and MRI may be necessary to demonstrate the extent of the dermoid. Surgical removal is required to prevent infection and recurrence. This may be done between ages 3 and 5 years if prior infection has not occurred. Dermoids confined to the nose are resected completely using a midline incision with an ellipse around the sinus tract.

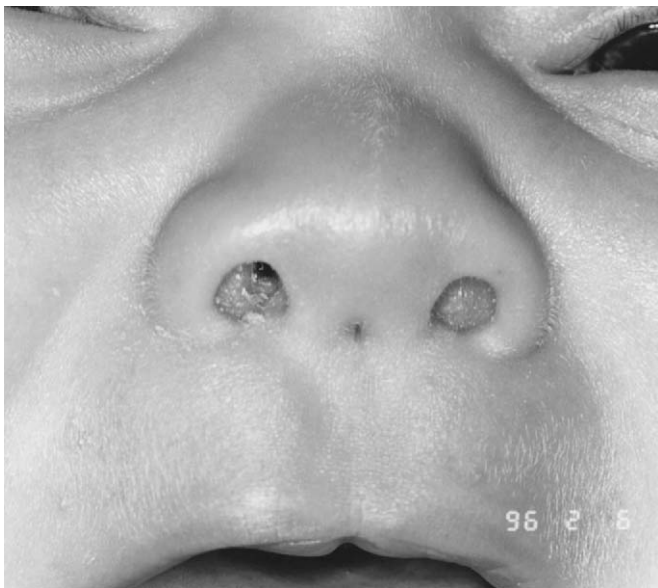

**Figure 52-3** Choanal atresia. This disorder frequently presents at birth with respiratory distress.





**Figure 52-4** Nasal dermoid presenting in the midline as a pit.



**Figure 52-5** Nasal dermoid. These lesions typically present on the nasal dorsum as a single midline pit, often with a hair extruding from the depths of the pit. The pits may also be found on the columella. The dermoid will then tract through the septum toward the cranial base.

The tract is followed to its termination, and the nasal bones may need to be separated to reach the end of the tract.<sup>27</sup>[pp 188-191] If an intracranial component is present, a combined craniotomy and nasal approach with a neurosurgeon is recommended.

### **Nasal Glioma and Encephalocele**

A nasal glioma presents as an intranasal mass and may be confused with a nasal polyp. The mass contains dysplastic brain tissue and may have an intracranial connection. CT and MRI are important to define the extent of the glioma and intracranial component as well as to plan the surgical approach.

An encephalocele presents as a soft compressible mass and may also be confused with a nasal polyp. Intranasal encephaloceles extend through a defect in the skull at the cribriform plate. CT and MRI define the extent of the encephalocele and are necessary to design the surgical approach. Surgical removal often includes a frontal craniotomy. Nasal encephaloceles may be associated with CSF rhinorrhea and meningitis.

## **Trauma**

### **Nasal Fracture**

An infant may be born with the soft nasal bones and the septum deviated to one side either as a result of a difficult delivery or from persistent intrauterine compression of the nose. The nasal structures can most often be returned to the midline with digital manipulation. If the nasal deformity is partially reduced, the nose usually straightens with growth during the first year to 18 months of age.

Nasal bone and nasal septal fractures in older children usually occur from a blow to the face during sports. There is usually a brief period of epistaxis and deviation of the nasal dorsum to one side. Swelling occurs rapidly, and the degree of the cosmetic deformity or the need for fracture reduction may not be easily determined. At the fourth to sixth day after injury, the edema subsides and the need for reduction can be determined. Nasal bone radiographs are of little help in making this judgment, so the need for nasal fracture reduction is usually based solely on clinical examination. Effective nasal fracture reduction may be done up to 2 weeks after the injury. Closed reduction under general anesthesia is the method of choice. Oral antibiotics prevent infection and are essential if nasal packing is used to support the nasal bone.

Although nasal fracture reduction is not urgent, a septal hematoma from a fractured septum should be excluded by the initial physician seeing the child. A septal hematoma that remains untreated may cause cartilage necrosis and loss of nasal support, with a resulting saddle-nose deformity. Treatment of a septal hematoma is with incision and evacuation of the clot. The mucoperichondral flap should then be sutured in place by bolster sutures through the septum. A small rubber band drain should remain in place for 12 to 24 hours, and antibiotics should be given.

Epistaxis in children usually occurs in Little's area of the anterior septum and frequently results from digital

trauma (nose picking). The bleeding usually stops with pressure by squeezing the nasal ala. Infrequently, cauterization of the vessels under general anesthesia is needed.

### **Nasal Foreign Bodies**

Children may be observed inserting a foreign body into their nose, or they may inform their parents of the event. Most children, however, present with a foul-smelling unilateral purulent nasal discharge and deny putting anything into their nose.

Most nasal foreign bodies are painless and do no harm to the nose except cause a foul nasal discharge. Disc batteries, on the other hand, cause very rapid alkali burns of the nasal cavity and pain. Batteries must be removed from the nose quickly because the chemical burn occurs in minutes to hours. If extensive tissue necrosis occurs, it may cause a nasal stenosis.

Removal of a nasal foreign body is aided by decongesting the nasal mucosa and using a headlamp to visualize the foreign body. A variety of forceps or hooks may be used. If the object is deep in the nose, the removal is best performed under general anesthesia. The endotracheal tube prevents aspiration of the object into the tracheobronchial tree if it is pushed back into the nasopharynx. One must remember that multiple foreign bodies may be present.

### **Nasal Lacerations**

Nasal lacerations should be closed with care to match edges and restore the contours of the nose. Standard wound closure technique is employed. The nasal mucosa does not need to be sutured unless a large flap is displaced.

### **Nasal Tumors**

Rhabdomyosarcoma, lymphoma, squamous cell carcinoma, and esthesioneuroblastoma may occur in the nose and sinuses of children. Fortunately, these malignant tumors are very rare in children. The treatment of children with malignant tumors of the nose and sinuses usually involves a multidisciplinary, multimodal approach.

Juvenile nasopharyngeal angiofibroma is a benign tumor of adolescent males that originates from the lateral wall of the nose and nasopharynx. The tumor may completely obstruct the nose and fill the nasopharynx. This type of angiofibroma may also extend intracranially through the base of the skull. Patients with these tumors present with nasal obstruction, recurrent epistaxis, and rhinorrhea.

The tumor may be seen with a flexible fiberoptic nasopharyngoscope or a rod lens telescope after decongesting the nasal mucosa. It appears as a smooth reddish mass. Biopsy of the mass should be avoided because of the potential for severe bleeding. CT and MRI define the extent and location of the tumor. MR angiography helps to delineate the blood supply, which may originate from both the internal and external carotid arteries. Contrast angiography may be reserved for presurgical planning and embolization of the copious blood supply that is often present.

The treatment of juvenile nasopharyngeal angiofibroma is complete surgical resection after preoperative embolization. Depending on the material used, the embolization may be effective for days to weeks. A variety of surgical approaches may be used, including endoscopic resection of small tumors. Extensive tumors may require a combined midfacial and craniotomy approach.<sup>29</sup>

Some authors have proposed radiation therapy as the primary treatment of juvenile nasopharyngeal angiofibroma, but many surgeons are concerned about the long-term effects of radiation in children, including the induction of malignant tumors.

## **ORAL CAVITY/PHARYNX**

### **Anatomy**

The boundaries of the oral cavity include the lips anteriorly, the cheeks laterally, and the palate superiorly. The posterior boundary is a plane that extends from the soft palate to the junction of the anterior two thirds and posterior one third of the tongue. The oral cavity is composed of the vestibule, the space between the lips and cheeks and alveolar ridges, and the oral cavity proper. The vestibule and oral cavity proper are separated by the alveolar ridge and teeth. The vestibule is divided in the midline by the labial frenula of the upper and lower lips. The alveolar ridge is contiguous superiorly with the hard palate. The parotid ducts (Stensen's ducts) enter the vestibule opposite the second maxillary molars. The submandibular ducts (Wharton's ducts) enter the floor of mouth near the lingual frenulum.

The palate is formed by a fusion of the primary palate anteriorly and medial growth of the palatal processes that form the secondary palate. The hard palate divides the nasal and oral cavities and is formed by the premaxilla and the horizontal plates of the palatine bones. The soft palate is formed by a muscular aponeurosis of the tensor veli palatini tendon. Five muscles insert into this aponeurosis and include the tensor veli palatini, levator veli palatini, palatoglossus, palatopharyngeus, and the musculus uvulae. Defects in formation of the hard and/or soft palate result in clefting. The sensory and motor innervation of the palate is through the trigeminal nerve and pharyngeal plexus.

The circumvallate papillae divide the tongue into the anterior two thirds that lies in the oral cavity and the posterior one third lying in the oropharynx. The innervation and vascular supply to the two major divisions of the tongue reflect their differences in origin—the anterior two thirds of the tongue being a first branchial arch derivative (trigeminal) whereas the posterior one third being a combination of third and fourth arch derivatives (pharyngeal plexus). The hypoglossal nerve supplies motor innervation to the intrinsic musculature. In addition to the intrinsic tongue musculature, the action of four extrinsic muscles combine to provide mobility. The genioglossus protrudes and depresses, the hyoglossus retracts and depresses, the styloglossus retracts, and the palatoglossus elevates. In addition to the circumvallate papilla, other taste buds on the tongue surface include conical, filiform, fungiform, and foliate papillae.

The pharynx is a fibromuscular tube that extends from the skull base to the level of the cricoid cartilage of the larynx and can be divided into three levels. The nasopharynx extends from the skull base to the level of the soft palate, the oropharynx extends from the soft palate to the tongue base, and the hypopharynx extends from the tongue base to the cricoid cartilage. Three muscular constrictors combine to form the muscular portion of the pharynx: superior, middle, and inferior constrictors. Passavant's ridge is a muscular segment of the superior constrictor that is involved in velopharyngeal closure. Lower fibers of the inferior constrictor help to form the upper esophageal sphincter. The motor and sensory innervation of the pharynx is from the glossopharyngeal and vagus nerves via the pharyngeal plexus.

A collection of lymphoid tissue within the pharynx forms Waldeyer's ring that includes the palatine tonsils, the adenoid (pharyngeal tonsil), and lymphoid follicles lining the lateral and posterior pharyngeal walls.

### Acute Pharyngotonsillitis

In addition to the acute onset of sore throat, viral pharyngitis typically presents with fever and malaise. Signs include erythema of the pharynx and cervical lymphadenopathy. Depending on the viral agent, associated symptoms of nasal obstruction and rhinorrhea may also be present. Rhinovirus, coronavirus, parainfluenza virus, respiratory syncytial virus, adenovirus, and influenza virus are agents responsible for viral pharyngitis.

Primary herpetic gingivostomatitis, caused by herpes simplex types 1 or 2, presents as fever, adenopathy, and vesicles and ulcers on the lips, tongue, buccal mucosa, soft palate, and pharyngeal mucosa. Herpangina and hand-foot-and-mouth disease are viral infections that involve the oropharynx. Epstein-Barr virus (EBV) infection (infectious mononucleosis) presents as acute pharyngotonsillitis, fever, generalized adenopathy, malaise, and splenomegaly. Although EBV infection is suspected by the appearance of 10% or more atypical lymphocytes on a complete blood cell count and the presence of a positive Monospot test, the definitive diagnosis is confirmed by elevated titers of EBV.

Group A  $\beta$ -hemolytic *Streptococcus* (GABHS, i.e., *S. pyogenes*) commonly infects the pharynx. In addition to sore throat, associated symptoms include fever, headache, and abdominal pain. Associated signs include pharyngeal erythema, halitosis, tonsillar exudates, and tender adenopathy. Diagnosis may be confirmed initially with a rapid streptococcal antigen test. Because rapid antigen testing is more sensitive than formal plating on blood agar, a negative test does not need confirmation, but positive rapid streptococcal tests should be confirmed with formal plating. Other bacterial pathogens that cause acute pharyngitis include *Haemophilus influenzae* and groups C and G  $\beta$ -hemolytic streptococci. Occasionally, concurrent infection with penicillin-resistant *Staphylococcus aureus* may interfere with treatment of a GABHS infection.<sup>28</sup> Although many cases of GABHS infections respond to treatment with penicillin V or amoxicillin, emerging resistance to oropharyngeal pathogens mandates treatment of

recalcitrant cases with an antibiotic having known effectiveness against  $\beta$ -lactamase-producing organisms. In cases in which a lack of compliance is suspected, intramuscular benzathine penicillin or ceftriaxone may be used.

Acute pharyngitis may also be associated with acute bacterial infections of the nose, nasopharynx, and sinuses. These infections may be caused by a variety of viral and bacterial pathogens; and in addition to sore throat, symptoms include fever, mucopurulent nasal drainage, nasal obstruction, and facial pain.

### Recurrent Pharyngotonsillitis

Recurrent infection of the pharynx may be either viral or bacterial. GABHS are the most worrisome bacterial organisms because recurrent infection may lead to complications such as scarlet fever, acute rheumatic fever, septic arthritis, and acute glomerulonephritis. In addition to a history of multiple positive cultures for *S. pyogenes*, elevated antistreptolysin-O (ASO) titers may identify patients with chronic infection who are at risk for developing complications. Some asymptomatic children may be chronic carriers of GABHS, and elevated ASO titers may not be a reliable indicator for distinguishing between an active infection and the carrier state.

Treatment of recurrent streptococcal infection or the child who is a carrier should include a trial course of an antibiotic shown to reduce carriage (e.g., clindamycin, vancomycin, or rifampin). Children with recurrent pharyngotonsillitis unresponsive to medical therapy or those who suffer a complication should be considered for surgical management. Whereas treatment of each child should be individualized, suggested guidelines for surgical candidates include seven infections in 1 year, five or more infections per year for 2 years, or three or more infections per year for 3 years.<sup>24</sup> Other factors to be considered in employing a surgical option include severity of infection, response to antibiotic therapy, loss of time from school, and need for hospitalization.

### Chronic Pharyngotonsillitis

The pharynx and specifically the tonsils may be the target of chronic infection. Affected children complain of chronic throat pain, halitosis, and production of white particles or tonsilliths. Signs include erythema of the tonsils, cryptic debris, and chronically enlarged cervical adenopathy. A variety of viral and bacterial agents can be blamed for chronic infection of the pharynx. Cultures may or may not be positive in these patients, because surface cultures may be negative while core tissue is positive. Antibiotic therapy directed at anaerobes or *S. aureus* may be helpful in resistant cases. Children with infections unresponsive to medical management are candidates for tonsillectomy.

### Peritonsillar Cellulitis/Abscess

Localized extension of tonsillar infection may result in peritonsillar cellulitis. The same pathogens that cause

acute pharyngotonsillitis are responsible for peritonsillar cellulitis. In addition to severe sore throat, symptoms and signs include drooling, trismus, muffled voice, ipsilateral referred otalgia, and tender lymphadenopathy. The affected tonsil is usually displaced in a medial and inferior position. Peritonsillar cellulitis may progress to frank abscess formation (quinsy).

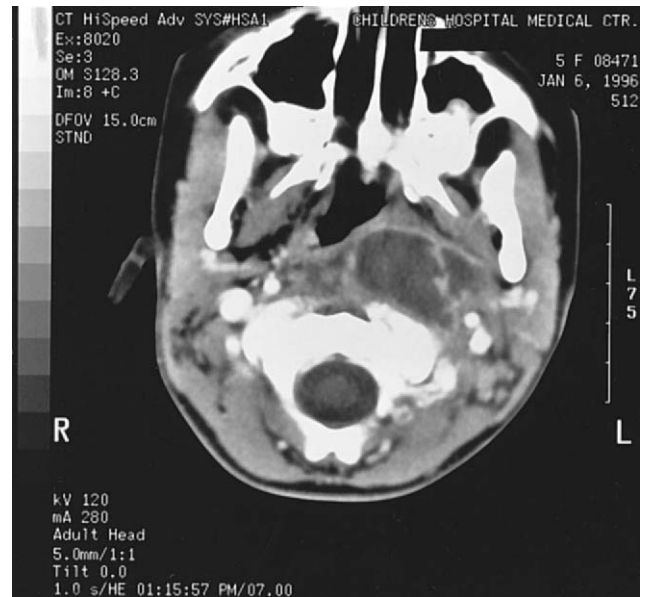
Early cases of peritonsillar cellulitis may respond to oral antibiotics, such as the penicillins, cephalosporins, erythromycins, or clindamycin. Unresponsive cases of cellulitis or abscess should be treated with intravenous antibiotics. In children with suspected abscess formation, a variety of surgical drainage procedures can be performed. Needle aspiration or incision and drainage have been shown to be equally effective.<sup>15</sup> In persistent cases or in those children who will require general anesthesia for drainage, consideration should be given to performing a tonsillectomy (quinsy tonsillectomy).

### Retropharyngeal/Parapharyngeal Space Infections

Signs and symptoms of deep neck space (retropharyngeal/parapharyngeal) infections that involve the pharynx typically present as fever, drooling, irritability, decreased oral intake, torticollis, and/or trismus. Often there is a history of a preceding viral illness. Stridor or symptoms of upper airway obstruction may be seen in half of patients.<sup>32</sup> A neck mass or enlarged cervical nodes may be present depending on the location of the infection. Usual pathogens include coagulase-positive staphylococci and GABHS. Anaerobic bacteria have been found in as many as 50% of cases.<sup>32</sup> Complications of deep neck space infections include airway obstruction, bacteremia, rupture of the abscess into the pharynx with aspiration, mediastinal extension of infection, jugular thrombosis, and carotid artery rupture.

In suspected cases, the diagnosis of a retropharyngeal/parapharyngeal space infection is confirmed with either contrast medium–enhanced CT or MRI. Widening of the retropharynx on a lateral neck radiograph suggests a retropharyngeal infection. While ultrasound can detect the presence of an abscess cavity, CT or MRI are most helpful in demonstrating the extent of infection and the location of surrounding structures of importance, specifically the great vessels. Contrast medium–enhanced CT is particularly useful in distinguishing a phlegmon (cellulitis) from cases of frank suppuration. Demonstration of a hypodense region with surrounding rim enhancement has been shown to correlate with an abscess in 92% of cases (Fig. 52-6).

The initial management of a deep neck infection should begin with intravenous antibiotics, including oxacillin, clindamycin, cefazolin,  $\beta$ -lactamase penicillins, or a combination thereof. Surgical drainage should be reserved for those children who fail to show clinical improvement or progress to frank abscess formation on CT. The usual approach to surgical drainage is intraoral if the abscess points medial to the great vessels or extraoral if the infection points lateral to the great vessels.



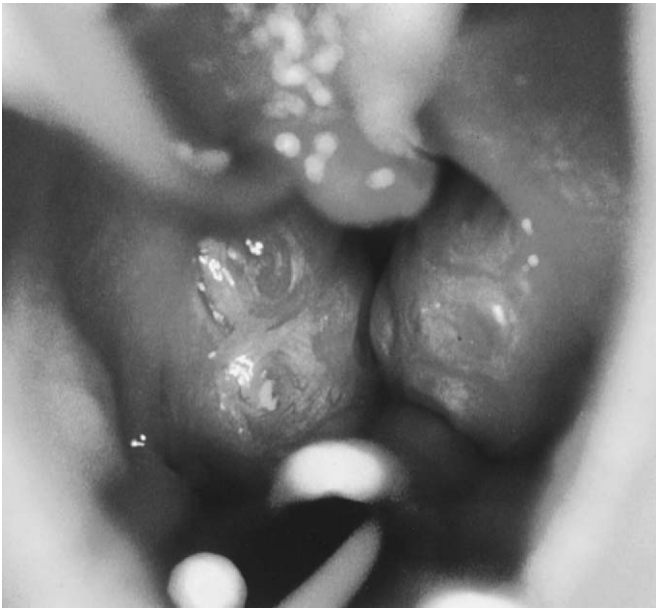**Figure 52-6** Retropharyngeal abscess. Computed tomography of the cervical area demonstrates fluid loculated in the retropharyngeal space. The abscess is typically unilateral and frequently extends into the medial aspect of the parapharyngeal space. In the absence of associated complications, drainage can be done intraorally.

Complications of deep neck infections should be treated aggressively. Mediastinal spread requires prompt surgical drainage in most cases. An infected jugular thrombosis (Lemierre's syndrome) can be a source of metastatic spread of infection as septic emboli. Signs and symptoms include spiking chills and fever (picket-fence fevers) and a neck mass in spite of appropriate antibiotic therapy. Ligature or excision of the infected thrombus may be required to eradicate the infection.

### Sleep-Disordered Breathing

In the past decade, the impact of sleep-disordered breathing (SDB) on the health of children has been well described, beginning with the report of normative sleep data by Marcus and colleagues.<sup>20</sup> Children appear to have briefer but more frequent episodes of partial (hypopnea) and complete (apnea) obstruction. Because an apnea of less than 10 seconds may represent several missed breaths in a child, an apnea of any duration is abnormal. In most cases the site of obstruction during sleep is in the pharynx. In contrast to adults with this disorder in whom the pharyngeal impingement is due to adipose tissue surrounding the pharyngeal musculature, the major cause of airway obstruction in children results from adenotonsillar hypertrophy.

The apnea index represents the number of apneas in an hour, with a normal value being less than 1 in children. Because most children have an increased frequency of partial obstructions compared with adults, a measure of hypopneas may be more significant. A hypopnea is variably described as a reduction in airflow or respiratory

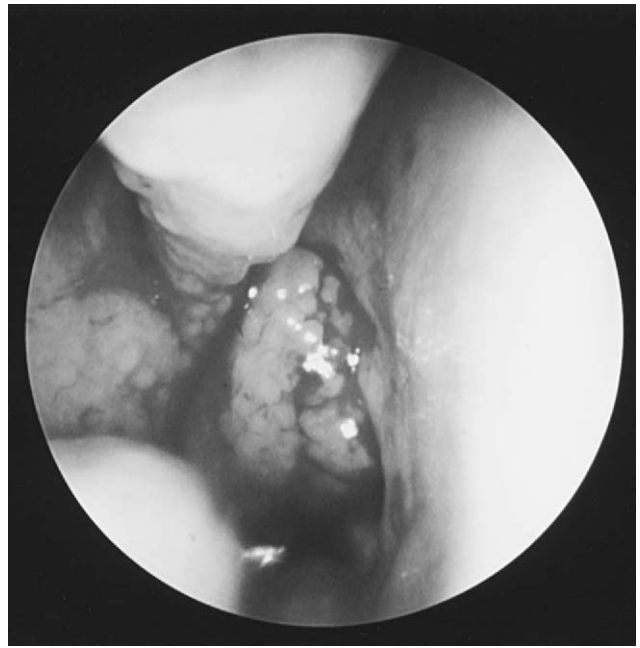

**Figure 52-7** Tonsillar hypertrophy. Tonsillar hypertrophy is rated on a scale of 1 to 4. Grade 1+ tonsils are hypertrophic, grade 2+ tonsils extend slightly beyond the tonsillar pillars, grade 3+ tonsils extend in a medial direction beyond the anterior tonsillar pillars, and grade 4+ tonsils touch in the midline.

effort or oxygen desaturation or combination thereof. Respiratory disturbance index is a measure of both apneas and hypopneas in an hour and may be a better reflection of SDB in children. A respiratory disturbance index greater than 5 is abnormal. Upper airway resistance syndrome represents obstructed breathing with normal respiratory indices but with sleep fragmentation and electroencephalographic arousals that indicate disordered sleep.

The major group at risk for SDB includes children with adenotonsillar hypertrophy secondary to lymphoid hyperplasia (Figs. 52-7 and 52-8). Whereas the age of affected children ranges from 2 years through adolescence, the prevalence mirrors the age of greatest lymphoid hyperplasia, 2 to 6 years, the age the tonsils and adenoids are largest in size. Other at-risk groups include syndromic children with Down syndrome, children with craniofacial disorders, and patients with cleft palate or storage diseases (Hunter's, Hurler's syndromes). Adverse effects of obstructive sleep apnea on children include poor school performance, failure to thrive, facial and dental maldevelopment, and, rarely, severe cardiac impairment, including systemic hypertension, cardiac arrhythmias, and cor pulmonale.

Daytime symptoms include noisy mouth-breathing, nasal obstruction and congestion, hyponasal speech, and dyspnea on exertion. In contrast to adults, hypersomnolence is uncommon in children because of the lower incidence of gas exchange abnormalities, specifically hypercarbia. Children may complain of headaches, seem irritable, and perform poorly in school. Nighttime symptoms are more obvious and include snoring, gasping and choking respirations, apnea, coughing, and a variety of



**Figure 52-8** Adenoid hypertrophy. Hypertrophy of the adenoids may cause the nasopharynx to be obstructed with tissue. Smaller amounts of tissue are also able to obstruct nasal respiration by growing into the posterior choana as shown in this photograph.

other behaviors including sleepwalking, sleepwalking, rocking, head banging, and bruxism. Enuresis may appear in children with airway obstruction and then resolve after surgical treatment. In addition to enlarged tonsils, signs include the presence of a posterior pharyngeal flap in cleft palate patients, a craniofacial disorder, adenoid facies, and, rarely, evidence of right-sided heart failure.

The diagnosis of SDB is suggested by history and physical examination. Confirmation of obstruction and apnea may be made with overnight pulse oximetry and video or audio monitoring of sleep. The "gold standard" in the diagnosis of obstructive sleep apnea remains formal polysomnography, including measures of nasal and oral airflow, chest wall movements, electrocardiography, extraocular muscle movements, and gastric pH monitoring in selected cases. Depending on the suspected site of obstruction, adjuvant studies such as a lateral neck radiograph, MRI of the head and neck, and flexible upper airway endoscopy might be helpful.

The nonsurgical management of SDB consists of weight loss in obese patients and treatment of underlying allergies and gastroesophageal reflux. Nasal and dental appliances to maintain airway patency that may be useful in adults are usually poorly tolerated in children. Nasal continuous positive airway pressure, the mainstay of treatment in adults, is tolerated in many children and should be considered as a treatment option, especially in patients in whom other therapies have been exhausted or proven ineffective.

The initial surgical treatment for most children with SDB remains a tonsillectomy and adenoidectomy, a therapy that is usually curative. In patients with documented sleep apnea or a sleep disorder, both procedures should

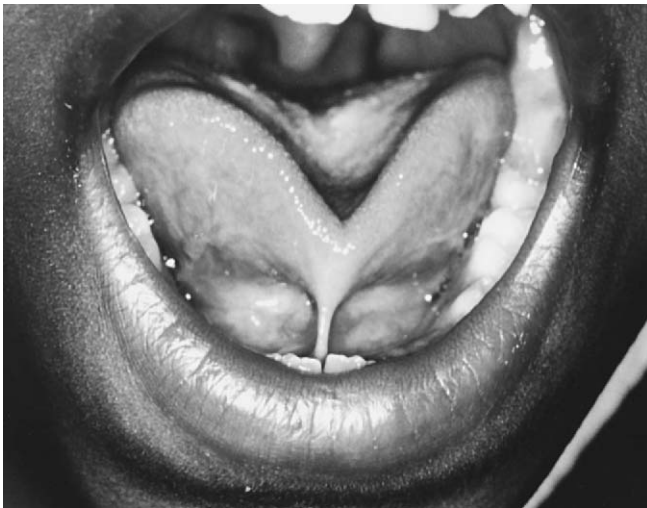be utilized even if the tonsils appear small. Tonsillectomy and adenoidectomy techniques that have been standard for decades have been supplanted in some institutions by new technology including use of Coblation, Harmonic Scalpel, and the microdebrider. Efficacy of these newer techniques over established methods remains unproven.

Complications after tonsillectomy and adenoidectomy usually consist of respiratory compromise and acute or delayed bleeding. Since the advent of modern pediatric anesthesia, respiratory complications such as aspiration with resultant pneumonia and lung abscess are rare. Humidification, corticosteroids, and antibiotics have all been shown to improve the postoperative course after tonsil and adenoid surgery. Young children are most vulnerable to complications, and in most institutions children younger than 4 years of age are observed overnight for signs of dehydration and respiratory compromise.

Adjuvant surgery in the management of SDB includes craniofacial repair or posterior flap revision surgery in appropriate patients. Midface, mandibular, and hyoid advancement have proved useful in selected patients, along with nasal surgery such as septoplasty, partial inferior turbinectomy, or nasal polypectomy. Tracheostomy remains the treatment of last resort in patients who fail to respond to other forms of therapy.

### Ankyloglossia

Ankyloglossia or tongue-tie is a common congenital disorder involving the lingual frenulum (Fig. 52-9). Neonates with diminished tongue mobility due to a foreshortened frenulum may have problems in sucking and feeding. Because the frenulum is thin and relatively avascular in neonates and young infants, it can often be incised as an office procedure. In older children the greatest effect of ankyloglossia is on speech. Because the tip of the tongue curls under on extrusion and has limited



**Figure 52-9** Ankyloglossia. Abnormal development of the lingual frenulum that limits extension of the tongue tip beyond the mandibular incisors frequently causes articulation disorders and should be corrected.

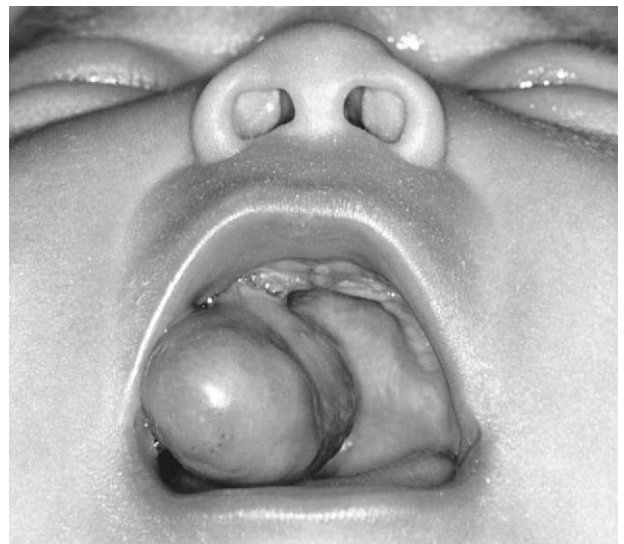
lateral and superior movement, speech articulation may be affected. Surgical treatment in these patients may require a short general anesthetic as the frenulum is thicker and more vascular, requiring surgical correction that includes either simple division with or without a Z-plasty repair.

### Macroglossia

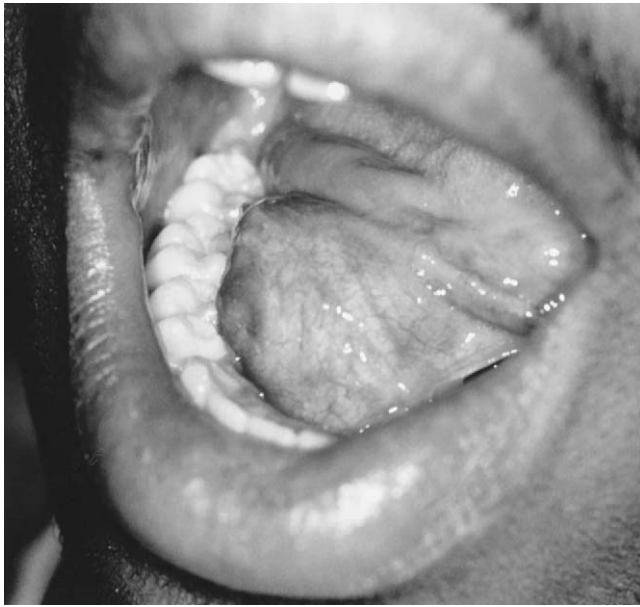Macroglossia is uncommon. Generalized macroglossia, as seen in association with omphalocele, visceromegaly, and adrenal and renal disorders (Beckwith-Wiedemann syndrome), with glycogen storage diseases (Hunter's and Hurler's syndromes) or hypothyroidism, is rare. Relative macroglossia can be seen normally on occasion but is most common in Down syndrome. The most serious complication of this condition is airway obstruction. In infants, macroglossia should be distinguished from focal enlargement of the tongue seen in patients with a lymphatic malformation or hemangioma. Glossoptosis, posterior displacement of a normal-sized tongue, is seen in association with cleft palate and micrognathia in infants afflicted with the Pierre Robin sequence. Infants with airway obstruction secondary to an enlarged or displaced tongue may require a tracheostomy. Macroglossia in older children that affects cosmesis, interferes with speech, or causes drooling may be treated with a variety of tongue reduction techniques.

### Benign Lesions

*Epulis* is a congenital granular cell tumor that typically presents as a soft, pink submucosal mass on the anterior alveolar ridge of the maxilla (Fig. 52-10). Females are



**Figure 52-10** Congenital epulis. The congenital epulis is an unusual benign lesion that frequently arises from the anterior maxillary alveolar ridge. Airway and feeding difficulties may develop secondary to large lesions. Surgical excision is required.



**Figure 52-11** A ranula is a pseudocyst caused by obstruction of a sublingual gland. It generally presents as a unilateral, painless swelling in the floor of the mouth.

more commonly affected, and symptoms are usually confined to feeding problems. Surgical excision is curative.

*Ranula* is a pseudocyst located in the floor of the mouth that may occur congenitally or result from intra-oral trauma (Fig. 52-11). Large ranulas may extend through the mylohyoid musculature and present in the neck as a “plunging ranula.” Treatment of ranulas is by excision or marsupialization of the pseudocyst, often in conjunction with excision of the sublingual gland. *Mucoceles* are also pseudocysts of minor salivary gland origin and frequently rupture spontaneously. Recurrent or symptomatic mucoceles respond to surgical excision.

*Hemangioma* is a proliferative endothelial lesion found commonly in the head and neck. Their growth characteristics include enlargement during the first year of life, followed by spontaneous resolution. Surgical excision or treatment with corticosteroids may be necessary in lesions that cause ulceration and bleeding, airway obstruction, cardiovascular compromise, or platelet-trapping coagulopathy (Kasabach-Merritt syndrome). *Vascular malformations*, including venous, arterial, or arteriovenous malformations, rarely occur in the oral cavity and pharynx and necessitate intervention only if they cause pain, bleeding, ulceration, or heart failure. Management of complicated cases is by surgical excision or sclerotherapy for low-flow lesions (venous) and angiographic embolization for high-flow lesions.

*Lymphatic malformation*, formerly known as lymphangioma or cystic hygroma, is congenital and usually presents before 2 years of age. Histologically, lymphatic malformations consist of multiple dilated lymphatic channels or may contain either capillary or venous elements (venolymphatic malformations). Lymphatic malformations can occur anywhere in the neck and may cause extensive cosmetic deformity and functional problems in

cases with involvement of the tongue, floor of mouth, mandible, or larynx. Surgical resection of lymphatic malformations may be fraught with difficulty because they lack a capsule and are infiltrative. During surgical excision, care should be taken to avoid damaging nearby vital structures, and debulking is an acceptable option to total radical excision in many cases. Postoperative suction drains can be helpful in preventing the recurrence of lymphatic drainage under skin flaps. Carbon dioxide laser therapy has been employed in superficial lymphatic malformations of the tongue, and sclerotherapy of large cystic lesions may be an option.

*Foregut cysts* are true cysts, lined with respiratory epithelium, that present in the floor of mouth and should be distinguished from *dermoid cysts*, lined with stratified squamous epithelium and skin appendages, which may also be found in this location. A *thyroglossal duct cyst* may rarely present in the base of the tongue. Likewise, aberrant thyroid tissue, *lingual thyroid*, presents as a purple mass in the tongue base. Thyroid tissue in this location is usually hypofunctioning, and affected children require thyroid supplementation. Other aberrant rests of tissue, *choristomas*, consist of gastric, enteric, or neural tissue of normal histology in an abnormal location.

*Second branchial cleft derivatives* will rarely present as a cystic mass near the superior pole of the tonsil. Their extent and associated tracts can be demonstrated on MRI. *Tornwaldt's cyst* is a blind pouch in the nasopharynx that represents a persistence of an embryonic connection between the primitive notochord and the pharynx. Other benign nasopharyngeal masses include *nasopharyngeal teratomas*, *dermoid lesions (hairy polyp)*, and *nasopharyngeal encephaloceles*. Most of these lesions are best evaluated by CT and/or MRI to determine their extent and the presence of an intracranial connection. Surgical excision is curative in most cases.

*Squamous papillomas* are benign slow-growing lesions typically found on the soft palate, uvula, and tonsillar pillars and are the result of infection with serotypes 6, 14, or 22 of the human papillomavirus (HPV). Because of concern that these lesions could spread to the larynx or trachea, complete surgical excision is usually recommended. *Pleomorphic adenoma* (mixed tumor) is a benign neoplasm of minor salivary glands with a predilection for the palate, although it may also be found in the lip and buccal mucosa. Treatment is with surgical excision.

## Malignant Lesions

*Rhabdomyosarcoma*, the most frequent soft tissue malignancy of childhood, typically occurs in the 2- to 6-year age group and is derived from embryonic skeletal muscle.<sup>4,18</sup> In the oral cavity and oropharynx it presents as a rapidly growing mass in the tongue, palate, and uvula or cheek. These tumors metastasize early to local nodes, lung, and bone. Surgical therapy is limited to biopsy, excision of small lesions, or surgical salvage of treatment failures. The usual therapy includes a combination of chemotherapy and radiation therapy.

*Lymphoma* of the oral cavity and oropharynx typically involves the lymphoid tissue of Waldeyer's ring and presents

as a mass of the tonsil or in the nasopharynx.<sup>8</sup> The diagnosis may be suspected by evidence of involved adenopathy in the neck but is confirmed by surgical biopsy. Treatment is with a combination of chemotherapy and radiation therapy.

Other rare malignant neoplasms of the oral cavity and pharynx include malignant salivary gland tumors (*mucoepidermoid carcinoma*) and *epidermoid* or *squamous cell carcinoma*. This latter tumor has been reported in organ transplant patients and adolescents who use snuff or chewing tobacco.<sup>19</sup> Treatment is usually surgical depending on the site and extent of involvement.

## LARYNX

### Anatomy

With the exception of the hyoid bone, the major structural framework of the larynx consists of cartilage and soft tissue. The hyoid bone lies superior to the larynx and is attached to it by the thyrohyoid membrane and strap muscles. The hyoid bone is derived from the second and third branchial arches. The cartilaginous structures of the larynx are composed of hyaline cartilage, with the exception of the epiglottis, which is composed of elastic cartilage. The cartilaginous structures of the larynx develop from the fourth, fifth, and sixth branchial arches. There are nine laryngeal cartilages, three that are single (thyroid, cricoid, and epiglottis) and six that are paired (arytenoid, cuneiform, and corniculate). The thyroid cartilage consists of two quadrilateral cartilages that form the anterior framework of the larynx. The cricoid cartilage is the only complete cartilaginous structure in the airway and provides posterior stability and a base of support for the cricoarytenoid and cricothyroid joints.

The cricothyroid muscles are paired extrinsic laryngeal muscles that serve to tilt the larynx down and forward, tensing the vocal folds. Paired intrinsic muscles—the thyroarytenoid, thyroepiglottic, and aryepiglottic muscles—act as a sphincter to close the larynx. The vocalis muscle comprises the internal fibers of the thyroarytenoid muscle and attaches to the vocal ligament. Action of this muscle serves to regulate the pitch of the vocal ligament. The other set of paired muscles includes the posterior cricoarytenoid, lateral cricoarytenoid, and interarytenoid muscles. The posterior cricoarytenoid muscles serve to abduct the vocal folds, whereas the cricoarytenoid and interarytenoid muscles adduct the vocal folds.

The quadrangular membrane is a connective tissue covering of the superior larynx that ends in a free margin along the vestibular ligament of the false cord. The conus elasticus is a membrane of elastic tissue that extends superiorly from the cricoid cartilage to form the paired vocal ligaments, the supporting structures of the vocal folds.

The blood supply of the larynx arises from the superior and inferior laryngeal arteries. The former is a branch of the superior thyroid artery, whereas the latter is a branch from the thyrocervical trunk. The intrinsic muscles of the larynx are innervated by the recurrent laryngeal nerve, which also supplies sensory branches to

the inferior larynx. The superior laryngeal nerve has two branches: the external branch innervates the cricothyroid muscle, while the internal branch supplies sensation to the superior larynx.

The larynx has multiple functions within the upper airway. During respiration, it regulates airflow by opening during inspiration. The posterior cricoarytenoid muscle contracts with each inspiration to abduct the cords just before activation of the diaphragm. The protective function of the larynx produces two reflexes: cough and closure. Cough is important to expel mucus and foreign objects. The closure reflex serves to prevent aspiration of foreign matter. In addition to closure, the larynx elevates during swallowing. Both closure and elevation occur simultaneously along with relaxation of the cricopharyngeus muscle during the swallow of a bolus. Finally, the larynx plays an important role in speech production by generating sound. Vibration of the mucosa covering the vocalis structures produces sound whose pitch and register is altered by changes in tension, length, and mass of the underlying vocalis muscle and ligament.

The larynx of an infant sits much higher than that of an adult. The cricoid is located at the level of C4, whereas the tip of the epiglottis is at C1. The close approximation of the epiglottis to the soft palate makes the infant an obligate nose breather. By 2 years of age, the larynx has descended to the level of C5 and reaches the adult level of C6 to C7 by puberty. The glottis of the newborn is 7 mm in the anteroposterior dimension and 4 mm in the lateral dimension. The narrowest area of the infant airway, the subglottis, is approximately 4 mm in diameter.

### Upper Airway Assessment

Symptoms of acute airway obstruction include dyspnea, cough, vocal changes, dysphagia, and sore throat. Dyspnea and rapid or labored breathing are indications of inadequate ventilation and may be triggered by changes in  $PCO_2$  and  $PO_2$ . A stimulus anywhere in the airway may produce cough. It is difficult to localize the site of the stimulus from the quality of the cough. Changes in the child's vocal character such as hoarseness or a muffled or weak cry may help in localizing the area of obstruction. Dysphagia for solids and/or liquids is often associated with airway obstruction. Depending on the cause of airway obstruction, affected patients may complain of sore throat.

The child's overall appearance is the first sign to be assessed in airway obstruction, because airway status often dictates how quickly further evaluation and intervention need to be performed. The level of consciousness should be determined because the unconscious or obtunded patient may need immediate airway management. Along with cyanosis in a patient without cyanotic heart disease, the presence of anxiety, restlessness, and diaphoresis are all ominous signs of impending airway compromise. Other symptoms of airway obstruction include tachypnea and substernal retractions. The child with airway obstruction is often tachycardic. The presence of bradycardia is a



late indicator of severe hypoxia. The presence of a muffled cry often suggests obstruction at the level of the pharynx, whereas a barking cough is associated with laryngeal inflammation and edema. Stertor is a snoring sound whose origin is often in the pharynx. Stridor is noise produced by turbulent airflow in the laryngeal or tracheal airway. Inspiratory stridor suggests turbulence at or above the glottis. Expiratory stridor results from turbulent airflow in the distal trachea or bronchi. Biphase stridor suggests a tracheal source. The degree and loudness of the sound is not always indicative of the severity of obstruction, because stridor can become softer just before complete obstruction. Other important signs of airway obstruction include drooling and use of accessory respiratory muscles.

In addition to determination of the child's physical status, assessment of the degree of airway obstruction should include an evaluation of the ventilatory status. Pulse oximetry provides an immediate record of arterial oxygenation while transcutaneous monitoring of CO<sub>2</sub> is a good indicator of ventilation. The lateral neck radiograph remains the best study for the initial evaluation of a child with airway obstruction because it demonstrates the anatomy from the tip of the nose to the thoracic inlet. The anteroposterior view of the neck is also helpful, specifically in defining areas of narrowing, such as a steep sign associated with subglottic edema. A chest radiograph is also important in the initial assessment to identify foreign bodies or other conditions such as unilateral emphysema, atelectasis, or pneumonia that may account for the child's respiratory compromise. If time permits, a barium swallow or airway fluoroscopy may provide additional information.

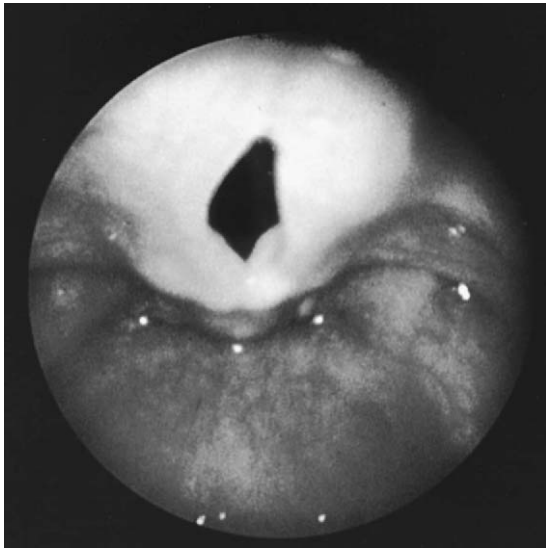
Additional airway evaluation may include a brief flexible endoscopic examination. The nose is first sprayed with a combination of 2% lidocaine and oxymetazoline, and the child is gently restrained. The airway can be examined from the nares to the glottis. Attempts to pass a flexible scope through the glottis in a child with airway obstruction should be avoided. Likewise, flexible endoscopy should be avoided in a child with supraglottitis because of the possibility of precipitating complete obstruction. Children with suspected airway pathology distal to the glottis or those in whom the possibility that flexible endoscopy could compromise the airway should undergo any airway examination in the operating room where rigid endoscopes and other airway equipment is immediately available to secure the airway if necessary.

Nonsurgical intervention in the child with acute airway obstruction may begin with just observation alone in a high surveillance unit. Humidified oxygen administered by face mask will improve PO<sub>2</sub> and clearance of secretions. Racemic epinephrine administered by nebulizer acts to reduce mucosal edema and is useful in conditions such as laryngotracheobronchitis (infectious croup). Because its length of action lasts 30 to 60 minutes, treated patients should be observed for signs of rebound for 4 to 6 hours after administration. Corticosteroids have been shown to have value in the management of postintubation croup, adenotonsillar hypertrophy that results from EBV infection, allergic edema, and spasmodic croup. Use of corticosteroids in infectious croup and in infants with a subglottic hemangioma remains controversial.<sup>10,16</sup>

Other adjuvant therapies include antibiotics and inhalation of helium/oxygen mixture (heliox). Although viral agents are often responsible for inflammation in the larynx and trachea, bacterial superinfection is also common. Because of the prevalence of penicillin-resistant organisms, broad-spectrum antibiotics, including a higher-generation cephalosporin, penicillinase-resistant penicillin, or  $\beta$ -lactamase penicillin, are useful in preventing or eradicating infection. Heliox is a mixture of gas in which helium is used to replace nitrogen. The advantage of the helium-oxygen mixture is that its low density reduces air turbulence and gas resistance, allowing improved delivery of oxygen in patients with airway obstruction.

Nonsurgical airway management may include use of nasal or oral airways, endotracheal intubation, and, rarely, transtracheal ventilation. Nasal airways of rubber or other synthetic material can be easily inserted into the nose of most children after adequate lubrication with a water-soluble lubricant. Their best use is in cases where the pharynx is the site of obstruction. Oral airways are not as readily tolerated by children and only serve as a brief solution to an airway problem. During the 1970s, endotracheal intubation with polyvinyl chloride tubes revolutionized the management of supraglottitis, and even today intubation remains the mainstay of initial airway therapy in most children with severe airway obstruction. The size of the endotracheal tube used correlates with the age of the child. The subglottis, the narrowest part of the infant airway, typically admits a 3.5- or 4.0-mm inner diameter tube. The tube used in children older than a year can be roughly estimated by using the following formula: tube size = (16 + age in years)  $\div$  4. Once the airway has been established, the tube should be carefully secured and the child appropriately sedated and/or restrained if necessary to avoid accidental self-extubation. Another method of airway management should be considered in children with an unstable cervical spine or in whom oral or neck trauma makes visualization difficult. Transtracheal ventilation, insertion of a 16-gauge needle through the cricothyroid membrane for the delivery of oxygen, should be reserved for emergencies and used only until a more stable airway can be obtained.

The surgical management of the child with acute airway obstruction should begin with endoscopy. The larynx can be visualized with one of a variety of pediatric laryngoscopes and the airway secured with a rigid pediatric ventilating bronchoscope of appropriate size. Once the airway is secured, a more stable form of airway management can be utilized. Rarely, in a child with acute airway obstruction, an airway cannot be established, and a cricothyrotomy may need to be performed. As in adults, this procedure avoids some of the risks of bleeding and pneumothorax inherent in a formal emergency tracheostomy. A small endotracheal or tracheostomy tube can be inserted through the incision in the cricothyroid membrane, but conversion should be made to a more stable airway as soon as possible. Tracheostomy remains the preferred airway in cases of acute obstruction in which a translaryngeal approach is unsuccessful or must be avoided. The emergent tracheostomy should be avoided if at all possible to lessen complications of bleeding, pneumothorax, pneumomediastinum, subcutaneous



**Figure 52-12** Laryngomalacia. This disorder classically presents as an omega-shaped epiglottis. The arytenoid mucosa is redundant, and the aryepiglottic folds are foreshortened. The result is a hooding of tissue over the glottic inlet that leads to airway obstruction on inspiration.

emphysema, or damage to surrounding structures. The incidence of these complications can be reduced by careful attention to surgical technique, good lighting, and adequate assistance.

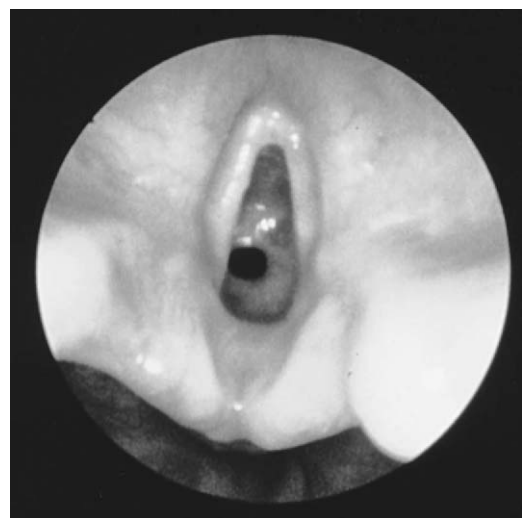### Congenital Laryngeal Anomalies

*Laryngomalacia* is the most common cause of newborn stridor and is caused by prolapse of the supraglottic structures (arytenoid cartilages, aryepiglottic folds) during inspiration (Fig. 52-12). Symptoms typically appear at birth or soon thereafter and include inspiratory stridor, feeding difficulties, and, rarely, apnea or signs of severe airway obstruction. Gastroesophageal reflux disease tends to worsen symptoms of laryngomalacia. The diagnosis is confirmed by flexible endoscopy of the larynx, and other airway pathology can be excluded with lateral neck, chest, and barium swallow radiography. In most cases, laryngomalacia is self-limited and resolves by 18 months of age. Changes in positioning and feeding, treatment of reflux, and, in some neonates, use of monitoring may be necessary. In severe cases, surgical intervention with either a supraglottoplasty (surgical division of the aryepiglottic folds) or a tracheostomy may be necessary.

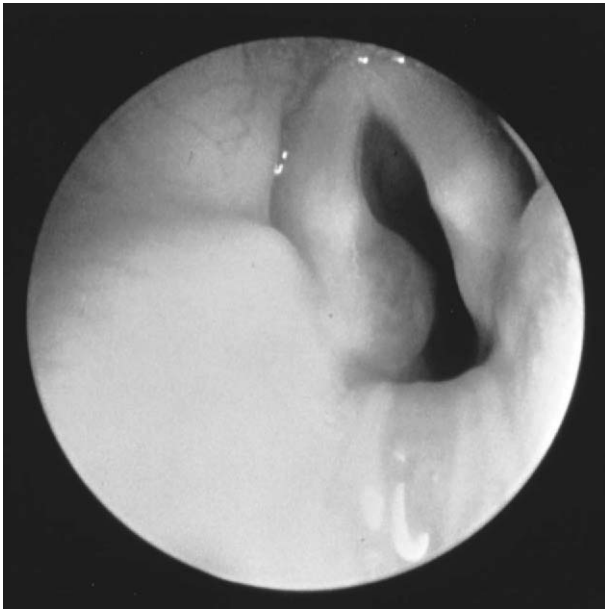*Tracheobronchomalacia* is defined as collapse of the tracheobronchial airway. It may be congenital or acquired (from long-standing intubation and infection) and may be segmental or involve the entire tracheobronchial tree. Depending on the extent and location, symptoms include low-pitched biphasic stridor and signs of respiratory compromise. The diagnosis is usually made with endoscopy, although fluoroscopy of the airway may often demonstrate it. Treatment ranges from observation in most cases to airway management with a tracheostomy tube and positive-pressure ventilation in severe cases.

*Vocal fold paralysis* is the second most common congenital laryngeal anomaly (after laryngomalacia) and may be unilateral or bilateral. Congenital vocal fold paralysis may be caused by neurologic abnormalities (hydrocephalus, Arnold-Chiari malformation), birth trauma, or rarely in association with neoplasms of the larynx or neck. Neonates with bilateral involvement typically present with high-pitched inspiratory or biphasic stridor but a good cry. Respiratory compromise and feeding difficulties may accompany the stridor. In infants with unilateral involvement, the airway may be adequate although a few infants will show evidence of compromise, especially during feeding. The cry is often hoarse or breathy. Acquired vocal fold paralysis may result from trauma or from neoplasms of the chest or neck or may be iatrogenic, typically after surgery of the neck or arch of the aorta. The diagnosis of unilateral or bilateral vocal fold paralysis is confirmed with endoscopy. Additional studies in the evaluation of patients with vocal fold paralysis include lateral neck and chest radiography, barium swallow, and CT or MRI of the head and neck. Most cases of unilateral involvement can be observed, but infants with bilateral vocal fold paralysis often require a tracheostomy. In addition, infants with associated feeding difficulties may necessitate a gastrostomy. In older children (> 4 or 5 years of age) a more permanent solution such as a cordotomy or arytenoidectomy can be considered to improve the glottic airway.

*Congenital subglottic stenosis* is the third most common congenital laryngeal anomaly and is defined as a neonatal larynx that fails to admit a 3.5-mm endotracheal tube without a history of prior instrumentation or intubation (Fig. 52-13). The underlying abnormality is a cricoid cartilage that is either small or deformed. Infants with congenital subglottic stenosis present with inspiratory or biphasic stridor, barking cough, and other symptoms of airway obstruction. The diagnosis is often suggested by narrowing of the subglottis on a lateral neck radiograph and confirmed by endoscopy. Treatment depends on the severity of symptoms and ranges from observation to laryngeal reconstruction to tracheostomy.



**Figure 52-13** Subglottic stenosis. Congenital and acquired stenosis create airway obstruction, depending on the severity and type of stenosis. Various forms of reconstruction are available (see Chapter 63).



**Figure 52-14** Subglottic hemangiomas typically arise from the posterior lateral aspect of the larynx. Small lesions may be managed conservatively, whereas lesions with aggressive growth patterns require tracheotomy to bypass the laryngeal obstruction.

A child with a *subglottic hemangioma* presents with the onset of progressive stridor during the first few months of life (Fig 52-14). Hemangiomas are proliferative endothelial lesions that can form in the submucosa of the posterior subglottis. Occasionally, they may involve the subglottis in a circumferential pattern. Associated cutaneous hemangiomas may be found in approximately 50% of patients. Symptoms are dependent on the amount of airway compromise and include biphasic stridor, barking cough, difficulty feeding, and other symptoms and signs of airway obstruction. The diagnosis may be suggested on a lateral neck radiograph but is confirmed with endoscopy. Nonsurgical management of infants with a subglottic hemangioma includes observation or treatment with systemic corticosteroids. Surgical therapy includes laser excision, open excision through a laryngofissure, or a tracheostomy.

A *laryngocele* is an air-filled dilatation of the sacculus of the larynx that communicates with the laryngeal airway. It may present internally into the posterior superior false cord region or externally through the thyrohyoid membrane. A *saccular cyst* is fluid filled and protrudes between the true and false vocal folds. The diagnosis of this lesion is confirmed endoscopically, and CT of the larynx is helpful in assessing its extent and if it is fluid or air filled. Treatment is with endoscopic marsupialization or excision through a laryngofissure.

### Inflammatory Disease of the Upper Airway

*Laryngotracheobronchitis (viral croup)* is an inflammation of the subglottic airway caused by a variety of parainfluenza and influenza viral agents. The infection may involve the

entire glottis and extend into the trachea and bronchi. Affected children fall typically into the 1- to 3-year age group; males are more commonly affected than females. Symptoms and signs of viral croup include biphasic stridor, barking cough, and hoarseness, often in association with a prodromal viral upper respiratory tract infection. The diagnosis of croup is made clinically, but endoscopic examination may help to exclude other pathologic processes. Care should be taken not to instrument the subglottis, causing more swelling and inflammation and precipitating acute obstruction. Lateral neck radiography demonstrates subglottic narrowing, whereas anteroposterior neck films show a “steeple sign,” the result of subglottic edema. Treatment of viral croup is typically supportive with humidification. Use of corticosteroids remains controversial. Treatment with nebulized racemic epinephrine in the emergency department or hospital setting often relieves symptoms; however, rebound of signs may occur several hours later and children should be monitored accordingly. Severely affected children may require intubation for respiratory failure. A smaller than normal tube should be employed. In rare cases, a tracheostomy may be required if the inflammation fails to resolve.

A child younger than 1 year of age with recurrent bouts of “croup” should be suspected of having either congenital subglottic stenosis or a hemangioma. Spasmodic croup is the recurrence of croup-like symptoms in a child who is otherwise well. Fever is rarely present, and the attacks frequently occur at night. Gastroesophageal reflux disease has been suggested as a possible inciting process. Treatment of spasmodic croup is usually observant, although corticosteroids or reflux medications may prove beneficial.

*Supraglottitis (epiglottitis)* is an infectious disease that involves the supraglottic larynx. In children the typical pathogen is type B *Haemophilus influenzae* (HIB). Other pathogens have been implicated in adolescent and adult cases. The incidence of supraglottitis in children has diminished markedly since the introduction of the conjugated HIB vaccine in the early 1990s.<sup>17</sup> Affected children are somewhat older than those seen with croup—in the 3- to 6-year age group. Symptoms and signs have a rapid onset, progress quickly to frank airway obstruction, and include stridor, dysphagia, fever, muffled voice, and signs of systemic toxicity. Affected children frequently sit and assume the “sniffing” position in an attempt to maximize their airway. Intraoral or endoscopic examination should be avoided in suspected patients because of concern for precipitating complete obstruction. Lateral neck radiography demonstrates a classic “thumbprinting” of the epiglottis but should only be obtained if facilities are present in close proximity to secure the airway.

Prompt airway management is essential in children with supraglottitis. The child’s airway should be secured in either the emergency department or operating room with team members who include a pediatrician, anesthesiologist, critical care physician, otolaryngologist, or pediatric surgeon or others familiar with the pediatric airway. After inducing the child with general anesthesia, the airway should be intubated. Examination of the supraglottis may be made, and cultures of the larynx and blood are obtained. Equipment to perform a tracheostomy should

be readily available. The child should remain intubated for 24 to 72 hours and should be supported with intravenous fluids and antibiotics that treat antibiotic-resistant *Haemophilus* (third-generation cephalosporins, chloramphenicol).

*Bacterial tracheitis (membranous croup)* often occurs as a complication of another infection, such as measles, varicella, or other viral agents. The most common organisms include *S. aureus*, GABHS, *M. catarrhalis*, or *H. influenzae*. It can occur in any age child and present with stridor, barking cough, and low-grade fever. Symptoms and signs then progress to include high fever and increasing obstruction and toxicity. The diagnosis may be suspected by diffuse narrowing of the tracheal air shadow on chest radiograph but is confirmed by endoscopic examination in the operating room. Purulent debris and crusts can be removed at this time. Cultures of secretions and crusts may be helpful in guiding intravenous antibiotic therapy that should be aimed initially at the usual pathogens. The airway should be secured with an endotracheal tube or, rarely, a tracheostomy. Repeat endoscopic examination of the airway may be warranted to continue débridement and to determine the feasibility of extubation.

### Chronic Airway Obstruction

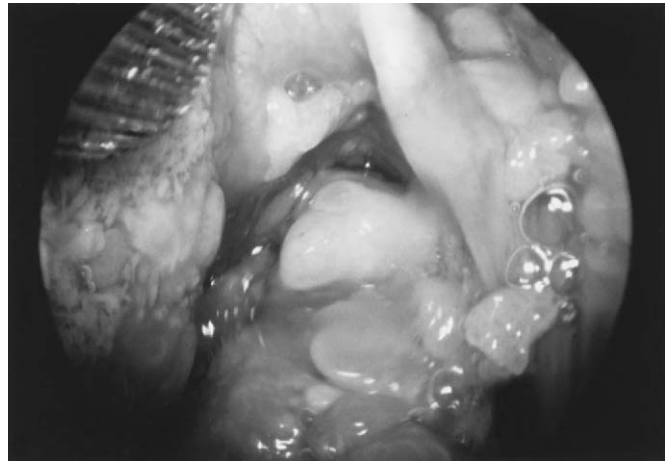
The chronic management of subglottic stenosis and other prolonged airway disorders is discussed in Chapter 63.

### Benign Laryngeal Neoplasms

*Recurrent respiratory papillomatosis* is the most common benign neoplasm of the larynx in children. Squamous papillomas involve the larynx and occasionally the trachea and lower respiratory tract as exophytic lesions. Because of its recurrent nature, recurrent respiratory papillomatosis causes morbidity and, rarely, mortality due to malignant degeneration. Patients may be almost any age, but the disease is more aggressive in children. Human papillomavirus subtypes 6, 11, 16, and 18 have all been identified within papilloma tissue. The first two subtypes have been associated with genital warts, whereas the latter two have been associated with cervical and laryngeal cancers. The exact mechanism of human papillomavirus infection in the larynx remains unknown. Transmission of virus to the child from a mother with genital warts is suspected in many cases, but there is no concrete evidence to support this route of infection.

Children afflicted with recurrent respiratory papillomatosis present initially with hoarseness but may also have symptoms and signs of airway obstruction, including stridor. Lateral neck radiography may suggest laryngeal involvement, but the diagnosis is confirmed by direct laryngoscopy and biopsy (Fig. 52-15). In addition to the trachea and bronchi, squamous papillomas may also be found in the oral cavity.

Surgical excision is the mainstay of therapy in patients with recurrent respiratory papillomatosis. In the past, papillomas were excised using the carbon dioxide laser. More recently, the laryngeal microdebrider has become



**Figure 52-15** Recurrent respiratory papillomatosis. Severe papillomatosis may completely obstruct the larynx. Papillomas are characterized by malignant degeneration and aggressive growth patterns.

the preferred method of excision in many centers. In aggressive cases with swift recurrence and accompanying airway obstruction, tracheostomy may be necessary for airway management, although tracheostomy has been implicated in the spread of disease to the trachea and lower respiratory tract. Medical adjuvant therapy that has been employed with mixed results includes interferon, photodynamic therapy with dihematoporphyrin ether, indole-3-carbinol, or antiviral agents such as cidofovir.

Other benign laryngeal neoplasms are rare and include connective tissue tumors such as chondromas or fibromas, neurogenic tumors such as neurofibromas, or granular cell tumors and other cell types such as hamartomas or fibrous histiocytomas. Malignant tumors of the larynx are also rare and include squamous cell carcinoma and a variety of epithelial and connective tissue malignancies such as spindle cell carcinoma, rhabdomyosarcoma, mucoepidermoid carcinoma, and chondrosarcoma. Metastatic tumors and lymphoma may also rarely involve the larynx in children. Diagnosis is suspected by the sudden appearance of stridor, hoarseness, and airway obstruction and confirmed by biopsy. Treatment is dependent on cell type and may include surgical excision, radiation therapy, and/or chemotherapy.

## NECK

### Anatomy

The surgical anatomy and embryology of the neck is discussed in Chapter 56.

### Clinical Evaluation

The initial examination of a disease or disorder of the neck begins with a thorough history. A detailed history can often serve to focus the differential diagnosis of a neck disorder. The age of the child is an important

first consideration. The appearance of a neck mass in an infant often suggests a congenital disorder, whereas the sudden appearance of a mass in an adolescent might suggest a malignant process. Inflammatory diseases of the neck may occur in any age group but typically mirror the incidence of upper respiratory tract infections in children. Growth and temporal relationships are often important clues to a diagnosis. Neck masses that grow rapidly suggest either an inflammatory or malignant process, whereas slow-growing masses are typically benign. A history of systemic infection elsewhere in the body or recent travel or exposure to farm animals often points to an infectious origin. A history of trauma to the neck may explain the sudden appearance of a neck mass. Likewise, changes in the size of a neck mass with eating may suggest a salivary gland origin. Vascular lesions enlarge with straining or crying. Finally, systemic symptoms of fever, weight loss, night sweats, or fatigue in association with the sudden development of a neck mass may indicate a malignant process.

The physical examination of a child with a neck mass should begin with a comprehensive examination of the entire head and neck. Because the vascular, neural, and lymphatic patterns of the head drain into the neck, the source of neck disorders may be found in the head. Depending on the differential diagnosis, a physical examination of the entire body, including an assessment of lymph nodes in the groin and axillae and the presence of an enlarged spleen or liver, is essential. Palpable lymph nodes in the neck of children are a common finding, but lymph nodes larger than 2 cm fall outside the range of normal hyperplastic nodes and should be either monitored or investigated. The sudden appearance of large nodes in either the posterior cervical or supraclavicular regions may suggest a malignancy.<sup>31</sup> The consistency of a neck mass is also important in narrowing the differential diagnosis. Hard masses tend to be associated with either infection or malignancy. Fixation of a neck mass to skin or nearby structures is also suggestive of a malignancy. Cysts or abscesses tend to have a characteristic feel on palpation.

Depending on the differential diagnosis after a history and physical examination, radiologic studies may be useful. A lateral neck radiograph may demonstrate an abnormality of the nasopharynx, retropharynx, or cervical spine. Likewise, a chest radiograph may identify a malignancy, sarcoidosis, or tuberculosis. Infection or a neoplastic process in the sinuses may appear on a sinus series. CT and MRI are useful in the evaluation of a neck mass. Demonstration of hypodensity on CT suggests an inflammatory or necrotic process. Ring enhancement of a hypodense region on a contrast CT scan is indicative of an abscess. MRI is excellent for distinguishing fine detail within soft tissue and in the evaluation of vascular lesions of the neck. Finally, ultrasound is helpful in distinguishing solid and cystic masses. Use of ultrasound preoperatively in patients with a thyroglossal duct cyst is also a simple and economic way to assess the presence of normal thyroid tissue when it is not easily felt. Ultrasound and thyroid scanning should be employed in the assessment of any thyroid mass.

Selected laboratory studies may be helpful in the evaluation of a child with a neck disorder. A complete blood

cell count with differential may identify patients with either a malignancy or systemic infection. Serologic testing for EBV or cytomegalovirus infection, toxoplasmosis, or cat-scratch disease may be diagnostic. Thyroid function testing is essential in any child with a suspected thyroid disorder. Finally, collection of urine for catecholamine metabolites (vanillylmandelic acid) may assist in the diagnosis of neuroblastoma.

If the diagnosis remains in doubt at this point, incisional or excisional biopsy may be indicated. Biopsy provides material for pathologic examination, culture, and other more sophisticated testing if necessary. Fine-needle aspiration of a neck mass in children for suspected malignancy is not as reliable as in adults.

### Congenital Tracts and Cysts

Congenital sinuses and cysts are discussed in Chapter 56.

### Inflammatory and Infectious Masses

*Viral adenitis* is the most common infectious disorder to involve the neck in children. Enlarged or hyperplastic lymph nodes are frequently the result of viral upper respiratory tract illnesses. Common pathogens include rhinovirus, adenovirus, and enterovirus, but measles, mumps, rubella, varicella, EBV, and cytomegalovirus may also cause lymphadenopathy. The diagnosis is often suspected by other findings in the history or physical examination and can be confirmed by serologic testing. Acute human immunodeficiency virus infection may present, as do other viral syndromes, with fever, headache, malaise, gastrointestinal symptoms, and a neck mass.

The usual source of *bacterial cervical adenitis* is the pharynx. Causative organisms are often streptococcal or staphylococcal species. Patients present with systemic symptoms of fever and malaise in addition to a neck mass that is diffusely swollen, erythematous, and tender. In contrast to viral adenitis, which is frequently bilateral, bacterial infections of the neck are usually unilateral. CT with contrast medium enhancement may be helpful in the evaluation of large infectious neck masses that may contain an abscess cavity. Needle aspiration of suspected infectious masses may provide material for culture and decompress the mass. Broad-spectrum antibiotic therapy, administered either orally or intravenously, may be curative, although surgical drainage is usually necessary in extensive cases.

*Cat-scratch disease* is caused by *Bartonella henselae* infection. The clinical picture includes the sudden appearance of unilateral lymphadenopathy after a scratch from a cat. Fever and malaise may be accompanying symptoms in many cases. Serologic testing for antibodies to *Bartonella* is diagnostic. Cat-scratch disease is usually self-limited, although some benefit has been described with the use of erythromycins and other antibiotics.<sup>21</sup>

In the past most mycobacterial infections have been caused by atypical organisms such as *Mycobacterium avium-intracellulare*, *M. scrofulaceum*, *M. bovis*, or *M. kansasii*. In the past decade or so, mycobacterial tuberculosis has

made a resurgence as the pathogen responsible for a neck infection. Atypical mycobacterial infections present as nontender nodes in the preauricular, intraparotid, or posterior triangle regions. The skin overlying the node typically assumes a violet color, and systemic symptoms are rare. A chest radiograph should be obtained if *M. tuberculosis* is suspected. The diagnosis is made by obtaining material for acid-fast stain and culture with needle aspiration, surgical drainage, or excision of involved nodes. Surgical curettage or total excision is curative for atypical lesions. Tuberculosis should be treated with appropriate antituberculin chemotherapy.

Rarely, the neck may be involved with infections such as tularemia, brucellosis, actinomycosis, plague, histoplasmosis, or toxoplasmosis. Inflammatory disorders that may affect the neck include Kawasaki syndrome, sarcoidosis, sinus histiocytosis (Rosai-Dorfman disease), Kikuchi-Fujimoto disease, and PFAPA syndrome (periodic recurrent fever).

### Malignant Neoplasms

Thyroid malignancies are not uncommon in the adolescent age group, with 10% of thyroid carcinomas occurring in patients younger than 21 years of age.<sup>3</sup> Well-differentiated tumors, usually *papillary carcinoma*, make up the majority of tumors. *Follicular, mixed, and medullary* tumors occur less commonly. Most patients present with a painless midline neck mass. On presentation, cervical adenopathy can be palpated in a majority of patients, a finding that reflects the high incidence of papillary disease that metastasizes via the lymphatics.<sup>9</sup> Other important symptoms and signs include a rapid rate of growth, pain, hoarseness, and dysphagia. Children who have received prior radiation are at greater risk of thyroid malignancy. The occurrence of thyroid malignancy may be associated with iodine deficiency, Hashimoto's thyroiditis, and Graves' disease.<sup>9,22</sup> Preoperative assessment should include thyroid nucleotide scanning to distinguish between cold (hypofunctioning) and hot (hyperfunctioning) nodules. Up to a third of cold nodules can be malignant, whereas hot nodules are rarely malignant.<sup>12</sup> Ultrasonography can distinguish between solid and cystic lesions, and fine-needle aspiration is an alternative to surgical biopsy for diagnosis. Surgical management includes near-total or total thyroidectomy, neck dissection if indicated, and postoperative <sup>131</sup>I ablation.

*Lymphoma* is a common pediatric malignancy and can present in the neck as painless lymphadenopathy. *Hodgkin's disease* occurs most often in late adolescence and has four histologic subtypes: lymphocyte predominance, nodular sclerosing, mixed cellularity, and lymphocyte depletion. Lymphocyte predominance and nodular sclerosing types make up most cases. Staging of Hodgkin's disease depends on the amount and location of nodal involvement and the presence or absence of systemic or B symptoms (fever, night sweats, weight loss). Treatment is with multiple-agent chemotherapy and localized radiation therapy. Non-Hodgkin's lymphoma can be divided into low-, intermediate-, or high-grade subtypes.

High-grade tumors may be further divided into large cell, lymphoblastic, and small cell types. Staging of non-Hodgkin's lymphoma is by location and extent. Treatment is with multiple-agent chemotherapy.

*Langerhans' cell histiocytosis* (previously histiocytosis X) includes the disease entities known as eosinophilic granuloma, Hand-Schüller-Christian syndrome, and Letterer-Siwe disease. The exact nature of this entity remains an enigma: it may represent a neoplasm or a hyperimmune response.<sup>7</sup> Symptoms and signs include lymphadenopathy, rashes, otorrhea, oral lesions, and hepatosplenomegaly. Diagnosis is dependent on the identification of Langerhan's cells on pathologic specimens. Treatment ranges from curettage or excision to intraleisional or systemic corticosteroids to chemotherapy and radiation therapy.

Two major categories of neural tumors may be found in the neck. *Neurofibromatosis* is a benign disorder that in some forms (plexiform) may infiltrate surrounding tissues. For this reason, CT and/or MRI are vital in the preoperative evaluation of these lesions. Surgical resection is the mainstay of treatment. *Neuroblastoma* is a malignancy that develops from neural crest cells and may present as a solitary tumor or as lymphadenopathy. Clinical staging determines the mode of therapy that includes surgery, chemotherapy, and radiation therapy.

*Rhabdomyosarcoma* rarely presents as a primary tumor in the neck, more often being found as a primary tumor in the orbit, temporal bone, or nasopharynx. The diagnosis is made by biopsy, and patients are staged according to involvement. Treatment includes surgery, chemotherapy, and radiation therapy.

Malignancies of almost any type and location in the body can metastasize to the neck. The most common are thyroid malignancies. In adolescents, carcinomas, especially those arising in the nasopharynx, may spread to the neck lymphatics.

### REFERENCES

1. Anon JB, Rontal M, Zinreich SJ: Anatomy and Embryology of the Paranasal Sinuses. New York, Thieme, 1996.
2. Bluestone CD, Klein JO: Otitis media and eustachian tube dysfunction. In Bluestone CD, Stool SE, Alper CM, et al (eds): Pediatric Otolaryngology, 4th ed. Philadelphia, WB Saunders, 2003, pp 474-686.
3. Buckwalter JA, Guril NJ, Thomas CG Jr: Cancer of the thyroid in youth. *World J Surg* 1981;5:15-25.
4. Cole RR, Cotton RT: Pediatric malignancies. In Bailey BJ, Johnson JT, Kohut RI, et al (eds): Head and Neck Surgery—Otolaryngology. Philadelphia, JB Lippincott, 1993, p 1388.
5. Cunningham MJ: Neoplasms of the ear and temporal bone. In Wetmore RF, Muntz HR, McGill TJ, et al (eds): Pediatric Otolaryngology: Principles and Practice Pathways. New York, Thieme, 2000, pp 385-408.
6. De la Cruz A, Chandrasekhar SS: Congenital malformations of the temporal bone. In Brackman DE, Shelton C, Arriaga MA (eds): Otolologic Surgery. Philadelphia, WB Saunders, 1994, pp 69-84.
7. Devaney KO, Putzi MJ, Ferlito A, et al: Head and neck Langerhans' cell histiocytosis. *Ann Otol Rhinol Laryngol* 1997;106:526-532.

8. Fierstein J, Thawley S: Lymphomas of the head and neck. *Laryngoscope* 1978;88:582-593.
9. Geiger JD, Thompson NW: Thyroid tumors in children. *Otolaryngol Clin North Am* 1996;4:711-719.
10. Hawkins DB, Crockett DM, Shum TK: Corticosteroids in airway management. *Otolaryngol Head Neck Surg* 1983;91:593-596.
11. Houser SM, Corey JP: Allergic fungal sinusitis: Pathophysiology, epidemiology and diagnosis. *Otolaryngol Clin North Am* 2000;33:399.
12. Hung W, Anderson KD, Chandra R: Solitary thyroid nodules in 71 children and adolescents. *J Pediatr Surg* 1992;27:1407-1409.
13. Jacobs IN, Potsic WP: Glomus tympanicum in infancy. *Arch Otolaryngol Head Neck Surg* 1994;120:203-205.
14. Jahrsdoerfer RA, Yeakley JW, Aguilar EA, et al: Grading system for the selection of patients with congenital aural atresia. *Am J Otol* 1992;13:6-12.
15. Johnson RF, Stewart MG, Wright CC: An evidence-based review of the treatment of peritonsillar abscess. *Otolaryngol Head Neck Surg* 2003;128:332-343.
16. Kairys SW, Olmstead EM, O'Connor GT: Steroid treatment of laryngotracheitis: A meta-analysis of the evidence from randomized trials. *Pediatrics* 1989;83:683-693.
17. Kessler A, Wetmore RF, Marsh RR: Childhood epiglottitis in recent years. *Int J Pediatr Otorhinolaryngol* 1993;25:155-162.
18. Kodet R, Fajstavr J, Kabelka Z, et al: Is fetal cellular rhabdomyoma an entity or a differentiated rhabdomyosarcoma? A study of patients with rhabdomyoma of the tongue and sarcoma of the tongue enrolled in the intergroup rhabdomyosarcoma studies I, II and III. *Cancer* 1991;67:2907-2913.
19. Lee YW, Gisser SD: Squamous cell carcinoma of the tongue in a nine-year renal transplant survivor: A case report with a discussion of the risk of development of epithelial carcinoma in renal transplant survivors. *Cancer* 1978;41:1-6.
20. Marcus CL, Omlin KJ, Basinski DJ, et al: Normal polysomnographic values for children and adolescents. *Am Rev Respir Dis* 1992;146:1235-1239.
21. Maurin M, Birtles R, Raoult D: Current knowledge of *Bartonella* species. *Eur J Clin Microbiol Infect Dis* 1997;16:487-506.
22. Millman B, Pellitteri PK: Thyroid carcinoma in children and adolescents. *Arch Otolaryngol Head Neck Surg* 1995;121:1261-1264.
23. Neault MW: Pediatric audiology. In Wetmore RF, Muntz HR, McGill TJ, et al (eds): *Pediatric Otolaryngology: Principles and Practice Pathways*. New York, Thieme, 2000, pp 183-202.
24. Paradise JL, Bluestone CD, Bachman RZ, et al: Efficacy of tonsillectomy for recurrent throat infection in severely affected children: Results of parallel randomized and non-randomized clinical trials. *N Engl J Med* 1984;310:674-683.
25. Pichichero ME: First-line treatment of otitis media. In Alper CM, Bluestone CD, Casselbrant ML, et al (eds): *Advanced Therapy of Otitis Media*. Hamilton, ON, BC Decker, 2004, p 32.
26. Poje CP, Rechtweg JS: Structure and function of the temporal bone. In Wetmore RF, Muntz HR, McGill TJ, et al (eds): *Pediatric Otolaryngology: Principles and Practice Pathways*. New York, Thieme, 2000, pp 127-146.
27. Potsic WP, Cotton RT, Handler SD (eds): *Surgical Pediatric Otolaryngology*. New York, Thieme, 1997, pp 18-59, 106-109, 188-191, 196-205.
28. Quie PG, Pierce HC, Wannamaker LW: Influence of penicillin-producing staphylococci and the eradication of group A streptococci from the upper respiratory tract by penicillin treatments. *Pediatrics* 1966;37:467-476.
29. Radkowski D, McGill TJ, Healhy GB, et al: Angiofibroma: Changes in staging and treatment. *Arch Otolaryngol Head Neck Surg* 1996;122:122-129.
30. Richardson MA: Regional and intracranial complications of sinuses. In Wetmore RF, Muntz HR, McGill TJ, et al (eds): *Pediatric Otolaryngology: Principles and Practice Pathways*. New York, Thieme, 2000, pp 487-496.
31. Torsiglieri AJ, Tom LWC, Ross A, et al: Pediatric neck masses: Guidelines for evaluation. *Int J Pediatr Otorhinolaryngol* 1988;16:199-210.
32. Wetmore RF, Mahboubi S, Soyupak SK: Computed tomography in the evaluation of pediatric neck infections. *Otolaryngol Head Neck Surg* 1998;119:624-627.
33. Woolley AL, Lusk RP: Pediatric cochlear implantation. In Wetmore RF, Muntz HR, McGill TJ, et al (eds): *Pediatric Otolaryngology: Principles and Practice Pathways*. New York, Thieme, 2000, pp 359-370.