

Growth Modulation for the Treatment of Juvenile Hallux Valgus: A Systematic Review of Literature

Muadh AlZeedi¹, J Patrick Park², Yousef Marwan³, Khaled Mousa Abu-Dalu⁴, Reggie Hamdy⁵, Chantal Janelle⁶

Received on: 21 August 2022; Accepted on: 20 April 2023; Published on: 31 May 2023

ABSTRACT

Background: Juvenile hallux valgus (JHV) is a forefoot deformity that causes pain and functional limitation. Treatment poses a challenge in terms of the optimal technique and timing of intervention. A systematic review of the literature on the use of growth modulation in treating JHV was conducted.

Materials and methods: The literature review was performed using PubMed and EMBASE searches for articles investigating growth modulation in the treatment of JHV published before December 1st, 2021. Seven articles were included in the final review that matched the inclusion and exclusion criteria. The primary outcomes included the degree of correction of hallux valgus angle and intermetatarsal angle. A qualitative assessment of the articles was done due to the heterogeneity of the growth modulation methods used in these articles.

Results: A total of 135 feet from 78 patients were included from the reviewed articles. Growth modulation methods included temporary screw lateral hemiepiphyseodesis of the first metatarsal, lateral drilling hemiepiphyseodesis of the first metatarsal, and a trephine plug removal of the lateral epiphysis followed by cancellous bone graft insertion. The degree of correction of the hallux valgus and intermetatarsal angles were found to be statistically significant in all studies, regardless of the technique.

Conclusion: Growth modulation for JHV by lateral hemiepiphyseodesis using minimally invasive techniques produced favourable radiologic outcomes with some evidence of clinical improvement. Larger, prospective and comparative studies with objective clinical outcome measures may further consolidate this surgical approach as a mean to treating this deformity.

Keywords: Epiphyseodesis, Growth modulation, Hemiepiphyseodesis, Juvenile hallux valgus, Paediatric hallux valgus.

Strategies in Trauma and Limb Reconstruction (2023): 10.5005/jp-journals-10080-1579

INTRODUCTION

Hallux valgus (HV) is a complex deformity of the forefoot involving the first ray; it is characterised by valgus deviation of the proximal phalanx and varus deviation of the metatarsal producing an apex of deformity at the first metatarsophalangeal joint. Hallux valgus in children, also known as juvenile hallux valgus (JHV), is a relatively uncommon deformity that may cause progressively worsening pain.¹ The exact pathophysiology of JHV is not well understood, but a strong hereditary component has been demonstrated in the literature.^{2,3}

Treatment for JHV is controversial due to limited data supporting any specific intervention. There are no studies which compare surgical or non-surgical treatment. The surgical options are often pursued in symptomatic patients when conservative management fails. Osteotomies in skeletally immature patients showed unacceptable rates of recurrence of the deformity and unsatisfactory outcomes.^{2,4-8} Alternatively, various techniques of growth modulation have been described, including, but not limited to, temporary screw lateral hemiepiphyseodesis, lateral drilling hemiepiphyseodesis and lateral hemiepiphyseal stapling.

Lateral hemiepiphyseodesis of the first metatarsal is emerging as a good option for treating symptomatic patients with HV who have not yet reached skeletal maturity. The described techniques are relatively simple and have low complication rates.⁹ The principle was first described in 1951 by Ellis.¹⁰ Since then, the principle of growth modulation has been utilised variously in treating JHV. Despite the favourable outcomes reported in some studies, the sample sizes are small and lack long-term outcome measurements.¹¹⁻¹⁴ The objective

^{1,2,4-6}Department of Pediatric Orthopaedic Surgery, Shriners Hospital for Children; Division of Pediatric Orthopaedic Surgery, Department of Pediatric Surgery, McGill University Health Centre, Montreal, Quebec, Canada

³Department of Surgery, College of Medicine, Health Sciences Centre, Kuwait University, Kuwait City, Kuwait

Corresponding Author: Muadh AlZeedi, Department of Pediatric Orthopaedic Surgery, Shriners Hospital for Children; Division of Pediatric Orthopaedic Surgery, Department of Pediatric Surgery, McGill University Health Centre, Montreal, Quebec, Canada, Phone: +1 4389229856, e-mail: muadh.1082@gmail.com

How to cite this article: AlZeedi M, Park JP, Marwan Y, *et al.* Growth Modulation for the Treatment of Juvenile Hallux Valgus: A Systematic Review of Literature. *Strategies Trauma Limb Reconstr* 2023;18(1):51-55.

Source of support: Nil

Conflict of interest: None

of this study was to perform a systematic review of the literature for JHV treated with growth modulation techniques.

MATERIALS AND METHODS

Two authors (MA and JPP) performed independent PubMed and EMBASE database searches for articles on growth modulation for the treatment of JHV, published on or before December 1, 2021. The following subject headings and related key terms were used: "juvenile hallux valgus" or "pediatric (paediatric) hallux valgus", "growth modulation", "hemiepiphyseodesis" or "hemiepiphyseodesis",

“epiphysiodesis” or “epiphysiodesis”. The exact search strategy was as follows: ((juvenile) OR (pediatric) OR (paediatric)) AND ((Hallux Valgus) OR (bunion)) AND ((Screw) OR (growth modulation) OR (hemiepiphyodesis) OR (epiphysiodesis) OR (epiphysiodesis) OR (hemiepiphyodesis)).

Inclusion criteria for the systematic review consisted of: (i) all levels of evidence, (ii) skeletally immature patients, (iii) hallux valgus treated with growth modulation and (iv) English language of publication. Exclusion criteria included: (i) review articles, (ii) conference abstracts, (iii) articles available in abstract format only (full-text not available online) and (iv) JHV treated with methods other than growth modulation (e.g., metatarsal osteotomy).

The titles and abstracts were screened by the two authors independently for their eligibility for inclusion. Articles considered to meet the criteria were reviewed in full by the same two authors independently. Subsequently, pertinent information from the included articles were retrieved and entered into a Microsoft Excel spreadsheet (Microsoft Excel for Mac, Version 16.4, Microsoft, Redmond, WA, USA). These included article information (author, year of publication, study design, level of evidence and sample size), patient demographics and clinical characteristics (age, pre-operative hallux valgus angle (HVA)), pre-operative intermetatarsal angle (IMA), method of growth modulation and post-operative follow-up data (duration of follow-up, degree of correction of HVA, degree of correction of IMA, complications, revision rate and functional outcome measures). All studies performed HVA and IMA measurements on pre-operative and post-operative plain radiographs.

The primary outcomes sought were the degree of correction of HVA and IMA whereas secondary outcomes included complications, revision rate and functional outcome measures. Due to the small number of articles available in literature and significant heterogeneity in the method of growth modulation utilised in the articles, a meta-analysis was not feasible; instead, a qualitative assessment of the identified articles was performed.

RESULTS

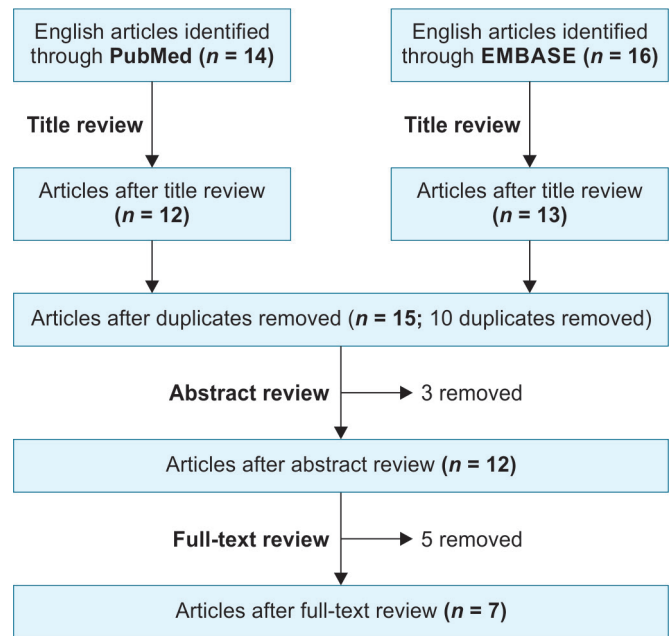
Systematic Review and Article Characteristics

The systematic review process is highlighted in **Flowchart 1**. A search of PubMed and EMBASE databases yielded 14 and 16 articles, respectively. After the title review, 12 and 13 articles were retained from the PubMed and EMBASE databases, respectively. Of these, 10 articles were duplicates and were removed. The resulting 15 articles underwent abstract review, which led to the exclusion of 3 articles. Five additional articles were removed after full-text review, leaving 7 articles for the final review (**Flowchart 1**). The two reviewers (MA and JPP) had no disagreements throughout all stages of the systematic review. Among the 7 articles, 4 were retrospective case series, 2 were case reports and 1 was a prospective cohort study. Five of the 8 articles were published after the year 2000. All the articles were of level IV evidence. A total of 135 feet from 78 patients were presented in these articles (**Table 1**).

Patient Demographics and Clinical Characteristics (**Table 1**)

All studies except for one (Ribotsky et al.¹⁵) had the mean age of study participants reported between 10 and 12 years of age. Across the studies, the mean preoperative HVA ranged from 25.1° to 34.5°. The mean preoperative HVA was not reported in one study – Ribotsky et al.¹⁵ The mean preoperative inter-metatarsal

Flowchart 1: Flowchart of article selection



angle (IMA) ranged from 11.9° to 15.5°. The preoperative IMA was not reported in one study.¹⁶

Procedure Details (**Table 1**)

AlFarii et al.¹⁷ and Schlickewei et al.¹³ utilised temporary screw lateral hemiepiphyodesis of the first metatarsal (MT1). Chiang et al.¹⁸ also performed this technique in addition to the medial percutaneous drilling hemiepiphyodesis of the first proximal phalanx. Therefore, temporary screw lateral hemiepiphyodesis of the MT1 was the most common procedure for growth modulation, performed in 66% of the cases (57 patients, 99 feet). Lateral drilling hemiepiphyodesis of the MT1 was the second most commonly performed procedure and used in 22% of the cases (19 patients, 33 feet).

In the two case reports, a removal of a trephine plug from the lateral hemi-epiphysis followed by cancellous bone grafting was performed (2 patients, 3 feet).^{15,16} Due to the very small sample size, this technique was excluded from the qualitative assessment.

Clinical Outcomes (**Table 1**)

The mean follow-up duration across the types of studies ranged from 24.7 months (SD 13.4 months) to 50 months (range 19–90 months). In those that utilised temporary screw lateral hemiepiphyodesis of the MT1,^{13,17,18} the mean corrections of the HVA were 3.2 ± 4.5° (SD),¹⁷ 4.7 ± 4.1°,¹⁸ and 5.5 ± 7.4°.¹³ The mean corrections of IMA were 2.0 ± 1.8°,¹⁷ 2.2 ± 2.0°,¹⁸ and 4.0 ± 5.4°.¹³ These were all statistically significant corrections of HVA and IMA ($p < 0.05$). In the studies that performed lateral drilling hemiepiphyodesis of the MT1,^{11,12} the mean corrections of HVA were 3.5 ± 4.4°,¹¹ and 4°.¹² The mean corrections of IMA were 2.3 ± 1.7°,¹¹ and 2°,¹² also representing statistically significant corrections of HVA and IMA ($p < 0.05$).

Among the three studies with temporary screw lateral hemiepiphyodesis, complications were reported in two studies. AlFarii et al.¹⁷ reported that 17.3% of study participants experienced symptomatic and uncorrected deformities, whereas 4.3% of cases had screw migration. Schlickewei et al.¹³ reported tenderness over the screw head in 7.7% of participants, as well as screw migration

Table 1: Summary of articles included

Author/ Year	Study design (Level of evidence)	Sample size [patients (feet)]	Mean age (years ± SD)	Pre-operative hallux valgus angle (degrees ± SD)	Pre-operative inter-metatarsal angle (degrees ± SD)	Method of growth modulation	Mean follow-up (months ± SD)	Mean correction of hallux valgus angle (degrees ± SD)	Mean correction of intermetatarsal angle (degrees ± SD)	Complications	Revision rate (%)	Functional outcome measures
Al Farifi, 2021 ¹⁷	Retrospective case series (IV)	14 (23)	10.6 ± 1.8	30.9 ± 6.7	14.6 ± 2.3	Temporary screw lateral hemiepiphysiodesis of MT1	24.7 ± 13.4	3.2 ± 4.5*	2.0 ± 1.8*	Symptomatic uncorrected deformity (17.3%), screw migration (4.3%)	21.7	NR
Chiang, 2019 ¹⁸	Retrospective case series (IV)	21 (37)	12.0 ± 1.3	25.1 ± 4.8	12.3 ± 2.4	Temporary screw lateral hemiepiphysiodesis of MT1 + medial percutaneous drilling hemiepiphysiodesis of PP1	35.1 ± 6.0	4.7 ± 4.1*	2.2 ± 2.0*	None	0	AOFAS score improved 68.7 → 85.2*
Davids, 2007 ¹¹	Retrospective case series (IV)	7 (11)	10.3 (range 9.6-11.1)	34.6 ± 6.3	15.5 ± 1.8	Lateral drilling hemiepiphysiodesis of MT1	50 (range 19-90)	3.5 ± 4.4*	2.3 ± 1.7*	Minimally displaced intraarticular fracture through base of MT1 (9.1%)	0	NR
Ribotsky, 1993 ¹⁵	Case report (IV)	1 (1)	9	NR	11.9	Trepine plug removal of lateral hemiepiaphysis + cancellous bone allograft	12	NR	2.9	None	0	NR
Sabah, 2018 ¹²	Prospective cohort study (IV)	12 (22)	10 (range 9-12)	26 (range 15-40)	13 (range 12-17)	Lateral drilling hemiepiphysiodesis of MT1	42 (range 24-60)	4*	2*	None	0	HMIS score improved 56 → 92*
Schlickewei, 2018 ¹³	Retrospective case series (IV)	22 (39)	11.1 ± 1.4	26.5 ± 6.6	14.1 ± 5.4	Temporary screw lateral hemiepiphysiodesis of MT1	27.8 ± 9.9	5.5 ± 7.4*	4.0 ± 5.4*	Tenderness over screw head (7.7%), screw migration (5.1%)	12.8	NR
Sheridan, 1987 ¹⁶	Case report (IV)	1 (2)	11.9	34.5	NR	Trepine plug removal of lateral hemiepiaphysis + cancellous bone autograft	52	7.5	NR	NR	NR	NR

*Statistically significant difference ($p < 0.05$) AOFAS, The American Orthopaedic Foot and Ankle Score; HMIS, Hallux metatarsophalangeal interphalangeal scale; MT1, first metatarsal; NR, not reported; PP1, first proximal phalanx; SD, standard deviation

in 5.1%. In these two studies, 21.7% and 12.8% of study participants underwent a revision procedure, respectively. No complication was reported by Chiang et al.¹⁸

Lateral drilling hemiepiphyodesis of the MT1 was performed by Davids et al.¹¹ and Sabah et al.¹² In these cases, only one case of minimally displaced intra-articular fracture through the base of the MT1 was reported.

Objective functional outcome measures were reported in two studies. Chiang et al.¹⁸ reported that patients who underwent temporary screw lateral epiphyodesis of the MT1 combined with medial percutaneous drilling hemiepiphyodesis of the first proximal phalanx showed an improvement in the American Orthopaedic Foot and Ankle Score (AOFAS), from 68.7 preoperatively to 85.2 postoperatively ($p < 0.05$). Sabah et al.¹² reported a significant improvement in the Hallux Metatarsophalangeal Interphalangeal Scale (HMIS) score in patients who underwent lateral drilling hemiepiphyodesis of the MT1 (56 preoperatively to 92 postoperatively; $p < 0.05$).

DISCUSSION

Hemiepiphyodesis of the first metatarsal was described as a procedure that takes advantage of the residual growth potential to correct the deformity slowly. Several techniques, either by permanent or temporary fixation of the lateral physis, have been used since the principle was first described in 1951. The outcomes of these techniques are favourable in treating HV in skeletally immature patients despite the variability in the surgical technique used.

Objective assessment of severity of JHV was done by measuring the HVA and IMA on plain radiographs. Regardless of the surgical technique used for growth modulation of the first metatarsal, there is significant correction of both HVA and IMA. However, correlation between the degree of correction and functional outcome measures was lacking.

High recurrence rates of HV deformity have been reported in patients who were treated by osteotomy before skeletal maturity,^{2,4-8} however, there are no studies comparing the outcomes of hemiepiphyodesis and osteotomy procedures. Moreover, the distal metatarsal articular angle (DMAA), if measured to be 10° or more on plain radiographs, is considered pathologic and may be seen in more severe cases of JHV.² Nevertheless, it is unclear whether hemiepiphyodesis of the first metatarsal helps to correct this deformity. If found to be not correctable by hemiepiphyodesis, an increased DMAA may be a contributing factor for persistent deformity or recurrence or both. Although the angular correction may not be clinically significant, this might make future correction osteotomies less complex.

The optimum timing for surgical intervention is uncertain. This is due to the unknown natural history of JHV and the unique growth potential of the metatarsals making an estimate of remaining growth unclear.^{19,20} In fact, Greene et al. showed that the overall plot of the foot multiplier curve for estimating the remaining growth in the foot is vastly different from other body regions.¹⁹ Except for one case report,¹⁵ the mean age of the patients in all studies was between 10 and 12 years. Owing to the progressive deformity in JHV and the uncertain natural history of the condition, some studies advocate for surgical intervention after skeletal maturity.^{2,7,21,22} However, the impact of pain and activity limitations in severe cases of JHV make conservative management, reportedly with suboptimal outcomes, an unsuitable option for treatment.

The correlation between age and the degree of correction achieved was highlighted in three studies where greater correction was observed of the HVA in younger patients.^{13,17,18} This may be due to a larger remaining growth potential in these patients which compensates for the slow rate of correction with hemiepiphyodesis. The metatarsal growth rate slows down and was found to decrease markedly in children as they approach skeletal maturity; therefore, more correction can be achieved with hemiepiphyodesis at a younger age.^{23,24} Interestingly, AlFarii et al.¹⁷ observed worsening of the HV deformity in three patients with comorbidities (periventricular leukomalacia, down syndrome and tight heel cord) despite surgical intervention. Chiang et al.¹⁸ were the only ones who reported on the gender ratio and ages of interventions; they included 9 male (mean age 13.0 years, SD 1.1) and 12 female (mean age 11.2 years, SD 0.9). Documented skeletal maturity at follow-up was only reported by Davids et al.¹¹ Neither of these studies performed subgroup analyses on the impact of these variables on the results or the final outcome. Further studies investigating the correlation between bone age and comorbidities to the degree of correction are needed.

The presence or absence of complications after surgical intervention were reported in six papers. There were no complications in three, while another three had low rates, including screw migration in 5% and one case of fracture of the base of the first metatarsal. Late complications included pain from symptomatic hardware, as was reported by Schlickewei et al.¹³ in 7.7% of cases, while AlFarii et al.¹⁷ reported symptomatic residual deformity in 17.3% of the cases. Regardless of the technique used, complications were relatively uncommon and were likely due to the minimally invasive approach of the technique as compared to the other surgical methods of treating JHV.^{11,13,14,18}

In all the studies, a significant correction of HVA and IMA on the follow-up radiographs was observed regardless of the surgical technique used. Although this may support using growth modulation for treating HV deformity in skeletally immature patients, several limitations have to be taken into consideration. Firstly, the duration of follow-up may not be sufficient to evaluate patient outcomes objectively, given that a significant proportion of participants in the studies had yet to reach skeletal maturity. Secondly, six studies were retrospective case series or cohort studies, and two studies were case reports. The relatively small number of study participants in each study, the significant heterogeneity in the utilised techniques and the lack of objective functional outcome measures prevent the drawing of any conclusions to advocate for one specific technique of growth modulation over another. A well-designed randomised controlled trial with sufficient statistical power will be helpful to determine the optimal method of growth modulation for the treatment of JHV.

CONCLUSION

Growth modulation for HV in skeletally immature patients via lateral hemiepiphyodesis with minimally invasive techniques showed favourable radiologic outcomes with some evidence of clinical improvement. Although the radiologic change is relatively small, this may ease future correction osteotomies of HV deformity. Larger prospective studies with objective clinical outcome measures may further determine the place of this surgical approach as a means to treating this deformity.

ORCID

Yousef Marwan  <https://orcid.org/0000-0001-5450-523X>

REFERENCES

1. Chell J, Dhar S. Pediatric hallux valgus. *Foot Ankle Clin* 2014;19(2): 235–243. DOI: 10.1016/j.fcl.2014.02.007.
2. Coughlin MJ. Juvenile hallux valgus: Etiology and treatment. *Foot Ankle Int* 1995;16(11):682–697. DOI: 10.1177/107110079501601104.
3. Groiso JA. Juvenile hallux valgus. A conservative approach to treatment. *J Bone Joint Surg Am* 1992;74(9):1367–1374. PMID: 1429792.
4. Ball J, Sullivan A. Treatment of the juvenile bunion By Mitchell osteotomy. *Orthopedics* 1985;8(10):1249–1252. DOI: 10.3928/0147-7447-19851001-09.
5. Canale PB, Aronsson DD, Lamont RL, et al. The Mitchell procedure for the treatment of adolescent hallux valgus. A long-term study. *J Bone Joint Surg* 1993;75(11):1610–1618. DOI: 10.2106/00004623-199311000-00005.
6. George HL, Casaletto J, Unnikrishnan PN, et al. Outcome of the scarf osteotomy in adolescent hallux valgus. *J Child Orthop* 2009;3(3): 185–190. DOI: 10.1007/s11832-009-0177-6.
7. Helal B, Gupta SK, Gojaseni P. Surgery for adolescent hallux valgus. *Acta Orthop Scand* 1974;45(1–4):271–295. DOI: 10.3109/17453677408989149.
8. Scranton PEJ, Zuckerman JD. Bunion surgery in adolescents results of Surgical Treatment. *J Pediatr Orthop* 1984;4(1):39–43. DOI: 10.1097/01241398-198401000-00009.
9. Métaizeau JP, Wong-Chung J, Bertrand H, et al. Percutaneous epiphysiodesis using transphyseal screws (PETS). *J Pediatr Orthop* 1998;18(3):363–369. DOI: 10.1097/01241398-199805000-00018.
10. Ellis VH. A method of correcting metatarsus primus varus. *J Bone Joint Surg Br* 1951;33-B(3):415–417. DOI: 10.1302/0301-620x.33b3.415.
11. Davids JR, McBrayer D, Blackhurst DW. Juvenile hallux valgus deformity: Surgical management by lateral hemiepiphysiodesis of the great toe metatarsal. *J Pediatr Orthop* 2007;27(7):826–830. DOI: 10.1097/BPO.0b013e3181558a7c.
12. Sabah Y, Rosello O, Clement JL, et al. Lateral hemiepiphysiodesis of the first metatarsal for juvenile hallux valgus. *J Orthop Surg* 2018;26(3):230949901880113. DOI: 10.1177/2309499018801135.
13. Schlickewei C, Ridderbusch K, Breyer S, et al. Temporary screw epiphysiodesis of the first metatarsal for correction of juvenile hallux valgus. *J Child Orthop* 2018;12(4):375–382. DOI: 10.1302/1863-2548.12.170208.
14. Seiberg M, Green R, Green D. Epiphysiodesis in juvenile hallux abducto valgus. A preliminary retrospective study. *J Am Podiatr Med Assoc* 1994;84(5):225–236. DOI: 10.7547/87507315-84-5-225.
15. Ribotsky B, Nazarian S, Scheuller HC. Epiphysiodesis of the first metatarsal with cancellous allograft. *J Am Podiatr Med Assoc* 1993;83(5):263–266. DOI: 10.7547/87507315-83-5-263.
16. Sheridan LE. Correction of juvenile hallux valgus deformity associated with metatarsus primus adductus using epiphysiodesis technique. *Clin Podiatr Med Surg* 1987;4(1):63–74. PMID: 2949818.
17. AlFarii H, Marwan Y, Algarni N, et al. Temporary screw lateral hemiepiphysiodesis of the first metatarsal for juvenile hallux valgus deformity: A case series of 23 feet. *J Foot Ankle Surg* 2022;61(1):88–92. DOI:10.1053/j.jfas.2021.06.012.
18. Chiang MH, Wang TM, Kuo KN, et al. Management of juvenile hallux valgus deformity: The role of combined hemiepiphysiodesis. *BMC Musculoskelet Disord* 2019;20(1):472. DOI: 10.1186/s12891-019-2867-7.
19. Greene JD, Nicholson AD, Sanders JO, et al. Analysis of serial radiographs of the foot to determine normative values for the growth of the first metatarsal to guide hemiepiphysiodesis for immature hallux valgus. *J Pediatr Orthop* 2017;37(5):338–343. DOI: 10.1097/BPO.0000000000000650.
20. Lovell WW, Winter RB, Weinstein SL, et al. Lovell and Winter's Pediatric Orthopaedics, vol. 2, 7th ed. Wolters Kluwer Health/Lippincott Williams and Wilkins; 2014.
21. Mann RA, Francisco S. Decision making in bunion surgery. *Iowa Orthop J* 1990;10:110–113. PMID: PMC2328776.
22. Myerson M. Hallux valgus. *Foot and Ankle Disorders*. Philadelphia: Saunders; 2000. pp. 213–288.
23. Anderson M, Blais MM, Green WT. Lengths of the growing foot. *J Bone Joint Surg* 1956;38-A(5):998–1000. DOI: 10.2106/00004623-195638050-00004.
24. Anderson M, Blais M, Green WT. Growth of the normal foot during childhood and adolescence. Length of the foot and interrelations of foot, stature, and lower extremity as seen in serial records of children between 1–18 years of age. *Am J Phys Anthropol* 1956;14(2):287–308. DOI: 10.1002/ajpa.1330140221.