

Received: 2017.02.24  
Accepted: 2017.04.03  
Published: 2017.04.22

# Correlation Between Expression of High Temperature Requirement Serine Protease A1 (HtrA1) in Nucleus Pulposus and T2 Value of Magnetic Resonance Imaging

Authors' Contribution:  
Study Design A  
Data Collection B  
Statistical Analysis C  
Data Interpretation D  
Manuscript Preparation E  
Literature Search F  
Funds Collection G

BEG 1 **Dapeng Li**  
CF 2 **Jiawei Yue**  
CD 2 **Lu Jiang**  
EF 1 **Yonghui Huang**  
BD 1 **Jifu Sun**  
AEG 1,2 **Yan Wu**

1 Department of Orthopaedics, Affiliated Hospital of Jiangsu University, Zhenjiang, Jiangsu, P.R. China  
2 Department of Physiology, Medical College of Jiangsu University, Zhenjiang, Jiangsu, P.R. China

**Corresponding Author:** Yan Wu, e-mail: [jb spine123@163.com](mailto:jb spine123@163.com)

**Source of support:** National Natural Science Foundation of China (81601931), Natural Science Foundation of Jiangsu Province (BK20150475) and Key Research and Development Programs of Zhenjiang City (SH2015085)

**Background:** Degrading enzymes play an important role in the process of disc degeneration. The objective of this study was to investigate the correlation between the expression of high temperature requirement serine protease A1 (HtrA1) in the nucleus pulposus and the T2 value of the nucleus pulposus region in magnetic resonance imaging (MRI).


**Material/Methods:** Thirty-six patients who had undergone surgical excision of the nucleus pulposus were examined by MRI before surgery. Pfirrmann grading of the target intervertebral disc was performed according to the sagittal T2-weighted imaging, and the T2 value of the target nucleus pulposus was measured according to the median sagittal T2 mapping. The correlation between the Pfirrmann grade and the T2 value was analyzed. The expression of HtrA1 in the nucleus pulposus was analyzed by RT-PCR and Western blot. The correlation between the expression of HtrA1 and the T2 value was analyzed.

**Results:** The T2 value of the nucleus pulposus region was 33.11–167.91 ms, with an average of 86.64±38.73 ms. According to Spearman correlation analysis, there was a rank correlation between T2 value and Pfirrmann grade ( $P<0.0001$ ), and the correlation coefficient ( $r_s$ )=-0.93617. There was a linear correlation between the mRNA level of HtrA1 and T2 value in nucleus pulposus tissues ( $a=3.88$ ,  $b=-0.019$ ,  $F=112.63$ ,  $P<0.0001$ ), normalized regression coefficient=-0.88. There was a linear correlation between the expression level of HtrA1 protein and the T2 value in the nucleus pulposus tissues ( $a=3.30$ ,  $b=-0.016$ ,  $F=93.15$ ,  $P<0.0001$ ) and normalized regression coefficient=-0.86.

**Conclusions:** The expression of HtrA1 was strongly related to the T2 value, suggesting that HtrA1 plays an important role in the pathological process of intervertebral disc degeneration.

**MeSH Keywords:** **Intervertebral Disc Degeneration • Low Back Pain • Magnetic Resonance Imaging**

**Full-text PDF:** <http://www.medscimonit.com/abstract/index/idArt/904018>

 2282

 2

 7

 33



## Background

Low back pain is a very common clinical problem in spine surgery [1], and about 70% of all people in their lifetime will suffer from low back pain at least once. Lumbar intervertebral disc degeneration is the most common cause of low back pain [2]. The pathological process of intervertebral disc degeneration mainly involves dehydration and fibrosis of the nucleus pulposus (NP), tearing of the annulus fibrosus, and sclerosis of the cartilage endplate [3,4]. Disc degeneration begins in the NP [5]. During the process of disc degeneration, the number of NP cells decreases and the function gradually degenerates [6]; thereafter, aggrecan, type II collagen, and other extracellular matrix, which are synthesized by NP cells to maintain the biological characteristics of NP tissue, are gradually degraded [7,8]. Furthermore, this leads to dehydration, crack formation, and fibrosis of NP tissue [9]. Disappearance of the gel morphology of NP results in a decrease in the capacity of the intervertebral disc to buffer the load and maintain the stability of the spinal column [10,11].

The degree of intervertebral disc degeneration is usually evaluated by use of the Pfirrmann grading system [12], which is based on magnetic resonance imaging (MRI). Pfirrmann grading is a comprehensive assessment of NP, annulus fibrosus signal intensity, and disc height. However, Pfirrmann grading provides grade data, but not quantitative information, which may lead to errors among independent observers [13]. In recent years, scholars [14–16] have assessed the degenerative degree of NP tissue through the MRI T2 value, which can reflect the water, protein, collagen, and other molecular content and the environment in NP tissue.

High temperature requirement serine protease A1 (HtrA1) belongs to the HtrA family of serine proteases, which constitutes a well-conserved group of proteolytic enzymes (HtrA1, 2, 3, and 4). HtrA1 is encoded by a gene located on chromosome 10 (10q26) and the transcription of its gene is highly regulated in both developing and adult tissues [17]. The substrates of HtrA1 include aggrecan, type II collagen, and elastin [18]. Some studies [19,20] found that the expression of HtrA1, which is increased in articular cartilage of osteoarthritis, rheumatoid arthritis, and HtrA1, can promote cartilage matrix degradation. Other studies [21] found that HtrA1 can up-regulate expression of cytokines in a time-dependent manner and suggested that HtrA1 promotes the occurrence and development of intervertebral disc degeneration [22]; however, the relationship between the expression level of HtrA1 and the degree of disc degeneration is largely unknown. Therefore, the present study was designed to explore the correlation between the expression level of HtrA1 in NP tissue and T2 value in the NP region.

**Table 1.** Characteristics of the total patients group.

Characteristic	Value
Sex (M: F)	21: 15
Age (yrs)	59.6±12.1 (18–80)
Segment (N)	
L1/2	2
L2/3	1
L3/4	4
L4/5	18
L5/S1	11
Etiology (N)	
Burst fracture	3
Disc herniation	18
Lumbar instability	8
Spondylolisthesis	7

## Material and Methods

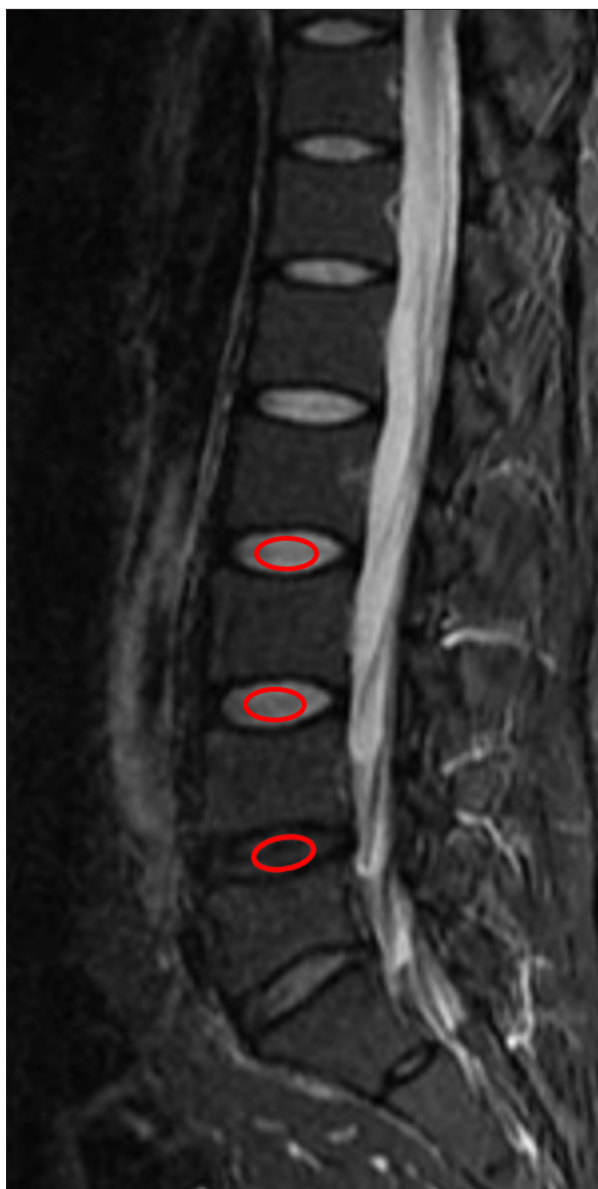### Source of NP tissue

We studied 36 patients with disc herniation, lumbar instability, or other disc degeneration-related diseases, who needed to have NP tissue removed. The operations were performed in our hospital from July 2015 to June 2016. Inclusion criteria were: (1) Single-level disc surgery, (2) MRI must be performed before surgery to determine the Pfirrmann grade, (3) No disc prolapse signs on MRI, (4) Age >18 years, and (5) No use of diatrizoate, methylene blue, or other drugs. Exclusion criteria were: (1) Multiple-level disc surgery, (2) Disc prolapse due to tear in the annulus fibrosus, (3) Intervertebral space infection, vertebra tuberculosis, vertebral tumor, and other diseases, (4) Age <18 years, and (5) Percutaneous endoscopic lumbar discectomy. Information on all 36 patients is listed in Table 1.

During the operation, the NP tissue was removed using NP forceps. Only the core NP tissue was chosen for use in the subsequent RT-PCR and Western blot analysis, as the part of inner annulus fibrosus and outer NP tissue might have been missed. We ensured that the core NP tissue was removed according to intraoperative fluoroscopy showing that the NP forceps were located in the center of the disc.

### Ethics

This study was approved by the Ethics Committee of the Affiliated Hospital of Jiangsu University (No. JDFYLL2015016), was conducted in accordance with the provisions of the



**Figure 1.** Sample image to determine the region of interest (ROI). In a median sagittal T2-weighted image, the center portion of NP with some distance from the bone edge was determined as ROI (red circle).

Declaration of Helsinki, and all 36 patients signed informed consent.

### MRI

All 36 patients underwent MRI scans before surgery. Patients were in supine position inside a 3.0 T MRI scanner (Magnetom TrioTim, Siemens, Erlangen, Germany) with the lumbar region centered over a lumbar surface coil. Sagittal T2-weighted images were obtained using the following settings: fast spin echo sequence, TR=3500 ms, TE=99.0 ms, section thickness=4.0 mm,

**Table 2.** Primers used in RT-PCR.

Gene	Primer sequences	Segment size
HtrA1	Forward: 5'-GACTACATCCAGACCGACGC-3' Reverse: 5'-GCTTTTCCTTGGCCTGTCG-3'	185 bp
$\beta$ -actin	Forward: 5'-TGACGTGGACATCCGCAAAG-3' Reverse: 5'-CTGGAAGGTGACAGCGAGG-3'	235 bp

and field of view=280 mm. Two spine surgeons and 1 radiologist independently performed Pfirrmann grading of the target intervertebral discs. When the grading results were inconsistent, the 3 experts discussed the case and reached a consensus.

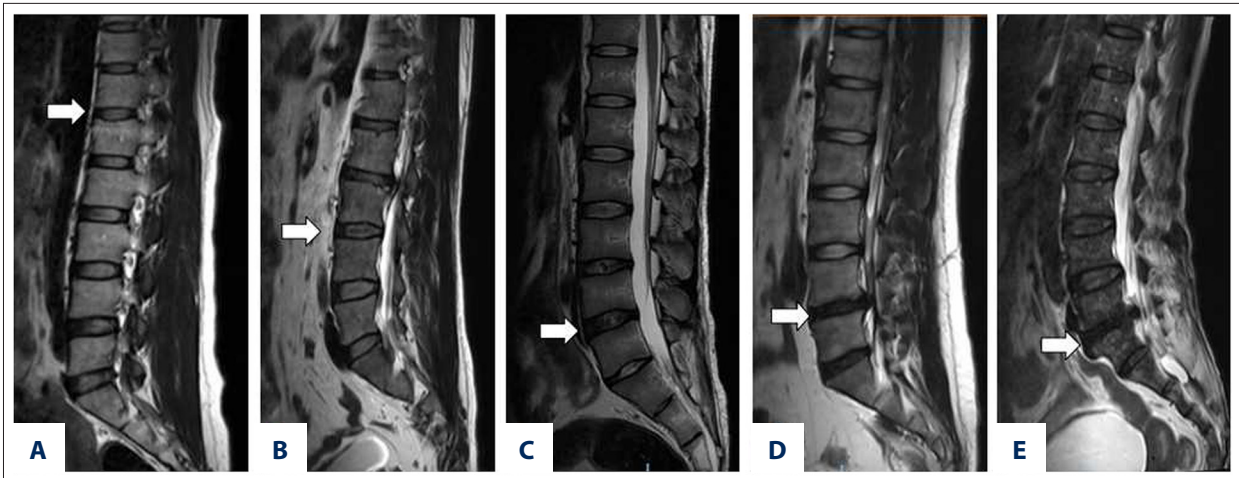
Median sagittal T2 mapping images were obtained using the following settings: TR=1200 ms, TE=13.8, 27.6, 41.4, 55.2, 69.0 ms, section thickness=4.0 mm, and field of view=280 mm. The core region of the NP was set to the region of interest (ROI) as recommended previously [13,23] (Figure 1), and the T2-value of the ROI was measured and recorded.

### RT-PCR

Total RNA was extracted from the NP tissue using 1 ml Trizol (Invitrogen, Carlsbad, CA, USA). Total RNA was reverse-transcribed into cDNA using the Thermo OneStep RT-PCR Kit (Thermo Scientific, Waltham, MA, USA) following the manufacturer's protocol. A 1- $\mu$ l volume of cDNA template was used for each RT-PCR reaction, and sequences were amplified using Taq DNA polymerase (Thermo Scientific, Waltham, MA, USA) and primers (Table 2) designed and synthesized by Sangon Biotech (Shanghai, CHN). The PCR conditions used were specific to each target transcript. HtrA1: denaturation for 3 min at 94°C, followed by 35 cycles of 94°C for 30 s, 59°C for 30 s, and 72°C for 45 s, and a final extension at 72°C for 7 min.  $\beta$ -actin: denaturation for 3 min at 94°C, followed by 30 cycles of 94°C for 30 s, 57°C for 30 s, and 72°C for 45 s, and a final extension at 72°C for 7 min. PCR products were separated on 1% agarose gel (Gene, Hong Kong, CHN) and stained with 0.5  $\mu$ g/ml EB. The bands (grey scale) were analyzed by use of an imaging analysis system (Syngene, Cambridge, UK).

### Western blot analysis

NP tissues were homogenized and lysed in RIPA buffer supplemented with proteinase inhibitors. Equal amounts of total protein were loaded and separated on 12% SDS-polyacrylamide gel. Following electrophoresis, the proteins were transferred to polyvinylidene difluoride membrane (Millipore, USA), blocked in 5% (w/v) non-fat milk, and incubated with the primary antibodies. Membranes were incubated with monoclonal antibody against  $\beta$ -actin (Santa Cruz, USA) and HtrA1 (Santa Cruz, USA)



**Figure 2.** Representative T2-weighted images of Pfirrmann grades I–V. (A) Pfirrmann grade I (T12/L1, white arrow); (B) Pfirrmann grade II (L3/4, white arrow); (C) Pfirrmann grade III (L4/5, white arrow); (D) Pfirrmann grade IV (L4/5, white arrow); (E) Pfirrmann grade V (L5/S1, white arrow).

at 4°C overnight. The membrane was washed with Tris-buffered saline/Tween 3 times. After washing, HRP-conjugated secondary antibody was added for 1 h at 37°C. Detection was performed with enhanced chemiluminescence and relevant blots were quantified by densitometry using the accompanying computerized image analysis program.

### Statistical analyses

Statistical analyses were performed using Statistical Package for Social Sciences System Version 14.0 (SPSS, Chicago, IL, USA). The correlation between T2 value and Pfirrmann grade was analyzed by Spearman correlation. The correlation between HtrA1 mRNA and protein expression level and T2 value was analyzed by linear regression analysis. A *P* value <0.05 was considered statistical significance.

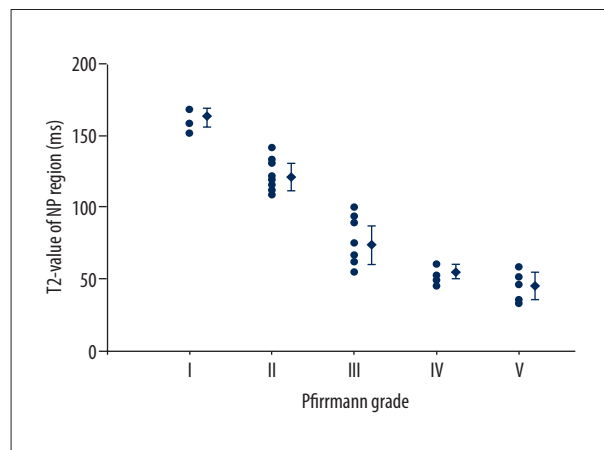
## Results

### Pfirrmann grade

According to Pfirrmann grading criteria based on T2-weighted MRI, there were 3 cases of Pfirrmann grade I (3 young donors with vertebra burst fractures), 10 cases of grade II, 11 cases of grade III, 7 cases of grade IV, and 5 cases of grade V in all the 36 intervertebral discs (Figure 2). The Kappa test showed excellent agreement among the 3 assessors (Kappa=0.817).

### Correlation between the T2 value of NP region and Pfirrmann grade

The average T2 value of NP region (ROI) was  $86.64 \pm 38.73$  ms (range: 33.11–167.91 ms). There was a rank correlation

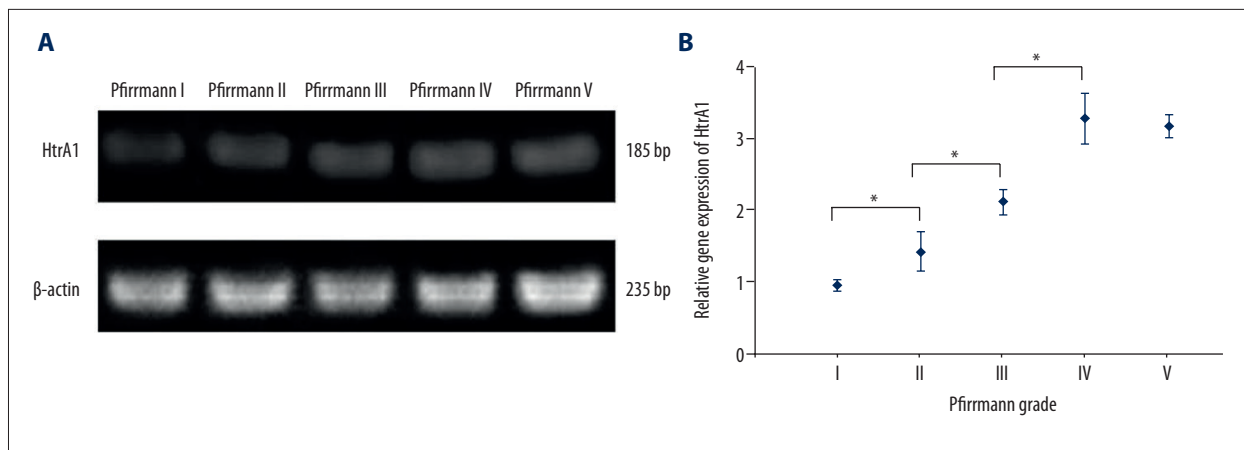


**Figure 3.** Correlation between the T2 value of NP region and Pfirrmann grade. The T2 value of Pfirrmann grade I to V was  $159.77 \pm 7.48$  ms,  $123.00 \pm 10.61$  ms,  $75.33 \pm 15.59$  ms,  $50.73 \pm 5.63$  ms, and  $45.17 \pm 10.72$  ms, respectively. There was a rank correlation between T2 value and Pfirrmann grade ( $P < 0.0001$ ) according to Spearman correlation analysis ( $r_s = -0.93617$ ).

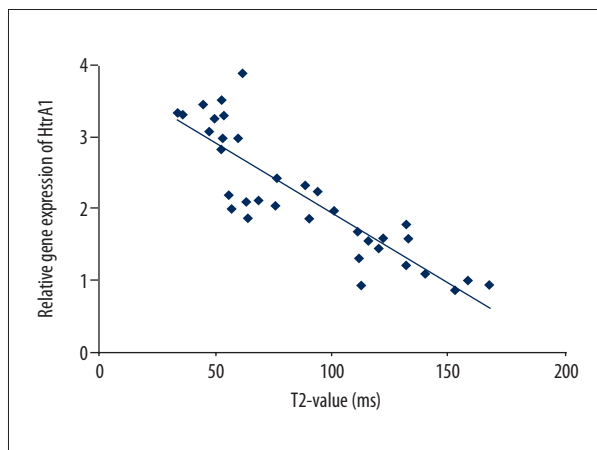
between T2 value and Pfirrmann grade ( $P < 0.0001$ ) according to Spearman correlation analysis, and the correlation coefficient ( $r_s$ ) was  $-0.93617$  (Figure 3).

### Correlation between T2-value of NP region and the HtrA1 mRNA level of NP tissue

Our data show the correlation between T2-value and Pfirrmann grade. We then analyzed the correlation between T2 value of the NP region (ROI) and the mRNA expression level of HtrA1 in NP tissue. The mRNA level of HtrA1 in NP tissue increased with increasing Pfirrmann grade. The difference was statistically



**Figure 4.** (A, B) The relative gene expression of HtrA1 of NP at different Pfirrmann grades. The relative gene expression of HtrA1 of Pfirrmann grade I to V was  $0.94\pm 0.07$ ,  $1.43\pm 0.28$ ,  $2.11\pm 0.18$ ,  $3.28\pm 0.36$ , and  $3.19\pm 0.16$ , respectively. The gene expression of HtrA1 increased with increasing Pfirrmann grade. \*  $P<0.05$ .



**Figure 5.** Correlation between T2 value and the relative gene expression of HtrA1. The average T2 value of NP region (ROI) was  $86.64\pm 38.73$  ms (range: 33.11–167.91 ms) and the average relative gene expression of HtrA1 was  $2.20\pm 0.86$  (range: 0.87–3.33). There was a linear correlation between the mRNA level and the T2 value ( $a=3.88$ ,  $b=-0.019$ ,  $F=112.63$ ,  $P<0.0001$ ) according to linear regression analysis.

significant among groups ( $P<0.05$ ); however, the difference between the Pfirrmann grade IV group and Pfirrmann grade V group was not statistically significant ( $t=0.50$ ,  $P=0.6256$ ) (Figure 4). There was a linear correlation between the mRNA level and the T2 value ( $a=3.88$ ,  $b=-0.019$ ,  $F=112.63$ ,  $P<0.0001$ ) according to linear regression analysis, and the normalized regression coefficient was  $-0.88$  (Figure 5).

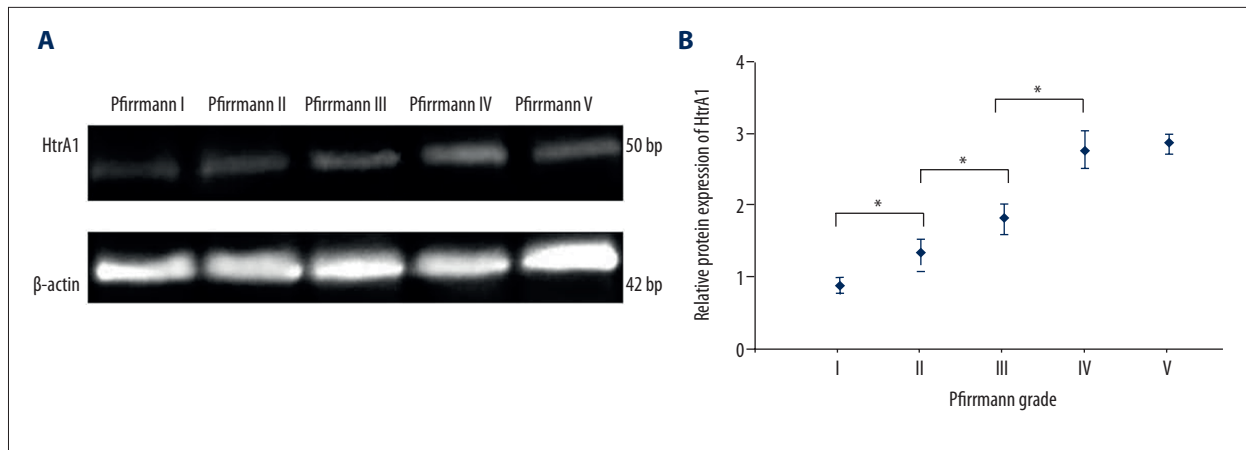
#### Correlation between T2 value of NP region and HtrA1 protein level of NP tissue

Similar data were also found in the correlation between T2 value of the NP region (ROI) and the HtrA1 protein level of NP tissue. The protein level of HtrA1 in NP tissue also increased with increasing Pfirrmann grade. Differences were also statistically significant among groups ( $P<0.05$ ), except for the difference between the Pfirrmann grade IV group and the Pfirrmann grade V group ( $t=-0.54$ ,  $P=0.6028$ ) (Figure 6). There was a linear correlation between protein level and the T2 value ( $a=3.30$ ,  $b=-0.016$ ,  $F=93.15$ ,  $P<0.0001$ ) according to linear regression analysis, and the normalized regression coefficient was  $-0.86$  (Figure 7).

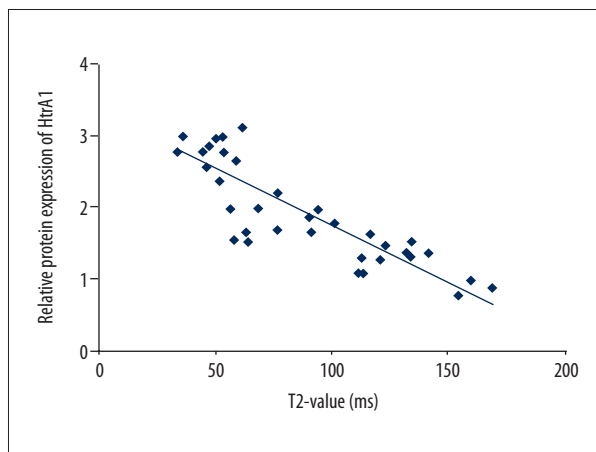
#### Discussion

Intervertebral discs consist of the annulus fibrosus, NP, and the upper and lower endplate cartilage [24]. In the pathological process of disc degeneration, there is an imbalance between synthesis and degradation of extracellular matrix in the NP, especially involving aggrecan and type II collagen, resulting in decreased water content in NP tissue, so NP tissue gradually loses its original gel-like morphology and fibrous changes gradually occur. The disappearance of the elastic state of the NP leads to reduced buffer load capacity. Subsequently, the annulus fibrosus tears due to abnormal stress, decreased disc height, and calcification of endplate cartilage. During the process of disc degeneration, the structure and function of the NP are dominant and key [24]. Therefore, this study chose the NP rather than the annulus fibrosus or the endplate as the research focus.

HtrA1 was originally isolated from fibroblasts as a transformation-sensitive protein due to its downregulation by SV40 [25]. The



**Figure 6.** (A, B) The relative protein expression of HtrA1 of NP at different Pfirrmann grades. The relative protein expression of HtrA1 of Pfirrmann grade I to V was  $0.89 \pm 0.11$ ,  $1.35 \pm 0.17$ ,  $1.82 \pm 0.21$ ,  $2.79 \pm 0.26$ , and  $2.87 \pm 0.14$ , respectively. The relative protein expression of HtrA1 increased with increasing Pfirrmann grade. \*  $P < 0.05$ .



**Figure 7.** Correlation between T2 value and the relative protein expression of HtrA1. The average T2 value of NP region (ROI) was  $86.64 \pm 38.73$  ms (range: 33.11–167.91 ms) and the average relative protein expression of HtrA1 was  $1.95 \pm 0.71$  (range: 0.79–3.01). There was a linear correlation between the protein level and the T2 value ( $a=3.30$ ,  $b=-0.016$ ,  $F=93.15$ ,  $P < 0.0001$ ) according to linear regression analysis.

C-terminal is a highly-conserved trypsin-like catalytic domain and PDZ domain, and the N-terminal is an insulin-like growth factor-binding domain and a Kazal type protease inhibitor domain [26]. Several studies [19,20] found the expression of HtrA1 increased in articular cartilage tissue in patients with osteoarthritis or rheumatoid arthritis, and it was reported that HtrA1 can promote cartilage matrix degradation, suggesting that HtrA1 plays an important role in joint degeneration. In addition, another study [27] suggested that a single-nucleotide polymorphism in the promoter region of the HtrA1 gene was associated with intervertebral disc degeneration, and people without the G allele are more prone to disc degeneration. Therefore, HtrA1 may play an important role in the pathological process of intervertebral disc degeneration.

MRI is helpful for diagnosis of spondylodiscitis, sacroiliitis, and other spinal disorders [28,29]. MRI is also one of the most widely used and accurate methods to evaluate the degree of disc degeneration. It can reflect the water content and morphological changes of intervertebral discs [13]. The degree of disc degeneration is divided into grades I-V by the Pfirrmann grading system [12], primarily based on changes in signal intensity, distinction between nucleus and annulus fibrosis, and disc height on MRI T2-weighted images. Pfirrmann grading is a subjective rating system and can provide a semiquantitative assessment of disc degeneration [30]. However, it lacks sensitivity to change and has only moderate-to-good reliability [31,32]. To overcome these limitations, quantitative measures (such as T2 and apparent diffusion coefficient mappings) of disc degeneration on MRI have been developed and used. Schultz et al. [33] found that T2 value can reflect the biochemical changes in the disc. Trattnig et al. [30] also reported that T2 quantitation provides a more sensitive and robust approach for detecting and characterizing the early stage of disc degeneration. Therefore, our study investigated the correlation between the expression of HtrA1 and the T2 value of ROI. To ensure the accuracy of the results of this study, a good consistency of the ROI with the removed NP tissue should be achieved. So, in this study, the center portion of NP with some distance from the bone edge was determined as ROI according to Wang's reports [13,23], and only the core NP tissue was chosen for biochemical analysis.

Tiaden et al. [21] found that expression levels of HtrA1 were significantly correlated ( $r=0.375$ ,  $P=0.024$ ) with Pfirrmann grade. Consistent with Tiaden's findings, our study also found that the mRNA and protein level of HtrA1 of NP tissue increased with increasing Pfirrmann grade. We also found the expression level of HtrA1 decreased with increasing T2 value, and there was a linear correlation between HtrA1 level and the T2 value,

suggesting that there was a correlation between HtrA1 and the degree of intervertebral disc degeneration, and HtrA1 may play an important role in the pathological process of intervertebral disc degeneration. In addition, our results also indicated that degradation of extracellular matrix such as aggrecan and type II collagen may be associated with an increased expression of HtrA1. Therefore, we intend to explore the mechanism by which HtrA1 affects the underlying cause of intervertebral disc degeneration, such as matrix metalloproteinases and a disintegrin and metalloproteinase with thrombospondin motifs, which are 2 major extracellular matrix-degrading enzymes.

## References:

- Ye S, Ju B, Wang H, Lee KB: Bone morphogenetic protein-2 provokes interleukin-18-induced human intervertebral disc degeneration. *Bone Joint Res*, 2016; 5: 412–18
- Zheng CJ, Chen J: Disc degeneration implies low back pain. *Theor Biol Med Model*, 2015; 12: 24
- Alini M, Roughley PJ, Antoniou J et al: A biological approach to treating disc degeneration: Not for today, but maybe for tomorrow. *Eur Spine J*, 2002; 11(Suppl. 2): 215–20
- Yang X, Li X: Nucleus pulposus tissue engineering: A brief review. *Eur Spine J*, 2009; 18: 1564–72
- Wang C, Auerbach JD, Witschey WR et al: Advances in magnetic resonance imaging for the assessment of degenerative disc disease of the lumbar spine. *Semin Spine Surg*, 2007; 19: 65–71
- Choi H, Johnson ZI, Risbud MV: Understanding nucleus pulposus cell phenotype: A prerequisite for stem cell based therapies to treat intervertebral disc degeneration. *Curr Stem Cell Res Ther*, 2015; 10: 307–16
- Park JY, Kuh SU, Park HS, Kim KS: Comparative expression of matrix-associated genes and inflammatory cytokines-associated genes according to disc degeneration: Analysis of living human nucleus pulposus. *J Spinal Disord Tech*, 2011; 24: 352–57
- Mayer JE, Iatridis JC, Chan D et al: Genetic polymorphisms associated with intervertebral disc degeneration. *Spine J*, 2013; 13: 299–317
- Li Z, Yu X, Liang J et al: Leptin downregulates aggrecan through the p38-ADAMST pathway in human nucleus pulposus cells. *PLoS One*, 2014; 9: e109595
- Tian Y, Yuan W, Li J et al: TGFbeta regulates Galectin-3 expression through canonical Smad3 signaling pathway in nucleus pulposus cells: Implications in intervertebral disc degeneration. *Matrix Biol*, 2016; 50: 39–52
- Iatridis JC, Nicoll SB, Michalek AJ et al: Role of biomechanics in intervertebral disc degeneration and regenerative therapies: What needs repairing in the disc and what are promising biomaterials for its repair? *Spine J*, 2013; 13: 243–62
- Pfirrmann CW, Metzendorf A, Zanetti M et al: Magnetic resonance classification of lumbar intervertebral disc degeneration. *Spine*, 2001; 26: 1873–78
- Rim DC: Quantitative Pfirrmann disc degeneration grading system to overcome the limitation of Pfirrmann disc degeneration grade. *Korean J Spine*, 2016; 13: 1–8
- Chai JW, Kang HS, Lee JW et al: Quantitative analysis of disc degeneration using axial T2 mapping in a percutaneous annular puncture model in rabbits. *Korean J Radiol*, 2016; 17: 103–10
- Zhang X, Yang L, Gao F et al: Comparison of T1rho and T2\* relaxation mapping in patients with different grades of disc degeneration at 3T MR. *Med Sci Monit*, 2015; 21: 1934–41
- Chen C, Jia Z, Han Z et al: Quantitative T2 relaxation time and magnetic transfer ratio predict endplate biochemical content of intervertebral disc degeneration in a canine model. *BMC Musculoskelet Disord*, 2015; 16: 157
- Stuqui B, Conceicao AL, Termini L et al: The differential role of HTRA1 in HPV-positive and HPV-negative cervical cell line proliferation. *BMC Cancer*, 2016; 16: 840
- Tiaden AN, Richards PJ: The emerging roles of HTRA1 in musculoskeletal disease. *Am J Pathol*, 2013; 182: 1482–88
- Grau S, Richards PJ, Kerr B et al: The role of human HtrA1 in arthritic disease. *J Biol Chem*, 2006; 281: 6124–29
- Wu J, Liu W, Bemis A et al: Comparative proteomic characterization of articular cartilage tissue from normal donors and patients with osteoarthritis. *Arthritis Rheum*, 2007; 56: 3675–84
- Tiaden AN, Klawitter M, Lux V et al: Detrimental role for human high temperature requirement serine protease A1 (HTRA1) in the pathogenesis of intervertebral disc (IVD) degeneration. *J Biol Chem*, 2012; 287: 21335–45
- Akhatib B, Onnerfjord P, Gawri R et al: Chondroadherin fragmentation mediated by the protease HTRA1 distinguishes human intervertebral disc degeneration from normal aging. *J Biol Chem*, 2013; 288: 19280–87
- Wang YX, Griffith JF, Leung JC, Yuan J: Age related reduction of T1rho and T2 magnetic resonance relaxation times of lumbar intervertebral disc. *Quant Imaging Med Surg*, 2014; 4: 259–64
- Daly C, Ghosh P, Jenkin G et al: A review of animal models of intervertebral disc degeneration: pathophysiology, regeneration, and translation to the clinic. *Biomed Res Int*, 2016; 2016: 5952165
- Zumbrunn J, Trueb B: Primary structure of a putative serine protease specific for IGF-binding proteins. *FEBS Lett*, 1996; 398: 187–92
- Eigenbrot C, Ultsch M, Lipari MT et al: Structural and functional analysis of HtrA1 and its subdomains. *Structure*, 2012; 20: 1040–50
- Urano T, Narusawa K, Kobayashi S et al: Association of HTRA1 promoter polymorphism with spinal disc degeneration in Japanese women. *J Bone Miner Metab*, 2010; 28: 220–26
- Frel M, Bialecki J, Wiecek J et al: Magnetic resonance imaging in differential diagnosis of pyogenic spondylodiscitis and tuberculous spondylodiscitis. *Pol J Radiol*, 2017; 82: 71–87
- Sudol-Szopinska I, Wlodkowska-Korytkowska M, Kwiatkowska B: Spectrum of inflammatory changes in the SJs on radiographs and MR Images in patients with suspected axial spondyloarthritis. *Pol J Radiol*, 2016; 81: 125–33
- Trattnig S, Stelzeneder D, Goed S et al: Lumbar intervertebral disc abnormalities: Comparison of quantitative T2 mapping with conventional MR at 3.0 T. *Eur Radiol*, 2010; 20: 2715–22
- Borthakur A, Maurer PM, Fenty M et al: T1rho magnetic resonance imaging and discography pressure as novel biomarkers for disc degeneration and low back pain. *Spine*, 2011; 36(25): 2190–96
- Salamat S, Hutchings J, Kwong C et al: The relationship between quantitative measures of disc height and disc signal intensity with Pfirrmann score of disc degeneration. *Springerplus*, 2016; 5: 829
- Schultz DS, Rodriguez AG, Hansma PK, Lotz JC: Mechanical profiling of intervertebral discs. *J Biomech*, 2009; 42: 1154–57

## Conclusions

Although there are some shortcomings in this study, such as the small number samples, and individual differences, we conclude that the expression of HtrA1 in NP tissue is strongly related to the T2 value, suggesting that HtrA1 plays an important role in the pathological process of intervertebral disc degeneration. Our findings may contribute to understanding the etiology and mechanism of intervertebral disc degeneration.

## Conflict of interests

None.