

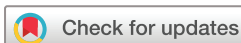# BMJ Open Application of the new 'XU-line' in the dynamic ultrasonographic evaluation of the spatial displacement of anterior cervical tissues for airway management: protocol for a prospective observational study

Yujie Wang <sup>1</sup>, Mingfeng Mao,<sup>2</sup> Yang Zhou,<sup>1</sup> Wanrui Shi,<sup>1</sup> Mao Xu<sup>1</sup>

**To cite:** Wang Y, Mao M, Zhou Y, *et al.* Application of the new 'XU-line' in the dynamic ultrasonographic evaluation of the spatial displacement of anterior cervical tissues for airway management: protocol for a prospective observational study. *BMJ Open* 2022;**12**:e058896. doi:10.1136/bmjopen-2021-058896

► Prepublication history for this paper is available online. To view these files, please visit the journal online (<http://dx.doi.org/10.1136/bmjopen-2021-058896>).

Received 01 November 2021  
Accepted 13 May 2022



© Author(s) (or their employer(s)) 2022. Re-use permitted under CC BY-NC. No commercial re-use. See rights and permissions. Published by BMJ.

<sup>1</sup>Department of Anesthesiology, Peking University Third Hospital, Beijing, China

<sup>2</sup>Department of Otorhinolaryngology, Sixth Medical Center of PLA General Hospital, Beijing, China

**Correspondence to**  
Professor Mao Xu;  
309617131@qq.com

## ABSTRACT

**Introduction** Patients with cervical spondylosis have a high incidence of difficult airway, and unpredicted difficult intubation may be life-threatening. Traditional predictors and imaging data may suggest a difficult airway, but these data have limited predictive value, with low sensitivity and specificity. Ultrasonography is a non-irradiating, reproducible, inexpensive and simple tool that provides good imaging of the cervical soft tissue for airway assessment. This study will use the new 'XU-line' in the dynamic ultrasonographic airway evaluation of the spatial displacement of the anterior cervical tissues to determine whether preoperative ultrasonographic assessment of the neck anatomy can predict difficult airway.

**Methods and analysis** This prospective, observational study will be conducted in a single centre. Four hundred and eleven patients scheduled for anterior cervical decompression and fusion under general anaesthesia will be recruited. The parallel trunk reference line through the mentum is defined as the XU-line, and the spatial displacement of the anterior cervical soft tissue relative to the XU-line at six anatomical levels in the transverse plane and two distances in the sagittal plane will be measured on ultrasonography with the patient in the supine position and the sniff position. The spatial displacement distances of soft tissue structures relative to the XU-line will be compared between the 'easy intubation' and 'difficult intubation' groups (in accordance with the Cormack-Lehane classification). Receiver operating characteristic curves will be used to determine the sensitivity and specificity of the 'difficulty prediction capability' of each ultrasonographic and physical measurement. Multiple logistic regression analysis will be performed to determine the independent predictors of difficult intubation.

**Ethics and dissemination** Ethical approval for this study has been obtained from the Peking University Third Hospital Medical Science Research Ethics Committee. The results of this study will be disseminated via a peer-reviewed publication and national and international conferences and workshops.

**Trial registration number** ChiCTR2000034446.

## INTRODUCTION

Unpredicted difficult intubation may be diagnosed during laryngoscopy, potentially

## STRENGTHS AND LIMITATIONS OF THIS STUDY

- ⇒ This protocol introduces the novel concept of the 'XU-line' (X line on ultrasonography, a reference line), which enables the measurement of the dynamic spatial changes in the pre-airway tissue structures rather than the static thickness of the local structures described in previous relevant studies.
- ⇒ This protocol introduces a custom-made coupling pad that could increase the smoothness of the contact surface between the ultrasound probe and the neck, increase the overall scanning range and improve ultrasonographic accuracy.
- ⇒ The application of the 'XU-line' during ultrasonography to evaluate the airway is non-irradiating, reproducible, inexpensive and easy to perform.
- ⇒ This study will comprise only patients with cervical spondylosis, who have a higher incidence of difficult airway; thereby, increasing the probability of identifying ultrasonographic clues to predict a difficult airway.
- ⇒ This will be a single-center observational study, and the extrapolation of our findings will require further evaluation.

causing a life-threatening scenario.<sup>1</sup> If patients with difficult airway could be identified earlier, clinicians may be better prepared, and the success rate of endotracheal intubation may be increased.<sup>2 3</sup> This is particularly important in patients with cervical spondylosis, who have a higher incidence of difficult airway.<sup>4</sup> The reported clinical predictors of difficult airway during laryngoscopy or intubation comprise the Mallampati score, upper lip bite test, interincisor distance, neck hyperextension, thyromental distance, sternomental distance, short neck, abnormal teeth, history of obstructive sleep apnoea and neck circumference. Medical imaging (radiography, CT and MRI) is also used to

predict difficult airway.<sup>5</sup> However, these imaging examinations require large pieces of equipment, and real-time observations are difficult. Therefore, there is a need for a more convenient examination method to predict difficult airway perioperatively.

Ultrasonography (US) machines are available in most modern operating theatres and emergency departments. As US is non-irradiating, reproducible, inexpensive and easy to perform,<sup>6</sup> a growing number of anaesthesiologists are using US in a variety of applications in daily practice, especially in airway evaluation. US can be used to estimate the required tracheal tube size, confirm the correct position of the tracheal tube and laryngeal mask, diagnose upper airway pathology, guide percutaneous tracheostomy or cricothyrotomy and predict post-extubation stridor.<sup>7</sup> Previous studies have found that a preanaesthetic ultrasonographic airway assessment is useful in predicting difficult intubation.<sup>8–10</sup> The size of the tongue relative to the oropharyngeal space is an important determinant of the ease of inserting the laryngoscope blade, and tongue size is traditionally assessed by the modified Mallampati classification, which has only moderate sensitivity.<sup>11</sup> However, US could be used to precisely calculate the tongue volume (based on the width and cross-sectional area of the tongue) to assess the tongue size on laryngoscopy.<sup>11</sup> Hui *et al*<sup>9</sup> recently showed that the visibility of the hyoid bone on a quick sublingual US predicts easy laryngoscopy, while the inability to visualise the hyoid bone on sublingual US predicts difficult laryngoscopy.

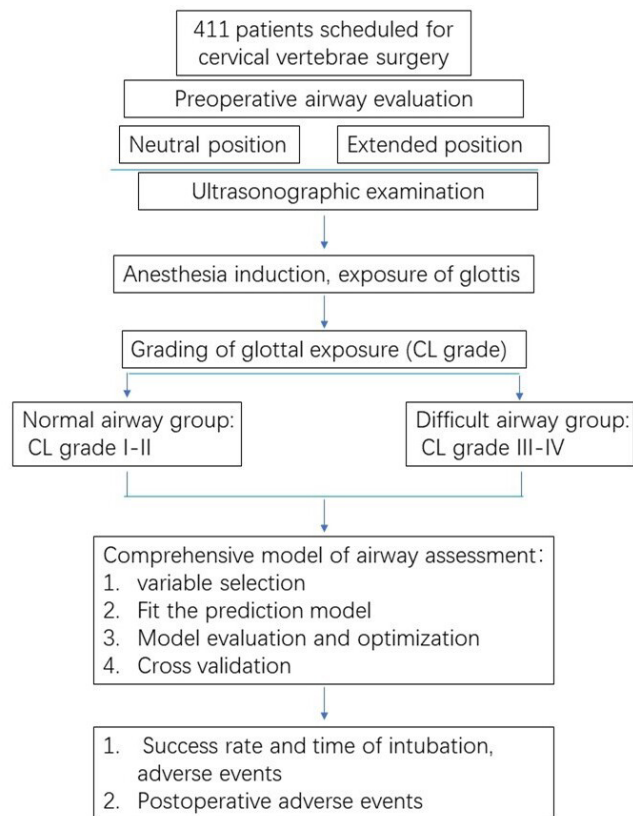
Despite having the potential to identify patients with probable difficult intubation, US is still not commonly used in airway assessment. One reason is that although several airway ultrasonographic parameters have been reported as possible indicators of difficult laryngoscopy in previous studies, there is minimal strong evidence supporting their validity.<sup>10 11</sup> Additionally, a prominent Adam's apple (anterior projection of the thyroid cartilage) may affect the contact between the US probe and the anterior skin of the neck, making it difficult to perform an ultrasonographic examination of the anterior median cervical airway, especially in men.

In this protocol, we designed a custom-made ultrasonographic coupling pad to increase the area and smoothness of the contact surface between the ultrasound probe and the neck. We also use a novel line, the 'XU-line', to assess the dynamic spatial displacement of the pre-airway tissue structures during endotracheal intubation. The aim of the proposed study is to explore whether one or more US indicators can predict difficult airway independently, using the XU-line.

## METHODS AND ANALYSIS

### Study design

This is a prospective, observational study conducted in a single centre. The active protocol at the time of writing is V.3, 10 July 2021. The flowchart of this trial is shown in figure 1.



**Figure 1** Study flowchart.

### Patient recruitment

The study cohort will comprise patients scheduled for anterior cervical decompression and fusion under general anaesthesia in the Peking University Third Hospital, Beijing, China, from December 2022 to December 2023.

### Inclusion criteria

- ▶ Age 18–70 years.
- ▶ Mental competence.
- ▶ American Society of Anaesthesiologists physical status I–III.
- ▶ Provision of written informed consent.

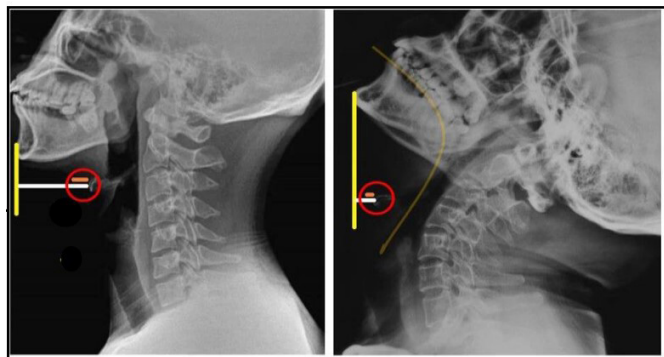
### Exclusion criteria

- ▶ Abnormal pharynx or other neck anatomy.
- ▶ Any abnormalities causing anatomical changes, such as facial/cervical fractures, maxillofacial abnormalities, cervical tumours or goitre.
- ▶ Patients who are unconscious, severely ill or have learning difficulties or a mental disability.

After providing informed consent, patients will be enrolled in the study and anonymised using an identification code. Patients will be able to voluntarily withdraw from the trial at any time.

### Sample size and study power

To build a multivariate logistic regression model of the measurements in the neutral position and sniff position, less than five parameters should be included in the model at the same time. Considering that 8–10



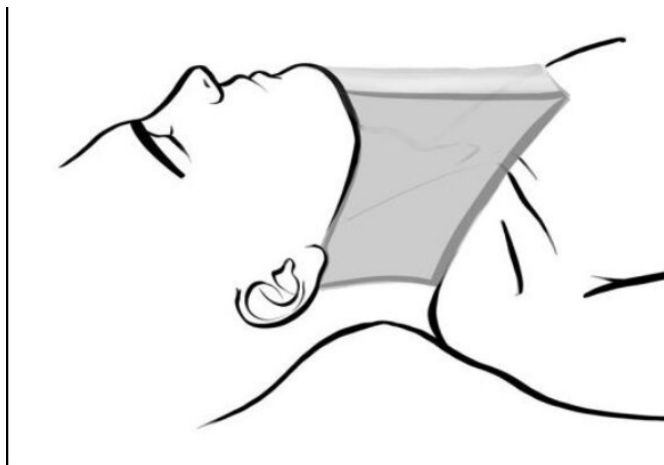**Figure 2** XU line in the radiographic image: a horizontal line parallel to the trunk of patient.

outcome events are needed for each independent variable, 50 patients with difficult airway should be enrolled. Our previous research revealed that the incidence of difficult airway in patients with cervical spondylosis is approximately 14.9%–17.1%<sup>12 13</sup>; therefore, a total of 336 surgical patients should be included in this study. The future comparison of different prediction methods will require a 10-fold cross-validation; therefore, we will enrol additional research subjects to ensure that there are sufficient numbers for each measurement when 90% of the subjects are extracted for modelling. Therefore, 373 (336/0.9) patients are needed. After adding 10% to account for other uncertainties, the estimated number of cases needed is 411.

### Study procedures

#### Definition of the XU-line

We define the parallel trunk reference line through the mentum as the XU-line (X line on ultrasonographic images), by which we will evaluate the spatial displacement of the pre-airway tissue (figure 2). To measure the distance from the pre-airway tissue to the XU-line, we will use a custom-made ultrasonographic coupling pad, with a thickness designed to reach the chin level (figure 3). The ultrasonographic coupling pad is in the shape of an



**Figure 3** A custom-made ultrasonographic coupling pad in the shape of an arch.

arch; its top layer is horizontal, and the bottom layer is arched to match the shape of the anterior neck, so the pad can be in close contact with the anterior neck. The pad can completely cover the entire neck of the patient from the lower chin to the superior sternal fossa after appropriate placement. The top layer of the pad matches the plane of the XU-line. Additionally, the coupling pad is filled with fluid, which allows ultrasound penetration to provide a clear image. Our preliminary experiment showed that real-time clear ultrasonographic images could be achieved using this coupling pad.

#### Preoperative evaluation and ultrasonography

The preoperative evaluation and ultrasonographic examination will be performed the day before surgery by the same trained examiner to avoid measurement bias. Each patient's basic information and medical history will be obtained. Physical examinations will comprise measurements of each patient's height, weight and body mass index. Airway evaluation will comprise the Mallampati score, neck mobility (degree of flexion/extension from the midline), upper lip bite test, jaw movement, presence of prominent incisors, mouth opening, thyromental distance, sternomental distance, hyomental distance and neck circumference at the level of the thyroid cartilage. Then, patients will be placed in the supine position with their head on a thin pillow, and the custom-made ultrasonographic coupling pad will be placed on the patient's neck. The curvilinear probe (frequency: 10 MHz, measurement depth: 5cm) of a portable US machine (M7 Super; Mindray, Shenzhen, China) will be placed on the top layer of the pad. The distances will then be measured from the XU line to anatomical landmarks at six levels (hyoid bone, thyrohyoid membrane, epiglottis, vocal cords, thyroid isthmus and suprasternal notch level) in the transverse plane, and the thickness of the genioglossus and the lingual-chin distance in the sagittal plane will be measured with the built-in screen ruler. Then, patients will change to the sniff position, and the same distances will be measured. The anaesthesiologists performing laryngoscopy and endotracheal intubation will be blinded to the ultrasonographic findings.

#### Anaesthetic procedure

Patients will fast for 8 hours but will be permitted to ingest clear fluids until 2 hours before anaesthesia. Standard monitoring (electrocardiography, pulse oximetry and non-invasive blood pressure monitoring) will be performed throughout anaesthesia. Equipment for difficult airway management will be ready for use. Preoxygenation will be performed for 3 min through a face mask before the administration of propofol (2 mg/kg) and a neuromuscular blocker (rocuronium 0.6 mg/kg) intravenously.

#### Laryngoscopy and ultrasonography

When the anaesthetic depth is sufficient, anaesthesiologists with more than 5 years of experience will perform

the laryngoscopy and endotracheal intubation. With the patient in the standard sniff position, a Macintosh curved laryngoscope blade will be inserted while real-time observation of endotracheal intubation will be performed by US. Traction and movement of the thyroid cartilage will be observed as the endotracheal tube enters the trachea. A maximum of three intubation attempts will be permitted. A modified version of the Cormack-Lehane classification will be used to evaluate the exposure of the glottis.<sup>14</sup> Patients with Cormack-Lehane grades I or II will be designated as the 'easy intubation' group; patients with Cormack-Lehane grades IIIa (only the epiglottis is visible and liftable), IIIb (epiglottis adherent to the pharynx) and IV (no laryngeal structures can be seen) will be designated as the 'restricted or difficult intubation' group. Difficult airway will be defined as Macintosh laryngoscope Cormack-Lehane grade III–IV, more than three intubation attempts or intubation time >10 min. If the patient has poor ventilation before surgery, slow induction of retained spontaneous breathing will be performed, and propofol will be administered at 1 mg/kg intravenously. If the ventilation is satisfactory, intubation will be performed after muscle relaxant administration. If effective ventilation cannot be maintained, a laryngeal mask airway device will be used to maintain ventilation. If the supraglottic airway device fails, cricothyroid membrane puncture will be performed immediately according to the difficult airway management guidelines issued by the American Society of Anaesthesiologists.<sup>15</sup>

After intubation, the presence of the proper capnograph waveform will be used to confirm tracheal intubation. Then, the position of the endotracheal tube will be examined by US to determine the distance between the cuff position and the glottis. The neck will be extended as much as possible for anterior cervical surgery. After the appropriate position is achieved, mechanical ventilation will be performed. The fresh gas flow rate will be 2 L/min, the oxygen concentration will be 50% and the tidal volume will be 10 mL/kg. The respiratory rate will be adjusted to maintain the end-expiratory CO<sub>2</sub> concentration between 35 and 40 mm Hg. Sevoflurane inhalation will be used for anaesthesia maintenance, and remifentanyl will be continuously injected intravenously. The remifentanyl dosage will be adjusted based on the blood pressure, and rocuronium bromide (0.15 mg/kg) will be added as needed. Tramadol 100 mg will be administered intravenously before the end of the operation. Sevoflurane and remifentanyl will then be discontinued, and the tracheal tube will be removed after the patient awakes and meets the extubation criteria.

The time required for intubation and the number of intubation attempts will be recorded. If the Cormack-Lehane grades is III or IV under Macintosh laryngoscopy, laryngeal intubation will be assisted by external pressure, and the Cormack-Lehane grade after pressing the larynx will also be recorded. The required auxiliary intubation methods and tools will be recorded. We will also record

the intubation success rate, immediate adverse events, and haemodynamic changes.

## Outcome measures

### Primary outcomes

- ▶ Ultrasonographic measurements in both the neutral position and the sniff position: distance from the XU-line to anatomical landmarks at six levels (hyoid bone, thyrohyoid membrane, epiglottis, vocal cords, thyroid isthmus and suprasternal notch level) in the transverse plane, and the thickness of the genioglossus and lingual–chin distance in the sagittal plane.
- ▶ Cormack-Lehane grade.

### Secondary outcomes

- ▶ Body mass index, Mallampati score, neck mobility (degree of flexion/extension from the midline), upper lip bite test, jaw movement, mouth opening (cm), thyromental distance, sternomental distance and neck circumference at the level of the thyroid cartilage.
- ▶ Time required for intubation, number of intubation attempts, required auxiliary intubation method and tools (endotracheal intubation device change, head and body position change, pressing of the larynx) and intubation success rate.
- ▶ Immediate adverse events (blood on the device, oropharyngeal abrasions, tooth injuries, lip injuries) and haemodynamic changes, such as hypotension, hypertension (blood pressure fluctuation of more than  $\pm 20\%$  of the base value), bradycardia (<50 beats/min), tachycardia (>100 beats/min) and hypoxia (blood oxygen saturation <92%).

### Additional risks to patients

Bedside airway US is noninvasive. Although ultrasonography during endotracheal intubation may prolong the endotracheal intubation time, anaesthesiologists with extensive experience can successfully establish an artificial airway before hypoxia and ensure the patient's safety. Therefore, this study does not involve additional risks to the patients, compared with the risks with conventional general anaesthesia methods.

### Data management safety committee

The data management safety committee will comprise three independent researchers. The researchers will review all adverse events, participant retention in each arm of the study and compliance with the study protocol at weekly intervals.

### Statistical methods

Data will be analysed using SPSS V.20.0 statistical software (IBM Corp., Armonk, New York, USA). The spatial displacement of the anterior cervical tissues and the clinical airway measurements will be compared between the easy intubation and difficult intubation groups. Receiver operating characteristic curves will be used to determine the sensitivity and specificity of the 'difficult

prediction capability' of each ultrasonographic and physical measurement. Clinical factors associated with difficult intubation will be determined by univariate analyses. The  $\chi^2$  test will be used for categorical or binary variables, and the unpaired t-test will be used for continuous variables. Multiple logistic regression analysis will be performed to determine the independent predictors of difficult intubation. Continuous data will be presented as the mean $\pm$ SD deviation, and categorical data will be expressed as frequency (%). For all variables, the p value, OR and 95% CI will be obtained. P values <0.05 will be considered statistically significant.

### Patient and public involvement

This research will be performed without patient involvement. Patients are not invited to comment on the study design or contribute to the writing or editing of this document for readability or accuracy.

### ETHICS AND DISSEMINATION

Ethics approval for this study has been obtained from the Medical Ethics Committee of Peking University Third Hospital (approval no. M2018159). The results of this study will be disseminated via a peer-reviewed publication and national and international conferences and workshops.

### DISCUSSION

The strengths of our study are: First, in most previous studies, US was used only when patients were in the neutral position.<sup>15–18</sup> However, endotracheal intubation is usually performed when the patient is in the sniff position; therefore, the dynamic spatial changes of the pre-airway tissue structures from the neutral position to the sniff position appear more meaningful to predict difficult airway. Wojtczak *et al*<sup>11</sup> found that the tongue–chin distance when the neck is extended is a more effective predictor of difficult laryngoscopic exposure than the distance in the neutral position. Our previous studies also found that the change in neck range of motion (angle difference between the neutral and extension positions) on radiography is a better predictor of difficult airway than that when using the raw data.<sup>12 13</sup> Therefore, in our study, we will first observe the pre-airway tissue structures in both the neutral position and the sniff position. Second, we define a novel line, the XU-line, by which we can measure the spatial displacements of the pre-airway tissue structures. Third, considering the influence of a prominent Adam's apple on ultrasonographic examination of the anterior median cervical airway, especially in men, we constructed a new ultrasonographic coupling pad shaped in accordance with the characteristics of the anterior neck. This custom-made coupling pad could increase the smoothness of the contact surface between the ultrasound probe and the neck, increase the overall US scanning range and improve US accuracy. Furthermore, to avoid

measurement bias, preoperative US examination will be performed by the same trained sonographer, and the anaesthesiologists performing laryngoscopy and endotracheal intubation will be blinded to the preoperative ultrasonographic findings. Therefore, this well-designed study is more likely to provide useful US clues for preoperative prediction of difficult airway.

The main limitations of this proposed study are: First, owing to the weight of the coupling pad, the anterior cervical soft tissue will be compressed after the pad is placed; therefore, the measured thickness of the anterior cervical soft tissues is not the actual value. However, the coupling pad is arched, with a thin centre section and thick sides; therefore, we believe that the change in the neck thickness caused by the coupling pad can be ignored. In addition, we will compare the spatial changes of the soft tissues of the neck in the neutral position with those in the sniff position while the position of the coupling pad remains unchanged; therefore, we believe that the pad will have little effect on the measurement results. Second, owing to posture variations in different patients, the coupling pad may not fit perfectly for all patients. Therefore, we fill the coupling pad with liquid to achieve maximum fit. Third, this is a single-centre observational study of people with cervical spondylosis; therefore, extrapolation of our findings to other patients will require further evaluation.

Our protocol is the first to introduce the novel concept of the XU-line, which enables the observation of dynamic changes in the pre-airway tissue structures rather than providing only the static evaluation of the local structures, as in previous relevant studies. The application of the XU-line is expected to identify ultrasonographic clues predicting difficult airway.

**Acknowledgements** We would like to thank MM for his help in designing this study.

**Contributors** YW, MM and MX designed and coordinated the study. YW, WS and YZ recruited the patients and collected data. YW, MM and MX drafted the manuscript. YW analysed the data and performed the statistical analysis. All authors have read and approved the manuscript.

**Funding** This work was supported by grants to MX from the Capital Clinical Characteristic Applied Research Project (Z181100001718109), and to YW from Science and Technology Innovation Fund for Youth of Peking University Health Science Centre (BMU2021PYB038).

**Competing interests** None declared.

**Patient and public involvement** Patients and/or the public were not involved in the design, or conduct, or reporting, or dissemination plans of this research.

**Patient consent for publication** Not applicable.

**Provenance and peer review** Not commissioned; externally peer reviewed.

**Open access** This is an open access article distributed in accordance with the Creative Commons Attribution Non Commercial (CC BY-NC 4.0) license, which permits others to distribute, remix, adapt, build upon this work non-commercially, and license their derivative works on different terms, provided the original work is properly cited, appropriate credit is given, any changes made indicated, and the use is non-commercial. See: <http://creativecommons.org/licenses/by-nc/4.0/>.

**ORCID iD**

Yujie Wang <http://orcid.org/0000-0002-0515-4338>



## REFERENCES

- 1 Cook TM, Woodall N, Frerk C. Major complications of airway management in the UK: results of the fourth national audit project of the Royal College of anaesthetists and the difficult airway Society. Part 1: anaesthesia †. *Br J Anaesth* 2011;106:617–31.
- 2 Mosier JM, Stolz U, Chiu S, *et al.* Difficult airway management in the emergency department: GlideScope videolaryngoscopy compared to direct laryngoscopy. *J Emerg Med* 2012;42:629–34.
- 3 Berlac P, Hyldmo PK, Kongstad P, *et al.* Pre-hospital airway management: guidelines from a task force from the Scandinavian Society for Anaesthesiology and intensive care medicine. *Acta Anaesthesiol Scand* 2008;52:897–907.
- 4 Han Y, Fang J, Zhang H, *et al.* Anterior neck soft tissue thickness for airway evaluation measured by MRI in patients with cervical spondylosis: prospective cohort study. *BMJ Open* 2019;9:e029987.
- 5 Kamalipour H, Bagheri M, Kamali K, *et al.* Lateral neck radiography for prediction of difficult orotracheal intubation. *Eur J Anaesthesiol* 2005;22:689–93.
- 6 Pourmand A, Lee D, Davis S, *et al.* Point-of-care ultrasound utilizations in the emergency airway management: an evidence-based review. *Am J Emerg Med* 2017;35:1202–6.
- 7 Reddy PB, Punetha P, Chalam KS. Ultrasonography - A viable tool for airway assessment. *Indian J Anaesth* 2016;60:807–13.
- 8 Kristensen MS. Ultrasonography in the management of the airway. *Acta Anaesthesiol Scand* 2011;55:1155–73.
- 9 Hui CM, Tsui BC. Sublingual ultrasound as an assessment method for predicting difficult intubation: a pilot study. *Anaesthesia* 2014;69:314–9.
- 10 Adhikari S, Zeger W, Schmier C, *et al.* Pilot study to determine the utility of point-of-care ultrasound in the assessment of difficult laryngoscopy. *Acad Emerg Med* 2011;18:754–8.
- 11 Wojtczak JA. Submandibular sonography: assessment of hyomental distances and ratio, tongue size, and floor of the mouth musculature using portable sonography. *J Ultrasound Med* 2012;31:523–8.
- 12 Han YZ, Tian Y, Zhang H, *et al.* Radiologic indicators for prediction of difficult laryngoscopy in patients with cervical spondylosis. *Acta Anaesthesiol Scand* 2018;62:474–82.
- 13 Xu M, Li X, Wang J, *et al.* Application of a new combined model including radiological indicators to predict difficult airway in patients undergoing surgery for cervical spondylosis. *Chin Med J* 2014;127:4043–8.
- 14 Cook TM. A new practical classification of laryngeal view. *Anaesthesia* 2000;55:274–9.
- 15 Apfelbaum JL, Hagberg CA, Connis RT, *et al.* 2022 American Society of Anesthesiologists practice guidelines for management of the difficult airway. *Anesthesiology* 2022;136:31–81.
- 16 Isaiiah A, Mezrich R, Wolf J. Ultrasonographic detection of airway obstruction in a model of obstructive sleep apnea. *Ultrasound Int Open* 2017;3:E34–42.
- 17 Saha S, Rattansingh A, Viswanathan K, *et al.* Ultrasonographic measurement of Pharyngeal-Airway dimension and its relationship with obesity and sleep-disordered breathing. *Ultrasound Med Biol* 2020;46:2998–3007.
- 18 Ahn JH, Park JH, Kim MS, *et al.* Point of care airway ultrasound to select tracheal tube and determine insertion depth in cleft repair surgery. *Sci Rep* 2021;11:4743.