



CASE REPORT

Open Access

Unusual pediatric co-morbidity: autoimmune thyroiditis and cortico-resistant nephrotic syndrome in a 6-month-old Italian patient

Flavia Urbano^{*}, Angelo Acquafredda, Gabriella Aceto, Rosa Penza and Luciano Cavallo

Abstract

We report on a case of autoimmune thyroiditis in a 6-month-old patient with cortico-resistant nephrotic syndrome. Normal serum levels of thyroid hormones and thyroid-stimulating hormone were detected with high titers of circulating antithyroid antibodies and a dysomogeneous ultrasound appearance of the gland, typical of autoimmune thyroiditis. The research of maternal thyroid antibodies was negative. This is the first case of autoimmune thyroiditis found in such a young patient with pre-existing nephrotic syndrome ever described in literature. This association is random because nephrotic syndrome does not have an autoimmune pathogenesis and the genes involved in autoimmune thyroiditis are not related to those of nephrotic syndrome.

Keywords: Autoimmune thyroiditis, Nephrotic syndrome, Childhood

Introduction

Autoimmune diseases are very rare conditions in infancy, especially in the first year of life [1-4]. We report on a case of unusual early-onset autoimmune thyroiditis in a 6-month-old child affected by nephrotic syndrome. Before that, a case of isolated autoimmune thyroiditis has been reported previously at a so early age: the patient, a 7-month-old child, died at the age of 9 months for a sepsis and his autopsy revealed a thyroid atrophy [1].

Case report

D.S. was admitted to our hospital at 6 months of age because of the appearance, two weeks before, of bilateral periorbital oedema associated with hypoalbuminemia (albumin 0.5 g/dl), hypoprotidemia (seric proteins 3.7 g/dl), proteinuria (proteinuria/creatinuria ratio 114,3) and dyslipidemia (total cholesterolemia 287 mg/dl, LDL-cholesterol 165 mg/dl, triglycerides 997 mg/dl). The diagnosis of nephrotic syndrome was established and a substitutive therapy including human albumin was immediately started, as well as calcium and potassium

supplementation, diuretics and intravenous immunoglobulines. After a few days albumin levels further decreased, general conditions became more serious and subcutaneous succulence spread especially in abdominal, scrotal and palpebral regions. For this reason, it became necessary to intensify albumin infusion as well as diuretic supply and to introduce prednisone (starting dose 1 mg/Kg/die, than 0,5 mg/Kg/die) in association with an ACE-inhibitor (dose 0,5 mg/Kg/die) for its antiproteinuric effect, in order to potentiate steroid action. This therapy was given for overall eight weeks without any response: therefore this form of nephrotic syndrome can be defined "cortico-resistant". After a few days, for the aggravation of clinical conditions, also cyclophosphamide (dose 1 mg/Kg/die) and spironolactone (potassium-sparing) were introduced unsuccessfully. Blood pressure was always normal. Because of the massive proteinuria, due to the renal failure, an evaluation of thyroid function was made: thyroid hormones were normal but high titers of circulating antithyroglobulin and anti-microsomal thyroid antigen antibodies were detected [5,6]. No antithyroid antibodies were found in his mother, excluding a transplacental transfer [7]. The diagnosis of autoimmune thyroiditis was confirmed by the typical ultrasound appearance of the gland,

* Correspondence: flavia.urbano@libero.it

Biomedicine Department of Development Age, University of Bari "Aldo Moro", Piazza Giulio Cesare, 11, 70124, Bari, Italy

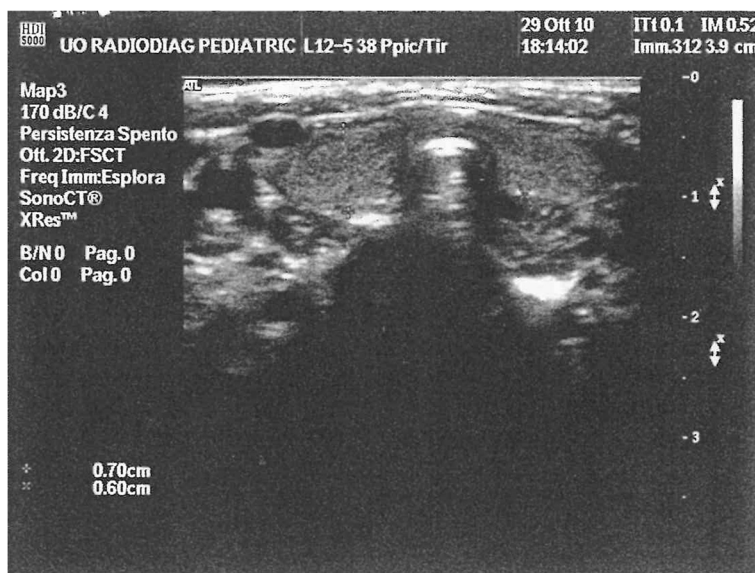


Figure 1 Ultrasound image of thyroiditis in a 6-month-old child.

characterized by normal morphology and sizes but a dysomogeneous structure (Figure 1).

After a month a blood assay revealed the persistence of high titers of antithyroid antibodies associated to a slight decrease of thyroid hormones (fT4 0,62 ng/dl with normal values between 0.70 and 1.80, fT3 1,32 pg/ml with normal values between 1.7 and 5.2) and normal levels of thyroid-stimulating hormone, without any clinical sign of hypothyroidism. Because of the aggravation of the renal disease, the patient was transferred to another hospital where he continued human albumin replacement therapy and cyclophosphamide and then he began haemodiafiltration. During this period he was subjected to renal biopsy which demonstrated the presence of a focal and segmental glomerulonephritis with mesangial matrix proliferation and an increase of Immunoglobulines M. Currently the patient is undergoing peritoneal dialysis waiting for kidney transplantation.

Conclusions

The significance of this study is due to the early onset of autoimmune thyroiditis in association with nephrotic syndrome in a child under one year of age. The association found in our patient seems to be random because nephrotic syndrome does not have an autoimmune pathogenesis and there is no genetic or antigenic relation between autoimmune thyroiditis and nephrotic syndrome [8-10]. Finally, the case described suggests that serum thyrotropin and thyroxin levels should be determined in all cases of renal failure, even if the patient does not present the clinical signs of hypothyroidism.

Consent

Written informed consent was obtained from the patient's parents for publication of this case report and any accompanying images.

Competing interests

The authors have indicated they have no relationships relevant to this article to disclose.

Authors' contributions

FU carried out the endocrinological and nephrological studies, drafted the manuscript and got the image. AA carried out the molecular genetic and pathogenetic studies. GA participated in the sequence alignment. RP provided the literature. LC coordinated the work. All authors read and approved the final manuscript.

Received: 26 February 2012 Accepted: 11 October 2012

Published: 23 October 2012

References

1. Ostergaard GZ, Jacobsen BB: **Atrophic, autoimmune thyroiditis in infancy. A case report.** *Horm Res* 1989, **31**(4):190-192.
2. Shalitin S, Philip M: **Autoimmune thyroiditis in infants with Down's syndrome.** *J Pediatr Endocrinol Metab* 2002, **15**(5):649-652.
3. Harris F, Koutsalieris E: **Hypothyroidism due to autoimmune thyroiditis in a young child with Down's syndrome.** *Arch. Dis. Childhood* 1967, **42**:449.
4. Foley TP Jr, Abbassi V, Copeland KC, Drazlin MB: **Brief report: hypothyroidism caused by chronic autoimmune thyroiditis in very young infants.** *N Engl J Med* 1994, **330**(7):466-468.
5. Valentin M, Bueno B, Gutiérrez E, Martínez A, González E, Espejo B, Torres A: **Membranoproliferative glomerulonephritis associated with autoimmune thyroiditis.** *Nefrologia* 2004, **24**(Suplemento 3):43-48.
6. Gurkan S, Dikman S, Saland MJ: **A case of autoimmune thyroiditis and membranoproliferative glomerulonephritis.** *Pediatr Nephrol* 2009, **24**(1):193-197. Epub 2007 Nov 16.
7. Pasquier S, Torresani T, Werder E, Gnehm HE: **Transitory neonatal hypothyroidism caused by transplacental transfer of anti-receptor of hypophyseal thyroid stimulation. Case report and estimated incidence.** *Schweiz Med Wochenschr* 1997, **127**(44):1824-1828.
8. Caputo M, Rivolta CM, Mories T, Carrales JJ, Galindo P, González-Sarmiento P, Targovnik HM, Miralles-García JM: **Analysis of thyroglobulin gene**

polymorphism in patients with autoimmune thyroiditis. *Endocrine* 2010, **37**(3):389–395. Epub 2010 Mar 18.

9. Arisaka O, Arisaka M, Nakayama Y, Shimura N, Obinata K, Ino T, Nijijima S, Akiyama T, Yabuta K, Arikawa K, *et al*: **Thyrotropin binding inhibitor immunoglobulin. Its pathogenetic importance in hypothyroidism.** *Am J Dis Child* 1986, **140**(10):998–1000.
10. Hinkes BG, Mucha B, Vlendos CN, Gbadegesin R, Liu J, Hasselbacher K, Hangan D, Ozaltin F, Zanker M, Hildebrandt F: **Nephrotic syndrome in the first year of life: two third of cases are caused by mutations in 4 genes (NPHS1, NPHS2, WT1, and LAMB²).** *Pediatrics* 2007, **119**(4):e907–e919. Epub 2007 May 19.

doi:10.1186/1824-7288-38-57

Cite this article as: Urbano *et al*: Unusual pediatric co-morbidity: autoimmune thyroiditis and cortico-resistant nephrotic syndrome in a 6-month-old Italian patient. *Italian Journal of Pediatrics* 2012 **38**:57.

**Submit your next manuscript to BioMed Central
and take full advantage of:**

- Convenient online submission
- Thorough peer review
- No space constraints or color figure charges
- Immediate publication on acceptance
- Inclusion in PubMed, CAS, Scopus and Google Scholar
- Research which is freely available for redistribution

Submit your manuscript at
www.biomedcentral.com/submit

