

# A case of congenital dermatofibrosarcoma protuberans in a 2-year-old child



Francesca Caroppo, MD,<sup>a</sup> Roberto Salmaso, MD,<sup>b</sup> Elena Fontana, MD,<sup>a</sup> and Anna Belloni Fortina, MD<sup>a</sup>  
Padova, Italy

## INTRODUCTION

Dermatofibrosarcoma protuberans is a rare cutaneous soft tissue tumor with a limited potential for metastasis, but a high risk of invasive growth and local recurrence. It is histologically characterized by a dense proliferation of uniform monomorphic spindle cells in the dermis, often infiltrating subcutaneous tissues (fat, muscle, and even bone). Fibroblasts appear arranged in disorganized fascicles with a typical storiform pattern within a slightly myxoid stroma. Tumor cells of dermatofibrosarcoma protuberans usually are positive for CD34 and negative for protein S100 and factor XIIIa. Treatment recommended consists of a complete surgical excision with large margins.<sup>1-3</sup>

Early diagnosis gives the best chance of successful surgical resection. Congenital dermatofibrosarcoma protuberans is extremely rare and very few cases have been reported.<sup>4,5</sup>

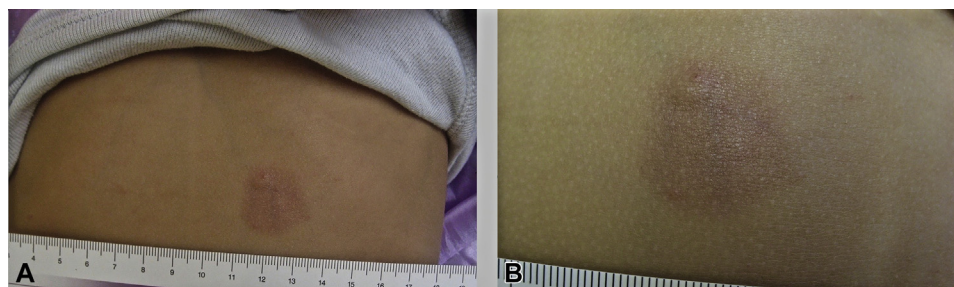
We describe a case of a congenital dermatofibrosarcoma protuberans diagnosed in a 2-year-old child.

## CASE REPORT

A 2-year-old female patient attended our Pediatric Dermatology Unit for evaluation of an asymptomatic hyperchromic patch with blurred edges and a fixed indurated brownish skin nodule, present from birth (Fig 1). This lesion measured approximately 25 × 20 mm, was localized in the abdominal region, and was progressively growing. In view of the progressive changes of the lesion, an incisional biopsy was performed to rule out malignancy.

Histopathologic examination showed a monomorphic fibrohistiocytic spindle cell tumor arranged in a storiform pattern infiltrating the deep dermis and subcutaneous tissue (Fig 2). Immunohistochemistry showed cells positive for CD34 and negative for protein S100. No cytologic abnormalities or mitoses were found. Based on the histologic data, the diagnosis was dermatofibrosarcoma protuberans.

The lesion was removed surgically with a safety margin of 3 cm. According to pediatric protocols, no other treatment was required.<sup>4</sup> Eighteen months after surgery no local recurrence was observed.



**Fig 1.** **A**, Hyperchromic skin patch with soft edges and fixed indurated brownish nodule on abdominal region. **B**, Close-up of the lesion.

From the Pediatric Dermatology Unit<sup>a</sup> and Surgical Pathology and Cytopathology Unit,<sup>b</sup> Department of Medicine (DIMED), University of Padova.

Funding sources: None.

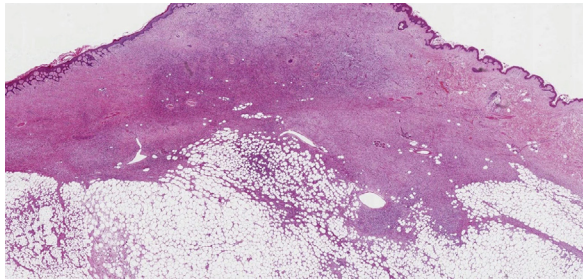
Conflicts of interest: None disclosed.

Correspondence to: Anna Belloni Fortina, MD, Pediatric Dermatology Unit, Department of Medicine (DIMED), University of Padova, Via Gallucci, 4, 35128 Padova, Italy. E-mail: [anna.bellonifortina@unipd.it](mailto:anna.bellonifortina@unipd.it).

JAAD Case Reports 2020;6:606-7.  
2352-5126

© 2020 by the American Academy of Dermatology, Inc. Published by Elsevier, Inc. This is an open access article under the CC BY-NC-ND license (<http://creativecommons.org/licenses/by-nc-nd/4.0/>).

<https://doi.org/10.1016/j.jidcr.2020.05.015>



**Fig 2.** Monomorphic fibrohistiocytic spindle cells infiltrating dermis and extending into the subcutaneous tissue.

## DISCUSSION

Dermatofibrosarcoma protuberans has an estimated incidence in the pediatric population of 1.02 per million person-years.<sup>1,2</sup> However, this estimate may not be correct; several diagnoses of dermatofibrosarcoma protuberans in adulthood may be due to missed diagnoses in childhood because of the tendency of dermatofibrosarcoma protuberans to grow slowly, the hesitancy to perform skin biopsies in children, or wrong diagnoses. Differential diagnoses of dermatofibrosarcoma protuberans include several skin conditions (eg, vascular malformation, aplasia cutis, dermoid cyst, fibrous hamartoma), which may lead to a wrong diagnosis, especially in the early stages of the disease.

Clinical suspicion by pediatricians or dermatologists is essential because an early diagnosis gives the best chances of successful surgical resection, reducing the dimensions of the surgical scar and avoiding extensive surgery reconstruction. The case we described underlines the importance of suspecting dermatofibrosarcoma protuberans in children and the need for a skin biopsy in any cutaneous persistent and growing plaque or nodule without pathognomonic clinical features, even when these lesions are present from birth.

## REFERENCES

1. Kornik RI, Muchard LK, Teng JM. Dermatofibrosarcoma protuberans in children: an update on the diagnosis and treatment. *Pediatr Dermatol.* 2012;29(6):707-713.
2. Valdivielso-Ramos M, Torrelo A, Campos M, et al. Pediatric dermatofibrosarcoma protuberans in Madrid, Spain: multi-institutional outcomes. *Pediatr Dermatol.* 2014;31(6):676-682.
3. Buteau AH, Keeling BH, Diaz LZ, et al. Dermatofibrosarcoma protuberans in pediatric patients: a diagnostic and management challenge. *JAAD Case Rep.* 2018;4(2):155-158.
4. Tsai YJ, Lin PY, Chew KY, Chiang YC. Dermatofibrosarcoma protuberans in children and adolescents: clinical presentation, histology, treatment, and review of the literature. *J Plast Reconstr Aesthet Surg.* 2014;67(9):1222-1229.
5. Han HH, Lim SY, Park YM, Rhie JW. Congenital dermatofibrosarcoma protuberans: a case report and literature review. *Ann Dermatol.* 2015;27(5):597-600.