

CASE REPORT

Malignant proliferating trichilemmal tumor in abdominal wall: Report of a rare case at an uncommon site with literature review

Mahdokht Azizi¹ | Mazaher Ramezani^{2,3} 

¹Department of Pathology, Shahid Beheshti Hospital, Yasuj University of Medical Science, Yasuj, Iran

²Molecular Pathology Research Center, Imam Reza Hospital, Kermanshah University of Medical Sciences, Kermanshah, Iran

³Clinical Research Development Center, Imam Reza Hospital, Kermanshah University of Medical Sciences, Kermanshah, Iran

Correspondence

Mazaher Ramezani, Molecular Pathology Research Center, Imam Reza Hospital, Kermanshah University of Medical Sciences, Kermanshah, Iran.
Email: mazaher_ramezani@yahoo.com

Funding information

There is no funding support

Abstract

The proliferating trichilemmal tumor (PTT) is a very rare cutaneous neoplasm that rarely is malignant. PTTs mainly occur in the scalp of elderly women. Only 10% occur in places other than scalp. We present a 62-year-old male patient with malignant PTT in his abdominal wall.

KEYWORDS

abdomen, malignant proliferating trichilemmal tumor

1 | INTRODUCTION

The proliferating trichilemmal tumor (PTT) is a very rare cutaneous adnexal neoplasm that originates from the external root sheath of the hair follicle, introduced by Jones as epidermal cyst in 1996.¹ PTTs are supposed to start from a smooth and round solitary lesion, known as trichilemmal cyst (TC), which transforms into neoplasm, PTT, by irritation, inflammation, or trauma.² Most cases are reported in elderly women, and the main tumor site is the scalp (about 90% of cases); very rare cases are observed outside the head and neck region.³

Due to the rarity of this condition, differentiating this tumor from other similar neoplasms is of great

importance; trichilemmal keratinization can help diagnosis of PTT.⁴ Three major types have been suggested for PTT: benign, locally aggressive, and malignant⁴; the latter, introduced in 1988,⁵ has variable clinical outcome, complex histopathologic characteristics, and controversial treatment.⁶

Owing to the fact that cases with malignant PTT may be misclassified as other PTT types or other tumor types, such as squamous cell carcinoma (SCC), the exact incidence of malignant PTT is unknown,³ but, generally fewer than 50 cases has been reported so far. Furthermore, despite the general concepts, introduced above, different presentations have been reported for malignant PTT, such as presentation at early age⁷ or giant tumor at an extraordinary site, back of the wrist.⁸ Therefore, presenting the

This is an open access article under the terms of the Creative Commons Attribution-NonCommercial License, which permits use, distribution and reproduction in any medium, provided the original work is properly cited and is not used for commercial purposes.

© 2022 The Authors. *Clinical Case Reports* published by John Wiley & Sons Ltd.

clinical experience of each case can help enrichment of the literature. In this paper, we present a male elderly with malignant PTT in his abdominal wall, a rare tumor site, which has been successfully treated with surgical excision.

2 | CASE PRESENTATION

The patient was a 62-year-old male patient, who had a subcutaneous nodule in his left abdominal wall near umbilicus since he was 2 years old, a painless mass at the size of a bean (about 1 cm), as the patient acknowledged. The patient did not refer to a physician for this problem, and the mass grew

very slowly, becoming about 3–4 cm; in 3–4 years ago, when the patient had a car accident and a blunt trauma to the abdomen, after which the mass started to grow rapidly and became ulcerative with smelling discharge; but he still did not seek medical help, although the smelling hematoma caused problems for the patient, during wearing his clothes.

When the patient referred to us, the physician examined the patient and referred him for surgical excision with wide margins. On the venous blood sample taken from the patient the day before surgery, the patient's serum parameters were within normal range (Table 1). The patient had neither history of chronic diseases nor family history of a similar disease. Under general anesthesia, the patient was operated with safety margin; the resected mass was sent to the laboratory for pathologic examination.

The pathologic examination showed malignant PTT, confirmed by two pathologists. The gross examination of the mass revealed one piece of ulcerated creamy/gray mass $7 \times 7 \times 6 \text{ cm}^3$ at 0.6 cm distance from closest margin, overlying skin tissue of $11 \times 10 \times 5 \text{ cm}^3$ (Figure 1). Cut sections showed poor-circumscribed solid heterogeneous appearance with firm consistency. Microscopic examination of the mass revealed skin tissue with poorly circumscribed lesion invading surrounding tissue culminating in desmoplastic stromal reaction. Trichilemmal keratinization with squamous eddies and no granular layer was present. Nuclear atypia, and atypical mitoses, scattered giant cell, and calcification were also noted (Figure 2). Necrosis was present; all margins were free of tumor. Distance of tumor from the closest margin was 0.6 cm. There was no lymphovascular or perineural invasion.

The patient received no postoperative treatment, other than antibiotic therapy. The patient is now in good condition after 3 months.

TABLE 1 Results of the serum parameters of the patient

Serum parameter	Patients' value	Normal range	Unit
White blood cell	10×10^3	4–11	count/micro
Red blood cell	5.63×10^6	4.5–5	count/micro
Hemoglobin	16.30	12–15.5	mg/dl
Hematocrit	46.30	35–45	%
Platelet count	200×10^3	150–450	count/micro
Partial thromboplastin time	30	35–45	sec
PT/INR	12	12–14	sec
PT.INR	0.86	-	-
Blood glucose	145		mg/dl
Blood urea nitrogen	12	7–25	mg/dl
Creatinine	0.7	0.7–1.4	mg/dl
Serum sodium	138	130–148	mEq/L
Serum potassium	4	3.5–5	mEq/L

Abbreviations: INR, international normalized ratio; PT, Prothrombin time.

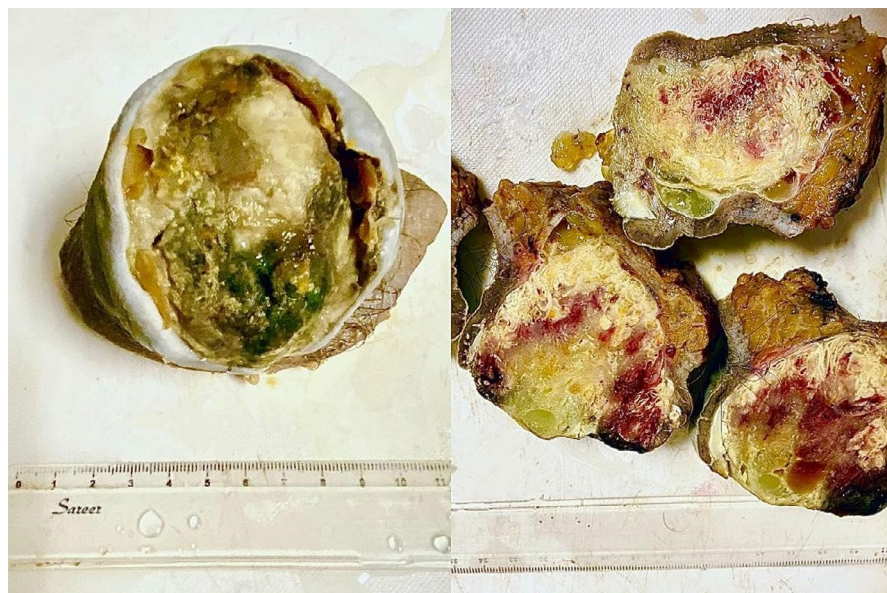


FIGURE 1 Gross image of the mass

3 | DISCUSSION

In this paper, we presented a male patient with malignant PTT. The patient's history suggested that he had TC since childhood, which remained undiagnosed and untreated, until it developed into PTT after a blunt trauma to the abdomen; the mechanism has been previously described for this type of tumors.² The tumor site in our case, the abdominal wall, was one of the rare sites of malignant PTT, as the head and neck, especially the scalp, is considered the most common site in previous reports.³ We summarized the cases reported with malignant PTTs at sites other than head and neck in Table 2. According to our literature review, there are only eight cases of malignant PTTs at sites other than head and neck (and two

conference presentations, not included); the rest of PTTs at sites other than head and neck were benign. Of note, malignant PTT has not been previously reported in the abdominal wall.

The literature review (Table 2) confirms the results of previous reports on higher incidence of malignant PTT in women,³ while our case was a male patient. A deeper look into this table shows a wide variety for the tumor sites, which suggests that malignant PTT can be found in almost any part of the body; therefore, the physicians must be aware of this fact, in order to reduce the risk of misdiagnosis. Unfortunately, many cases have been misdiagnosed as other conditions and have not received the appropriate treatment, such as the case presented by Uchia et al. who underwent radical mastectomy with axillary dissection,

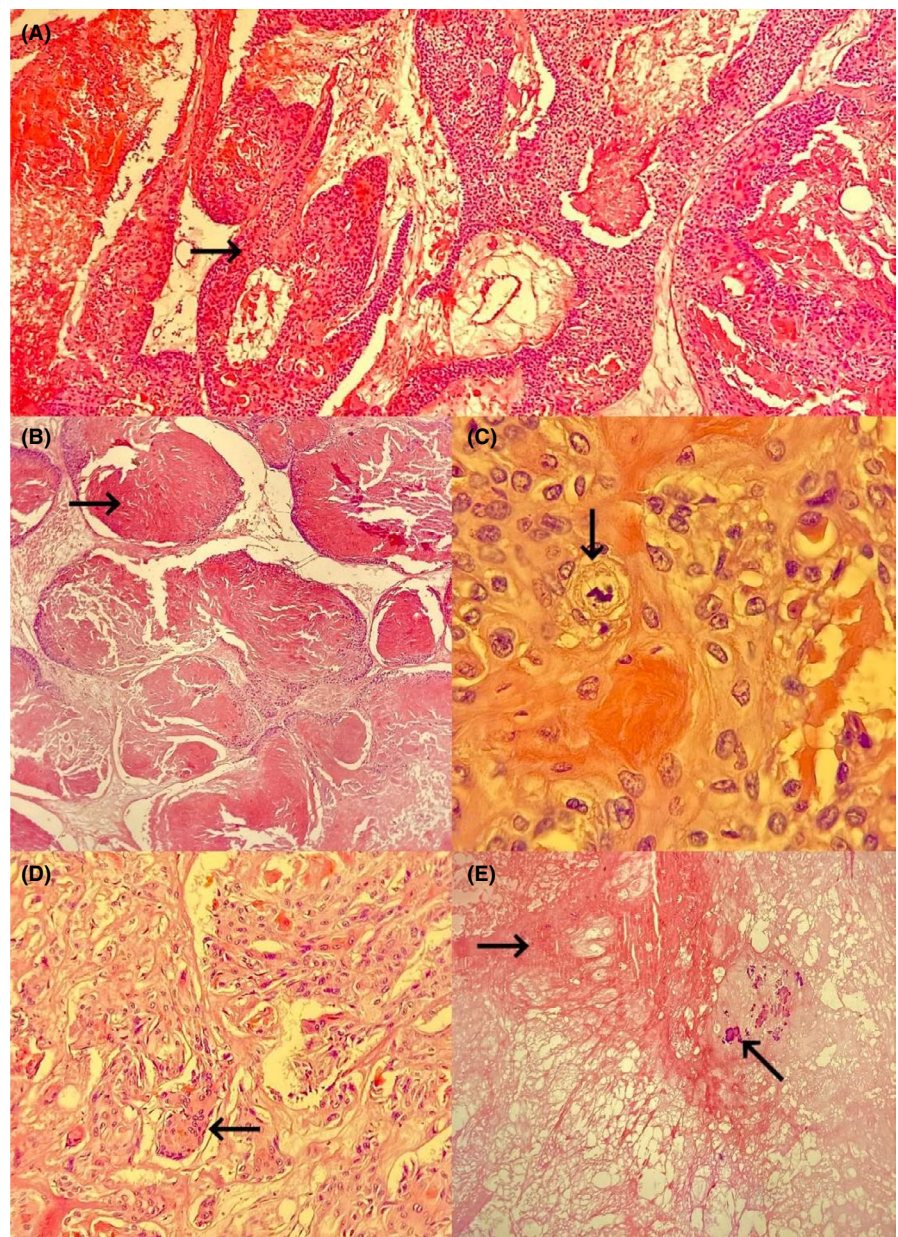


FIGURE 2 Light microscopic view (Hematoxylin and eosin, $\times 200$). (A and B) trichilemmal keratinization without granular layer; (C) Nuclear atypia and mitotic activity ($\times 400$); (D) Stromal invasion ($\times 400$); and (E) Necrosis and calcification ($\times 200$)

TABLE 2 Review of studies reporting malignant proliferating trichilemmal tumor at sites other than head and neck

Author(s)	Tumor site	Tumor size	Patient's age	Patient's sex	Treatment	Outcome
Aneiros-Fernandez et al. ⁸	Arm, wrist, and back of hand	14 × 9 cm ²	63	M	Surgical excision with wide margins with axillary dissections	No recurrence after 3 months
Quiñones-Martínez et al. ¹⁷	Right forearm	9.5 × 7.5 × 4.5 cm ³	81	F	Surgical excision with 1 cm free margins + skin graft	Lost to follow-up
Akrami et al. ¹⁸	Left breast	3 cm	62	F	Surgical excision with 2 cm margins	No recurrence after 6 months
Uchia et al. ⁹	Breast with metastatic axillary lymph node	10 × 10 cm ²	67	F	Radical mastectomy with axillary dissection	No recurrence after 8 months
Cui et al. ¹⁹	Anus	3 cm	73	F	Local excision with close follow-up	No recurrence after 1 year
D'Avila et al. ²⁰	Perianal	3 cm	56	F	Surgical excision with safety margins	Not reported
Waziri et al. ¹⁰	Gluteal	12 × 8 cm	69	M	Deep resection	Not reported
Yi et al. ¹⁶	Left thigh	5 × 5 × 4 cm	63	F	Wide surgical excision	Recurrence and metastasis after 2 years

due to misdiagnosis as primary SCC,⁹ or that presented by Waziri et al. with the impression of lipoma.¹⁰

Diagnosis of malignant PTT for the present case was performed by postoperative histopathologic examination, which resulted in observation of necrosis, high mitotic count, and atypia, advocated as the hallmarks of diagnosis.⁴ Others have also suggested the positivity of immunohistochemical markers, like CD34, in malignant PTT,¹¹ which have not been tested in the present study. Yet, more definite classifications are required for a better differentiation of the types.¹² Fine needle biopsy has been suggested as inappropriate diagnostic method, and full excision is required.¹³ Beside the difficulty of diagnosis, the optimal treatment of malignant PTT is also controversial; some suggest radical excision as the solitary treatment required, while others suggest the need for adjuvant therapies.⁶ There is also report of a successful radical radiotherapy in a case with inability to undergo surgery.¹⁴

For the choice of treatment, we have performed wide surgical excision and the results of follow-up showed success of this treatment without recurrence or metastasis to other sites. This is while some report metastasis and recurrence of malignant PTT.^{15,16} The results of Table 2 also show that the majority of malignant PTT, at sites other than head and neck, have undergone surgical excision with wide margins (1–2 cm) without adjuvant therapy, which is similar to the treatment performed in the present study. But we cannot definitely state that this treatment is appropriate for this type of neoplasm, as most studies have not reported the long-term outcome of the patients or have only reported 3–6 months' follow-up results.

4 | CONCLUSION

This paper presents a rare neoplasm, malignant PTT, at a rare site and rare gender, which has been diagnosed by postoperative histopathologic assessment. Fortunately, the wide excision cured the patient's problem without recurrence or metastasis until the publication of this paper. This report emphasizes on the importance of considering malignant PTT at any part of the body's skin, in order to reduce misdiagnosis and mistreatment of the patients and improve the patients' prognosis.

ACKNOWLEDGEMENTS

The authors would like to thank the Clinical Research Development Center of Imam Reza Hospital for Consulting Services.

CONFLICTS OF INTEREST

The authors declare that there is no conflict of interest.

AUTHOR CONTRIBUTION

M.A. performed the histopathology examination and diagnosis. M.R. performed the histopathology consultation and confirmation. M.A. designed the figures. M.A. and M.R. wrote the manuscript and contributed to the final version of the manuscript.

ETHICAL APPROVAL

This case report is ethically according to the world medical association declaration of Helsinki.

CONSENT

Written informed consent is obtained from the patient to publish this report.

DATA AVAILABILITY STATEMENT

The data that support the findings of this study are available on request from the corresponding author. The data are not publicly available due to privacy or ethical restrictions.

ORCID

Mazaher Ramezani  <https://orcid.org/0000-0003-1897-7410>

REFERENCES

- Jones EW. Proliferating epidermoid cysts. *Arch Dermatol*. 1966;94(1):11-19.
- Shimizu Y, Sakita K, Arai E, et al. Clinicopathologic features of epidermal cysts of the sole: comparison with traditional epidermal cysts and trichilemmal cysts. *J Cutan Pathol*. 2005;32(4):280-285.
- Goyal S, Jain BB, Jana S, Bhattacharya SK. Malignant proliferating trichilemmal tumor. *Indian J Dermatol*. 2012;57(1):50.
- Ye J, Nappi O, Swanson PE, Patterson JW, Wick MR. Proliferating pilar tumors: a clinicopathologic study of 76 cases with a proposal for definition of benign and malignant variants. *Am J Clin Pathol*. 2004;122(4):566-574.
- Saida T, Oohard K, Hori Y, Tsuchiya S. Development of a malignant proliferating trichilemmal cyst in a patient with multiple trichilemmal cysts. *Dermatology*. 1983;166(4):203-208.
- Deshmukh BD, Kulkarni MP, Momin YA, Sulhyan KR. Malignant proliferating trichilemmal tumor: a case report and review of literature. *J Cancer Res Ther*. 2014;10(3):767.
- Rao S, Ramakrishnan R, Kamakshi D, Chakravarthi S, Sundaram S, Prathiba D. Malignant proliferating trichilemmal tumour presenting early in life: an uncommon feature. *J Cutan Aesthet Surg*. 2011;4(1):51.
- Aneiros-Fernandez J, Jimenez-Rodriguez JM, Martin A, Arias-Santiago S, Concha A. Giant proliferating trichilemmal malignant tumor. *Indian J Dermatol Venereol Leprol*. 2011;77(6):730.
- Uchida N, Tsuzuki Y, Ando T, et al. Malignant proliferating trichilemmal tumor in the skin over the breast: a case report. *Breast Cancer*. 2000;7(1):79-82.
- Waziri GD, Suleiman DE, Mohammed TT, Samaila MO. Gluteal malignant proliferating pilar tumor: an unusual presentation in an elderly male. *Ann Trop Pathol*. 2018;9(2):164.
- Chaichamnan K, Satayasontorn K, Puttanupaab S, Attainsee A. Malignant proliferating trichilemmal tumors with CD34 expression. *J Med Assoc Thai*. 2010;93(Suppl 6):S28-S34.
- Sharma R, Sharma S, Verma P, Yadav P. Proliferating trichilemmal tumor of scalp: benign or malignant, a dilemma. *J Cutan Aesthet Surg*. 2012;5(3):213.
- Kini JR, Kini H. Fine-needle aspiration cytology in the diagnosis of malignant proliferating trichilemmal tumor: report of a case and review of the literature. *Diagn Cytopathol*. 2009;37(10):744-747.
- Sutherland D, Roth K, Yu E. Malignant proliferating trichilemmal tumor treated with radical radiotherapy: a case report and literature review. *Cureus*. 2017;9(1):e999.
- Dubhashi S, Jadhav S, Parasnis A, Patil C. Recurrent malignant proliferating trichilemmal tumor with lymph node metastasis in a young woman. *J Postgrad Med*. 2014;60(4):400.
- Yi HS, Sym SJ, Park J, et al. Recurrent and metastatic trichilemmal carcinoma of the skin over the thigh: a case report. *Cancer Res Treat*. 2010;42(3):176.
- Quiñones-Martínez A, Nieves-Ríos C, Bolaños-Ávila G. Malignant proliferating trichilemmal tumor of the forearm: a case report of an unusual location of a rare cutaneous adnexal tumor. *J Surg Case Rep*. 2018;2018(10):rjy290.
- Akrami M, Talei A, Nazemzadegan B, et al. Low grade malignant proliferating pilar tumor arising from breast skin simulating squamous cell carcinoma, a case report. *Indian J Surg Oncol*. 2013;4(4):397-398.
- Cui A, Mei Z, Cui L. Anal malignant proliferative trichilemmoma: report of a rare case with review of literature. *Int J Clin Exp Pathol*. 2015;8(3):3349.
- D'Avila DG, Kanno DT, da Silva DDC, et al. A proliferating trichilemmal cyst in the perianal region: a case report. *Int J Surg Case Rep*. 2018;53:175-178.

How to cite this article: Azizi M, Ramezani M. Malignant proliferating trichilemmal tumor in abdominal wall: Report of a rare case at an uncommon site with literature review. *Clin Case Rep*. 2022;10:e05259. doi:[10.1002/ccr3.5259](https://doi.org/10.1002/ccr3.5259)