

A comparative evaluation of electronic and radiographic determination of root canal length in primary teeth: An *in vitro* study

IYER SATISHKUMAR KRISHNAN, SHEELA SREEDHARAN

Abstract

Aims: The purpose of this *in vitro* study was to compare the root canal length determination by Electronic apex locator (EAL) (Raypex 5) and conventional radiography, and then compare them with the actual measurements obtained by direct visualization. **Settings and Design:** This study was conducted at the Department of Pedodontics and Preventive Dentistry, Government Dental College, Thiruvananthapuram, Kerala, India. **Subjects and Methods:** One hundred single rooted primary teeth extracted due to extensive caries, trauma, serial extraction or unwillingness of the parent to save the teeth were selected. The teeth were numbered and root canal length was determined using the visual, electronic and the radiographic methods. The actual, electronic and the radiographic measurements were recorded. **Statistical Analysis Used:** Data were analyzed using Intraclass correlation test and linear regression analysis. **Results:** The accuracy of EAL and radiographic methods were 92% and 72%, respectively within + 0.5 mm. Both the electronic and conventional radiographic methods showed a high correlation and agreement (ICC intraclass correlation coefficient = 0.99 and 0.98 respectively) with the actual measurements. **Conclusions:** EALs proved to be more accurate in determining the root canal length than the radiographic method.

Keywords: Electronic apex locators, intraoral periapical radiography, primary teeth, root canal length determination

Introduction

Root canal treatment helps to maintain the integrity of primary dentition until their normal exfoliation when pulp becomes infected. Preservation of a primary tooth whose pulp has been endangered is a unique challenge to the pediatric dentist in caring for the teeth of children. Age and behavior of the child compromise a lot on the success of the treatment.^[1] Moreover; morphological configurations of the root canals in primary teeth make mechanical debridement and subsequent filling difficult. The objective in pulp therapy by the pediatric dentist has always been the same, i.e., to retain the tooth in a non-pathologic, healthy condition, fulfill its role in mastication and also act as an excellent space maintainer for the permanent dentition. In addition, the factors of comfort, speech and prevention of aberrant

habits can be best controlled by retention of primary tooth in the dental arch.

The success of a pulpectomy procedure mainly depends on accurate determination of the root canal length. A working length established beyond the apical foramen may cause apical perforation and overfilling. Alternately, a working length established short of the apical foramen may lead to inadequate debridement and underfilling. Retained pulp tissue may persist and cause prolonged pain. Several techniques have been proposed to determine root canal length, but the ideal procedure is yet to be identified. Traditionally, radiographs were the primary tool for determining primary root canal lengths for pulpectomy procedures.^[2] Dental radiography enabled the clinician to visualize the extent of the tooth, the obturating material and the periradicular structures. Radiographic determination of canal lengths, however, is subject to several problems. Radiographs are two dimensional images of a three dimensional structure.^[3] It is often impossible to locate structures in the buccolingual aspect due to superimposition. Root resorption and superimposition of permanent successors over the primary root apices very well obscure canal length determination. Radiographic distortion also compromises accurate location of root apices.^[4-6] In addition, radiographs are highly dependent on patient cooperation, especially in child patients. Radiographs lengthen appointment time, and most importantly, expose patients to ionizing radiation. In spite of these drawbacks, it still remains the most commonly used method to determine the root canal length.

Electronic apex locators (EALs) have attracted a great deal of attention as they operate on the basis of electronic principles rather than by a visual inspection. They were developed, in

Department of Pedodontics and Preventive Dentistry, Government Dental College, Trivandrum, Kerala, India

Correspondence: Dr. Iyer Satishkumar Krishnan, Room No. 401, Department of Pedodontics, Government Dental College, Trivandrum, Kerala, India.
E-mail: dr.satishiyer@gmail.com

Access this article online	
Quick Response Code: 	Website: www.contempclindent.org
	DOI: 10.4103/0976-237X.107430

an attempt to obtain more precise measurements of root length and to establish the apical limit of instrumentation.^[7] Since then, they have been widely used on permanent teeth. The use of apex locators in primary teeth has however not gained much popularity. The measurements appear to be less accurate when the apical foramen is immature or large, which is often the case in primary teeth as they constantly undergo physiologic root resorption.^[8] Investigators who carried out *in vivo* and *in vitro* studies with apex locators on primary teeth concluded that EALs are safe, painless, accurate and extremely useful because they avoid unnecessary radiation exposure to children.^[9,10]

The purpose of this study was to evaluate the accuracy of EAL and conventional radiographic technique in determining the root canal length of primary teeth by comparing with the actual root canal length of these teeth.

Materials and Methods

The present study, *in vitro* study, was conducted in the Department of Pedodontics, Government Dental College, Thiruvananthapuram, Kerala, India to evaluate the accuracy of EAL and conventional radiographic technique in determining the root canal length of primary teeth by comparing with the actual root canal length of these teeth.

The study included 100 single rooted primary anterior teeth, which were extracted due to extensive caries, trauma, serial extraction or unwillingness of the parent to save the teeth. All the teeth selected did not show resorption more than 1/3rd the root length. The extracted teeth were numbered from 1 to 100. The teeth were flattened upto the cemento enamel junction to create a reproducible reference point. Actual measurements were recorded by inserting a 21 mm size 15 K – File into the canal till the tip of the instrument flushed with the apical foramen. Rubber stoppers were then moved to the coronal reference point to mark each canal's length. The files were removed, and root canal lengths were determined using a digital vernier caliper [Figure 1]. This actual measurement was

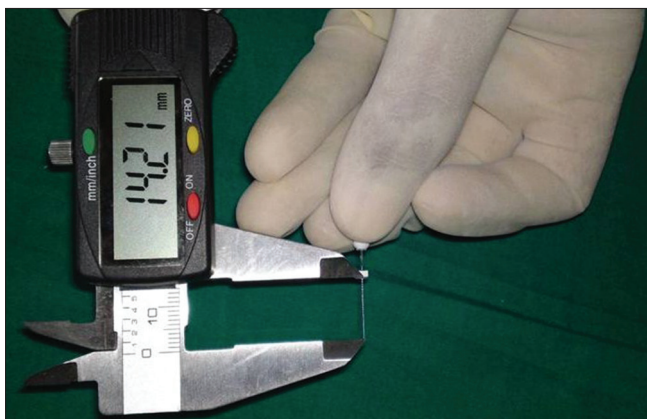

Figure 1: Measurement of the actual length using digital vernier caliper

considered as the gold standard to which the electronic and the radiographic measurements were compared.

Raypex 5, a fourth generation apex locator manufactured and marketed by VDW endodontic surgery, Munich, Germany was used to determine the root canal length electronically.^[11] The impedance measurement of this apex locator is based on advanced multi-frequency system and the device has the latest digital technology, which makes it easier for the clinician to obtain accurate readings. The large display which shows separate apex zoom graphic of the last apical third and foldable backlight display, which can be adjusted to the desired viewing angle make it user friendly. This device had the following advantages over the routinely used apex locators, like reliability, accurateness, user friendliness, patient friendliness and safety.

In vivo conditions were simulated by embedding the teeth in an alginate model as described by Kaufman in his study.^[12] A metal rod was inserted into the alginate before it set to provide an attachment for the contrary electrode. The canals were irrigated with 3% sodium hypochlorite solution and subsequently dried using paper points. The lip-clip (contrary electrode) was attached to the metal rod and the file holder was attached onto the shaft of a 21 mm size 15 K – file. The file with the rubber stopper adapted to the reference point was advanced apically into the canal, until the beeping sound and the light-emitting diode marked the APEX on the panel, indicating that the tip of the file had reached the predetermined length of the apical constriction [Figure 2]. The file was carefully withdrawn from the canal and the measurements were recorded using the same digital vernier caliper. All measurements were made in intervals of 2 h, with the alginate kept sufficiently humid for this period of time.

The root canal lengths were then determined by the conventional radiographic method. The alginate block was




Figure 2: Electronic apex locator indicating the apical constriction

cut in such a way that the tooth was positioned parallel to the X-ray film. To minimize image distortion, radiographs were taken according to the paralleling technique using an X-ray equipment operating at 7 Ma and 60 Kvp.^[13] An E – speed dental X-ray film was placed parallel to the teeth, maintaining a 20 cm focus-film distance using a position indicating device and 0.2 s exposure time [Figure 3]. A metallic mesh grid with 1 mm × 1 mm calibration was placed in between the teeth and the film to facilitate obtaining accurate measurements. The length of the tooth was measured by the traditional radiographic method using the same digital vernier caliper.

The final step was to compare the electronic and the radiographic measurements with the gold standard value, i.e., the actual root canal length. This was done using intraclass correlation coefficient. Linear regression analysis was performed in order to predict the actual values using the electronic and the conventional radiographic methods. Furthermore, the differences between the electronic and actual measurements and radiographic and the actual measurements were calculated and compared.

Results

Both the electronic and the conventional radiographic methods displayed very high correlation and agreement (ICC = 0.99 and 0.98 respectively) with the actual measurements. The electronic and the radiographic methods, on comparison, also suggested a high correlation and agreement (ICC = 0.97) [Table 1]. The radiographic technique overestimated the root canal length in 95% of the total sample. In spite of this overestimation, the radiographic method showed an accuracy of 72% within + 0.5 mm and 95% within + 1 mm. The EAL showed an accuracy of 92% within + 0.5 mm and 100% within + 1 mm. Regression analysis showed that the EAL could predict the actual value with 98.2% accuracy [Table 2] whereas the radiographic method could predict the actual value with 93.9% accuracy [Table 3].



Figure 3: Radiographs taken using the paralleling technique with 1 × 1 mm metallic mesh grid placed between the sample and the film

Discussion

The determination of an accurate working length during root canal treatment of primary teeth is necessary to promote complete cleaning and disinfection of the root canals as well as to avoid damage to the permanent tooth germ.^[14] The use of EALs overcomes several limitations inherent with radiographic methods. Current EALs have high reliability, high accuracy, and high reproducibility in locating the apical foramen regardless of the electrolyte.^[15] In addition to improving working length accuracy,^[16] EALs address concerns about radiation as they have the potential to reduce the number of radiographs taken during root canal treatment.^[17]

In the present study, the radiographic method showed an accuracy of 72% within + 0.5 mm and 95% within + 1 mm. The accuracy of EALs was 92% within + 0.5 mm and 100% within + 1.0 mm. None of the actual measurements coincided with those obtained by the radiographic method. On the other hand, the actual measurement and the electronic measurements coincided only in one tooth. The possible reason for this may be the use of a digital caliper which had an accuracy of 0.03 mm and the values obtained were not rounded off to the closest whole number. The radiographic method overestimated the root canal length determination in 95% of the samples whereas the EAL overestimated the canal length in only 25% of the samples. Previously, ElAyouti^[18] had stated in his study that the radiographic technique tends to overestimate the root canal length in about 51% cases. This result is also in accordance with studies conducted by Kaufman, Brunton, Mohammed, and Ehsan.^[10,12,19,20] An explanation may be that an apical foramen that is located short of the radiographic apex on the facial or lingual aspect of the

Table 1: Intraclass correlation coefficient values for the methods of study

Comparison	Average ICC values (95% Confidence interval)
Radiographic and actual	0.9841
Electronic and actual	0.9955
Electronic and radiographic	0.9775

ICC= Intraclass correlation coefficient

Table 2: Regression analysis for the electronic method

R	R square	Adjusted R square	Std. error of the estimate
0.991	0.982	0.982	0.2211

Table 3: Regression analysis for the radiographic method

R	R square	Adjusted R square	Std. error of the estimate
0.969	0.939	0.938	0.4107

Table 4: Regression analysis used to predict the actual value based on the radiographic value.

	Unstandardized coefficients		Standardized coefficients Beta	t	Sig.	95% Confidence interval for B	
	B	Std. error				Lower bound	Upper bound
(Constant)	-0.415	0.280		-1.486	0.141	-0.970	0.139
Radiographic measurement	0.999	0.026	0.969	38.871	0.000	0.948	1.050

Table 5: Regression analysis used to predict the actual value based on the electronic value

	Unstandardized coefficients		Standardized coefficients Beta	t	Sig.	95% Confidence interval for B	
	B	Std. error				Lower bound	Upper bound
(Constant)	7.131E-02	0.141		0.507	0.614	-0.208	0.351
Electronic measurement	1.005	0.014	0.991	73.838	0.000	0.978	1.032

root makes it generally difficult to identify the position of the apical foramen on the radiograph. Furthermore, some of the teeth used in this study exhibited a slight degree of resorption. The root canals frequently did not end close to the radiographic apex or the apical reference point. This may also have led to overestimation of the canal length by the radiographic method. The results of our study do not coincide with the observations made by Melo Santos and Neena *et al.*^[21,22] In this study, the radiographic method provided ICC of 0.9686 for single measure and 0.9841 for average measure with the actual measurements. The results are similar to those obtained by Shanmugaraj *et al.*^[23] This presents a very high correlation and agreement between the two methods and suggests that the radiographic method accurately records the root canal length. The results of the electronic measurements were an almost perfect correlation (ICC = 0.99) with those of the direct method. The single measure ICC was 0.9910 and the average measure ICC was 0.9955.

A linear regression analysis was done between the radiographic and actual measurements. Based on the independent variable (radiographic measurement), linear regression analysis provides the investigator an equation which can be used to predict the values of the dependent variable (actual length). Regression analysis suggested that the radiographic method could predict 93.2% of the actual values accurately. EALs could predict 98.2% of the actual measurements accurately.

A regression equation was developed by which the actual values could be predicted using either the radiographic or the electronic values. The regression equations for the radiographic and electronic methods are as follows:

Actual value = -0.415 + 0.999 (Radiographic measurement)...
[Table 4]

Actual value = 0.07131 + 1.005 (Electronic measurement)...
[Table 5]

In this study, the presence of resorption did not affect the accuracy of EAL. This finding has been previously corroborated by Katz *et al.*,^[2] Mente *et al.*,^[24] and Kielbassa *et al.*^[25] Two *ex vivo* studies conducted by Leonardo *et al.*,^[26,27] who assessed the accuracy of Root ZX II locator and Digital Signal Processing, respectively, revealed no significant difference between single-rooted or multirooted teeth as well between roots with resorption and roots without resorption.

Conclusion

EALs eliminate the need for an additional radiograph during the pulpectomy procedure thereby reducing ionizing radiation to the child patient as well as the clinician. The diagnostic radiograph may be used as a tool for complementing and/or assisting the electronic method to determine the root canal length. The results of this study from conventional radiography and EAL were similar; intra-class correlation coefficient also showed that both the radiographic and electronic methods are reliable in determining the root canal length and there is no need to use them together.

References

1. Ingle J, Backland LK. Pediatric Endodontics. Endodontics. 5th ed. Philadelphia: Lea and Febiger; 2002. p. 861.
2. Katz A, Mass E, Kaufman AY. Electronic apex locator: A useful tool for root canal treatment in the primary dentition. ASDC J Dent Child 1996;63:414-7.
3. Pineda F, Kuttler Y. Mesiodistal and buccolingual roentgenographic investigation of 7,275 root canals. Oral Surg Oral Med Oral Pathol 1972;33:101-10.
4. Gelfand M, Sunderman EJ, Goldman M. Reliability of radiographical interpretations. J Endod 1983;9:71-5.
5. Stein TJ, Corcoran JF. Radiographic "working length" revisited. Oral Surg Oral Med Oral Pathol 1992;74:796-800.
6. Ghaemmaghani S, Eberle J, Duperon D. Evaluation of the Root ZX apex locator in primary teeth. Pediatr Dent 2008;30:496-8.
7. Plotino G, Grande NM, Brigante L, Lesti B, Somma F. *Ex vivo* accuracy of three electronic apex locators: Root ZX, Elements Diagnostic Unit and Apex Locator and ProPex. Int Endod J 2006;39:408-14.

8. Finn SB. Pulpal treatment of Primary teeth. Clinical Pedodontics. 4th ed. Philadelphia, USA: Saunders; 1995. p. 201-23.
9. Bodur H, Odabaş M, Tulunoğlu O, Tinaz AC. Accuracy of two different apex locators in primary teeth with and without root resorption. Clin Oral Investig 2008;12:137-41.
10. Brunton PA, Abdeen D, MacFarlane TV. The effect of an apex locator on exposure to radiation during endodontic therapy. J Endod 2002;28:524-6.
11. Stavrianos, Vasiliadis L, Stavrianou I, Louloudiadias A. *In vitro* Evaluation of the ability of Ray-Pex 5 to determine the working length in teeth with simulated apical root resorption. Balk J Stom 2009;13:96-8.
12. Kaufman AY, Keila S, Yoshpe M. Accuracy of a new apex locator: An *in vitro* study. Int Endod J 2002;35:186-92.
13. BhakdinaronkA, Manson-Hing LR. Effect of radiographic technique upon prediction of tooth length in intraoral radiography. Oral Surg Oral Med Oral Pathol 1981;51:100-7.
14. Cohen S, Burns RC. Pediatric Endodontic Treatment. Pathways of the Pulp. 6th ed.. St Louis, MO: Mosby Co; 1998. p. 633-71.
15. Jenkins JA, Walker WA 3rd, Schindler WG, Flores CM. An *in vitro* evaluation of the accuracy of the root ZX in the presence of various irrigants. J Endod 2001;27:209-11.
16. Nekoofar MH, Ghandi MM, Hayes SJ, Dummer PM. The fundamental operating principles of electronic root canal length measurement devices. Int Endod J 2006;39:595-609.
17. Pagavino G, Pace R, Baccetti T. A SEM study of *in vivo* accuracy of the Root ZX electronic apex locator. J Endod 1998;24:438-41.
18. ElAyouti A, Weiger R, Löst C. The ability of root ZX apex locator to reduce the frequency of overestimated radiographic working length. J Endod 2002;28:116-9.
19. Ehsan S. Comparative role of radiographs and electronic apex locators in working length determination. Pak Oral Dental J 2011;31:187-90.
20. Mohammed AG. An *in vitro* comparison of root canal length measurements in primary teeth. Al-Rafidain Dent J 2009;9:77-82.
21. deMelo Santos L, dosReis JI. Comparative analysis of the electronic and radiographic determination of root canal length in primary molars: An *ex vivo* study. Braz J Oral Sci 2009;8:189-92.
22. Neena IE, Ananthraj A, Praveen P, Karthik V, Rani P. Comparison of digital radiography and apex locator with the conventional method in root length determination of primary teeth. J Indian Soc Pedod Prev Dent 2011;29:300-4.
23. Shanmugaraj M, Nivedha R, Mathan R, Balagopal S. Evaluation of working length determination methods: An *in vivo/ex vivo* study. Indian J Dent Res 2007;18:60-2.
24. Mente J, Seidel J, Buchalla W, Koch MJ. Electronic determination of root canal length in primary teeth with and without root resorption. Int Endod J 2002;35:447-52.
25. Kielbassa AM, Muller U, Munz I, Monting JS. Clinical evaluation of the measuring accuracy of ROOT ZX in primary teeth. Oral Surg Oral Med Oral Pathol Oral Radiol Endod 2003;95:94-100.
26. Leonardo MR, da Silva LA, Nelson-Filho P, da Silva RA, Lucisano MP. *Ex vivo* accuracy of an apex locator using digital signal processing in primary teeth. Pediatr Dent 2009;31:320-2.
27. Leonardo MR, Silva LA, Nelson-Filho P, Silva RA, Raffaini MS. *Ex vivo* evaluation of the accuracy of two electronic apex locators during root canal length determination in primary teeth. Int Endod J 2008;41:317-21.

How to cite this article: Krishnan IS, Sreedharan S. A comparative evaluation of electronic and radiographic determination of root canal length in primary teeth: An *in vitro* study. Contemp Clin Dent 2012;3:416-20.

Source of Support: Nil. **Conflict of Interest:** None declared.

Author Help: Reference checking facility

The manuscript system (www.journalonweb.com) allows the authors to check and verify the accuracy and style of references. The tool checks the references with PubMed as per a predefined style. Authors are encouraged to use this facility, before submitting articles to the journal.

- The style as well as bibliographic elements should be 100% accurate, to help get the references verified from the system. Even a single spelling error or addition of issue number/month of publication will lead to an error when verifying the reference.
- Example of a correct style
Sheahan P, O'leary G, Lee G, Fitzgibbon J. Cystic cervical metastases: Incidence and diagnosis using fine needle aspiration biopsy. Otolaryngol Head Neck Surg 2002;127:294-8.
- Only the references from journals indexed in PubMed will be checked.
- Enter each reference in new line, without a serial number.
- Add up to a maximum of 15 references at a time.
- If the reference is correct for its bibliographic elements and punctuations, it will be shown as CORRECT and a link to the correct article in PubMed will be given.
- If any of the bibliographic elements are missing, incorrect or extra (such as issue number), it will be shown as INCORRECT and link to possible articles in PubMed will be given.