

IgG4-related thyroiditis: a case report and review of literature

Mahmud Abo Salook¹, Carlos Benbassat^{1,3}, Yulia Strenov² and Amit Tirosh^{1,3}

¹Endocrine Institute ²Pathology Laboratory, Rabin Medical Center, Beilinson Campus, Petah Tiqva 49100, Israel

³Sackler School of Medicine, Tel Aviv University, Tel Aviv, Israel

Correspondence
should be addressed
to A Tirosh
Email
tiroshamit@gmail.com

Summary

A 55-year-old male, with a positive medical history for hypothyroidism, treated with stable doses for years was admitted with subacute thyroiditis and a feeling of pain and pressure in the neck. Laboratory tests showed decrease in TSH levels, elevated erythrocyte sedimentation rate, and very high antithyroid antibodies. Owing to enlarging goiter and exacerbation in the patient's complaints, he was operated with excision of a fibrotic and enlarged thyroid lobe. Elevated IgG4 plasma levels and high IgG4/IgG plasma cell ratio on immunohistochemistry led to the diagnosis of IgG4-mediated thyroiditis. We concluded that IgG4-thyroiditis and IgG4-related disease should be considered in all patients with an aggressive form of Hashimoto's thyroiditis.

Learning points

- IgG4-related disease is a systemic disease that includes several syndromes; IgG4-related thyroiditis is one among them.
- IgG4-thyroiditis should be considered in all patients with an aggressive form of Hashimoto's thyroiditis.
- Patients with suspected IgG4-thyroiditis should have blood tested for IgG4/IgG ratio and appropriate immunohistochemical staining if possible.

Background

This case is of special interest for the practice of endocrinology because it sheds light on a unique presentation of a common problem, explained by a unique systemic disease. Expanding goiter is a common disease, but its severity leads to the rare diagnosis of IgG4-related thyroiditis.

Case presentation

A 55-year-old pilot was hospitalized complaining of neck pressure, fever, and weight loss. His medical history was positive for primary hypothyroidism treated with L-thyroxin (L-T₄) at stable doses for several years, angioedema, and pernicious anemia, and a positive family

medical history of a sister with hypothyroidism. The patient denies any symptoms recently suggestive of infection or exposure to environmental pollutants at work. Physical examination revealed an enlarged and mildly tender thyroid gland. Laboratory tests revealed increased erythrocyte sedimentation rate (104 mm/h), elevated C-reactive protein levels (22.0 mg/dl, normal 0–0.5 mg/dl), thyroid-stimulating hormone (TSH) 0.13 mIU/l (normal, 0.35–4.2, patient baseline 4.6–10.7 in the previous four years), FT₄ 23 pmol/l (normal, 10.2–19.8), anti-TPO Ab 12 590 IU/ml, and anti-TG Ab 504 070 IU/ml. Plasma protein electrophoresis showed polyclonal hyperglobulinemia, with normal immunofixation. Neck ultrasound demonstrated diffuse hypoechoic goiter, hypervascular on doppler, and Tc99 thyroid scintigraphy showed suppressed uptake. Subacute

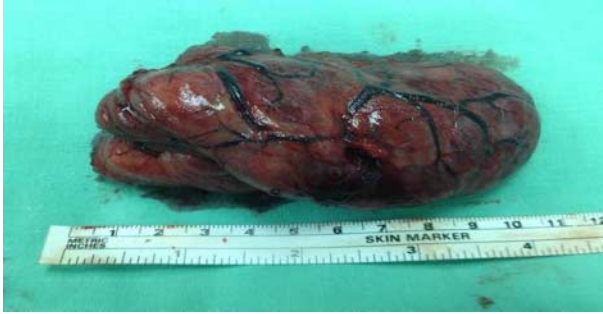

Figure 1
Excised left lobe of the thyroid gland showing significant enlargement.

thyroiditis was suspected, L-T₄ was stopped, and non steroidal anti-inflammatory drugs (NSAIDs) were started.

Investigation

During ambulatory follow-up, TSH levels increased gradually and L-T₄ was re-started, with a required daily dose of 300 µg/day. Ultrasound-guided FNA was performed and cytology showed poor material with colloid, few Hurthle cells, grouped follicular cells, and tissue destruction. As neck pain and pressure worsened, a decision was made to perform a thyroidectomy. On operation, the recurrent laryngeal nerve seemed to be damaged due to the mass effect of a stiff thyroid gland (size 5×5.5×8 cm, weight 83 g; Fig. 1), hence only hemithyroidectomy was performed. Pathology of the excised lobe showed extensive fibrotic process, heavy plasmacytic infiltrates, and storiform fibrosis (Fig. 2), which immunostained strongly for IgG and IgG4 (Figs 3 and 4 respectively) with an IgG4/IgG ratio higher than 80%. Serum IgG4 level was 737 mg/dl (normal, 3–201), with normal IgG1 and IgG3 levels and borderline IgG2 levels (805, normal 169–786 mg/dl). Thus, a diagnosis of IgG4-related thyroiditis was established. Eight months after the left hemithyroidectomy, the patient underwent completion right hemithyroidectomy for esthetical reasons. The pathology report was the same as that of the first operation.

Outcome and follow-up

Two months after the second operation, IgG4 plasma levels dropped by half and, 3 months later, it became completely normalized.

Discussion

In 2001, Hamano *et al.* (1) described elevated IgG4 plasma levels in sera of patients with autoimmune

pancreatitis (AIP). Few years later, IgG4-positive cells were found in other organs and the term IgG4-related systemic disease was suggested (2). IgG4-related disease is now considered a systemic disease that might affect every organ with progressively growing fibroinflammatory lesions causing a mass effect. Its diagnosis is based on a typical histology (dense lymphoplasmacytic infiltrates, storiform fibrosis, mild eosinophilic infiltration, and obliterative phlebitis), high count of IgG4-positive plasma cells per high-power field (HPF), and high IgG4/IgG ratio. Diagnostic criteria for IgG4-related disease (IgG4-RD) have been proposed (3), and two criteria were established: IgG4 plasma level of > 135 mg/dl and an IgG4/IgG plasma cell ratio of > 40% with > 10 IgG4-positive plasma cells per HPF.

Several clinical entities considered distinct now fall within the spectrum of IgG4-RD, among them are retroperitoneal fibrosis (Ormond's disease), eosinophilic angiocentric fibrosis, and inflammatory aortic aneurysm and inflammatory pseudotumor. Naitoh *et al.* (4) described extrapancreatic lesions in 61 out of 64 (95%) patients with AIP, with frequencies of 84% for sclerosing cholangitis, 77% for mediastinal or hilar lymphadenopathy, 23% for sclerosing sialadenitis, and 16% for retroperitoneal fibrosis. IgG4 is also involved in the pathophysiology of other autoimmune disorders including anti-ADAMTS13 autoantibodies in thrombotic thrombocytopenic purpura and anti-M-type phospholipase A2 receptor autoantibodies in idiopathic membranous glomerulonephritis. However, these are distinct both clinically and pathologically from the IgG4-RD.

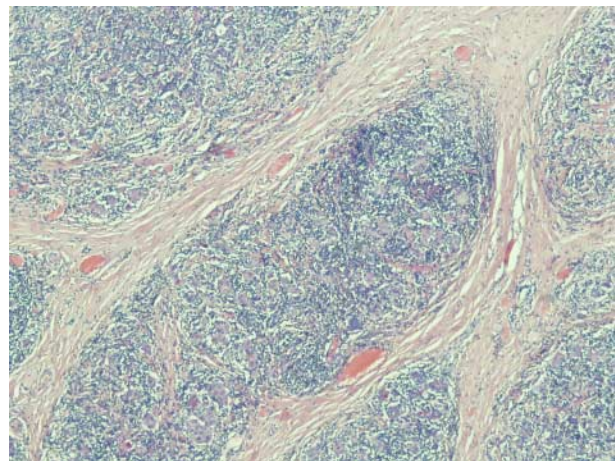


Figure 2
Histopathology showing heavy plasmacytic infiltrates and a storiform fibrosis typical of IgG4-related disease of the thyroid gland.

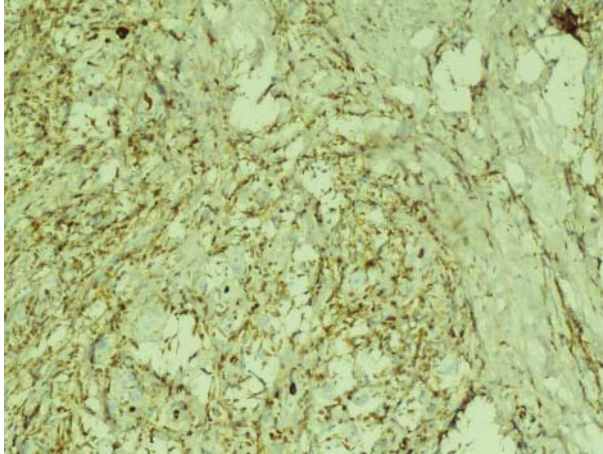


Figure 3
Immunohistochemistry showing plasmacytic cells stained for IgG.

Involvement of the thyroid gland in IgG4-RD remains a controversial issue. In a series of 64 patients, Hamano *et al.* (5) found antithyroid antibodies in 41% and hypothyroidism in 22%. No biopsies were performed and no case of Riedel's thyroiditis (RT) was observed. Thyroid abnormalities were not reported in subsequent studies by Naitoh *et al.* (5), $n=64$, Notohara *et al.* (6), $n=35$, Masaki *et al.* (7), $n=64$, and Takuma *et al.* (8), $n=56$. Owing to the high prevalence of retroperitoneal fibrosis in IgG4-RD, it has been suggested that RT can be one of its extrapancreatic manifestations. Indeed, some publications have described IgG4 abnormalities in RT. Pusztaszeri *et al.* (9) described a patient with a rapidly expanding thyroid nodule. On pathology 70 IgG4-positive

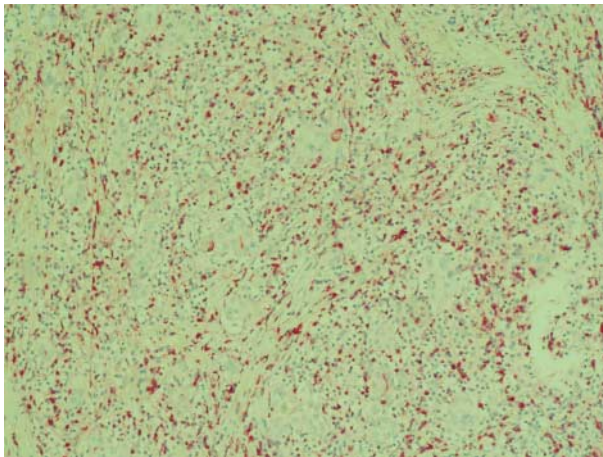


Figure 4
Immunohistochemistry showing that most of the IgG-positive plasmacytic cells are also stained for IgG4.

plasma cells per HPF were found, with a 70% IgG4/IgG ratio. Despite normal plasma IgG4 levels and no other organ involvement, the authors concluded that RT with high IgG4-positive plasma levels might be the first clinical manifestation of IgG4-RD. Dahlgren *et al.* (10) have described three patients diagnosed with RT, according to fibroinflammatory process in thyroid gland pathology. All patients had an elevated IgG4/IgG plasma cell ratio, and the patients had 10, 11, and 53 IgG4-positive plasma cells per HPF.

IgG4-related thyroiditis has been investigated by Li *et al.* (11) in a surgical series of 70 patients with Hashimoto's thyroiditis, 19 of whom were immunostained positive for IgG4. This subgroup was characterized by a higher male/female ratio, more rapid progression, and a higher level of circulating antibodies, with no clinical evidence of other organ involvement. The authors concluded that IgG4-related thyroiditis constitutes a distinct and more aggressive form of Hashimoto's thyroiditis, as it was the case in our patient. As AIP can be preceded by its extrapancreatic manifestations and its association with hypothyroidism remains unclear, we suggest considering IgG4-RD in all patients with IgG4-related thyroiditis.

Declaration of interest

The authors declare that there is no conflict of interest that could be perceived as prejudicing the impartiality of the research reported.

Funding

This research did not receive any specific grant from any funding agency in the public, commercial, or not-for-profit sector.

Patient consent

A written informed consent was obtained from the patient for publication of the submitted article and the accompanying images.

Author contribution statement

Mahmud Abo Salook was the physician of the patient. Carlos Benbassat was the senior physician in charge and performed literature review. Yulia Strenov was the case pathologist. Amit Tirosh performed data gathering, literature review, and case report writing.

References

- 1 Hamano H, Kawa S, Horiuchi A, Unno H, Furuya N, Akamatsu T, Fukushima M, Nikaido T, Nakayama K, Usuda N *et al* 2001 High serum IgG4 concentrations in patients with sclerosing pancreatitis. *New England Journal of Medicine* **344** 732–738. (doi:10.1056/NEJM200103083441005)



- 2 Kamisawa T, Funata N, Hayashi Y, Eishi Y, Koike M, Tsuruta K, Okamoto A, Egawa N & Nakajima H 2003 A new clinicopathological entity of IgG4-related autoimmune disease. *Journal of Gastroenterology* **38** 982–984. (doi:10.1007/s00535-003-1175-y)
- 3 Umehara H, Okazaki K, Masaki Y, Kawano M, Yamamoto M, Saeki T, Matsui S, Yoshino T, Nakamura S, Kawa S *et al* 2012 Comprehensive diagnostic criteria for IgG4-related disease (IgG4-RD), 2011. *Modern Rheumatology* **22** 21–30. (doi:10.3109/s10165-011-0571-z)
- 4 Naitoh I, Nakazawa T, Ohara H, Ando T, Hayashi K, Tanaka H, Okumura F, Miyabe K, Yoshida M, Sano H *et al* 2010 Clinical significance of extrapancreatic lesions in autoimmune pancreatitis. *Pancreas* **39** 1–5. (doi:10.1097/MPA.0b013e3181bd64a1)
- 5 Hamano H, Arakura N, Muraki T, Ozaki Y & Kiyosawa K 2006 Prevalence and distribution of extrapancreatic lesions complicating autoimmune pancreatitis. *Journal of Gastroenterology* **41** 1197–1205. (doi:10.1007/s00535-006-1908-9)
- 6 Notohara K, Burgart LJ, Yadav D, Chari S & Smyrk TC 2003 Idiopathic chronic pancreatitis with periductal lymphoplasmacytic infiltration. Clinicopathological features of 35 cases. *American Journal of Surgical Pathology* **27** 1119–1127. (doi:10.1097/00000478-200308000-00009)
- 7 Masaki Y, Dong L, Kurose N, Kitagawa K, Morikawa Y, Yamamoto M, Takahashi H, Shinomura Y, Imai K, Saeki T *et al* 2009 Proposal for a new clinical entity, IgG4-positive multiorgan lymphoproliferative syndrome: analysis of 64 cases of IgG4-related disorders. *Annals of the Rheumatic Diseases* **68** 1310–1315. (doi:10.1136/ard.2008.089169)
- 8 Takuma K, Kamisawa T, Anjiki H, Naoto E & Igarashi Y 2010 Metachronous extrapancreatic lesions in autoimmune pancreatitis. *Internal Medicine* **49** 529–533. (doi:10.2169/internalmedicine.49.3038)
- 9 Puztaszeri M, Triponez F, Pache JC & Bongiovanni M 2012 Riedel's thyroiditis with increased IgG4 plasma cells: evidence for an underlying IgG4-related sclerosing disease? *Thyroid* **22** 964–968. (doi:10.1089/thy.2011.0404)
- 10 Dahlgren M, Khosroshahi A, Nielsen GP, Deshpande V & Stone JH 2010 Riedel's thyroiditis and multifocal fibrosclerosis are part of the IgG4-related systemic disease spectrum. *Arthritis Care & Research* **62** 1312–1318. (doi:10.1002/acr.20215)
- 11 Li Y, Nishihara E, Hirokawa M, Taniguchi E, Miyauchi A & Kakudo K 2010 Distinct clinical, serological, and sonographic characteristics of Hashimoto's thyroiditis based with and without IgG4-positive plasma cells. *Journal of Clinical Endocrinology and Metabolism* **95** 1309–1317. (doi:10.1210/jc.2009-1794)

Received in final form 4 July 2014

Accepted 9 July 2014