

# Sex determination using maxillary sinus

Ranjith Kumar Kanthem,  
Venkateswara Rao  
Guttikonda,  
Sivaranjani Yeluri,  
Geetha Kumari

Department of Oral Pathology  
and Microbiology, Mamata  
Dental College and Hospital,  
Khammam, Andhra Pradesh,  
India

## Address for correspondence:

Dr. Ranjith Kumar Kanthem,  
Department of Oral  
Pathology and Microbiology,  
Mamata Dental College  
and Hospital, Giriprasad  
Nagar, Khammam - 507 002,  
Andhra Pradesh, India.  
E-mail: sam.deepss@gmail.com

## Introduction

Sex determination is one of the important parameters in forensic identification. Gender determination in damaged and mutilated dead bodies or from skeletal remains constitutes the foremost step for identifying in medico-legal examination.<sup>[1]</sup> Matching specific features detected on the dead bodies with data recorded during the life of an individual is an important aspect in forensics, and can be performed by fingerprint analysis, deoxyribonucleic

## Abstract


**Background:** Individual identification is a subtle concept and often one of the most important priorities in mass disasters, road accidents, air crashes, fires, and even in the investigation of criminal cases. Matching specific features detected on the cadaver with data recorded during the life of an individual is an important aspect in forensics, and can be performed by fingerprint analysis, deoxyribonucleic acid matching, anthropological methods, radiological methods and other techniques which can facilitate age and sex identification. Sinus radiography is one such method that has been used for determination of the sex of an individual. Hence, an attempt is being made to use the different dimensions of the maxillary sinus in the determination of sex using coronal and axial sections of plain computed tomography (CT) scan. **Materials and Methods:** A total of 30 patients including 17 male and 13 female, visiting the Outpatient Department of the Mamata General Hospital were included as the study subjects. The dimensions of right and left maxillary sinuses of 30 subjects from plain CT were measured using SYNGO software and statistical analysis was done. **Results:** Sex determination using height, length, width, and volume of the maxillary sinus on both sides showed statistically significant results with a higher percentage of sexual dimorphism in the case of volume. **Conclusion:** Volume of the right maxillary sinus can be used as accurate diagnostic parameter for sex determination.

**Key words:** Computerized tomography, forensic identification, maxillary sinus, sexual dimorphism

acid matching, anthropological methods, radiological methods and other techniques which can facilitate age and sex identification.<sup>[2]</sup>

Determination of gender is done through various body parts, the skull, the pelvis, the long bones with an epiphysis and a metaphysis in skeletons, the mastoid process, the foramen magnum and the paranasal sinuses. In explosions, warfare, and other mass disasters like aircraft crashes, the skull and other bones are badly disfigured, however it has been reported that maxillary sinuses remain intact.<sup>[3]</sup>

Maxillary sinuses are two spaces, which are filled with air, located in the maxillary bone and can be in various sizes and shapes. Their walls are thin. The apex of the sinuses can extend into the zygomatic process and can occupy the zygomatic bone. The floor formed by the alveolar process, the first, the second and the third molars and the roots of the canines may elevate the sinuses or may perforate their floor.<sup>[3]</sup>

Access this article online	
<b>Website:</b> www.jfds.org	<b>Quick Response Code</b> 
<b>DOI:</b> 10.4103/0975-1475.154595	

Sinus radiography has been used for identification of remains and determination of sex and ancestry.<sup>[2]</sup> Computed tomography (CT) scans are excellent imaging modality used to evaluate the signal-nasal cavities. They provide an accurate assessment of the paranasal sinuses, craniofacial bones, as well as the extent of pneumatization of the sinuses.<sup>[4]</sup> It provides detailed information that is not available from standard radiographs.<sup>[5]</sup> CT measurements of maxillary sinuses are useful to support gender determination.

Sexual dimorphism refers to the systemic difference in the form (either in shape or size) between individuals of different sexes in the same species.<sup>[1]</sup> Maxillary sinuses of various species are known to exhibit sexual dimorphism. The maxillary sinus in males is larger than in females in contemporary human populations.

Based on this background, this study was done to estimate different dimensions of the maxillary sinuses to determine gender of an individual and sexual dimorphism.

## Materials and Methods

A total of 30 patients including 17 male and 13 female, visiting the Outpatient Department of the Mamata General Hospital, Khammam, Andhra Pradesh were included as the study subjects. The current study included local patients who had complained of headache without any pathology. The dimensions of right and left maxillary sinuses of 30 subjects from plain CT were measured using SYNGO software. (syngo.via<sup>2</sup> 3D software)

The following measurements were performed by radiologists:

- The right and left side height of the maxillary sinus (height-maximal craniocaudal diameter) [Figure 1]
- The right and left side depth of the maxillary sinus (depth-anterioposterior diameter) [Figure 2]
- The right and left side width of the maxillary sinus (width-maximal width) [Figure 3]
- The height measurement of the maxillary sinus was performed on coronal images, whereas measurements of the depth and width were performed on axial images.

As all three-dimensions of the maxillary sinus were measured, the volume of each maxillary sinus was also calculated using the following equation.<sup>[6]</sup>

$$\text{Volume} = (\text{height} \times \text{depth} \times \text{width} \times 0.5).$$

After measuring all dimensions statistical analysis was performed by Mann-Whitney U-test.

Sexual dimorphism is calculated using the following formula.<sup>[1]</sup>

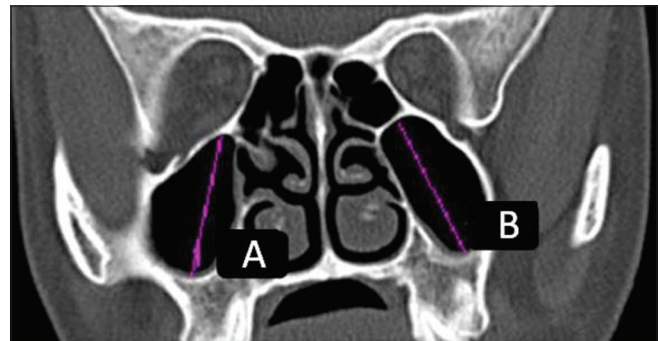
$$\text{Percentage of dimorphism} = \{(X_m/X_f) - 1\} \times 100$$

$X_m$ : Mean male maxillary sinus dimension

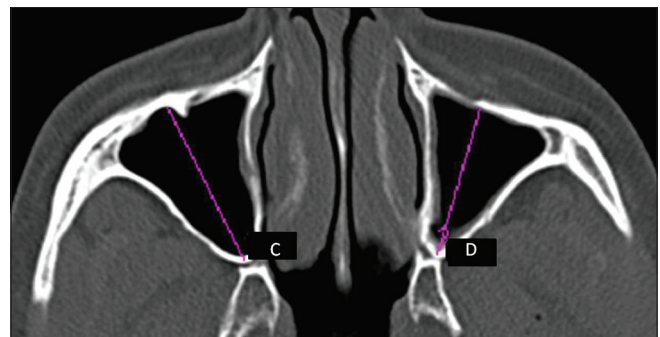
$X_f$ : Mean female maxillary sinus dimension.

## Results

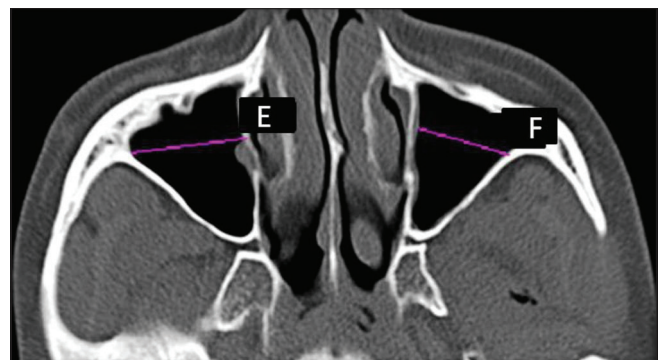
The mean values of the right side maxillary sinus height, length, width, and volume for males is 4, 3.76, 2.63, and 39.93, respectively, and in case of females it was 3.09, 3.12, 2.23, and 21.53. Sex determination using height, length, width and volume of the maxillary sinus on the right side



**Figure 1:** Axial computed tomography image showing: (a) Right side height (maximal craniocaudal diameter) of maxillary sinus. (b) Left side height (maximal craniocaudal diameter) of maxillary sinus



**Figure 2:** Coronal computed tomography image showing: (c) Right side depth (anterioposterior diameter) of maxillary sinus. (d) Left side depth (anterioposterior diameter) of maxillary sinus



**Figure 3:** Coronal computed tomography image showing: (e) Right side width (maximal width) of maxillary sinus. (f) Left side width (maximal width) of maxillary sinus

showed statistically significant results with  $P = 0.00001$ ,  $0.00001$ ,  $0.00701$ , and  $0.00001$  [Table 1 and Figure 4].

The mean values of left side maxillary sinus height, length, width and volume for males is 3.93, 3.73, 2.53, and 37.64, respectively, and in case of females it was 3.07, 3.12, 2.20, and 21.10. Sex determination using height, length, width, and volume of the maxillary sinus on the left side also showed statistically significant results with  $P = 0.00001$ ,  $0.00001$ ,  $0.0110$ , and  $0.00001$  [Table 2 and Figure 5].

The sexual dimorphism of maxillary sinus right side height, length, width, and volume showed the percentages of 29.44%, 20.51%, 17.937, and 85.46%, respectively [Table 3].

The sexual dimorphism of maxillary sinus left side height, length, width, and volume showed the percentages of 28.01%, 19.5512%, 15, and 78.38%, respectively [Table 4].

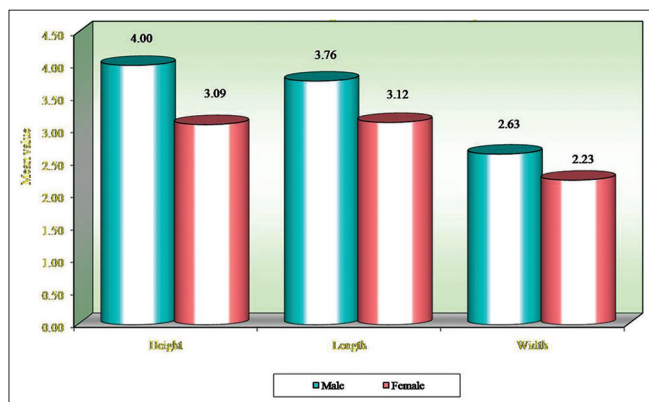
## Discussion

A forensic study is very important in the identification of sex especially when the body of the deceased has been

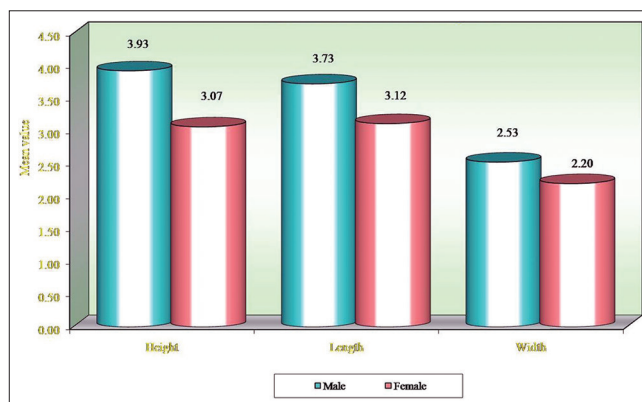
destroyed as a result of physical injury due to weapons, fire or strong chemicals. This becomes more difficult if the bones are compromised by physical insults such as explosive or violence.<sup>[7]</sup> In that case, maxillary sinus remains intact, therefore maxillary sinuses can be used for sex identification.

In addition to the maxillary sinus, sexual dimorphism can also be done using other skeletal structures such as foramen magnum, occipital bone and frontal bone. In a study done about the gender determination from the foramen magnum, the results demonstrated that sexual dimorphism is present in foramen magnum. Anteroposterior diameter and transverse diameter were higher in male skulls than females (34.04 vs. 31.72 and 28.63 vs. 26.59).<sup>[8]</sup> In another study gender determination was done using calvarial thickness in different skeletal patterns. They concluded that frontal and occipital bones can be used as important key bones for understanding the calvarial phenotypic description and sexual dimorphism.<sup>[9]</sup>

In the present study, the dimensions and volume of maxillary sinuses of right and left side were notably larger



**Figure 4:** Comparison of males and females with respect to height, length and width in right side of maxillary sinus



**Figure 5:** Comparison of males and females with respect to height, length and width in left side of maxillary sinus

**Table 1: Comparison of males and females with respect to height, length, width and volume in right side of maxillary sinus by Mann-Whitney U-test**

Parameters	Sex	n	Minimum	Maximum	Mean	Median	SD	SE	Z	P
Height	Male	17	3.64	4.43	4.00	3.97	0.22	0.05	-4.6270	0.00001*
	Female	13	2.77	3.23	3.09	3.10	0.13	0.03		
	Overall	30	2.77	4.43	3.61		0.50	0.09		
Length	Male	17	2.92	4.14	3.76	3.92	0.35	0.09	-3.9180	0.00001*
	Female	13	2.96	3.50	3.12	3.12	0.14	0.04		
	Overall	30	2.92	4.14	3.48		0.42	0.08		
Width	Male	17	2.12	3.26	2.63	2.52	0.41	0.10	-2.7110	0.00701*
	Female	13	1.98	2.60	2.23	2.22	0.19	0.05		
	Overall	30	1.98	3.26	2.46		0.38	0.07		
Volume	Male	17	26.06	53.51	39.93	38.38	9.16	2.22	-4.5830	0.00001*
	Female	13	18.17	28.21	21.53	21.05	2.69	0.75		
	Overall	30	18.17	53.51	31.95		11.63	2.12		

\* $P < 0.05$ . SD: Standard deviation, SE: Standard error

**Table 2: Comparison of males and females with respect to height, length, width and volume in left side of maxillary sinus by Mann-Whitney U-test**

Parameters	Sex	n	Minimum	Maximum	Mean	Median	SD	SE	Z	P
Height	Male	17	3.12	4.48	3.93	3.94	0.35	0.08	-4.3760	0.00001*
	Female	13	2.69	3.34	3.07	3.12	0.17	0.05		
	Overall	30	2.69	4.48	3.55		0.52	0.09		
Length	Male	17	3.10	4.31	3.73	3.79	0.32	0.08	-4.0000	0.00001*
	Female	13	2.87	3.46	3.12	3.12	0.19	0.05		
	Overall	30	2.87	4.31	3.46		0.40	0.07		
Width	Male	17	2.07	3.29	2.53	2.46	0.36	0.09	-2.5330	0.0110*
	Female	13	1.87	2.75	2.20	2.15	0.21	0.06		
	Overall	30	1.87	3.29	2.39		0.34	0.06		
Volume	Male	17	24.12	56.32	37.64	38.71	9.73	2.36	-4.2900	0.00001*
	Female	13	18.15	27.07	21.10	20.11	2.85	0.79		
	Overall	30	18.15	56.32	30.47		11.19	2.04		

\*P<0.05. SD: Standard deviation, SE: Standard error

**Table 3: Percentage of dimorphism of right side**

Parameter	Mean±SD		P	Percentage of dimorphism
	Male	Female		
Height	4±0.22	3.09±0.13	0.00001	29.44
Length	3.76±0.35	3.12±0.14	0.00001	20.512
Width	2.63±0.41	2.23±0.19	0.0701	17.937
Volume	39.93±9.16	21.53±2.69	0.00001	85.46

SD: Standard deviation

**Table 4: Percentage of dimorphism of left side**

Parameter	Mean±SD		P	Percentage of dimorphism
	Male	Female		
Height	3.93±0.35	3.07±0.17	0.00001	28.01
Length	3.73±0.32	3.12±0.19	0.00001	19.55
Width	2.53±0.36	2.20±0.21	0.0110	15
Volume	37.64±9.73	21.10±2.85	0.00001	78.38

SD: Standard deviation

in males compared with females. They showed statistically significant values with a higher percentage of sexual dimorphism in the case of volume with 85.46% for the right side and 78.38% for the left side.

Kawarai *et al.* in 1999 did a study on volume quantification of healthy paranasal cavities by three dimensional CT imaging in 20 Japanese subjects and confirmed that paranasal sinuses were individually and on the whole, apparently larger in case of males than females.<sup>[10]</sup>

Fernandes and Sahlstrand-Johnson *et al.* stated that the mean value of the maxillary sinus volume was significantly larger in males than in females. In addition to this, Fernandes, found that the European crania had significantly larger maxillary sinus volume than Zulu crania.<sup>[6,11]</sup> In case of Egyptians cephalocaudal and size of the left maxillary sinuses are a useful feature in gender determination.<sup>[12]</sup>

Teke *et al.* in 2007 studied width, length and the height of the maxillary sinus in 127 adult patients by CT and observed

that the measurements of the maxillary sinuses of males are larger than those of females. The mean estimated rate of gender was detected at 69.3%.<sup>[3]</sup>

Accordingly Uthman *et al.*, maxillary sinus height was the best discriminate parameter that could be used to study sexual dimorphism with overall accuracy of 71.6%.<sup>[13]</sup> Attia *et al.* study concluded that maxillary sinus dimension measurements, especially the right height, are valuable in studying the sexual dimorphism with overall accuracy 69.9%.<sup>[4]</sup>

Vidya *et al.* in 2013 studied 30 dry skulls of south Indian origin. The height, length, width and volume of maxillary sinuses on each side were determined. The results showed the measurements and volume of maxillary sinus of males were slightly more compared with females. The left width and right sided volume showed statistically significant values.<sup>[14]</sup>

## Conclusion

Gender determination is an important step in identifying in forensic science. The result of the present study showed that the maxillary sinus exhibits anatomic variability between the genders. Maxillary sinus dimensions, especially the right side volume are valuable in studying sexual dimorphism and the CT images could provide adequate measurements for maxillary sinus.

## References

1. Khangura RK, Sircar K, Singh S, Rastogi V. Sex determination using mesiodistal dimension of permanent maxillary incisors and canines. *J Forensic Dent Sci* 2011;3:81-5.
2. Patil N, Karjodkar FR, Sontakke S, Sansare K, Salvi R. Uniqueness of radiographic patterns of the frontal sinus for personal identification. *Imaging Sci Dent* 2012;42:213-7.
3. Teke HY, Duran S, Canturk N, Canturk G. Determination of gender by measuring the size of the maxillary sinuses in computerized tomography scans. *Surg Radiol Anat* 2007;29:9-13.

4. Attia AM, Badrawy AM, Shebel HM. Gender identification from maxillary sinus using multi-detector computed tomography. *Mansoura J Forensic Med Clin Toxicol* 2012;20:17-26.
5. White PS, Robinson JM, Stewart IA, Doyle T. Computerized tomography mini-series: An alternative to standard paranasal sinus radiographs. *Aust N Z J Surg* 1990;60:25-9.
6. Sahlstrand-Johnson P, Jannert M, Strömbeck A, Abul-Kasim K. Computed tomography measurements of different dimensions of maxillary and frontal sinuses. *BMC Med Imaging* 2011;11:8.
7. Ukoha U, Egwu OA, Okafor IJ, Anyabolu AE, Ndukwe GU, Okpala I. Sexual dimorphism in the Foramen magnum of Nigerian adult. *Int J Biol Med Res* 2011;2:878-81.
8. Radhakrishna SK, Shivarama CH, Ramakrishna A, Bhagya B. Morphometric analysis of foramen magnum for sex determination in South Indian population. *Nitte Univ J Health Sci* 2012;2:20-2.
9. Khatieeb MM. Sexual dimorphism of calvarial thickness parameter in different skeletal patterns. *Mustansiria Dent J* 2011;8:144-51.
10. Kawarai Y, Fukushima K, Ogawa T, Nishizaki K, Gunduz M, Fujimoto M, *et al.* Volume quantification of healthy paranasal cavity by three-dimensional CT imaging. *Acta Otolaryngol Suppl* 1999;540:45-9.
11. Fernandes CL. Forensic ethnic identification of crania: The role of the maxillary sinus – A new approach. *Am J Forensic Med Pathol* 2004;25:302-13.
12. Amin MF, Hassan EI. Sex identification in Egyptian population using Multidetector Computed Tomography of the maxillary sinus. *J Forensic Leg Med* 2012;19:65-9.
13. Uthman AT, Al-Rawi NH, Al-Naaimi AS, Al-Timimi JF. Evaluation of maxillary sinus dimensions in gender determination using helical CT scanning. *J Forensic Sci* 2011;56:403-8.
14. Vidya CS, Shamasundar NM, Manjunatha B, Raichurkar K. Evaluation of size and volume of maxillary sinus to determine gender by 3D computerized tomography scan method using dry skulls of South Indian origin. *Int J Curr Res Rev* 2013;5:97-100.

**How to cite this article:** Kanthem RK, Guttikonda VR, Yeluri S, Kumari G. Sex determination using maxillary sinus. *J Forensic Dent Sci* 2015;7:163-7.

**Source of Support:** Department of Radiology, Mamata General Hospital, Khammam, **Conflict of Interest:** None declared