

CASE REPORT

A Rare Case of Recurrent Intrahepatic Cholestasis of Pregnancy With Prolonged Postpartum Hepatic Inflammation Despite Normalization of Bile Acid Levels



Pir Ahmad Shah,^{1,2,‡} Akira Nishio,^{3,4,‡} Sharika Hasan,³ Lily Wu,⁵ Lucy Chie,⁵ Barbara Rehermann,^{3,*} and Daryl T.-Y. Lau^{1,*}

¹Liver Center, Department of Medicine, Beth Israel Deaconess Medical Center, Harvard Medical School, Boston, MA, United States; ²Department of Medicine, University of Texas Health Science Center at San Antonio, TX, United States (current affiliation); ³Immunology Section, Liver Diseases Branch, NIDDK, National Institutes of Health, Bethesda, MD, United States; ⁴Department of Gastroenterology and Hepatology, Osaka University Graduate School of Medicine, Suita, Osaka, Japan (current affiliation); ⁵Department of Obstetrics and Gynecology, Beth Israel Deaconess Medical Center, Harvard Medical School, Boston, MA, United States

Intrahepatic cholestasis of pregnancy is one of the most common liver diseases during the second and third trimesters of pregnancy, but its pathogenesis remains unclear. Intrahepatic cholestasis of pregnancy is associated with elevations of maternal bile acids, serum aminotransferases, and adverse fetal outcomes. Besides direct cytotoxic liver injury by bile acids, it has been suggested that bile acid-induced oxidative stress and mitochondrial injury lead to a cascade of inflammatory responses. Here, we demonstrate that the extended elevation of serum aminotransferases after normalization of bile acid levels coincides with an extended increase of the chemokine CXCL10 and inflammatory cytokines.

Keywords: Cytokines; Hepatic Inflammation; Intrahepatic Cholestasis of Pregnancy

Introduction

Intrahepatic cholestasis of pregnancy (ICP) usually presents during the second and early third trimesters of pregnancy and can lead to preterm birth, respiratory distress syndrome, and stillbirth.¹ It is characterized by elevated bile acid levels and pruritus. The elevated serum bile acids and amino acid transferases typically normalize postpartum. However, ICP can recur during the subsequent pregnancy in 60%–70% of the cases.² Our patient presented with recurrent ICP. This case is atypical for her serum aminotransferases increased postpartum despite normalization of bile acids in both pregnancies. We examined serial cytokine levels in an attempt to understand the persistent inflammatory response.

Case Report

The patient was a 31-year-old Chinese female with no family history of ICP or preexisting liver condition. During her first pregnancy, she experienced pruritus associated with

significant elevation of bile acids to 170 $\mu\text{mol/L}$ and mild alanine transaminase (ALT) increase at about 20 weeks of gestation (Figure 1A). ICP was diagnosed, and she was promptly started on ursodeoxycholic acid (UDCA). Bile acid levels decreased, and pruritus resolved. The patient had a spontaneous delivery at 30 weeks of gestation. UDCA was discontinued after delivery, and bile acids completely normalized by week 6 postpartum. ALT, however, increased to >200 U/L and persisted at >100 U/L for a prolonged period after delivery. Liver biopsy at 26 weeks postpartum reported nonspecific inflammation with no fibrosis or steatosis. ALT finally normalized by 55 weeks postpartum.

Four years later, the patient had a second pregnancy with asymptomatic elevation of bile acids at 14 weeks of gestation. By the 26th week of gestation, ALT and bile acids increased to 68 U/L and 20.8 $\mu\text{mol/L}$, respectively, (Figure 1B). She experienced mild pruritus in bilateral feet, and UDCA was initiated. The bile acid levels increased further to 53.5 $\mu\text{mol/L}$ despite UDCA treatment. Induced labor was planned at 37 weeks of gestation, and the delivery was uneventful. UDCA was discontinued postpartum. At 3 weeks postpartum, ALT increased to 259 U/L even though bile acids continued to decrease. About 1 week after restarting UDCA, ALT decreased to 62 U/L, and bile acids completely normalized. The patient became noncompliant between 8 and 12 weeks postpartum; ALT increased to 159 U/L, but bile acids stayed normal. After counseling, the patient took UDCA without interruption and ALT normalized by 18 weeks postpartum and remained within a normal range off therapy up to week 29.

*Joint senior author contribution. †Equal first author contribution.

Most current article

Copyright © 2023 Published by Elsevier Inc. on behalf of the AGA Institute. This is an open access article under the CC BY-NC-ND license (<http://creativecommons.org/licenses/by-nc-nd/4.0/>).

2772-5723

<https://doi.org/10.1016/j.gastha.2022.08.011>

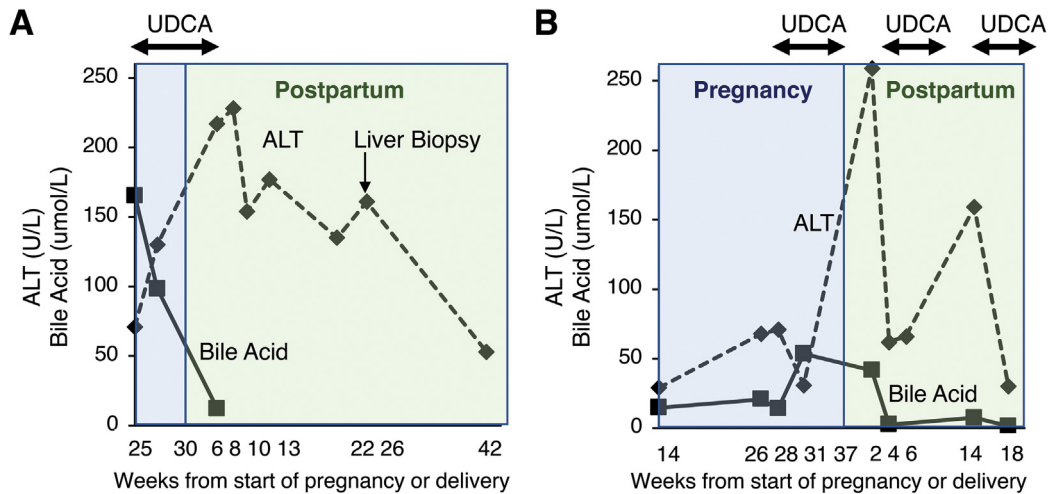


Figure 1. Clinical course of primary and recurrent ICP during 2 subsequent pregnancies in the same patient. Serum bile acid levels and alanine aminotransferase activity in the patient with recurrent ICP during her (A) first pregnancy and (B) second pregnancy. Increased ALT activity persists despite normalization of bile acid levels. UDCA, ursodeoxycholic acid.

Serial plasma samples were prospectively collected from this patient and from 3 other pregnant Asian women without ICP. Cytokines were measured using the V-PLEX Human Cytokine 36-Plex Kit (Mesoscale Discovery, Rockville, MD). Plasma CXCL10, IL-12p40, and IL-10 levels were higher in the patient with ICP than in the 3 controls without ICP during the third trimester and postpartum (Figure 2). Of note, the chemokine CXCL10 increased in parallel to the bile acid rise and prior to the ALT increase in the third trimester. In contrast, IFN- γ and IL-10 levels peaked after the peak ALT. As ALT levels decreased, levels of all cytokines except IL-12 returned to baseline. The plasma concentration of IL-12 remained at high levels for more than 12 months postpartum.

Discussion

ICP is significantly more frequent in South Asia (0.8%–1.46%) and South America (9.2%–15.6%) than in Europe (0.1%–0.2%).³ The pathophysiology of ICP is complex involving genetic susceptibility and environmental risk factors. Genetic predisposition has been linked to mutations in the bile acid transporter genes *ABCB4*, *ABCB11*, and *ABCC2*.⁴ Mutations in the coding sequence of these genes may result in impaired transport of cytotoxic bile acids out of hepatocytes. This effect can possibly be exaggerated during pregnancy due to elevated levels of estrogen and progesterone which further impair the transport of bile acids.^{2,5} ICP with serum bile acid elevation to >40 $\mu\text{mol/L}$ confers a 1.5- and 3-times increased risk of preterm and stillbirth, respectively.⁶ These complications could be related to accumulation of bile acids in fetal organs. Timely management with close monitoring and induced delivery between 37 and 39

weeks are crucial to prevent adverse fetal outcomes.⁷ There were controversial reports on the beneficial effects of UDCA in fetal outcomes.^{8–10} The decision to initiate UDCA in this case, especially its prolonged use during the second pregnancy, was an attempt to improve serum aminotransferases in addition to the potential benefits to the fetus.

In the typical ICP setting, serum bile acids and aminotransferases usually normalize within 1–3 months after delivery, and UDCA therapy can be discontinued.⁷ Significant and prolonged postpartum ALT elevation despite normalization of bile acid levels, as in the case described here, is highly unusual. The pathogenesis of ICP is not fully understood. Previously, the cholestatic liver injury was believed to be related to the direct cytotoxic effects or the apoptosis of hepatocytes that produce bile acids.¹¹ Recent studies of ICP-related liver injury provided evidence that the elevated bile acid levels in the hepatocytes cause oxidative stress and mitochondrial injury. The DNA released by the injured mitochondria, in turn, activates the toll-like receptor 9 signaling pathway. This may lead to synthesis of proinflammatory cytokines in hepatocytes.^{11–13}

Our observation that the chemokine CXCL10 level increased in parallel with bile acid levels is in agreement with the published report.¹³ We hypothesize that the elevated bile acid levels lead to hepatic recruitment of immune cells which express the CXCR3 receptors for CXCL10. The subsequent immune cell activation with release of IFN- γ may maintain the inflammatory response and contribute to the prolonged ALT elevation even after the bile acid levels returned to normal. In our patient, the ALT levels normalized with a prolonged postpartum course of UDCA treatment. That could be the results of the antiapoptotic and endotoxin disposal effects of

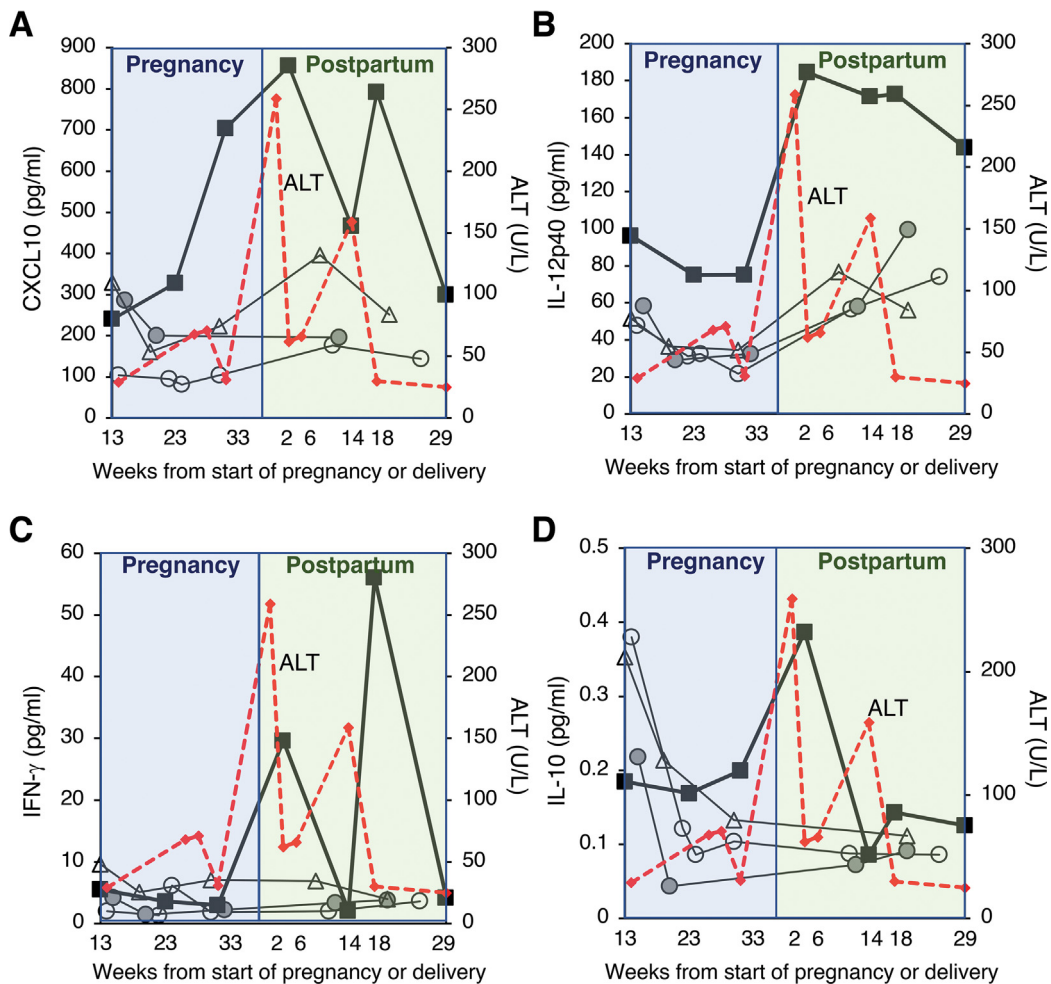


Figure 2. Chemokine and cytokine response associated with recurrent ICP. Serial serum levels of the (A) chemokine CXCL10 and cytokines (B) IL-12p40, (C) IFN- γ , and (D) IL-10 of the patient with recurrent ICP are shown as bold lines during her second pregnancy. The corresponding levels in 3 control patients without ICP are shown as grey lines (open circle, open triangle, and filled circle). The dotted red line indicates the ALT activity of the patient with ICP.

UDCA.¹⁴ Thus, in atypical ICP cases such as ours, an individualized and prolonged UDCA therapy should be considered.

12. Allen K, et al. *Am J Pathol* 2011;178:175–186.
13. Cai SY, et al. *JCI Insight* 2017;2:e90780.
14. Poupon R, et al. *J Hepatol* 2000;32:129–140.

References

1. Piechota J, et al. *J Clin Med* 2020;9:1361.
2. Glantz A, et al. *Hepatology* 2004;40:467–474.
3. Tan LK. *Ann Acad Med Singap* 2003;32:294–298.
4. Turro E, et al. *Nature* 2020;583:96–102.
5. Reyes H. *Hepatology* 2008;47:376–379.
6. Ovadia C, et al. *Lancet* 2019;393:899–909.
7. Lee RH, et al. *Am J Obstet Gynecol* 2021;224:B2–B9.
8. Bacq Y, et al. *Gastroenterology* 2012;143:1492–1501.
9. Chappell LC, et al. *Lancet* 2019;394:849–860.
10. Ovadia C, et al. *Lancet Gastroenterol Hepatol* 2021;6:547–558.
11. Cai SY, et al. *Ann Transl Med* 2021;9:737–748.

Received July 30, 2022. Accepted August 31, 2022.

Correspondence:

Address correspondence to: Daryl T.-Y. Lau, MD, MSc, MPH, Translational Liver Research, Beth Israel Deaconess Medical Center, Harvard Medical School, Boston, Massachusetts; Harvard Medical School, Liver Center, 110 Francis Street, Suite 4A, Boston, Massachusetts 02118. e-mail: dtau@bidmc.harvard.edu.

Conflicts of Interest:

The authors disclose no conflicts.

Funding:

This work was supported by the NIH Bench-to-Bedside award (to B.R. and D.T.-Y.L.) and the intramural research program of NIDDK, NIH.

Ethical Statement:

The corresponding author, on behalf of all authors, jointly and severally, certifies that their institution has approved the protocol for any investigation involving humans or animals and that all experimentation was conducted in conformity with ethical and humane principles of research.