

Treatment of Complete Persistent Sciatic Artery with Distal Thromboembolism by Thromboembolectomy Only

Yun Kyung Choi, M.D., Jae Ho Ahn, M.D., Kwan Chang Kim, M.D., Tae Hee Won, M.D.

A persistent sciatic artery (PSA) is very rare congenital vascular anomaly which is present in 0.025% to 0.04% of the population by an angiographic study. A PSA is usually combined with aneurysmal disease or thromboembolic events because of its arteriosclerosis and vessel wall degeneration. The treatments of symptomatic PSA are comprised of exclusion of PSA from circulation and bypass surgery for the lower limb. However, surgical treatment should be tailored to its anatomy and presentation. We report a successful treatment of PSA with distal thromboembolism by thromboembolectomy without bypass surgery.

Key words: 1. Persistent sciatic artery
2. Thromboembolism
3. Thromboembolectomy

CASE REPORT

A 61-year-old man, with no previous history of trauma, was referred to Ewha Womans University Mokdong Hospital for further evaluation of left claudication which was appeared a month prior to admission. On physical examination, absence of pulsation at left dorsalis pedis was noted with relatively intact pulsation at left popliteal artery and left femoral artery. His past medical history was unremarkable. A computed tomography (CT) angiogram (Fig. 1), performed to evaluate the whole vascular bed of lower extremity, revealed the presence of complete persistent sciatic artery (PSA) with incompletely developed superficial femoral artery (SFA) (type 2A persistent sciatic artery), and the complete obstruction of distal popliteal artery by thrombus was also noted. Despite of the complete obstruction of the distal portion, patency from internal iliac artery to proximal portion of popliteal artery

through the PSA was relatively preserved. With neither tortuous feature nor aneurysmal change in PSA, we decided to perform thromboembolectomy only. Elective thromboembolectomy for distal popliteal arterial thrombosis was performed. The patient was placed in prone position and a vertical incision was made over the popliteal fossa. Exposure of the popliteal artery was followed by arteriotomy and distal embolectomy using a Fogarty catheter. A considerable amount of fresh red and old organized thrombus was removed. Although mild calcification of arterial wall was found, another bypass surgery was not considered because of the relatively good arterial bed. Patient made uneventful recovery and postoperative follow-up CT angiogram showed no residual thrombus in popliteal artery (Fig. 2). He was discharged 7 days after the operation and took aspirin and warfarin. However, he readmitted for recurrence of left claudication 6 months later. The finding in CT angiogram was similar to the preoperative one

Department of Thoracic and Cardiovascular Surgery, Ewha Womans University School of Medicine

Received: April 6, 2012, Revised: June 11, 2012, Accepted: June 13, 2012

Corresponding author: Tae Hee Won, Department of Thoracic and Cardiovascular Surgery, Ewha Womans University School of Medicine, 1071 Anyangcheon-ro, Yangcheon-gu, Seoul 158-710, Korea
(Tel) 82-2-2650-5151 (Fax) 82-2-2650-2652 (E-mail) wth@ewha.ac.kr

© The Korean Society for Thoracic and Cardiovascular Surgery. 2012. All right reserved.

© This is an open access article distributed under the terms of the Creative Commons Attribution Non-Commercial License (<http://creativecommons.org/licenses/by-nc/3.0>) which permits unrestricted non-commercial use, distribution, and reproduction in any medium, provided the original work is properly cited.

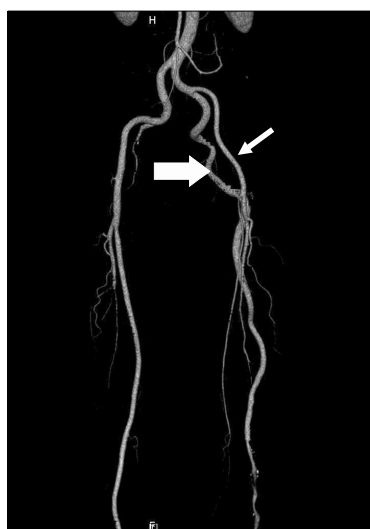


Fig. 1. Preoperative computed tomography angiogram (1st operation). The presence of complete persistent sciatic artery (large arrow) with incompletely developed superficial femoral artery (small arrow) was noted. It also presented the complete obstruction of distal popliteal artery by thrombus and tapering-off of the arterial flow distal to popliteal artery. Persistent sciatic artery originated from internal iliac artery shows relatively preserved patency without any aneurismal change.

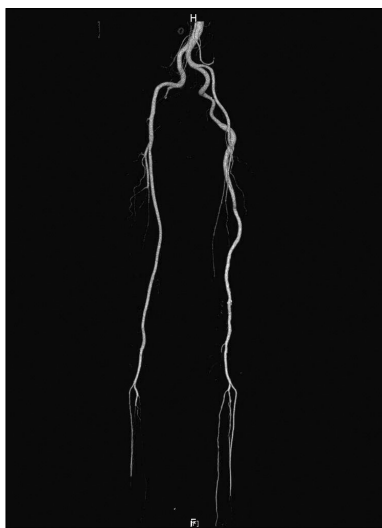


Fig. 2. Immediate, postoperative computed tomography angiogram. Note the patency of the whole persistent sciatic artery and iliofemoral artery system. No residual thrombus was noted.

without any interval aggravation of arteriosclerosis or aneurysmal change (Fig. 3). Thromboembolctomy was performed



Fig. 3. Preoperative computed tomography (CT) angiogram (2nd operation). Similar findings compared to preoperative CT angiogram (1st operation) with no definite aggravation of arteriosclerosis and aneurismal change.

again and the intraoperative findings were unremarkable to previous one. The postoperative recovery was uneventful and discharged without any complications. During the 6-year follow-up period, he was supposed to take aspirin and warfarin for 3 years and aspirin only after that. And there was no recurrence of thromboembolism or complications including aneurysmal formation.

DISCUSSION

The sciatic artery, a branch of umbilical artery, is the main arterial supply of the developing lower limb during 6 mm stage of embryonic development [1,2]. With the development of femoral artery from the external iliac artery, the sciatic artery regresses with time [1-5]. The PSA originated from the failure of sciatic arterial involution process, with low incidence of between 0.025% and 0.04% [1,3-5]. The anomaly of this process determines the types of PSA from the incomplete type to complete type with relative hypoplastic femoral artery [2,6]. Pillet et al. [7,8] has suggested four different types of PSA according to the result of angiogram. For the complete type (type 1 and 2) PSA, which has continuation with popliteal artery, the presence of normal femoral artery

determines the PSA type. Different from type 1 PSA with normal femoral artery, type 2 represents a complete PSA with relatively under-developed femoral artery. Type 2 can be sub-typed again into type 2A (presence of incomplete SFA) and type 2B (absence of SFA), according to the presence of SFA. For incomplete PSA, which has partial remnant of PSA and normal SFA, the anatomical location of SPA determines the type: type 3 PSA with only upper remnant of PSA and type 4 with lower remnant.

The PSA, which is more prone to arteriosclerosis and vessel wall degeneration, can present with combined vascular complication: aneurysmal change with or without thromboembolism [1]. In spite of low incidence rate, 46.1% to 47% of PSA patients present combined aneurysmal change with or without thromboembolism [4,6]. Except for asymptomatic patients (40%), common manifestations can be summarized as pulsatile, painful buttock mass and lower limb ischemia [1,6]. Different from other peripheral obstructive disease, intact popliteal and distal pulsations with relatively weak or absent femoral pulsation can suggest PSA. The tentative diagnosis can be achieved by CT angiogram of lower extremity, which allows demonstration of the various anatomic configurations both in the sciatic and femoral arterial systems.

The choice of treatment is mainly dependent on the presence of symptoms, classification of PSA (anatomy of the sciatic artery and the iliofemoral system), the presence of concurrent vascular complication (vascular occlusive disease or aneurysm) [1,2]. Asymptomatic patients with incidental findings of PSA require close follow-up observation only rather than surgical intervention. Symptomatic patients are surgical candidates, and the type of surgery can be specified according to the presence of complication and classification of PSA. Incomplete PSA with aneurysmal change, with or without vascular occlusive disease, can be obliterated by exclusion, endovascular embolization, or resection [4]. Complete PSA with aneurysmal change requires concurrent revascularization procedure to prevent aggravation of lower extremity ischemia. Non-aneurysmal PSA with symptomatic thromboembolism can be managed with embolectomy, either by endovascular intervention or open surgical approach.

Our patient showed type 2A PSA (complete PSA with incompletely developed SFA system) with distal popliteal thromboembolism. Although there would be persistent and repetitive risk of thromboembolism and aneurysmal change, we decided to perform thromboembolectomy only. It's because of relatively good PSA without arteriosclerosis and aneurysm. By eliminating complicated operative procedures for exclusion of PSA and bypass, lots of complications including damage to sciatic nerve can be avoided.

In conclusion, Treatment of symptomatic PSA should be tailored to its anatomy and presentations and thromboembolectomy without bypass surgery should be considered as one of strategies in the treatment of symptomatic PSA.

REFERENCES

1. Yamamoto H, Yamamoto F, Ishibashi K, et al. *Intermediate and long-term outcomes after treating symptomatic persistent sciatic artery using different techniques.* Ann Vasc Surg 2011;25:837.e9-15.
2. van Hooft IM, Zeebregts CJ, van Sterkenburg SM, de Vries WR, Reijnen MM. *The persistent sciatic artery.* Eur J Vasc Endovasc Surg 2009;37:585-91.
3. Gabelmann A, Kramer SC, Wisianowski C, Tomczak R, Pamler R, Gorich J. *Endovascular interventions on persistent sciatic arteries.* J Endovasc Ther 2001;8:622-8.
4. Mousa A, Rapp Parker A, Emmett MK, AbuRahma A. *Endovascular treatment of symptomatic persistent sciatic artery aneurysm: a case report and review of literature.* Vasc Endovascular Surg 2010;44:312-4.
5. Jung AY, Lee W, Chung JW, et al. *Role of computed tomographic angiography in the detection and comprehensive evaluation of persistent sciatic artery.* J Vasc Surg 2005;42: 678-83.
6. Bito Y, Sakaki M, Iida O, Inoue K, Yoshioka Y, Mizoguchi H. *Clinical management of lower limb ischemia secondary to a persistent sciatic artery aneurysm: report of a case.* Surg Today 2011;41:402-5.
7. Pillet J, Albaret P, Toulemonde JL, Cronier P, Raimbeau G, Chevalier JM. *Ischio-popliteal artery trunk, persistence of the axial artery.* Bull Assoc Anat (Nancy) 1980;64:97-110.
8. Pillet J, Cronier P, Mercier PH, Chevalier JM. *The ischio popliteal arterial trunk: a report of two cases.* Anat Clin 1982;3:329-31.