



## Effects of two different topographic approaches for combined sciatic and femoral nerve block in calves, guided by ultrasound and neurostimulation

Marcos Paulo Antunes de Lima<sup>a,b,\*</sup>, Renata Andrade Silva<sup>b</sup>, Patrícia de Castro Duarte<sup>b</sup>, Sérgio da Silva Rocha Júnior<sup>b</sup>, Stephanie Elise Muniz Tavares Branco<sup>b</sup>, Cahuê Francisco Rosa Paz<sup>b</sup>, Pablo Ezequiel Otero<sup>c</sup>, Rafael Resende Faleiros<sup>b</sup>, Suzane Lilian Beier<sup>b</sup>

<sup>a</sup> Veterinary Medicine Course, Biological and Health Sciences Institute, Pontifícia Universidade Católica de Minas Gerais, Minas Gerais, Brazil

<sup>b</sup> Department of Veterinary Clinic and Surgery, Federal University of Minas Gerais, Belo Horizonte, Minas Gerais, Brazil

<sup>c</sup> Department of Anesthesiology and Pain Management, Facultad de Ciencias Veterinarias, Universidad de Buenos Aires, Buenos Aires, Argentina

### ARTICLE INFO

#### Keywords:

Locoregional anaesthesia  
Perineural  
Regional anaesthesia  
Ropivacaine

### ABSTRACT

To evaluate the sensory and motor effects promoted by a combined sciatic and femoral nerve block in calves using two approaches. Six calves were used, in a crossover study. Ultrasound combined with neurostimulation, was used to perform the following block combinations: the proximal approach (PA), which consisted of the association of the parasacral approach (sciatic nerve block) and ventral to the ilium approach (femoral nerve block); distal approach (DA) consisted of the association of a lateral approach to the pelvic limb approach (sciatic nerve block), and an inguinal approach, underneath the femoral trigone (femoral nerve block). Pressure algometry and motor function of the limb were evaluated. Mechanical nociceptive threshold (MNT) increase, and ataxia duration means were  $9.5 \pm 0.7$  kg and  $10.4 \pm 3.9$  hr for PA and  $10.4 \pm 3.9$  kg and  $12.7 \pm 1.9$  hr for DA, respectively with no significant difference. There was no significant difference between MNT elevation time and the duration of ataxia using the same approach. The DA treatment showed significant MNT elevation in 72% of the tested regions, while the PA treatment showed an elevation in 100% regions tested. Topographic approaches closer to where the spinal nerves emerge produced a larger desensitized area.

### 1. Introduction

The growing advances in locoregional anaesthesia in the last few years in veterinary medicine are evident since there are numerous recent publications on this topic (Campoy, 2019; Portela et al., 2018). Perineural blocks in the pelvic limb, guided by ultrasound and/or neurostimulation, show similar analgesic qualities to those promoted by neuraxial techniques (Horasanli et al., 2010), shorter hospitalisation times, fewer complications such as haemodynamic changes, and absence of intestinal or bladder atony (Hajibandeh et al., 2018; Roberts, 2006; Zhang et al., 2015). Its advantages are also evidenced by the selectivity promoted by these techniques, which allow an individualized block of the limb and its segment that is going to be operated on (Campoy, 2019).

The extensive use of these new peripheral nerve block techniques, guided by ultrasound imaging and neurostimulation, has been well outlined, with promising results for dogs and cats (Campoy et al., 2012;

Caniglia et al., 2012; Haro et al., 2012; Mosing et al., 2010; Vettorato et al., 2012). However, only a few studies regarding refinements of guided peripheral nerve blocks were developed in calves (Devlamynck et al., 2013; Re et al., 2016), and remains with restricted techniques to be applied in clinical surgical scenarios, demanding higher sedative, analgesic, and general anaesthetic consumption, with its inherent adverse effects (Valverde & Sinclair, 2015).

This study aimed to evaluate the sensory effects on the mechanical nociceptive threshold (MNT), and the motor effects promoted by two distinct approaches of a combined block of the sciatic and femoral nerves, guided by ultrasound and neurostimulation.

### 2. Material and methods

This study was approved by the Ethical Use of Animals Committee of Federal University of Minas Gerais protocol no. 116/2017.

\* Corresponding author.

E-mail address: [limampa@hotmail.com](mailto:limampa@hotmail.com) (M.P.A. Lima).

Six healthy mixed-breed calves (five males and one female) aged 5–8 months, weighing  $120 \pm 28$  kg, were enrolled in this study. They had no scars or lesions in the pelvic limbs, and none of them had a history of lameness. They were kept in grazing areas or stables for 15 days for acclimation and received corn silage, hay, and water ad libitum.

A crossover experimental design was used, in which each animal was subjected to both proposed treatments. To avoid eventual residual effects between treatments, a 7-day interval was established. Treatments consisted of a proximal (PA) or distal (DA) approach. The PA consisted of a sciatic and femoral nerve block performed by a parasacral (Waag et al., 2014) and a ventral to the ilium (Devlamynck et al., 2013) approach, respectively. The DA consisted of a sciatic and femoral nerve block performed lateral to the pelvic limb (Re et al., 2014) and an inguinal approach (Viscasillas et al., 2015), respectively:

- Parasacral approach (sciatic nerve): through the dorsal aspect of the gluteal area, tracing a line between the dorso-cranial portion of the iliac crest and ischiatic tuberosity, the ultrasound probe is positioned in its medium portion and, through the superficial and middle gluteal muscles, the sciatic nerve is identified medially to the body of the ilium and close to the cranial gluteal artery and vein.
- Ventral to the ilium approach (femoral nerve): ventrally to the body of the ilium, the ultrasound probe is placed through the lateral aspect of the pelvic limb, approximately 3 to 4 cm caudal to the iliac wing, and in between the psoas major and minor muscles, near the external iliac artery and vein, the femoral nerve is located.

Before each treatment, food and water were withheld for 24 h and 12 h, respectively. Xylazine (0.07 mg/kg, Xylasin, Syntec, Brazil 2%) was administered intravenously (IV). After sedation was achieved, the calf was positioned in right lateral recumbency on a padded surface with the limb to be blocked uppermost. Hair was clipped from the region for locoregional anaesthesia, followed by antiseptics with chlorhexidine gluconate and alcoholic chlorhexidine. A perineural block was administered under ultrasound guidance. In all cases, the manoeuvre was assisted by a nerve stimulator and ultrasonography was performed with a linear 7.5–10 MHz probe (Gen 3 Ultrasound Wi-fi, Beijing Konted Medical Technology), always on the animals' left pelvic limb. After visualising the target nerve, a 21-gauge, 100 mm neurostimulation needle (Locoplex, Vygon, Ecouen, France), with the extension line filled with the local anaesthetic and connected to the nerve stimulator (Plexygon, Vygon, Ecouen, France), was used for needle advancement and local anaesthetic injection. The neurostimulator setting was standardised at 1 Hz and 0.1 ms, and needle positioning was confirmed by direct visualisation of the needle-to-nerve proximity with the ultrasound, as well as obtaining an adequate motor response at 0.5 mA. For the femoral nerve, contraction of the quadriceps femoris muscle and consequent extension of the stifle joint was searched, while for the sciatic nerve, responses such as a dorsal extension or plantar flexion of the tarsus and/or digits were sought out. The blocks were always performed by the same researcher, using an "in-plane" technique. In both treatments, 0.75% ropivacaine (Ropi, Cristália, Brazil) was administered at a volume of 0.1 ml/kg per nerve, administered over 1 min. After the blocks were performed, 0.01 mg/kg IV of atipamezole was administered (Antisedan, Zoetis).

During the execution of the perineural block techniques, ultrasound image quality was assessed and categorised into scores as proposed by Devlamynck et al. (2013): score 1: *excellent* (clear visualisation of the anatomical references, innervation, and needle position); score 2: *acceptable* (visualisation of anatomical references, innervation, and/or position of the needle); score 3: *poor* (difficult visualisation of the anatomical references, innervation, or position of the needle).

Each block performance time, starting from the nerve localisation, until the local anaesthetic injection was registered.

The effects of the perineural block on sensitivity within various regions of the hind limb were evaluated using a portable dynamometer

(Instrutemp 20 kgf ITFG-5020, \*\*), as described in previous studies in horses (Paz et al., 2016) and dogs (Harris et al., 2015). The device had a 12 cm long stem with a 1 mm diameter conic tip, with readings made in kilogrammes (kg). The stem was applied at a 90° angle to various regions of the hindlimb with continuously increasing force, with a maximum applied value of 3 kg to avoid tissue injury in the animals. The stimulus was discontinued when the animal generated adverse movements due to the stimulus, removing the limb, or looking at the stimulated area. The points tested were based on the bovine pelvic limb dermatomes: gluteal region; cranial, caudal, and medial thigh regions; cranial, lateral, and medial knee region; medial and lateral tibial region; dorsal and plantar metatarsal region.

The ataxia score was characterised according to the scale proposed by Bigham et al. (2010): 0 – no ataxia or proprioceptive deficits; 1 – mild ataxia, mild proprioceptive deficit, the animal can move; 2 – moderate ataxia, marked proprioceptive deficit, marked difficulty to move; however, can remain in standing position and walk; 3 – severe ataxia, falling, cannot remain in standing position or move.

The evaluations were always performed by the same researcher, at baseline (before sedation), 30 min after reversal with atipamezole, and every 1 h after reversal with atipamezole, until full recovery of motor function and sensibility.

### 3. Statistics

The Shapiro-Wilk test was used to assess the occurrence of normal distribution of the collected data. The data that had a normal distribution were then subjected to analysis of variance with multiple repetitions followed by Tukey's test to evaluate differences between times in the same treatment. To compare the means of the different treatments, a paired *t*-test was used. Data with non-normal distribution were subjected to Friedman analysis followed by Dunn test to evaluate differences between times in the same treatment, and Wilcoxon test to evaluate differences between treatments. Statistical significance was set at  $p < 0.05$ .

### 4. Results

No differences in the ultrasonographic scores of the femoral and sciatic nerves were observed when comparing the different approaches ( $p > 0.05$ ). Better ultrasonographic scores were observed for the sciatic nerve in comparison to the femoral nerve in the DA ( $p = 0.009$ ) as well as in the PA ( $p = 0.0065$ ) (Table 1).

The time for the combined sciatic and femoral nerve block was higher when the PA was used in comparison to the mean DA time ( $p = 0.042$ ) (Table 1).

DA treatment promoted a significant increase in the MNT in 8/11 of the tested regions (72.7%), while PA promoted a significant increase in 11/11 of the tested regions (100%). The mean elevation values of the

**Table 1**

Median (range) values of ultrasonographic scores (US score) of sciatic and femoral nerves; mean (standard deviation) values of time to perform sciatic and femoral nerve blocks under different topographic approaches, proximal (PA) or distal approaches (DA), with ropivacaine 0.75%.

Variables	Treatments			
	Distal Approach		Proximal Approach	
	Femoral	Sciatic	Femoral	Sciatic
<b>US Score</b>	2 (2–3) <sup>†</sup>	1 (1–2) <sup>†</sup>	2 (2–2) <sup>†</sup>	1 (1–2) <sup>†</sup>
<b>Time (min)</b>	8.2 ± 4.1 <sup>†</sup>	3.5 ± 1.22 <sup>*†</sup>	12 ± 8.1	7.5 ± 3.27*
<b>Total time (min)</b>	11.67 ± 4.76*		20.33 ± 7.42*	

\* significantly different compared between approaches, for the same nerve ( $p < 0.05$ ).

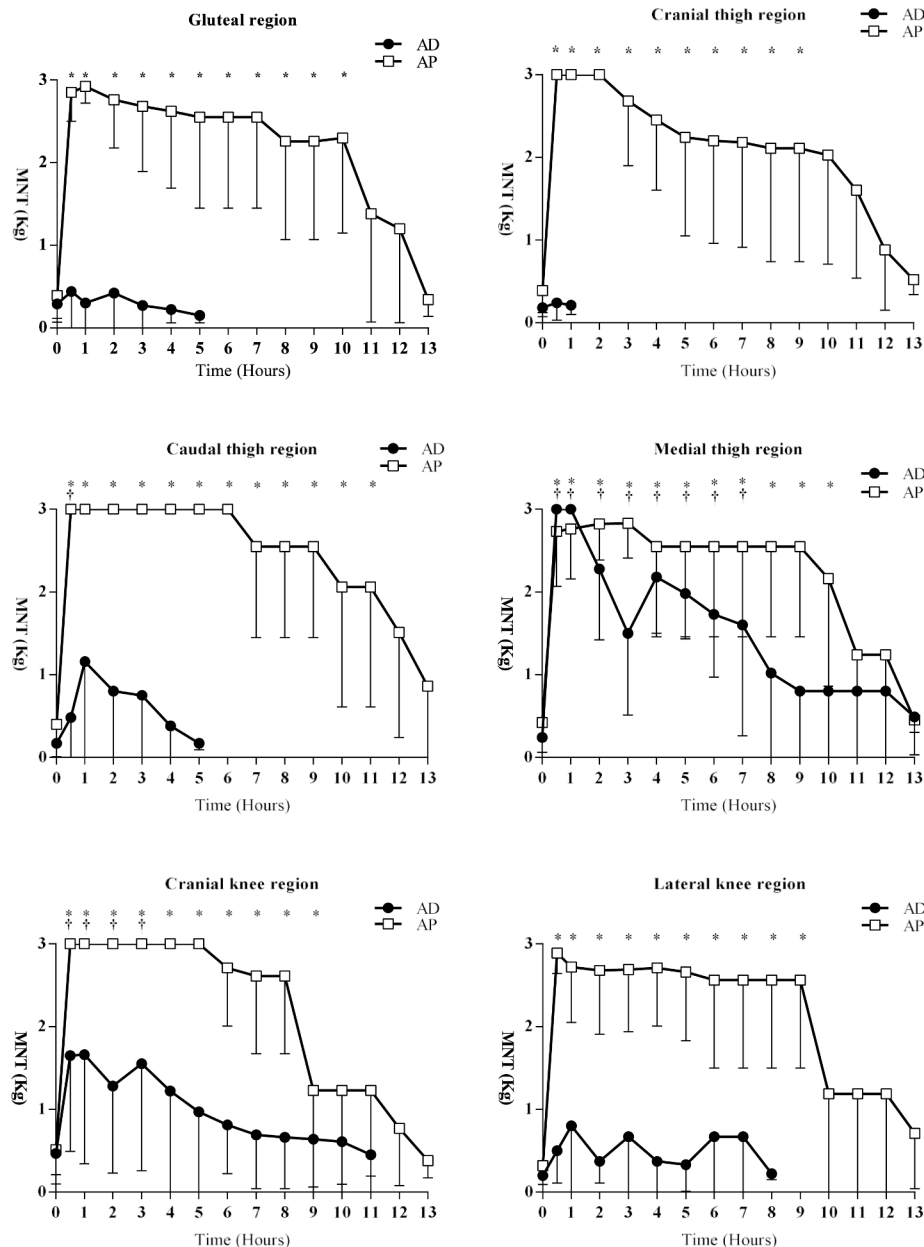
† significantly different compared between nerves, for the same approach ( $p < 0.05$ ).

MNT for each tested region and the approach used are shown in Figs. 1 and 2.

The MNT mean elevation time in all tested regions where  $9.5 \pm 0.7$  kg and  $10.4 \pm 3.9$  h for PA and DA, respectively, with no difference ( $p = 0.472$ ). Ataxia durations mean times were  $10.5 \pm 3$  h and  $12.7 \pm 1.9$  h for PA and DA, respectively, with no difference ( $p = 0.177$ ). While comparing the MNT elevation time and the ataxia duration time in each treatment, no differences were observed ( $p > 0.05$ ). Ataxia scores observed throughout the experiment and between treatments, were different, with higher values in the PA treatment than that of the DA treatment. All animals in the PA had severe ataxia scores, while those in the DA had an evident sign of proprioceptive deficit and plantar flexion of the metatarsophalangeal joint.

### 5. Discussion

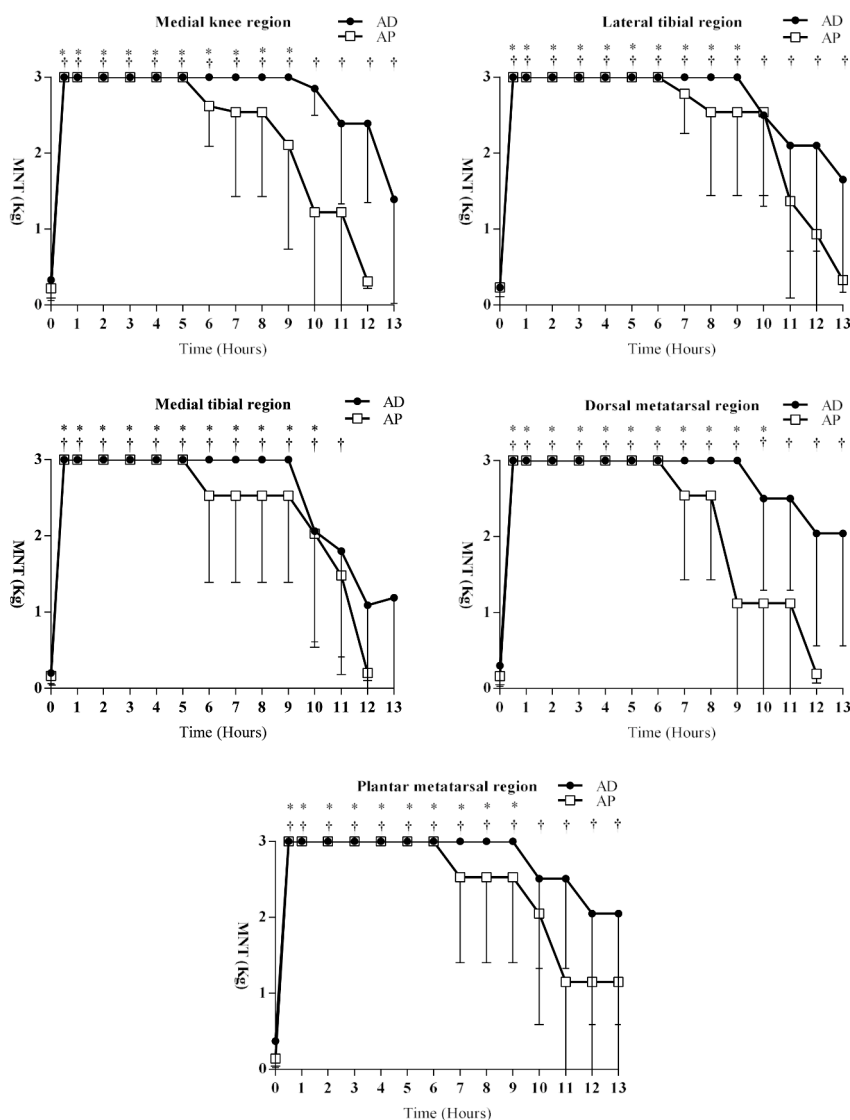
Visualization of the sciatic and femoral nerves was possible in all approaches during the execution of perineural nerve block (PNB) techniques. However, while evaluating the ultrasound scores for the execution of the PNB techniques, considering not only the target nerve visualization; however, also the simultaneous visualization of the needle position and its proximity to the nerves, both approaches for femoral nerve block were worse when compared to the sciatic nerve block approaches. This difficulty corroborates the findings of *Re et al. (2014)* and *Devlamynck et al. (2013)*, wherein their studies with calf cadavers, performing ventral access to the ilium for femoral nerve block (the same approach used in the present study), reported the difficulty in



**Fig. 1.** Mean and standard deviation of MNT, in kg, under different anatomical regions of pelvic limb of calves: gluteal region; cranial, caudal, and medial thigh regions; cranial and lateral knee region. Calves submitted to a combined sciatic and femoral nerve blocks under Proximal (PA) or Distal (DA) approaches, with ropivacaine 0.75%.

\*significantly different to baseline (0 hour), for PA ( $p < 0.05$ ).

†significantly different to baseline (0 hour), for DA ( $p < 0.05$ ).



**Fig. 2.** Mean and standard deviation of MNT, in kg, under different anatomical regions of pelvic limb of calves: medial knee region; medial and lateral tibial region; dorsal and plantar metatarsal region. Calves submitted to a combined sciatic and femoral nerve blocks under Proximal (PA) or Distal (DA) approaches, with ropivacaine 0.75%.

\*significantly different to baseline (0 hour), for PA ( $p < 0.05$ ).

†significantly different to baseline (0 hour), for DA ( $p < 0.05$ ).

visualizing these nerves and staining using methylene blue, with a success rate of 6/10 and 8/20 attempts, respectively.

The parascral approach for sciatic nerve block has already been described in dogs (Shilo et al., 2010) and sheep (Waag et al., 2014); however, it has not been performed and described in cattle. Its execution, target nerve, and anatomical reference visualization were possible in all animals in this study, corroborating the findings of Waag et al. (2014), who described that in a cadaveric ovine study, sciatic nerve visualization was medial to the body of the ilium and lateral to the cranial gluteal vein and artery, deep to the superficial and middle gluteal muscles. In this study, the authors achieved a success rate of 24/26 visualisations and staining of the sciatic nerve in sheep.

The femoral nerve can be blocked in its more distal portion using an inguinal approach under the femoral triangle (Portela et al., 2018); however, in dogs, several studies reported difficulty in visualising the nerve during its execution (Echeverry et al., 2010; Shilo et al., 2010). The visualisation was possible and practical in the present study, probably due to the size of the animals used, corroborating with the

findings by Viscasillas et al. (2015), who reported a calf that underwent distal correction of a metatarsus fracture and received, as a component in the balanced analgesia, femoral nerve block by inguinal approach, under the femoral triangle, the same approach used in this study.

Through the lateral approach in the pelvic limb, for sciatic nerve block, technique execution and target innervation were obtained, corroborating previous findings in cattle (Re et al., 2014; Viscasillas et al., 2015). Re et al. (2014) reported sciatic nerve visualization with this approach in all animals tested and determined a success rate of 9/10 for methylene blue staining when ultrasound was used for its localization.

The volumes used for perineural block vary, in the canine species, according to the approach, from 0.05 to 0.4 ml/kg in each block point (Campoy, 2019; Portela et al., 2018), as well as in cattle, with variations from 0.05 to 0.2 ml/kg in each administration point (Devlamynck et al., 2013, 2013; Re et al., 2016). It is important to establish an adequate volume for each specific block, as perineural block efficiency correlates with its extension that is soaked by the local anaesthetic, which should

be more than 25 mm (Raymond et al., 1989). A volume of 0.2 ml/kg per nerve was indicated for sciatic and femoral nerve block in cattle that in a cadaveric study had methylene blue staining of  $6.8 \pm 3.3$  cm for the sciatic nerve and  $7.8 \pm 2.4$  cm for the femoral nerve (Re et al., 2014). In a surgical condition, the combined sciatic and femoral nerve block, with distal approaches, applied a volume of 0.05 ml/kg per point to obtain a block that was considered sufficient for metatarsus fracture reduction and stabilization in a calf, with no need for analgesic rescue during the procedure (Viscasillas et al., 2015). Therefore, the volume of 0.1 ml/kg per block point applied in this study's methodology is as per the limits described in the literature.

According to the topographic level in which a nerve is blocked, its anaesthetic effects over different desensitised areas will occur according to the approximation or increased distance to its intervertebral origin Portela et al. (2018), since each of its posterior neural ramifications innervates specific areas (Dellmann et al., 1986; Nickel et al., 1981). The greater coverage of desensitised areas with PA than with DA agrees with this statement. Using the PA, at the parassacral level, there is access to the lumbosacral plexus, where the following nerves are unsensitised: dorsal branches of the L6-S3 nerves, responsible for the cutaneous innervation of the gluteal area; caudal cutaneous femoral nerve, responsible for the cutaneous innervation of the lateral-caudal aspect of the thigh; lateral sural cutaneous nerve, responsible for innervating the lateral aspect of the leg; and the sciatic nerve, which gives rise to the fibular nerve, responsible for emitting cutaneous branches to the dorsal aspect of the metatarsus, and finally the tibial nerve, responsible for emitting cutaneous branches to the metatarsus plantar aspect (Dellmann et al., 1986; Nickel et al., 1981). In both human (Helayel et al., 2009) and canine (Shilo et al., 2010) studies, the effectiveness in tested areas in conscious patients submitted to the parasacral approach was based on the painful response of the tibial and fibular dermatomes, distal to the limb, without reporting broader methodologies such as the one used in the present study; therefore, a better comparison of the in vivo results could be established. However, while evaluating the distal approach for sciatic nerve block, through the lateral aspect of the pelvic limb, similar results based on the unsensitised areas were described in cattle while using 2% lidocaine (Re et al., 2014), corroborating with the present study's findings.

Re et al. (2014), while using 2% lidocaine for femoral nerve block by an approach ventral to the ilium, observed unsensitised cutaneous areas cranial and laterally to the thigh, and cranial and lateral to the stifle joint, corroborating the results of the present study, which showed a significant increase in the MNT at these same sites. The interesting part of these results is that, the cranial and lateral aspect of the thigh receives sensitive cutaneous innervation from the lateral cutaneous nerve of the thigh, which also contributes to the medial portion of this segment, and that the lateral and cranial portion of the stifle joint also receives a mixed innervation of the ilioinguinal and iliohypogastric nerves, in variable contribution; however, with greater importance of the lateral cutaneous nerve of the thigh (Dellmann et al., 1986; Nickel et al., 1981). The medial region of the thigh, in the cattle, unlike the canine and human, does not receive cutaneous innervation from the genitofemoral nerve (Larson et al., 1956), which then seems to have a greater dependency in this region to the lateral cutaneous nerve of the thigh, and possibly contributes to the femoral nerve. Considering that there are species-specific variations (Dellmann et al., 1986; Larson et al., 1956; Nickel et al., 1981), caution should be used when comparing inter-species results. A possible explanation for the observation of these unsensitised areas that do not correspond to the dermatomes that are supplied exclusively by the femoral nerve, with the proximal approach, can be that the local anaesthetic applied to owe to the use of an approach ventral to the ilium, spread between the psoas compartment and then unsensitised other neural components of the lumbar branches. By comparatively analysing the femoral nerve block technique using the approach ventral to the ilium approach (Re et al., 2014), performed in this experiment, with the lateral pre-iliac approach performed in dogs

(Portela et al., 2013), and the "3-in-1" approach in humans (Geier, 2004; Winnie et al., 1973), we can conclude that the needle's perineural positioning would be similar and that all these techniques can give access to the psoas compartment and/or to the iliac fascia, amplifying the obtained block. Portela et al. (2018) in a cadaveric study with dogs, administering 0.1 ml/kg of the lidocaine-methylene blue solution, realised that in all approaches there was staining of the femoral innervation, and the cranial dispersion of the solution in the psoas compartment reached the topographic level of up to L5, with the obturator nerve dyed in three out of four approaches performed. In humans, the "3-in-1" block, also known as the iliac fascia block, is a technique that shows potential for femoral, obturator, and lateral cutaneous nerve of the thigh block (Geier, 2004; Winnie et al., 1973), and the efficiency to block all three nerves is dependant on the volume applied (Geier, 2004).

Dellmann and McLure (1986) and Nickel et al. (1981) described that the cutaneous region medial to the stifle joint and tibia receives a contribution from the saphenous nerve, originating from the femoral nerve, corroborating the findings of this study, where the MNT was significantly elevated in these regions, in both approaches, showing the efficiency of the treatments in desensitising their respective dermatomes. Studies in dogs evaluating whether these dermatomes are common to both species (König et al., 2011) have also shown to be related to the efficiency of the femoral/saphenous nerve block (Trein et al., 2017).

Ropivacaine's lower selectivity to motor block is the main characteristic during its choice (Casati & Putzu, 2005), which would bring great advantages when incorporated into PNB techniques in large animals as it could promote quicker motor function return and fewer complications while lifting the animal after limb orthopaedic procedures (Nuss, 2016). In the present study, the duration of the sensory block evaluated using the elevation time of the MNT in comparison to the motor block time was similar, and this highly preferred feature was not observed. This was probably due to the high local anaesthetic concentration used since the evidence of greater differentiation of sensory and motor block time is concentration-dependant (Casati & Putzu, 2005). Similar sensitive block times with the use of ropivacaine were described, and in sheep that received ropivacaine for distal thoracolumbar block, it was 590 min Oliveira et al. (2016)].

The greater propensity to fall in the PA treatment was probably due to the ascendant block through the psoas compartment or the iliac fascia (Geier, 2004; Portela et al., 2013; Winnie et al., 1973), as discussed previously, blocking not only the femoral nerve but also the obturator nerve. In a study using the ventral to the ilium approach for femoral nerve block in cattle, 40% of the animals presented with intense ataxia, promoting recumbency, and inability to stay in a quadrupedal position (Re et al., 2014). This higher propensity to intense ataxia and motor inability in the PA treatment was probably due to relaxation and block of the quadriceps femoris, pectineus, gracilis, thigh adductor, and obturator muscles, which were together responsible for the muscular sustaining function in the pelvic limb. In the DA, the plantar flexion of the metatarsophalangeal joint with some degree of abduction of the pelvic limb became more evident due to the restricted influence of the femoral nerve on the motor function of the pelvic limb, showing the motor effects of the sciatic nerve.

Pressure algometry used to assess the MNT after perineural block in equines was previously tested (Paz et al., 2016); however, its use for that purpose has not been reported in cattle, and maybe it was a limitation of this study when compared with other data in the literature.

Due to literature divergence regarding the dermatomes in the bovine pelvic limb, and with the results obtained in this study referring to the unsensitised areas, additional anatomical studies are important to determine the influence of the PA for the femoral nerve block to promote combined block of the lateral cutaneous nerve of the thigh and the obturator nerve.



## 6. Conclusion

In conclusion, the combined use of ultrasound imaging and neurostimulation permitted both approaches to perform efficiently, with the PA producing a greater unsensitized area than the DA. The use of 0.75% ropivacaine resulted in prolonged elevation time of the MNT and ataxia duration, with no difference between motor and sensory blocks.

## Declaration of Competing Interest

None.

## References

- Bigham, A. S., Habibian, S., Ghasemian, F., & Layeghi, S. (2010). Caudal epidural injection of lidocaine, tramadol, and lidocaine-tramadol for epidural anesthesia in cattle. *Journal of Veterinary Pharmacology and Therapeutics*, 33, 439–443.
- Campoy, L. (2019). Locoregional anesthesia for hind limbs. *Veterinary Clinics of North America - Small Animal Practice*, 49, 1085–1094.
- Campoy, L., Martin-Flores, M., Ludders, J. W., Hollis, Erb, H. N., & Gleed, R. D. (2012). Comparison of bupivacaine femoral and sciatic nerve block versus bupivacaine and morphine epidural for stifle surgery in dogs. *Veterinary Anaesthesia and Analgesia*, 39, 91–98.
- Caniglia, A. M., Driessen, B., Puerto, D. A., Bretz, B., Boston, R. C., & Larenza, M. P. (2012). Intraoperative antinociception and postoperative analgesia following epidural anesthesia versus femoral and sciatic nerve blockade in dogs undergoing stifle joint surgery. *Journal of the American Veterinary Medical Association*, 241, 1605–1612.
- Casati, A., & Putzu, M. (2005). Bupivacaine, levobupivacaine and ropivacaine: Are they clinically different? *Best Practice and Research in Clinical Anaesthesiology*, 19, 247–268.
- Dellmann, H. D., & Macclure, R. C. (1986). Sistema nervoso do ruminante (Nervous system of the ruminants). In S. Sisson, & J. D. Grossman (Eds.), *Anatomia dos animais domésticos (Anatomy of the domestic animals)* (5th edn, pp. 998–1077). BR: Guanabara Koogan.
- Devlamynck, C., Vlamynck, L., & Hauspie, S. (2013). Ultrasound-guided femoral nerve block as a diagnostic aid in demonstrating quadriceps involvement in bovine spastic paresis. *Veterinary Journal (London, England : 1997)*, 196, 451–455.
- Echeverry, D. F., Gil, F., Laredo, F., Ayala, M. D., Belda, E., Soler, M., & Agut, A. (2010). Ultrasound-guided block of the sciatic and femoral nerves in dogs: A descriptive study. *Veterinary Journal (London, England : 1997)*, 186, 210–215.
- Geier, K. O. (2004). Bloqueio “3 em 1” por via anterior: Bloqueio parcial, completo ou superdimensionado? Correlação entre anatomia, clínica e radio imagens (Anterior “3-in-1” blockade: Partial, total or overdimensioned block? Correlation between anatomy, clinic and radio images). *Revista Brasileira de Anestesiologia*, 54, 560–572.
- Hajibandeh, S., Hajibandeh, S., & Adasonla, K. (2018). Loco-regional versus general anaesthesia for elective endovascular aneurysm repair – results of a cohort study and meta-analysis. *VASA. Zeitschrift für Gefasskrankheiten*, 47, 209–217.
- Haro, P., Laredo, F., Gil, F., Belda, E., Ayala, M. D., Soler, M., & Agut, A. (2012). Ultrasound-guided block of the feline sciatic nerve. *Journal of Feline Medicine and Surgery*, 14, 545–552.
- Harris, L. K., Murrell, J. C., VanKlink, E. G. M., & Whay, H. R. (2015). Influence of experimental protocol on response rate and repeatability of mechanical threshold testing in dogs. *Veterinary Journal (London, England : 1997)*, 204, 82–87.
- Helayel, P. E., Conceição, D. B., Knaesel, J. A., Cecon, M. S., DalMago, A. J., & OliveiraFilho, G. R. (2009). Volumes anestésicos efeitos no bloqueio do nervo isquiático: Comparação entre as abordagens parassacral e infraglútea-parabicipital com bupivacaína a 0,5% com adrenalina e ropivacaína a 0,5% (Effective anesthetic volumes in sciatic nerve block: Comparison between the parassacral and infraglutal-parabiceps approaches with 0.5% bupivacaine with adrenaline and 0.5% ropivacaine). *Ver Brasileira de Anestesiologia*, 59, 521–530.
- Horasanli, E., Gamli, M., Pala, Y., Erol, M., Sahin, F., & Dikmen, B. (2010). A comparison of epidural anesthesia and lumbar plexus-sciatic nerve block for knee surgery. *Clinics*, 65, 29–34.
- König, H. E., Liebich, H. G., & Cervený, C. (2011). Sistema nervoso (Nervous system). In H. E. König, & H. G. Liebich (Eds.), *Anatomia dos animais domésticos: Texto e atlas colorido (Anatomy of the domestic animals: Text book and coloured atlas)* (4th edn, pp. 509–580). BR: Artmed. pp. 509–580.
- Larson, L. L., & Kitchell, R. L. (1956). Nervenversorgung des Vorderfusses beim rind (Nerve supply of the calf hindlimb). *Deutsche Tierärztliche*, 60, 307–309.
- Mosing, M., Reich, H., & Moens, Y. (2010). Clinical evaluation of the anaesthetic sparing effect of brachial plexus block in cats. *Veterinary Anaesthesia and Analgesia*, 37, 154–161.
- Nickel, R., Schummer, A., & Seiferle, E. (1981). *The anatomy of the domestic animals* (3rd edn, p. 499). UK: Paul Parey.
- Nuss, K. (2016). Surgery of the distal limb. *Veterinary Clinics of North America - Food Animal Practice*, 32, 753–775.
- Oliveira, A. R., Araújo, M. A., Jardim, P. H., Lima, S. C., Leal, P. V., & Frazílio, F. O. (2016). Comparison of lidocaine, levobupivacaine or ropivacaine for distal paravertebral thoracolumbar anesthesia in ewes. *Veterinary Anaesthesia and Analgesia*, 43, 670–674.
- Paz, C. F. R., Magalhães, J. F., Mendes, H. M. F., RochaJunior, S. S., Belknap, J. K., Alves, G. E. S., & Faleiros, R. R. (2016). Mechanical thresholds of dorsal laminae in horses after local anaesthesia of the palmar digital nerves or dorsal branches of the digital nerve. *Veterinary Journal (London, England : 1997)*, 214, 102–108.
- Portela, D. A., Otero, P. E., Briganti, A., Romano, M., Corletto, F., & Breggi, G. (2013). Femoral nerve block: A novel psoas compartment lateral pre-iliac approach in dogs. *Vet. Anaesth. Analg.*, 40, 194–204.
- Portela, D. A., Verdier, N., & Otero, P. E. (2018). Regional anesthetic techniques for the pelvic limb and abdominal wall in small animals: A review of the literature and technique description. *Veterinary Journal (London, England : 1997)*, 238, 27–40.
- Raymond, S. A., Steffensen, S. C., Gugino, L. D., & Strichartz, G. R. (1989). The role of length of nerve exposed to local anesthetics in impulse blocking action. *Anesthesia and Analgesia*, 68, 563–570.
- Re, M., Blanco, J., & DeSegura, I. A. G. (2016). Ultrasound-guided nerve block anesthesia. *Veterinary Clinics of North America - Food Animal Practice*, 32, 133–147.
- Re, M., Blanco-Murcia, J., Fernández, A. V., Simón, I. G., & DeSegura, I. A. G. (2014). Ultrasound-guided anaesthetic blockade of the pelvic limb in calves. *Veterinary Journal (London, England : 1997)*, 200, 434–439.
- Roberts, S. (2006). Ultrasonographic guidance in pediatric regional anesthesia. Part 2: Techniques. *Paediatric Anaesthesia*, 16, 1112–1124.
- Shilo, Y., Pascoe, P. J., Cissell, D., Johnson, E. G., Kass, P. H., & Wisner, E. R. (2010). Ultrasound-guided nerve blocks of the pelvic limb in dogs. *Veterinary Anaesthesia and Analgesia*, 37, 460–470.
- Trein, T. A., Floriano, B. P., Wagatsuma, J. T., Ferreira, J. Z., DaSilva, G. L., DosSantos, P. S. P., Perri, S. H. V., & Oliva, V. N. L. S. (2017). Effects of dexmedetomidine combined with ropivacaine on sciatic and femoral nerve blockade in dogs. *Veterinary Anaesthesia and Analgesia*, 44, 144–153.
- Valverde, A., Sinclair, M., et al. (2015). Ruminant and swine local anesthetic and analgesic techniques. In K. Grimm, L. Lamont, W. Tranquilli, et al. (Eds.), *Veterinary anaesthesia and analgesia* (5th edn, pp. 956–958). USA: John Wiley & Sons.
- Vettorato, E., Bradbrook, C., Gurney, M., Aprea, F., Clark, L., & Corletto, F. (2012). Peripheral nerve blocks of the pelvic limb in dogs: A retrospective clinical study. *Veterinary and Comparative Orthopaedics and Traumatology*, 25, 314–320.
- Viscasillas, J., Drozdzyńska, M. J., & McSloy, A. (2015). Ultrasound-guided sciatic and femoral nerve block for metatarsal fracture stabilization in a two-days neonatal calf. *Open Veterinary Journal*, 3, 1–4.
- Waag, S., Stoffel, M. H., Spadavecchia, C., & Eichenberger, U. (2014). Ultrasound-guided block of sciatic and femoral nerves: An anatomical study. *Laboratory Animals*, 48, 97–104.
- Winnie, A. P., Ramamurthy, S., & Durrani, Z. (1973). The inguinal paravascular technic of lumbar plexus anesthesia: The “3-in-1 block”. *Anesthesia and Analgesia*, 52, 989–996.
- Zhang, L., Tong, Y., Li, M., Niu, X., Zhao, X., Lin, F., & Li, Q. (2015). Sciatic-femoral nerve block versus unilateral spinal anesthesia for outpatient knee arthroscopy: A meta-analysis. *Minerva Anestesiologica*, 81, 1359–1368.