



Infected Haller Cell Misdiagnosed as Invasive Fungal Sinusitis - A Parallax

Reshma Raj MS¹ · Prerna Angrish MS¹ · Chirag K Ahuja² · Kanika Arora¹ · Ramandeep Singh Virk¹ 

Received: 28 May 2022 / Accepted: 23 September 2022
© Association of Otolaryngologists of India 2022

Abstract

We report an unusual case of a 29-year-old female with a short duration of right lower eyelid swelling, painful eye movement and paraesthesia of right cheek. She was subsequently worked up with mucormycosis in mind, but intra-operative findings were suggestive of an infected Haller cell and post-operatively she was symptom free.

Keywords Infected haller cell · mucormycosis · infraorbital cell

Introduction

Haller cell (HC) is a normal anatomical variant of paranasal sinus which can arise either from the anterior or posterior ethmoidal cell [1]. It has an overall incidence of 5.5–45.9% [2] and is located in roof of the maxillary sinus, above the maxillary sinus ostium, forming inferior orbital wall and lateral wall of infundibulum [3]. HC itself does not present as disease state but predisposes to Sino-nasal pathology by obstructing the normal ventilation and drainage pathway [2]. Of all the possible differentials causing these symptoms, patient was counselled about possibility of invasive fungal disease due to cognitive bias after the pandemic, but it finally turned out to be an infected Haller cell intra-operatively.

Case Report

A 29-year-old female with no comorbidities presented to our ENT OPD with complaints of swelling in right lower eyelid for two days with paresthesia over right cheek for one day which was sudden in onset with no associated

visual disturbance, nasal obstruction, or nasal discharge. On examination there was painful right eye movement on downward gaze and paresthesia over distribution of maxillary nerve on right cheek and periorbital edema with normal visual acuity. On nasal endoscopy, nasal mucosa was congested but no purulent discharge or necrotic tissue noted. In view of the persistent complaints radiological investigations were done, Non-Contrast Computed Tomography of Nose, Paranasal sinus (PNS) and orbit (NCCT) (Fig. 1 A) revealed soft tissue density in right infra-orbital cell causing adjoining bony rarefaction, obstructing the osteo-meatal complex (OMC) and Contrast Enhanced Magnetic Resonance Imaging (CEMRI) of Nose, PNS and Orbit revealed T1 isointense and T2 hyperintense contents in the infra-orbital cell with mild adjoining inflammation (Fig. 1B-D). The orbital fat was preserved. She was prescribed a course of antibiotics for five days following which her eye complaints improved but altered sensations over the cheek persisted. In view of the persisting paresthesia and imaging findings, the patient was counselled regarding possibility of invasive fungal sinusitis and was planned for surgery. She underwent Endoscopic sinus surgery in the form of uncinectomy and maxillary antrostomy with intra-operative findings of inverted uncinate process obstructing the OMC (Fig. 2). An infected haller cell with unhealthy mucosa and minimal purulent discharge was present between the right maxillary antrum and floor of orbit (Fig. 3). The bulla ethmoidalis and the right infra-orbital cell were uncapped and the hypertrophied mucosa from the infra-orbital cell region was sent for Fungal smear and Histopathological examination (HPE). The post-operative HPE of the mucosa showed

✉ Ramandeep Singh Virk
virkdoc@hotmail.com

¹ Department of Otolaryngology and Head and Neck surgery, Postgraduate Institute of Medical Education and Research, Chandigarh, India

² Department of Radiodiagnosis, Postgraduate Institute of Medical Education and Research, Chandigarh, India

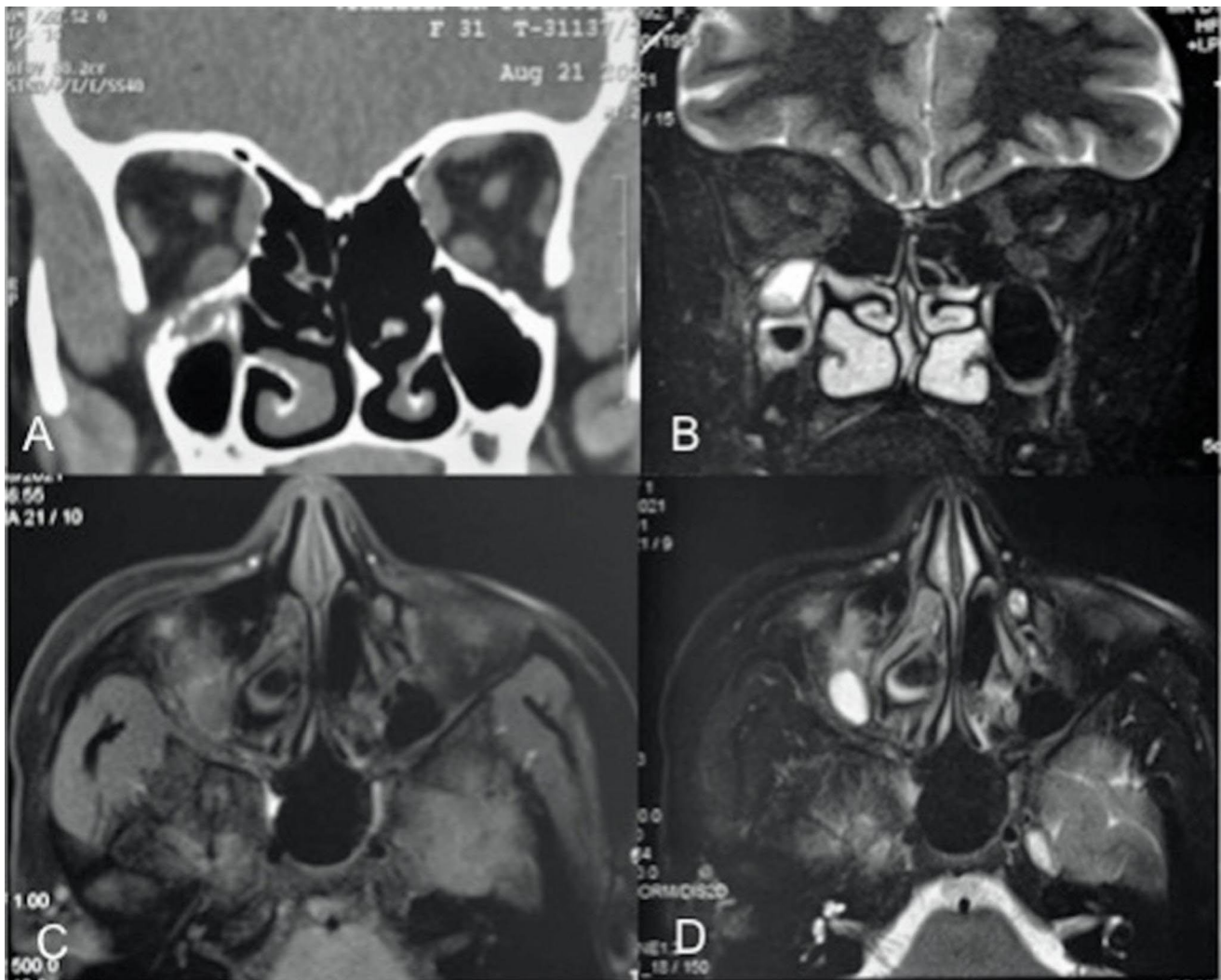


Fig. 1 Coronal NCCT scan (A) showing soft tissue density in right infra-orbital region obstructing the osteomeatal complex. Coronal T2 FS (B), axial T1 FS (C) and T2 FS (D) MR images demonstrate

fibro-collagenous tissue with mixed infiltrate of neutrophils, lymphocytes plasma and occasional eosinophils, no granuloma or fungal hyphae seen suggestive of inflammatory pathology and fungal smear showed no fungal hyphae. Post-surgery her symptoms resolved and on postoperative day three she was able to perceive cheek sensations.

Discussion

Haller cell is known by many names like infraorbital ethmoidal cell, orbito-ethmoidal cell, maxilla-ethmoidal cell [1]. HC can arise from anterior or posterior ethmoidal cell but more commonly arises from anterior ethmoidal cell near the infundibulum and it must be differentiated from

liquified soft tissue in the right infra-orbital region in the Haller cell area along with mucosal thickening in the maxillary sinus. The rest of the sinuses appear clear

infraorbital recess of maxillary sinus. The HC is in close relation to the infraorbital nerve [4].

An enlarged HC constricts the posterior aspect of ethmoidal infundibulum and superior aspect of maxillary ostium thereby blocking the drainage pathway [1]. It can compress the infra-orbital nerve and produce symptoms like paresthesia of cheek, painful eye movements, nasal obstruction, nasal discharge, headache, facial or eye swelling, proptosis, and diplopia. The same symptoms along with a normal nasal endoscopy has been seen in mucormycosis patients during the pandemic. So, a limited fungal infection was kept as one of the main differentials.

India has been a hotspot for mucormycosis cases with incidence of 0.14 cases per 1000 population. But after the second wave of COVID-19 pandemic, there has been an unprecedented escalation in the number of mucormycosis

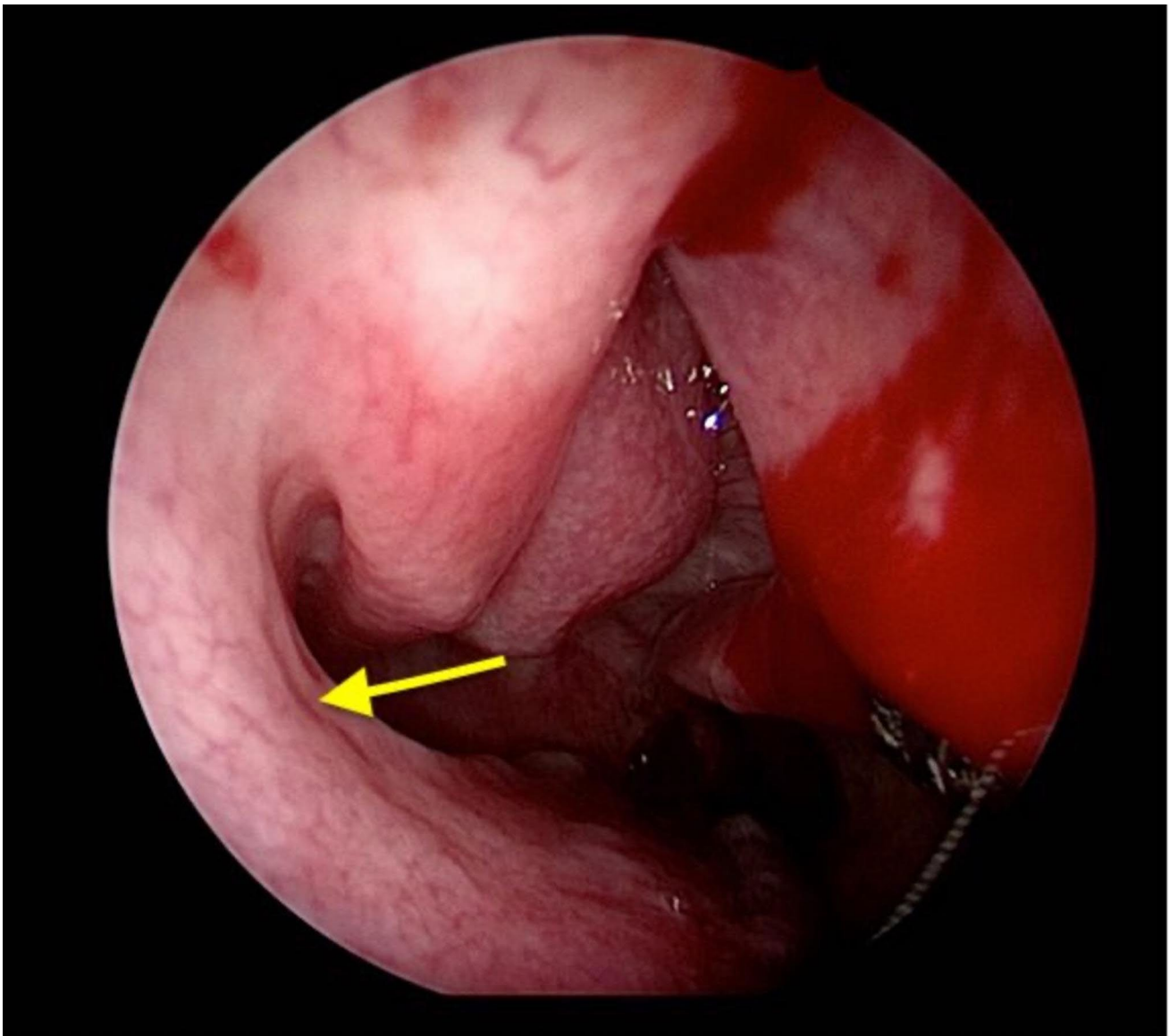


Fig. 2 Intra-operative image-Inverted uncinate process (*yellow arrow*) obstructing the OMC in the right nasal cavity

cases [5]. Although mucormycosis is common in patients with uncontrolled diabetes mellitus, the extensive use of steroids in a COVID-19 patient leads to cytokine storm predisposing them to development of life-threatening fungal infection which has a very drastic outcome on the future quality of life of the individual [6]. Persisting paresthesia over right side of cheek in our patient, especially when India was taken by mucormycosis wave in covid pandemic era, possibility of mucormycosis in our patient was kept as one of the differentials.

The diagnosis of an infected HC is quite difficult and can be easily missed or mistaken for any other disease as it is not visible on endoscopy due to hidden location lateral to the uncinate process and needs radiological imaging to confirm diagnosis. On NCCT it usually appears as a well-defined

round oval or tear drop shaped unilocular or multilocular radiolucency with smooth borders medial to the infraorbital foramen just like in our case. Although CEMRI is not routinely done, an infected HC has fluid-filled appearance in the maxillary sinus roof and is hyperintense on T1-weighted and isointense on T2-weighted imaging [1], in contrast to mucormycosis which appears isointense on T1-weighted imaging with post-contrast enhancement and variable intensity on T2-weighted imaging [7]. HC on NCCT scan can be identified by a criteria by Ahmed et al.: (1) Well-defined, round, tear-drop shaped radiolucency, single or multiple, unilocular or multilocular, with smooth border, which may be corticated, (2) Located medial to infraorbital foramen, (3) Most of the border in the panoramic section being visible, (4)

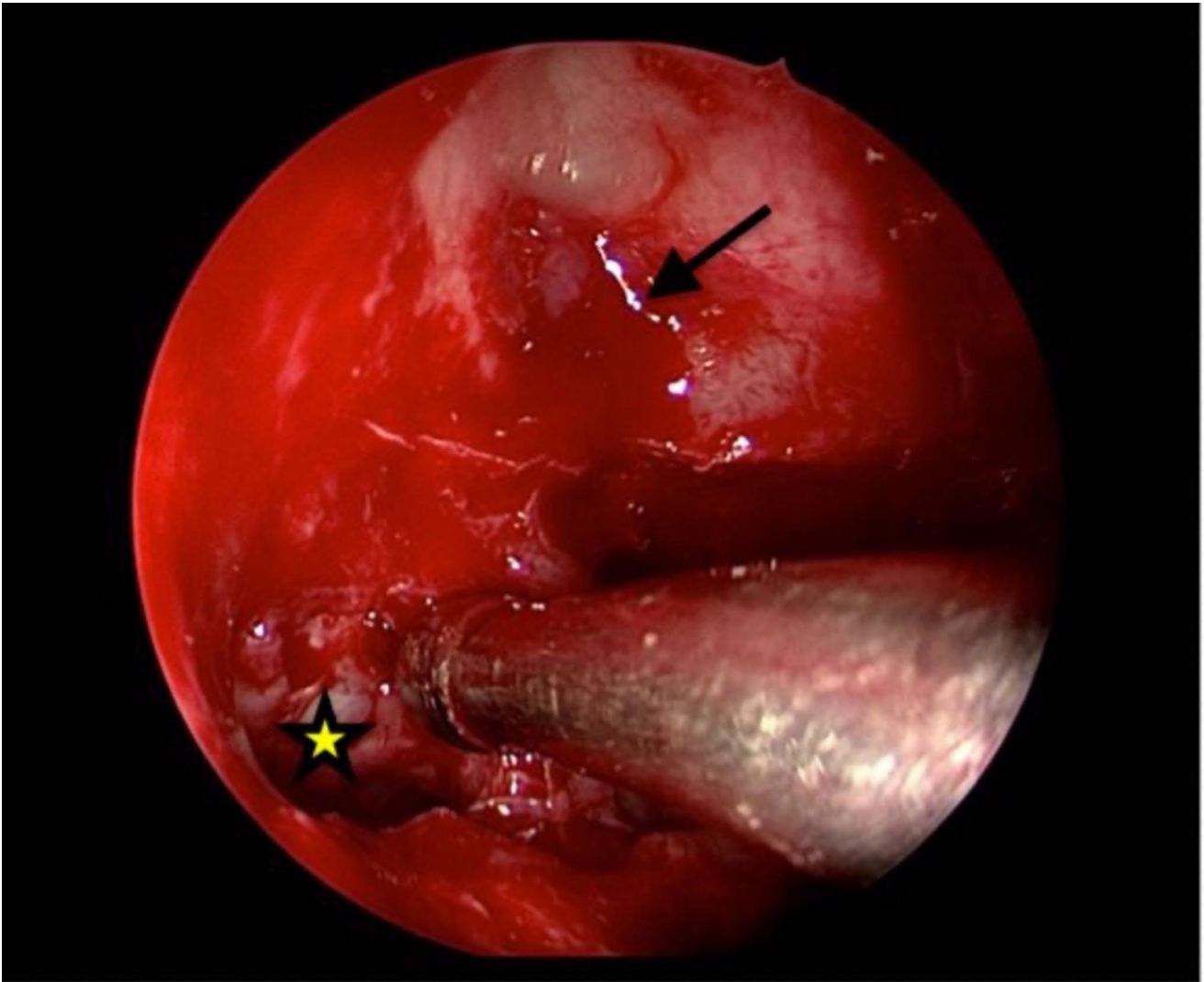


Fig. 3 Intra-operative image- Haller cell uncapped (*yellow star*) and the Bulla uncapped (*black arrow*)

The inferior border of the orbit lacks cortication or remains indistinguishable in areas superimposed by this entity.

With the above history and clinical examination, our main differential diagnosis was mucormycosis, neuroma of infraorbital nerve and mucocele of Haller cell and hence we proceeded for surgery but the intraoperative findings as mentioned earlier clearly suggested it to be a case of infected HC causing symptoms which as expected in the post-operative period completely resolved and patient was symptom free within a week's time.

To conclude, Infected Haller cell should always be thought of as a differential diagnosis in a patient with an acute history of cheek paresthesia and not be biased during this mucormycosis epidemic. Also, for a diagnosis of infected HC, radiological imaging is very useful as it can be missed on nasal endoscopy.

Contributions All authors contributed equally to the publication.

Funding Statement Not applicable.

Data Availability Not applicable.

Declarations

Code of Availability Not applicable.

Conflicts of Interest/Competing Interests The author declare that they have no conflict of interest.

Ethics Approval Ethical approval was not necessary in the preparation of this article.

Patient Consent for Participation Written informed consent was taken from the patients' parents at every step of investigation and treatment as per protocol.

Consent for Publication Consent was taken for the use of patient's treatment related data and images for academic use and publication on the condition of anonymity.

References

1. Choi JH (2020) Hypoesthesia of midface by isolated Haller's cell mucocele. *Braz J Otorhinolaryngol* 86:516–519
2. Wanamaker HH (1996) Role of Haller's cell in headache and sinus disease: a case report. *Otolaryngol Head Neck Surg* 114:324–327
3. Caversaccio M, Boschung U, Mudry A (2011) Historical review of Haller's cells. *Ann Anat* 193:185–190
4. Yesilova E, Bayrakdar I The Appearance of The Infraorbital Canal and Infraorbital Ethmoid (Haller's) Cells on Panoramic Radiography of Edentulous Patients. *Biomed Res Int* 20188; 2018:1293124
5. Pal P, Singh B, Singla S, Kaur P (2021) Mucormycosis in COVID-19 pandemic and its neurovascular spread. *Eur Arch Otorhinolaryngol* 12:1–8
6. Mehta S, Pandey A (2020) Rhino-orbital mucormycosis associated with COVID-19. *Cureus*. ;12.e10726
7. Aribandi M, McCoy VA, Bazan IIC (2007) Imaging features of invasive and noninvasive fungal sinusitis: a review. *Radiographics* 27:1283–1296

Publisher's Note Springer Nature remains neutral with regard to jurisdictional claims in published maps and institutional affiliations.

Springer Nature or its licensor holds exclusive rights to this article under a publishing agreement with the author(s) or other rightsholder(s); author self-archiving of the accepted manuscript version of this article is solely governed by the terms of such publishing agreement and applicable law.