

Ultrasound-guided supraclavicular brachial plexus block in patient with halo device

Mohamed Bilal Delvi

Department of Anesthesia,
College of Medicine, King Saud
University, Riyadh, Saudi Arabia

Address for correspondence:
Dr. Mohamed Bilal Delvi,
Department of Anesthesia, #41,
PO Box 7805 KCUH, Riyadh
11472, Saudi Arabia.
E-mail: delvimb@yahoo.com

www.saudija.org

ABSTRACT

Ultrasound guided regional blocks are on the rise, many institutes are training their staff to master this technique of regional anesthesia. Regional anesthesia in case of an emergency surgery or elective surgery can be the best choice. The case described here is an example - patient with a halo fixation device after motor vehicle accident scheduled for surgery of the extremity. The main aim of management of this case is to achieve a safe anesthesia with minimal interference of the cervical fixation. Supraclavicular brachial plexus block is a good choice for surgeries of the arm and hand and use of an ultrasound to guide the block adds to the safety profile of this versatile block. It has been described as "Spinal of the upper limb". Patients with co-morbidities and injuries to the cervical spine are challenging cases to anesthetize, as regional anesthesia is a very attractive option, failure of the regional block will expose the patient to all adverse sequelae, which were being avoided by planning for a regional anesthesia. Ultrasound has revolutionized the way regional anesthesia is practiced and the proper drug can be placed at the right place in the hands of an experienced anesthesiologist and the block will help in avoiding all the complications of endotracheal anesthesia in these cases.

Key words: *Ultrasound, brachial plexus block, halo device*

DOI: 10.4103/1658-354X.62610

INTRODUCTION

Ultrasound guided regional blocks are used with great interest nowadays. We described here the anesthetic management of a patient with a halo fixation device following motor vehicle accident scheduled for upper extremity surgery. The main aim of the management of this case was to achieve a safe anesthesia with minimal interference of the cervical fixation.

CASE REPORT

A 30-year-old male patient post motor vehicle accident was admitted through the emergency to King Khalid University hospital with multiple injuries, the main concern on admission was a cervical fracture at level C3 and C4 with a very unstable cervical spine he had to undergo a fixation of the halo frame to stabilize his cervical spine under local infiltration with Lignocaine, he had also sustained pelvic fracture and compound fracture both bones in the left upper limb.

He was scheduled as an emergency case for debridement, open reduction and internal fixation of radius and ulna of the left arm. On examination, the patient was fully

conscious and oriented, he was in the halo frame, his back was positioned at 45 degree angle due to the halo frame and access to his airway was limited and difficult for conventional endotracheal anesthesia. The choice of anesthesia in this situation was discussed with the patient and regional anesthesia under ultrasound guidance was offered to him, the patient consented to the anesthesia procedure. The orthopedic surgeon was informed about the inability to move the patient to the OR table and after consultation it was decided to do the procedure on the patients trolley with all aseptic precautions. An ultrasound guided supraclavicular block was planned (as the surgeon was planning to use the tourniquet) and explained to the patient. The difficult intubation trolley along with equipment for awake fiber optic intubation was prepared and checked inside the OR in case of any adverse outcome or failed regional block.

A large bore IV line (16G) with lactated ringer was introduced on the right hand under local anesthesia, monitors like ECG, pulse oximetry, end tidal carbon dioxide (14G cannula connected to the face mask) were attached. The supraclavicular area was cleaned with Iodine and Alcohol and draped with a transparent drape. An M-Turbo Ultrasound Machine (Sonosite Inc Bothell WA) with a High frequency linear probe (HFL38 13-6 MHz) was prepared

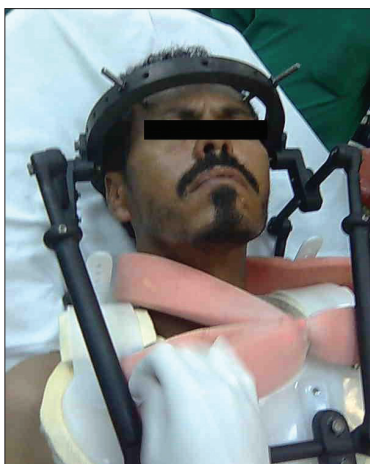

Figure 1: Patient in halo device on the transportation trolley (Note position of the back rest)

with sterile gel and the image of the brachial plexus was acquired with appropriate adjustments of the gain, depth and focusing on the target for block, 20 cc of Bupivacaine 0.5% and 2% Lignocaine (50-50) were prepared in two 10cc syringes. A stimplex needle 50mm 22 G (B Braun) was introduced under ultrasound guidance by the in-plane technique, the needle tip was directed to the angle between the first rib and the subclavian artery after confirming that the aspiration was negative for blood the first 10ccs of the drug was injected observing the spread of the drug and the displacement of the brachial plexus in a upward and lateral position, another 10ccs of the drug was injected around the superior extent of the brachial plexus.

Surgery commenced 10 minutes after the injection, after testing for anesthesia in the surgical field. The patient was sedated with 2mg Midazolam and the surgery was uneventful. Surgery lasted for one hour and 20 minutes; all the monitored parameters were within normal limits and the patient was transferred to the post anesthesia care unit with oxygen mask and to the floor after one hour.

DISCUSSION

A case of cervical spine fracture, which is unstable, is challenging to the anesthesiologist as it poses many anesthetic implications namely, the airway maintaining a neutral position as there should be no movement at the atlanto-occipital joint, positioning of the patient and during transport of the patient.

Ultrasound-guided regional blocks are on the rise and have been encouraging to the regional anesthesiologist as many studies have proved the same.^[1] There are case reports on management of the patient in the halo frame for various surgeries under general anesthesia with either endotracheal intubation or other airway devices

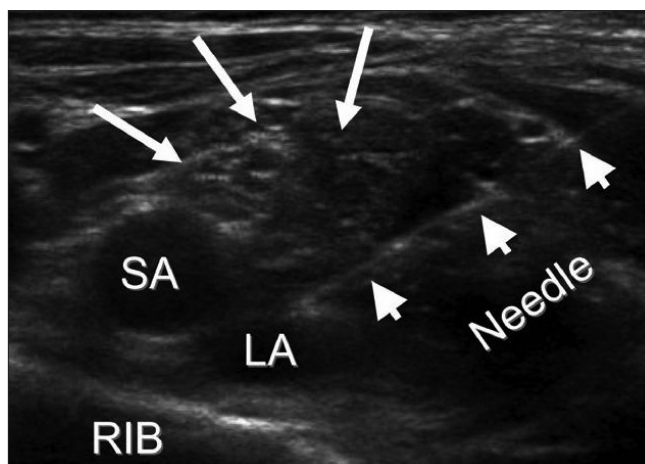


Figure 2: The supraclavicular block at the angle between the first rib and the subclavian artery. SA-subclavian artery, LA-local anesthetic, Big arrows – brachial plexus, small arrows – needle

in emergency management.^[2-4] The halo traction device poses a number of problems to the anesthesiologist mainly accessibility to the airway and in positioning the patient supine or lateral for any procedure [Figure 1].

Awake endotracheal intubation is recommended as a safe way to access the airway in such cases but other airway tools like combitube, intubating laryngeal mask airway, retrograde endotracheal intubation have been described in case reports. Ultrasound-guided block of the brachial plexus in the supraclavicular has higher rate of success if placed at the angle between the subclavian artery and the first rib laterally, but it has to be done with the tip of the needle under the beam of ultrasound from the introduction of the needle to the deposition of the drug^[5] [Figure 2].

In conclusion, an ultrasound-guided supraclavicular brachial plexus block can be used successfully in a patient with cervical fracture and in a halo device, anticipation of failure of the block and complications are to be considered and the anesthesiologist must be prepared and equipped with techniques described in the various cases, so to the best of our knowledge we did not come across any case of a patient in a halo frame undergoing a regional block under ultrasound guidance.

REFERENCES

1. Soeding PE, Sha S, Royse CE, Marks P, Hoy G, Royse AG. A randomized trial of ultrasound-guided brachial plexus anaesthesia in upper limb surgery. *Anaesth Intensive Care* 2005;33:719-25.
2. Crosby ET. Airway management in adults after cervical spine trauma. *Anesthesiology* 2006;104:1293-318.
3. Sims CA, Berger DL. Airway risk in hospitalized trauma patients with cervical injuries requiring halo fixation. *Ann Surg* 2002;235:280-4.

4. Bhardwaj N, Yaddanapudi S, Makkar S. Retrograde tracheal intubation in a patient with a halo traction device. *Anesth Analg* 2006;103:1628-9.
5. Soares LG, Brull R, Lai J, Chan VW. Eight ball, corner pocket: The optimal needle position for ultrasound-guided supraclavicular block. *Reg Anesth Pain Med* 2007;32:94-5.

Source of Support: Nil, **Conflict of Interest:** None declared.