

# The Removal of a Fractured Guidewire During Mechanical Thrombectomy. A Case Report

Rares Cristian Filep<sup>1</sup>, Andrei Florin Bloj<sup>2\*</sup>, Lucian Marginean<sup>3</sup>

<sup>1</sup> PhD School of Medicine, George Emil Palade University of Medicine, Pharmacy, Science, and Technology of Targu Mures, Romania

<sup>2</sup> Emergency Clinical County Hospital Targu Mures, Romania

<sup>3</sup> George Emil Palade University of Medicine, Pharmacy, Science, and Technology of Targu Mures, Romania

## ABSTRACT

Recent randomized controlled trials have transformed the treatment of acute ischemic stroke. Mechanical or aspiration thrombectomy is the main treatment option for occlusions of large intracranial vessels. Despite its high technical success rate, endovascular thrombectomy can sometimes be complicated by anatomical peculiarities or device failures. The most frequent complications are related to vessel dissection or vessel perforation by devices while navigating intricate anatomy. Rarer still are technical device failures, like spontaneous stent-retriever detachment, which occurred with older generation retrievers. This case reports a rare device failure, which, to the best of our knowledge, has not been reported in the literature so far, namely a microwire fracture in the middle cerebral artery. This was successfully removed with an Eric stent-retriever. The potential causes and possible management strategies are discussed.

**Keywords:** acute ischemic stroke, large vessel occlusion, mechanical thrombectomy

Received: 3 September 2020 / Accepted: 8 February 2021

## BACKGROUND

Acute ischemic stroke (AIS) is one of the leading causes of neurological death and disability worldwide. Up to 2015, intravenous tPA was the only approved therapy for AIS secondary to a large vessel occlusion (LVO). This strategy achieved recanalization rates of up to 30% with only modest clinical outcomes. Endovascular thrombectomy changed AIS treatment owing to recanalization rates of up to 90% and a higher likelihood of good long-term neurological outcomes [1].

Despite all the significant advantages of thrombectomy, some procedures are futile or even harmful to patients due to the intricate anatomy, clot composition, and technical or device complications. Arterial dissection or vessel perforation are major complications that can occur in up to 5% of thrombectomy procedures [2]. Device failures are infrequent and were reported with older generation devices.

The current case reports the spontaneous fracture of a guidewire in the intracranial vessels.

## CASE REPORT

A 49-year-old male patient with a history of alcohol abuse was brought to the emergency department of the Emergency Clinical County Hospital, Targu Mures, Romania, complaining of abrupt onset of right extremity weakness and speech difficulties.

Neurological examination revealed a conscious patient, a Glasgow Coma Scale (GCS) 15, with grade 2 right hemiparesis, Kaplan 2 aphasia, and a National Institute of Health Stroke Scale (NIHSS) of 8.

On admission, non-contrast CT (NCCT) and CT angiography showed decreased attenuation of the left insula and putamen, consistent with an Alberta Stroke Program Early CT Score (ASPECTS) score of 8, and occlusion of the distal M1 segment of the left middle cerebral artery (MCA).

Under conscious sedation, one hour after admission, via a femoral approach, a 9F Cello balloon-guide catheter (Medtronic, California, USA) was placed in the distal internal carotid artery (ICA). A Rebar 27 microcatheter (Medtronic, California, USA) with an Avigo guidewire (Medtronic, California, USA), were navi-

\* Correspondence to: Andrei Florin Bloj, County Emergency Hospital Targu Mures, Romania. E-mail: bloj.florin@gmail.com

gated in the MCA and passed through the thrombus (Figure 1a, b).

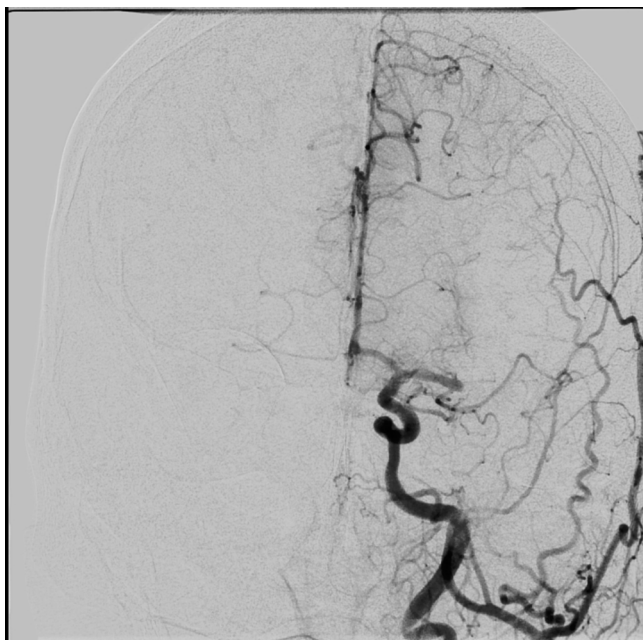
Although two retrieval attempts were performed, the vessel opened only partially due to apparent stenosis located at the MCA bifurcation after the thrombus was passed. Re-occlusion occurred after a few minutes. The wire and microcatheter were navigated for a third time distal to the occlusion.

While trying to retrieve the wire, the distal radioopaque tip fractured spontaneously (Figure 1b) in the distal ICA and MCA. Because no snare devices were available in the department, Solitaire retrievers were used in an attempt to extract the wire. This strategy was unsuccessful. Finally, the fragment was retrieved with an Eric 6x44mm retriever partially opened distal to the ruptured wire's tip (Figures 1c, 2).

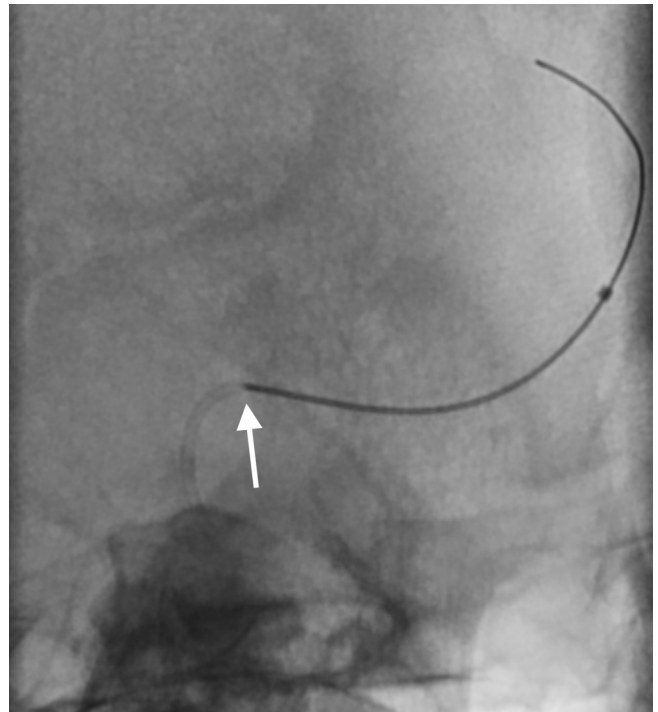
After the wire was extracted, balloon angioplasty was performed twice for the underlying stenosis. However, only a partial reopening of the vessel was obtained.

Post procedurally, the patient's neurological status deteriorated to right hemiplegia and complete global aphasia, with an NIHSS of 17.

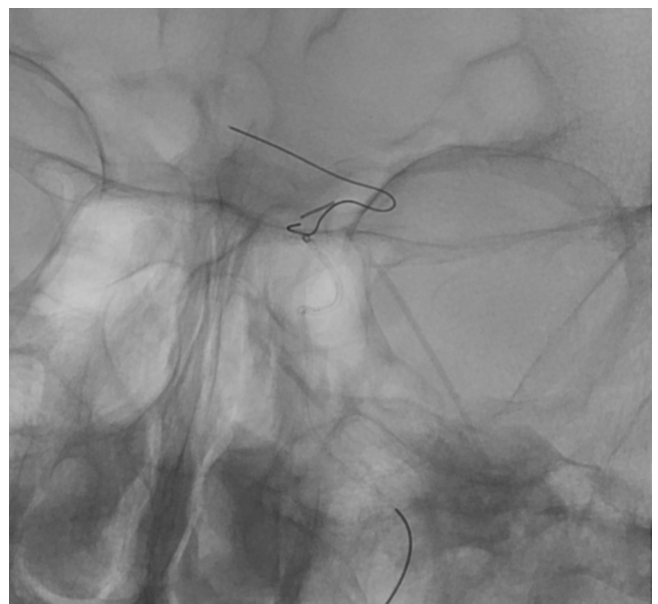
NCCT performed 24 hours later showed a large area of infarcted tissue, corresponding to the MCA territory. Furthermore, a haemorrhagic transformation occurred at the level of the basal ganglia. Subsequent control NCCT confirmed growing brain oedema. The



**Fig. 1a.** Digital subtraction angiogram while injecting contrast in the left ICA shows occlusion of the left MCA's distal M1 segment.



**Fig. 1b.** The fractured radioopaque guidewire tip is seen inside the microcatheter (white arrow) in this unsubtracted, magnified image.



**Fig. 1c.** After multiple attempts, successful capture of the wire with the Eric retriever is visible.



**Fig. 2.** The distal radioopaque 5 cm of the wire extracted is seen along with Eric retriever's structure.

patient developed anisocoria. His consciousness gradually declined to a GCS of 3 four days later. Due to a cardiac arrest, the patient unfortunately died.

## ■ DISCUSSIONS

Spontaneous fracture of microwires, used for intracranial vessels, is an infrequent complication during neurovascular interventions. Micro wire entrapment in cerebral arteries with subsequent rupture in the aorta has been published before [3, 4]. However, the current case reports a different technical scenario, requiring distinct management strategies.

From the beginning of the current reported procedure and during the necessary repetitive manoeuvres, the wire's advancement and retraction were challenging; however, once the microcatheter was "relaxed", the wire moved smoothly. At the third attempt to pass the occlusion with the microcatheter, while trying to remove the microwire, the distal part detached spontaneously, partially inside the microcatheter (Figure 1b).

The operators felt neither the resistance while retracting the wire, nor the rupture itself.

Due to a lack of snare- or alligator-type devices in the department at that time, stent-retrievers were used for wire extraction. The first attempt was to advance a Solitaire distal to the wire tip pointing in the ACA and catch it while retracting. This manoeuvre failed and was followed by two Solitaire devices, deployed simultaneously, one entirely distal for the tip. The second, partially opened in front of the wire tip, followed by retrieval of both devices simultaneously. After these failed attempts, a first-generation Eric 6x44mm stent-retriever was used.

We navigated the microwire and microcatheter distal to the tip and deployed an Eric 6x44mm stent-retriever.

While gently retrieving the device, the wire tip's capture was noticed, and forward pressure was placed on the microcatheter to secure the wire inside the retriever. Both microcatheter and retriever were slowly pulled together, and the wire was successfully extracted at the first attempt (Figures 1c, 2).

Micro wire complications during neurovascular procedures are relatively rare. One that is more frequently reported is vessel perforation with the wire tip. It occurs during approximately 1.5% of thrombectomy procedures [2]. One other unusual complication is wire retainment in small intracranial branches, possibly due

to vasospasm [3], or entanglement with stent struts [5]. In these cases, the wire was transected at the level of the femoral artery. Fracture of the wire body occurred months later at the level of the aorta, leading to severe cardiovascular and pulmonary complications [3]. Intraoperative fracture of the wire tip in the intracranial vessels has not been reported previously. A wealthier scientific body of evidence related to such complications is found in the coronary intervention's literature.

Predisposing factors for fracture or entrapment are tortuous anatomy, severe arterial stenosis or occlusions, the necessity to cross a previously implanted stent or the need to perform a "jailed wire technique", in which a guidewire is placed in one side-branch for its protection while carrying out a balloon angioplasty for bifurcation lesions. Additionally, some mechanisms can enhance fracture risk: excessive twisting of the wire, more than 180 degrees [6]. Moreover, twisting the wire through a "tensioned" microcatheter caused by tortuous vessels can further increase fracture probability.

Several therapeutic strategies are available for extracting fractured guidewires. Specific devices designed for intravascular foreign body removal, like a snare loop, or gooseneck snare, can be an excellent first choice. If a snare-device is not available, a double- or triple-wire technique can be an alternative [7]. It involves navigating two or three wires parallel to the fractured fragment and twisting them, to entangle the piece, followed by removing all of them at once. This technique can have devastating consequences in the intracranial vessels, such as vasospasm, perforation, or even further fractures. Therefore, its use should be avoided. Stent-retrievers have been used successfully for the extraction of coils. In a prospective case series, Leslie-Mazwi et al. (2013) used stent-retrievers for the retrieval of displaced coils during aneurysm treatment in 14 patients [8]. In their experience, no complications related to coil extraction were encountered. The safety and lack of complications of stent-retrievers for extraction of coils might not hold true for guidewire tips; these are stiffer than coils and can potentially, perforate or dissect vessels during the retrieval manoeuvre. In the absence of snare devices, we were obliged to use a retriever. The tip of the fragment was not captured by the Solitaire device but was extract by an Eric retriever.

If wire removal fails, a stent can be implanted to cover the wire and position it against the vessel wall. Stenting remains a good first-line approach in these cases.

## ■ CONCLUSIONS

Intraprocedural fracture of a microwire tip during mechanical thrombectomy for acute ischemic stroke is an infrequent complication. It can be caused by a combination of tortuous anatomy and excessive twisting of the wire during the procedure, mainly when the microcatheter is tensioned.

In the absence of snare-devices, the Eric stent-retriever can be used to remove the fractured fragment.

## ■ CONFLICT OF INTEREST

The authors declare no conflict of interest.

## ■ REFERENCES

1. Turc G, Bhogal P, Fischer U, et al. European Stroke Organisation (ESO) - European Society for Minimally Invasive Neurological Therapy (ESMINT) Guidelines on Mechanical Thrombectomy in Acute Ischemic Stroke. *J NeuroIntervent Surg*. 2019 Feb 26.
2. Balami JS, White PM, McMeekin PJ, et al. Complications of endovascular treatment for acute ischemic stroke: Prevention and management. *International Journal of Stroke*. 2017;13(4):348–61.
3. Han Z, Du Y, Chen J, Qi H. A retained guidewire fractured with subsequent pericardial tamponade two years after endovascular neurointervention. *Interv Neuroradiol*. 2018;25(1):117–20.
4. Konstas AA, Pile-Spellman J. Aortic dissection associated with a neurointerventional guidewire retained in a perforating branch of the right posterior cerebral artery. *BJR*. 2007;80(960):e290–2.
5. Koo H-W, Park W, Yang K, et al. Fracture and migration of a retained wire into the thoracic cavity after endovascular neurointervention: report of 2 cases. *J Neurosurg*. 2016;126(2):354–9.
6. Al-Moghairi AM, Al-Amri HS. Management of retained intervention guidewire: a literature review. *Curr Cardiol Rev*. 2013;9(3):260–6.
7. Collins N, Horlick E, Dzavik V. Triple wire technique for removal of fractured angioplasty guidewire. *J Invasive Cardiol*. 2007;19(8): E230–4.
8. Leslie-Mazwi TM, Heddier M, Nordmeyer H, et al. Stent Retriever Use for Retrieval of Displaced Microcoils: A Consecutive Case Series. *AJNR Am J Neuroradiol*. 2013 Oct 8;34(10):1996–9.