

# A case report on intensive, robot-assisted rehabilitation program for brainstem radionecrosis

Francesco Tartamella, MD, Antonino Chillura, MD, Maria Francesca Pisano, MSc, Adele Cacioppo, MSc, Simona Licari, MSc, Deborah Caradonna, MSc, Simona Portaro, MD, PhD, Rocco Salvatore Calabrò, MD, PhD\*, Placido Bramanti, MD, Antonino Naro, MD, PhD

## Abstract

**Introduction:** Radiotherapy is a valid treatment option for nasopharyngeal carcinoma. However, complications can occur following irradiation of the closest anatomical structures, including brainstem radionecrosis (BRN). The rehabilitation is poorly described in patients with BRN, despite its usefulness in improving functional independence in patients with brain tumors. We aimed at testing the usefulness of intensive, robot-assisted neurorehabilitation program to improve functional independence in a 57-year-old male with BRN.

**Patient concerns:** A 57-year-old male diagnosed with a nasopharyngeal carcinoma, received a radiation total dose of 72 Gy. Owing to the appearance of a severe symptomatology characterized by dysphagia, hearing loss, and left sided hemiparesis, the patient was hospitalized to be provided with intensive pharmacological and neurorehabilitation treatment.

**Diagnosis:** Follow-up brain magnetic resonance imaging disclosed no residual cancer, but some brainstem lesions compatible with BRN areas were appreciable.

**Intervention:** The patient underwent a 2-month conventional, respiratory, and speech therapy. Given that the patient only mildly improved, he was provided with intensive robot-aided upper limb and gait training and virtual reality-based cognitive rehabilitation for other 2 months.

**Outcomes:** The patient reported a significant improvement in functional independence, spasticity, cognitive impairment degree, and balance.

**Conclusion:** Our case suggests the usefulness of neurorobotic intensive rehabilitation in BRN to reduce functional disability. Future studies should investigate whether an earlier, even multidisciplinary rehabilitative treatment could lead to better functional outcome in patients with BRN.

**Abbreviations:** BRN = brainstem radionecrosis, FIM = Functional Independence Measure, MAS = Modified Ashworth Scale, MMSE = Mini-Mental State Examination, MRC = Muscle Research Council for upper limb muscles (shoulder abductors, elbow flexors, elbow extensors, wrist extensors, finger flexors, hand intrinsic), and upper limb muscles (hip flexors, knee extensors, dorsiflexors, great toe extensor, and plantar flexors), MRI = magnetic resonance imaging, POMA = Tinetti Performance Oriented Mobility Assessment \_B balance, \_G gait, RCI = Reliable Change Index, VR = virtual reality, VRRS = Virtual Reality Rehabilitation System Environment, WST = 3 fl.oz Water Swallow Test.

**Keywords:** brainstem radionecrosis, cognitive rehabilitation, robot-aided gait training, robot-aided upper limb training, virtual reality

Editor: N/A.

All procedures performed in studies involving human participants were in accordance with the ethical standards of the institutional and/or national research committee and with the 1964 Helsinki declaration and its later amendments or comparable ethical standards.

Patient provided his written informed consent to study participation and publication.

The authors have no conflicts of interest to disclose.

IRCCS Centro Neurolesi "Bonino-Pulejo," Messina, Italy.

\* Correspondence: Rocco Salvatore Calabrò, IRCCS Centro Neurolesi "Bonino-Pulejo," Messina, Italy (e-mail: salbro77@tiscali.it).

Copyright © 2020 the Author(s). Published by Wolters Kluwer Health, Inc. This is an open access article distributed under the Creative Commons Attribution License 4.0 (CCBY), which permits unrestricted use, distribution, and reproduction in any medium, provided the original work is properly cited.

How to cite this article: Tartamella F, Chillura A, Pisano MF, Cacioppo A, Licari S, Caradonna D, Portaro S, Calabrò RS, Bramanti P, Naro A. A case report on intensive, robot-assisted rehabilitation program for brainstem radionecrosis. *Medicine* 2020;99:10(e19517).

Received: 19 June 2019 / Received in final form: 23 December 2019 /

Accepted: 10 February 2020

<http://dx.doi.org/10.1097/MD.00000000000019517>

## 1. Introduction

Radiotherapy is a valid treatment option for head-neck malignancies, including nasopharyngeal carcinoma.<sup>[1]</sup> However, complications can occur following irradiation of the closest anatomical structures, including brainstem. About that, brainstem radionecrosis (BRN) is a late, rare, and severe complication of radiotherapy, which can cause severe neurocognitive and motor dysfunctions, including impaired mobility, limitations in activities of daily living, risk for complications of immobility, falls, pain, anxiety/depression, with a consequent loss of functional independence and worsened quality of life.<sup>[2-4]</sup>

Corticosteroids and surgery are the main approaches to limit the evolutivity of BRN, reduce intracranial hypertension, and preserve the neighboring healthy brain.<sup>[5]</sup> The usefulness of rehabilitative approaches in BRN survivors is instead poorly addressed in the literature,<sup>[6]</sup> even though intensive rehabilitation has been shown to be useful in improving cognitive-motor dysfunction, survival, and quality of life in malignant primary brain tumors.<sup>[7,8]</sup>

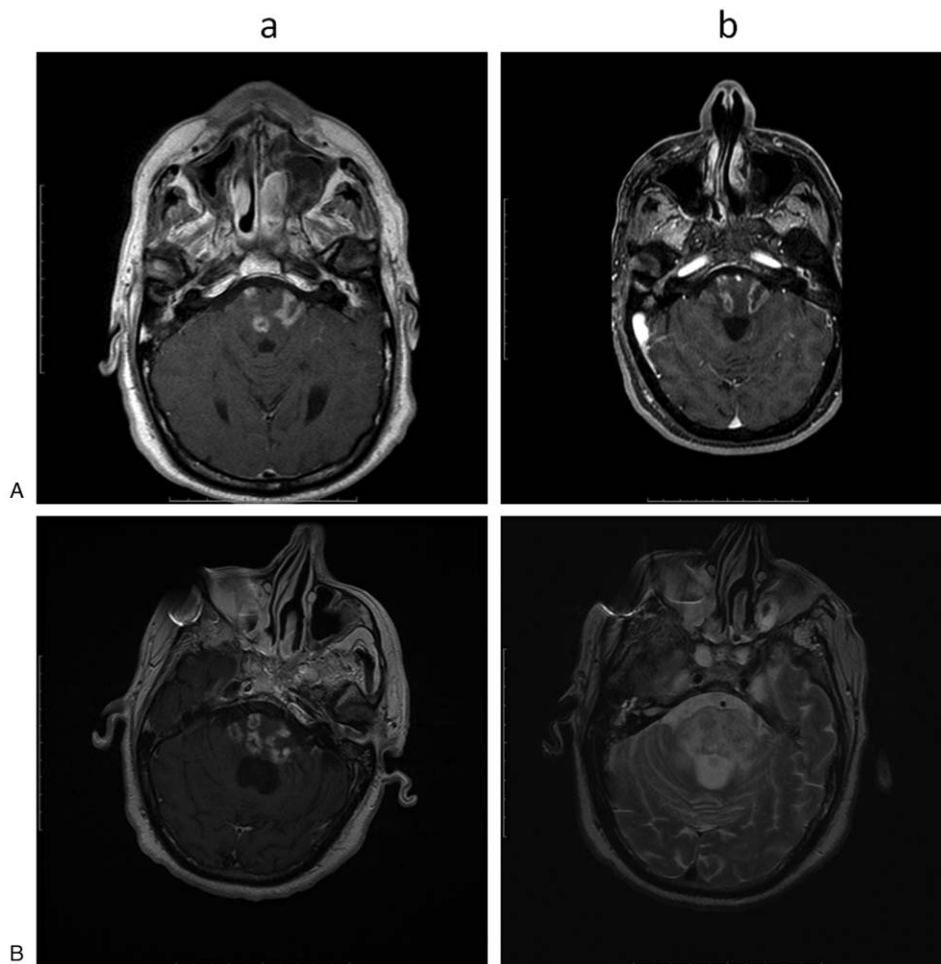
There is growing evidence on the usefulness of rehabilitation robotics (using devices with motorized orthoses and weight

support systems, exercise scenarios, and control strategies) aimed at facilitating the recovery of impaired sensory, motor, and cognitive skills.<sup>[9,10]</sup> However, whether robot-aided rehabilitation of patients with BRN may be helpful in minimizing loss of neurological function, improving functional outcome, and reducing disability burden should be demonstrated. Herein, we report the case of a patient with BRN who was managed with an intensive, robot-assisted neurorehabilitation program, reporting on its usefulness.

## 2. Case description

A 57-year-old male was diagnosed with a nasopharyngeal carcinoma (T4, N2, and M0) on January 2017. His past clinical history was unremarkable. He received a radiation total dose of 72 Gy in 2 Gy fraction, once a day, 5 days per week; an induction chemotherapy (2 cycles) using cisplatin was also provided. Brain magnetic resonance imaging (MRI) performed during the follow-up (T) at second (T2) and fourth (T4) month after radiotherapy showed no residual cancer. However, brain MRI at T6 showed some brainstem lesions characterized by T1-hypointensity, T2-hyperintensity, and heterogeneous contrast enhancement (Fig. 1A). These areas were hypometabolic at the Positron Emission

Tomography. A diagnosis of BRN was thus made. The patient was still asymptomatic but he was provided with dexamethasone 8 mg bid. At T10, the patient was hospitalized as he began to complain a severe symptomatology characterized by left arm and facial paresthesia, dysphagia (as per 3-oz, Water Swallow Test), bilateral hearing loss, left facial nerve palsy, and left sided hemiparesis (as per Muscle Research Council scale) with unstable ambulation (as per Tinetti Performance Oriented Mobility Assessment); consequently, he showed a clear independence impairment (as per Functional Independence Measure) (Table 1). Systemic steroid therapy was continued. An intensive neurorehabilitation program was also prescribed. The rehabilitation protocol consisted of a daily 180-minutes conventional, occupational, and respiratory therapy (including limbs mobilization, muscle tone normalization, muscle strengthening, electrical muscle stimulation, and transfer, gait, and balance training), 6 days a week for 8 weeks. At T11, a brain MRI showed an enlargement and a numerical increment of the brainstem lesions found at T6 (Fig. 1B). At T12 (i.e., 2 months after admission), the patient was still unable to standing and ambulation, and complained also of a moderate cognitive deterioration (as per Mini-Mental State Examination test) and left side spasticity (as per Modified Ashworth Scale) (Table 1). No respiratory or cardiovascular clinical impairment was evident;



**Figure 1.** (A) Brain MRI at T10 showing multiple, nodular or curvilinear brainstem white matter lesions characterized by low signal in T1 (a) with heterogeneous contrast enhancement (“Swiss-cheese”), and high signal in T2 (edema and mass effect) (b). (B) Brain MRI at T11 showing more brainstem lesions with a worsening of the MRI features (edema and contrast enhancement). MRI = magnetic resonance imaging.

**Table 1****Clinical scores.**

	T12	T14	RCI
FIM	33/126	80/126	-7.5
MAS	3/4	2/4	2.6
MRC upper limb	2/5	4/5	-3.7
Lower limb	3/5	4/5	-2.04
WST	4/4	3/4	1.5
MMSE	19/30	23/30	-1.3
POMA_B	8/18	12/18	-2.3
POMA_G	0/14	2/14	-1.2

Statistically significant changes ( $<-1.96$  and  $>1.96$ ) are indexed by the Reliable Change Index (RCI) and highlighted in italic.

FIM=Functional Independence Measure, MAS=Modified Ashworth Scale, MMSE=Mini-Mental State Examination, MRC=Muscle Research Council for upper limb muscles (shoulder abductors, elbow flexors, elbow extensors, wrist extensors, finger flexors, hand intrinsic), and upper limb muscles (hip flexors, knee extensors, dorsiflexors, great toe extensor, and plantar flexors), POMA=Tinetti Performance Oriented Mobility Assessment \_B balance, \_G gait, RCI=Reliable Change Index, WST=3 fl.oz Water Swallow Test.

blood chemistry was normal except for slight leukocytosis. Therefore, the patient was provided with additional 45-minutes of gait training by using LokomatPro (Hocoma AG; Volketswil, Switzerland), 45-minutes of upper limb training by using ArmeoSpring (Hocoma AG), and 30-minutes of cognitive rehabilitation by using the Virtual Reality Rehabilitation System Environment (VRRS) (Khymeia Group; Noventa Padovana, Italy). All these adjunctive treatments were carried daily, 6 days a week.

We adopted these robotic devices as the robotic limb orthoses combined with a body/limb weight support system (and a treadmill in the case of the LokomatPro) provide patients with intensive, repetitive, and task-oriented step/upper limb exercises that the patient can perform longer and with minor effort.<sup>[11]</sup> Specifically, LokomatPro system guides patient's legs on the treadmill according to a preprogrammed physiological gait pattern, which is transmitted to both the treadmill movement and the motorized gait orthoses to induce physiological stance and swing phases. Both the body weight support and the specific level of guidance provided by the motorized gait orthoses were adapted to the patient's clinical condition to either achieve enhancements in gait speed, endurance, and gait quality and minimizing destructive compensatory gait pattern and avoidable stress to the patient.<sup>[12]</sup>

ArmeoSpring provides the patient with game-like functional limb movements and exercises within an interactive 2DVR environment (via computer screen). The exoskeleton is equipped with an upper limb weight support and allows movements related to reach and retrieval function, pronation, supination, wrist flexion and extension, and grasps and release. Thus, movements involving shoulder, elbow, wrist, and finger muscle and joints within a specified workspace are stimulated. The upper limb weight support provided by the limb orthosis was adapted to the patient's clinical condition.<sup>[13]</sup>

Further, employing virtual reality (VR) environment (i.e., VRRS) provides the patient with different kinds of motor tasks in which to hold a real manipulable object while interacting with a VR scenario.<sup>[14]</sup> Specifically, we included a series of exercises involving attention, memory (verbal and visuospatial), spatial cognition, ocular-manual coordination, gnosis abilities, problem solving, executive function, and constructive praxis.<sup>[13]</sup>

The patient well tolerated the entire robot-aided training program, without any adverse event to be reported (including

falls, muscle/tendon/joint strain, skin irritation). After 2 months (T14), the patient got a significant improvement in global functional disability, spasticity, cognitive impairment degree, and balance (Table 1). Significance of changes between T12 and T14 was assessed using the reliable change index. Consequently, the patient was discharged to continue the rehabilitation program in outpatient regimen.

### 3. Discussion

To the best of our knowledge, this is the first report on the application of a robotic-aided rehabilitative program in a patient with BRN. To date, there is no univocally effective treatment of cerebral radionecrosis.<sup>[15]</sup> Conservative management mainly includes corticosteroid therapy,<sup>[15]</sup> hyperbaric oxygen, anti-coagulants, and monoclonal antibodies (e.g., bevacizumab); invasive procedures like craniotomy and lobectomy are used in drug-resistant conditions, but they are associated with a high risk of morbidity.<sup>[5]</sup>

Rehabilitation therapy is a cornerstone in the management of all brain tumor patients.<sup>[7,16,17]</sup> Nonetheless, a rehabilitation plan should be always developed also in brain tumor complications and regardless of the rehabilitation setting.<sup>[17]</sup> Rehabilitation setting and protocol have to be carefully tailored to patient tolerance, level of assistance in mobility, and activities of daily living, in keeping with the sensitivity of the case.<sup>[17]</sup> Thus, an inadequate (in positive or negative) degree of conventional physiotherapy may result in a lack of benefit for the patient in terms of functional outcome.

Our case suggests that robot-aided rehabilitation can help to overcome the limitations to bear conventional physiotherapy due to patient's clinical condition. In fact, our patient showed a clear improvement in nearly all the outcomes when provided with the intensive robot-aided rehabilitative protocol, despite the corticosteroid treatment started since T6, the conventional physiotherapy since T10, and the worsening of MRI lesions from T6 to T11.

The strength point of robotic rehabilitation may depend on the fact that upper and lower extremity orthotic devices may work better in the patients who have persistent weakness and joint instability compared to those with a lesser extent of functional impairment.<sup>[18,19]</sup> Further, robotic devices equipped with body weight support allow enhancing the effects of functional training by providing the patient with highly intensive, repetitive, precise, and task-oriented motor and cognitive tasks, in addition to conventional rehabilitation.<sup>[10,20]</sup> Therefore, robot-aided intervention may be particularly indicated in patients with significant physical limitation, as in the case of BRN.

VR-based devices help in reducing the motor dysfunction in brain tumor patients, by emphasizing retraining and substitution of intact abilities and compensatory approaches.<sup>[21]</sup> Thus, conjugating motor and cognitive rehabilitation may be of significant help in managing BRN-induced motor and cognitive limitations.

It is also hypothesizable that advanced neurorehabilitation may foster a higher entrainment of neuroplasticity mechanisms.<sup>[22]</sup> It is known that neuroplasticity is the key mechanism by which the recovery processes following brain injury take place,<sup>[23]</sup> and it is prompted by daily intensive neurorehabilitation.<sup>[23]</sup> However, we can only speculate on the higher neuroplasticity effect of neurorobotics rehabilitation, as we did not perform neuroplasticity measures.

Notably, our intervention was safe for the patient. He indeed well tolerated the entire robot-aided training program, without any adverse event to be reported (including falls, muscle/tendon/joint strain, and skin irritation). The safety of robot-aided training program was mainly guaranteed by the use of joint sensors to monitor the force information of the subjects during the movement (thus avoiding too high reaction force caused by the muscle tension); a servomechanism preventing muscle strain when the patient appeared with muscle spasm, and controlling movement speed and the displacement of the robot; and a working space limited to a reasonable range of movements. Further, a trained operator set and controlled the parameters of the driving device and monitored the robot motion state in real time. Last, the patient was instructed and put in a position to push a press-and-stop button whether necessary.

One may concern that the improvement we observed could be attributed to the prolonged steroid therapy, spontaneous recovery, or both. However, 6 months of steroid therapy were ineffective, and steroid effectiveness usually occurs rapidly due to the resolution of the edema.<sup>[24]</sup> Thus, spontaneous recovery can be ruled out, also because the MRI pattern was even worse at T11.

In conclusion, our case suggests the usefulness and safety of neurorobotics intensive rehabilitation in BRN to minimize the loss of neurological function, improve functional outcome, and reduce disability burden. Future studies should investigate whether an earlier, even multidisciplinary rehabilitative treatment could lead to better functional outcome in patients with BRN.

## Author contributions

**Conceptualization:** Francesco Tartamella.

**Data curation:** Maria Francesca Pisano, Adele Cacioppo, Simona Licari, Deborah Caradonna.

**Formal analysis:** Maria Francesca Pisano, Adele Cacioppo, Simona Licari, Deborah Caradonna.

**Funding acquisition:** Simona Portaro.

**Project administration:** Simona Portaro.

**Resources:** Simona Portaro.

**Supervision:** Rocco Salvatore Calabrò, Placido Bramanti, Antonino Naro.

**Validation:** Rocco Salvatore Calabrò, Placido Bramanti, Antonino Naro.

**Visualization:** Rocco Salvatore Calabrò, Placido Bramanti, Antonino Naro.

**Writing – original draft:** Francesco Tartamella, Antonino Chillura.

**Writing – review & editing:** Rocco Salvatore Calabrò, Antonino Naro.

## References

- [1] Blanchard P, Lee A, Marguet S, et al. MAC-NPC Collaborative Group-Chemotherapy and radiotherapy in nasopharyngeal carcinoma: an update of the MAC-NPC meta-analysis. *Lancet Oncol* 2015;16:645–55.

- [2] Afrantou T, Natsis KS, Aristomenis A. Brainstem radionecrosis in a patient with nasopharyngeal carcinoma. *Can J Neurol Sci* 2017;44:734–5.
- [3] Hsu YC, Wang LF, Lee KW, et al. Cerebral radionecrosis in patients with nasopharyngeal carcinoma. *Kaohsiung J Med Sci* 2005;21:452–9.
- [4] Lahlali F, Echchikhi Y, Chbili R, et al. Brain radionecrosis in patients irradiated for nasopharyngeal carcinoma: about four cases. *Int Ann Med* 2017;1.
- [5] Li Y, Shi X, Rong X, et al. Neurosurgery and prognosis in patients with radiation-induced brain injury after nasopharyngeal carcinoma radiotherapy: a follow-up study. *Radiat Oncol* 2013;8:88.
- [6] Kim HM, Hong BY, Lee JL, et al. Pontine necrosis related with radiation therapy, complicated with spontaneous hemorrhage. *Brain Neurorehabil* 2017;10:e1.
- [7] Khan F, Amatya B, Ng L, et al. Multidisciplinary rehabilitation after primary brain tumor treatment. *Cochrane Database Syst Rev* 2013;1:CD009509.
- [8] Wong ST, Loo KT, Yam KY, et al. Results of excision of cerebral radionecrosis: experience in patients treated with radiation therapy for nasopharyngeal carcinoma. *J Neurosurg* 2010;113:293–300.
- [9] Calabrò RS, Cacciola A, Bertè F, et al. Robotic gait rehabilitation and substitution devices in neurological disorders: where are we now? *Neurol Sci* 2016;37:503–14.
- [10] Colombo R, Sanguineti V. *Rehabilitation Robotics: Technology and Applications*. London: Elsevier Academic Press; 2018.
- [11] Krebs HI, Volpe BT. *Rehabilitation robotics*. *Handb Clin Neurol* 2013;110:283–94.
- [12] Chung BP. Effectiveness of robotic-assisted gait training in stroke rehabilitation: a retrospective matched control study. *Hong Kong Physiother J* 2016;36:10–6.
- [13] De Luca R, Russo M, Naro A, et al. Effects of virtual reality-based training with BTs-Nirvana on functional recovery in stroke patients: preliminary considerations. *Int J Neurosci* 2018;128:791–6.
- [14] Tieri G, Morone G, Paolucci S, Iosa M. Virtual reality in cognitive and motor rehabilitation: facts, fiction and fallacies. *Expert Rev Med Devices* 2018;15:107–17.
- [15] Shaw PJ, Bates D. Conservative treatment of delayed cerebral radiation necrosis. *J Neurol Neurosurg Psychiatry* 1984;47:1338–41.
- [16] Geler-Kulcu D, Gulsen G, Buyukbaba E, Ozkan D. Functional recovery of patients with brain tumor or acute stroke after rehabilitation: a comparative study. *J Clin Neurosci* 2009;16:74–8.
- [17] Vargo M. Brain tumor rehabilitation. *Am J Phys Med Rehabil* 2011;90(5 Suppl 1):S50–62.
- [18] Hussain A, Budhota A, Contu S, et al. Quantitative assessment of motor functions post-stroke: responsiveness of upper-extremity robotic measures and its task dependence. *IEEE Int Conf Rehabil Robot* 2017;2017:1037–42.
- [19] Wei XJ, Tong KY, Hu XL. The responsiveness and correlation between Fugl-Meyer Assessment, Motor Status Scale, and the Action Research Arm Test in chronic stroke with upper-extremity rehabilitation robotic training. *Int J Rehabil Res* 2011;34:349–56.
- [20] Gassert R, Dietz V. Rehabilitation robots for the treatment of sensorimotor deficits: a neurophysiological perspective. *J Neuroeng Rehabil* 2018;15:46.
- [21] Yoon J, Chun MH, Lee SJ, Kim BR. Effect of virtual reality-based rehabilitation on upper-extremity function in patients with brain tumor: controlled trial. *Am J Phys Med Rehabil* 2015;94:449–59.
- [22] Turner DL, Ramos-Murguialday A, Birbaumer N, et al. Neurophysiology of robot-mediated training and therapy: a perspective for future use in clinical populations. *Front Neurol* 2013;4:184.
- [23] Dimyan MA, Cohen LG. Neuroplasticity in the context of motor rehabilitation after stroke. *Nat Rev Neurol* 2011;7:76–85.
- [24] Vellayappan B, Tan CL, Yong C, et al. Diagnosis and management of radiation necrosis in patients with brain metastases. *Front Oncol* 2018;8:395.