

Does Quadriceps-sparing Total Knee Arthroplasty Increase the Risk of Lower Limb and Component Malalignment? A Minimum 5-year Follow-up Study

Yan-Song Qi, Bo Yang, Jia-Kuo Yu, Ji-Ying Zhang, Ai-Bing Huang, Hai-Jun Wang
Institute of Sports Medicine, Peking University Third Hospital, Beijing 100191, China

Key words: Component Alignment; Conventional; Minimally Invasive; Total Knee Arthroplasty; Quadriceps-sparing

INTRODUCTION

The conventional total knee arthroplasty (TKA) is the most successful surgical procedure for relieving pain and improving poor function in patients with advanced arthritis. However, postoperative pain and delayed rehabilitation are the greatest complaints for the conventional approach. Recently, various minimally invasive surgery (MIS) TKA-techniques have been developed to address the concern. MIS-TKAs have shown less postoperative pain, shorter hospital stays, and quicker recovery after surgery.

Inappropriate surgical technique, inadequate exposure, and lack of TKA experience can cause lower limb and component malalignment, finally result in inferior function and early revision. Quadriceps-sparing (QS) TKA is different from other minimally invasive approaches. The first MIS-QS TKA procedure was performed in 2002^[1] and is similar to medial capsulotomy performed in unicompartmental arthroplasty.^[2] Nevertheless, only a few short-term follow-up studies have been published on lower limb and component alignments following MIS-QS TKA.^[3] The purpose of this study was to evaluate the lower limb and component alignments following MIS-QS TKA in comparison with conventional TKA after more than 5 years follow-up.

METHODS

We retrospectively reviewed 58 cases performed between 2005 and 2007. All surgeries were performed at our institution by a single surgeon (Jia-Kuo Yu). Patients were provided informed written consent, and this study was approved by the institutional review board of Peking University Third Hospital (No. IRB00006761-2011072). Inclusive

criteria included advanced primary osteoarthritis with radiograph-evident narrowing (<2.5 mm) or disappear of the joint gap, persistent symptoms after ≥6 months of conservative treatment. Exclusive criteria included rheumatoid arthritis, knees with excessive deformity (hip-knee-ankle [HKA] angle >15° valgus, >25° varus, or flexion contracture >30°), active infection, and prior surgery.

Of the 58 identified cases, the first group contained 26 patients (28 knees) who underwent conventional TKA between March 2005 and January 2006. The other group consisted of 28 patients (30 knees) who underwent MIS-QS TKA between February 2006 and March 2007.

The average ages of the conventional and QS groups were 64.0 ± 5.7 and 65.3 ± 6.9 years, respectively. The average body mass indices of the conventional and QS groups were 28.1 ± 4.1 kg/m² and 26.5 ± 3.0 kg/m², respectively. Two men and 26 women comprised the conventional group, and 2 men and 28 women comprised the QS group. The mean follow-up time was 74.8 months.

In the QS group, all procedures were performed with a medial parapatellar skin incision. The incision was made from the superior pole of the patella to the medial side where the patella tendon inserts into the tibia tubercle. The extent of

Address for correspondence: Dr. Jia-Kuo Yu,
Institute of Sports Medicine, Peking University Third Hospital, No. 49,
North Garden Road, Haidian District, Beijing 100191, China
E-Mail: yujiakuo@126.com

This is an open access article distributed under the terms of the Creative Commons Attribution-NonCommercial-ShareAlike 3.0 License, which allows others to remix, tweak, and build upon the work non-commercially, as long as the author is credited and the new creations are licensed under the identical terms.

For reprints contact: reprints@medknow.com

© 2015 Chinese Medical Journal | Produced by Wolters Kluwer - Medknow

Received: 18-07-2015 **Edited by:** Li-Shao Guo
How to cite this article: Qi YS, Yang B, Yu JK, Zhang JY, Huang AB, Wang HJ. Does Quadriceps-sparing Total Knee Arthroplasty Increase the Risk of Lower Limb and Component Malalignment? A Minimum 5-year Follow-up Study. Chin Med J 2016;129:92-4.

Access this article online

Quick Response Code:



Website:
www.cmj.org

DOI:
10.4103/0366-6999.172601

the incision into the quadriceps tendon was limited to 2 cm from the superior pole of the patella. The vastus medialis was not split if its patellar insertion was not lower than the upper pole of the patella, and the suprapatellar bursa was only partially opened. The patella osteotomy was done at first, the bone cutting surface was protected by a metallic patellar protector, and then the protected patella was displaced laterally in an upstanding way without eversion. MIS-QS instruments (Zimmer, Warsaw, Indiana, USA) were used for the procedure. Distal femur cut was performed using a medially mounted minimally invasive cutting block in intramedullary way. The femoral rotation was referred to the posterior condylar line and the Whiteside line. The MIS 4 in 1 cutting block and the MIS notch box cutting block were used for the femoral osteotomies. The proximal tibia was cut using an extramedullary alignment guide in a medially mounted way that was perpendicular to the long axis of the tibia with a 7° posterior slope angle. After the extension and flexion gaps were tested, tibia tray prosthesis was cemented and implanted at 90° knee flex without the tibia dislocation. The cemented femoral component was put into position with the knee flexed to 110° to 120° and was hammered into position at 90° of the knee flexion. Then, the knee was kept in full extension, and the ultrahigh molecular polyethylene patellar prosthesis was cemented and implanted. At last, the polyethylene insert was locked into position during knee flexion.

Compared with the MIS-QS procedure, the difference in the conventional procedure were mainly as follow: (1) the skin incision was cut in the center of the front knee with a length of 15–20 cm. (2) The arthrotomy extended into the quadriceps tendon 6–8 cm above the upper pole of the patella. (3) The patella was everted from the beginning of the femoral resection to the prosthesis implantation and the patella resurface was done at last. (4) Distal femoral cutting guide was put upper the distal femur with knee in 90° flexion, and distal femoral resection was conducted in a up and down direction. (5) Proximal tibia resection was performed by putting the standard proximal tibia cutting guide for standard conventional TKA (Zimmer) in front of the proximal tibia with the full tibia anterior dislocation. (6) The tibia tray prosthesis and the polyethylene insert were implanted with the knee flexed to 90° and full tibia anterior dislocation.

All other surgical techniques used in both groups were similar, and the NexGen Legacy Posterior Stabilizing High-Flex prosthesis was used in all surgeries (Zimmer).

Radiological measurements

The HKA angle of the lower limbs and the coronal components alignment were evaluated on full-length weight-bearing radiographs preoperative and postoperative, and the sagittal components alignment were evaluated on lateral radiographs postoperative.

All the measurements (HKA angle; coronal femoral component angle [CFCA]; coronal tibial component angle [CTCA]; sagittal femoral component angle [SFCA]; and sagittal tibial component angle [STCA]) were made by

the same observer according to the suggestion of the knee society,^[4] and the location of all radiolucent lines at the cement-bone interface was also evaluated.

Statistical method

SPSS software (version 18.0; IBM SPSS Statistics for Windows, IBM Corp., Armonk, NY, USA) was used to perform the statistical analysis. Descriptive statistical methods (e.g., mean and standard deviation) were used to evaluate data. The Student's *t*-test was used to determine significant differences between groups. In this study, differences were considered statistically significant when $P < 0.05$.

RESULTS

Five of 35 knees (14%) in the MIS-QS TKA group were lost during the follow-up period. In the conventional group, two patients (2 knees) died, and 5 knees were lost on follow-up (in total, 7 knees [20%] were unavailable for analysis). The average length of the skin incision was 17.2 ± 1.7 cm in the conventional group and 10.0 ± 1.0 cm in the MIS-QS TKA group. Average preoperative HKA was $6.9 \pm 6.8^\circ$ and $7.2 \pm 6.0^\circ$ in the conventional TKA and MIS-QS TKA groups, respectively. There were no statistically significant differences in terms of preoperative HKA.

Average postoperative HKA was $2.8 \pm 2.9^\circ$ and $2.6 \pm 3.9^\circ$ in the conventional and QS groups, respectively. There were no significant differences between the two groups with regard to the postoperative CFCA, CTCA, SFCA, and STCA values. Variations in postoperative HKA are shown in Figure 1.

At final follow-up, two cases (conventional group 1 case and QS group 1 case) had radiolucent lines <1 mm thick in zone 1 of the tibial tray. The two patients were asymptomatic and required no intervention.

DISCUSSION

Accurate lower limb and component alignment are critical for achieving good long-term effects, such as less pain,

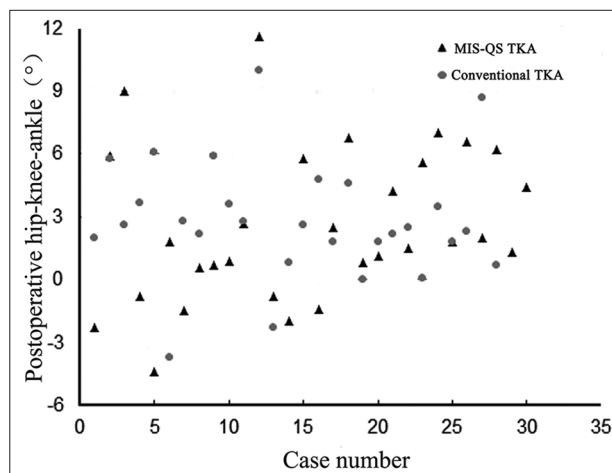


Figure 1: Scatterplot showed the distribution of the postoperative hip-knee-ankle between the conventional and minimally invasive surgery-quadriceps-sparing total knee arthroplasty groups.

quicker rehabilitation, and better functional recovery. Choong *et al.*^[5] reported that patients with coronal alignment within 3° of neutral have superior International Knee Society and short-form 12 scores at 6 weeks, 3 months, 6 months, and 12 months in comparison with patients with alignment >3° after TKA.

An important concern regarding MIS for TKA is possible malpositioning of the postoperative limb and component. First, the MIS-QS technique decreases the operative view field, thereby exposing limited bone landmarks and making it difficult to position instruments. Avoiding lower limb and component malalignment require the prudent examination of the bone landmarks and proper instrument positioning at the cut position. Second, MIS-QS TKA is a new minimally invasive technique, and surgeons need an initial learning period. Alignment improves with the number of cases and experience. This study is limited by its relatively small population, but the results do indicate the need for careful component positioning during MIS. In conclusion, this study did not show any poorer outcomes of the MIS-QS TKA regarding the lower limb and component malalignment when compared with conventional TKA. Given the small sample size and the retrospective nature of the study, it is necessary to perform high-quality study to fully investigate the benefits of the approach.

Financial support and sponsorship

This study was supported by grants from the Sino-Germany

Cooperation Project of the Ministry of Science and Technology of China (No. 2011DFA31340), the Beijing Science and Technology Planning Projects of Beijing Science and Technology Committee (No. Z131100005213004), and the Instrument Research Project of the National Natural Science Foundation (No. 81327001).

Conflicts of interest

There are no conflicts of interest.

REFERENCES

1. Chen AF, Alan RK, Redziniak DE, Tria AJ Jr. Quadriceps sparing total knee replacement. The initial experience with results at two to four years. *J Bone Joint Surg Br* 2006;88:1448-53. doi: 10.1302/0301-620X.88B11.18052.
2. Yu JK, Yu CL, Ao YF, Gong X, Wang YJ, Wang S, *et al.* Comparative study on early period of recovery between minimally invasive surgery total knee arthroplasty and minimally invasive surgery quadriceps-sparing total knee arthroplasty in Chinese patients. *Chin Med J* 2008;121:1353-7.
3. Chiang H, Lee CC, Lin WP, Jiang CC. Comparison of quadriceps-sparing minimally invasive and medial parapatellar total knee arthroplasty: A 2-year follow-up study. *J Formos Med Assoc* 2012;111:698-704. doi: 10.1016/j.jfma.2011.11.025.
4. Ewald FC. The Knee Society total knee arthroplasty roentgenographic evaluation and scoring system. *Clin Orthop Relat Res* 1989;248:9-12. doi: 10.1097/00003086-198911000-00003.
5. Choong PF, Dowsey MM, Stoney JD. Does accurate anatomical alignment result in better function and quality of life? Comparing conventional and computer-assisted total knee arthroplasty. *J Arthroplasty* 2009;24:560-9. doi: 10.1016/j.arth.2008.02.018.