



**Cochrane**  
**Library**

Cochrane Database of Systematic Reviews

## 123I-MIBG scintigraphy and 18F-FDG-PET imaging for diagnosing neuroblastoma (Review)

Bleeker G, Tytgat GAM, Adam JA, Caron HN, Kremer LCM, Hooft L, van Dalen EC

Bleeker G, Tytgat GAM, Adam JA, Caron HN, Kremer LCM, Hooft L, van Dalen EC.  
123I-MIBG scintigraphy and 18F-FDG-PET imaging for diagnosing neuroblastoma.  
*Cochrane Database of Systematic Reviews* 2015, Issue 9. Art. No.: CD009263.  
DOI: [10.1002/14651858.CD009263.pub2](https://doi.org/10.1002/14651858.CD009263.pub2).

[www.cochranelibrary.com](http://www.cochranelibrary.com)

**123I-MIBG scintigraphy and 18F-FDG-PET imaging for diagnosing neuroblastoma (Review)**

Copyright © 2019 The Authors. Cochrane Database of Systematic Reviews published by John Wiley & Sons, Ltd. on behalf of The Cochrane Collaboration.

**WILEY**

## TABLE OF CONTENTS

HEADER .....	1
ABSTRACT .....	1
PLAIN LANGUAGE SUMMARY .....	3
SUMMARY OF FINDINGS .....	4
BACKGROUND .....	6
OBJECTIVES .....	7
Figure 1. ....	8
METHODS .....	9
RESULTS .....	11
Figure 2. ....	12
Figure 3. ....	15
Figure 4. ....	16
Figure 5. ....	18
Figure 6. ....	21
DISCUSSION .....	23
AUTHORS' CONCLUSIONS .....	25
ACKNOWLEDGEMENTS .....	26
REFERENCES .....	27
CHARACTERISTICS OF STUDIES .....	41
ADDITIONAL TABLES .....	115
APPENDICES .....	119
CONTRIBUTIONS OF AUTHORS .....	121
DECLARATIONS OF INTEREST .....	121
SOURCES OF SUPPORT .....	122
DIFFERENCES BETWEEN PROTOCOL AND REVIEW .....	122
INDEX TERMS .....	122

[Diagnostic Test Accuracy Review]

# 123I-MIBG scintigraphy and 18F-FDG-PET imaging for diagnosing neuroblastoma

Gitta Bleeker<sup>1</sup>, Godelieve AM Tytgat<sup>2</sup>, Judit A Adam<sup>3</sup>, Huib N Caron<sup>4a</sup>, Leontien CM Kremer<sup>2</sup>, Lotty Hooft<sup>5</sup>, Elvira C van Dalen<sup>2</sup>

<sup>1</sup>Radiology and Nuclear Medicine, Northwest Clinics, Alkmaar, Netherlands. <sup>2</sup>Princess Máxima Center for Pediatric Oncology, Utrecht, Netherlands. <sup>3</sup>Nuclear Medicine and Radiology, Amsterdam UMC, University of Amsterdam, Amsterdam, Netherlands. <sup>4</sup>iPODD Pediatric Oncology team, Pharma Development Oncology, F. Hoffmann-La Roche AG, Basel, Switzerland. <sup>5</sup>Cochrane Netherlands, Julius Center for Health Sciences and Primary Care, University Medical Center Utrecht, Utrecht University, Utrecht, Netherlands

<sup>a</sup>The author was not employed by F. Hoffmann-La Roche AG until after the work on the review was complete, and will not participate in any updates

**Contact address:** Godelieve AM Tytgat, Princess Máxima Center for Pediatric Oncology, Heidelberglaan 25, Utrecht, 3584 CS, Netherlands. [G.A.M.Tytgat@prinsesmaximacentrum.nl](mailto:G.A.M.Tytgat@prinsesmaximacentrum.nl).

**Editorial group:** Cochrane Childhood Cancer Group.

**Publication status and date:** Edited (no change to conclusions), published in Issue 10, 2019.

**Citation:** Bleeker G, Tytgat GAM, Adam JA, Caron HN, Kremer LCM, Hooft L, van Dalen EC. 123I-MIBG scintigraphy and 18F-FDG-PET imaging for diagnosing neuroblastoma. *Cochrane Database of Systematic Reviews* 2015, Issue 9. Art. No.: CD009263. DOI: [10.1002/14651858.CD009263.pub2](https://doi.org/10.1002/14651858.CD009263.pub2).

Copyright © 2019 The Authors. Cochrane Database of Systematic Reviews published by John Wiley & Sons, Ltd. on behalf of The Cochrane Collaboration. This is an open access article under the terms of the [Creative Commons Attribution-Non-Commercial-No-Derivatives](https://creativecommons.org/licenses/by-nc-nd/4.0/) Licence, which permits use and distribution in any medium, provided the original work is properly cited, the use is non-commercial and no modifications or adaptations are made.

## ABSTRACT

### Background

Neuroblastoma is an embryonic tumour of childhood that originates in the neural crest. It is the second most common extracranial malignant solid tumour of childhood.

Neuroblastoma cells have the unique capacity to accumulate Iodine-123-metaiodobenzylguanidine (<sup>123</sup>I-MIBG), which can be used for imaging the tumour. Moreover, <sup>123</sup>I-MIBG scintigraphy is not only important for the diagnosis of neuroblastoma, but also for staging and localization of skeletal lesions. If these are present, MIBG follow-up scans are used to assess the patient's response to therapy. However, the sensitivity and specificity of <sup>123</sup>I-MIBG scintigraphy to detect neuroblastoma varies according to the literature.

Prognosis, treatment and response to therapy of patients with neuroblastoma are currently based on extension scoring of <sup>123</sup>I-MIBG scans. Due to its clinical use and importance, it is necessary to determine the exact diagnostic accuracy of <sup>123</sup>I-MIBG scintigraphy. In case the tumour is not MIBG avid, fluorine-18-fluorodeoxy-glucose (<sup>18</sup>F-FDG) positron emission tomography (PET) is often used and the diagnostic accuracy of this test should also be assessed.

### Objectives

Primary objectives:

1.1 To determine the diagnostic accuracy of <sup>123</sup>I-MIBG (single photon emission computed tomography (SPECT), with or without computed tomography (CT)) scintigraphy for detecting a neuroblastoma and its metastases at first diagnosis or at recurrence in children from 0 to 18 years old.

1.2 To determine the diagnostic accuracy of negative <sup>123</sup>I-MIBG scintigraphy in combination with <sup>18</sup>F-FDG-PET(-CT) imaging for detecting a neuroblastoma and its metastases at first diagnosis or at recurrence in children from 0 to 18 years old, i.e. an add-on test.

### 123I-MIBG scintigraphy and 18F-FDG-PET imaging for diagnosing neuroblastoma (Review)

Copyright © 2019 The Authors. Cochrane Database of Systematic Reviews published by John Wiley & Sons, Ltd. on behalf of The Cochrane Collaboration.

Secondary objectives:

2.1 To determine the diagnostic accuracy of  $^{18}\text{F}$ -FDG-PET(-CT) imaging for detecting a neuroblastoma and its metastases at first diagnosis or at recurrence in children from 0 to 18 years old.

2.2 To compare the diagnostic accuracy of  $^{123}\text{I}$ -MIBG (SPECT-CT) and  $^{18}\text{F}$ -FDG-PET(-CT) imaging for detecting a neuroblastoma and its metastases at first diagnosis or at recurrence in children from 0 to 18 years old. This was performed within and between included studies.  $^{123}\text{I}$ -MIBG (SPECT-CT) scintigraphy was the comparator test in this case.

### Search methods

We searched the databases of MEDLINE/PubMed (1945 to 11 September 2012) and EMBASE/Ovid (1980 to 11 September 2012) for potentially relevant articles. Also we checked the reference lists of relevant articles and review articles, scanned conference proceedings and searched for unpublished studies by contacting researchers involved in this area.

### Selection criteria

We included studies of a cross-sectional design or cases series of proven neuroblastoma, either retrospective or prospective, if they compared the results of  $^{123}\text{I}$ -MIBG (SPECT-CT) scintigraphy or  $^{18}\text{F}$ -FDG-PET(-CT) imaging, or both, with the reference standards or with each other. Studies had to be primary diagnostic and report on children aged between 0 to 18 years old with a neuroblastoma of any stage at first diagnosis or at recurrence.

### Data collection and analysis

One review author performed the initial screening of identified references. Two review authors independently performed the study selection, extracted data and assessed the methodological quality.

We used data from two-by-two tables, describing at least the number of patients with a true positive test and the number of patients with a false negative test, to calculate the sensitivity, and if possible, the specificity for each included study.

If possible, we generated forest plots showing estimates of sensitivity and specificity together with 95% confidence intervals.

### Main results

Eleven studies met the inclusion criteria. Ten studies reported data on patient level: the scan was positive or negative. One study reported on all single lesions (lesion level). The sensitivity of  $^{123}\text{I}$ -MIBG (SPECT-CT) scintigraphy (objective 1.1), determined in 608 of 621 eligible patients included in the 11 studies, varied from 67% to 100%. One study, that reported on a lesion level, provided data to calculate the specificity: 68% in 115 lesions in 22 patients. The sensitivity of  $^{123}\text{I}$ -MIBG scintigraphy for detecting metastases separately from the primary tumour in patients with all neuroblastoma stages ranged from 79% to 100% in three studies and the specificity ranged from 33% to 89% for two of these studies.

One study reported on the diagnostic accuracy of  $^{18}\text{F}$ -FDG-PET(-CT) imaging (add-on test) in patients with negative  $^{123}\text{I}$ -MIBG scintigraphy (objective 1.2). Two of the 24 eligible patients with proven neuroblastoma had a negative  $^{123}\text{I}$ -MIBG scan and a positive  $^{18}\text{F}$ -FDG-PET(-CT) scan.

The sensitivity of  $^{18}\text{F}$ -FDG-PET(-CT) imaging as a single diagnostic test (objective 2.1) and compared to  $^{123}\text{I}$ -MIBG (SPECT-CT) (objective 2.2) was only reported in one study. The sensitivity of  $^{18}\text{F}$ -FDG-PET(-CT) imaging was 100% versus 92% of  $^{123}\text{I}$ -MIBG (SPECT-CT) scintigraphy. We could not calculate the specificity for both modalities.

### Authors' conclusions

The reported sensitivities of  $^{123}\text{I}$ -MIBG scintigraphy for the detection of neuroblastoma and its metastases ranged from 67 to 100% in patients with histologically proven neuroblastoma.

Only one study in this review reported on false positive findings. It is important to keep in mind that false positive findings can occur. For example, physiological uptake should be ruled out, by using SPECT-CT scans, although more research is needed before definitive conclusions can be made.

As described both in the literature and in this review, in about 10% of the patients with histologically proven neuroblastoma the tumour does not accumulate  $^{123}\text{I}$ -MIBG (false negative results). For these patients, it is advisable to perform an additional test for staging and assess response to therapy. Additional tests might for example be  $^{18}\text{F}$ -FDG-PET(-CT), but to be certain of its clinical value, more evidence is needed.

The diagnostic accuracy of  $^{18}\text{F}$ -FDG-PET(-CT) imaging in case of a negative  $^{123}\text{I}$ -MIBG scintigraphy could not be calculated, because only very limited data were available. Also the detection of the diagnostic accuracy of index test  $^{18}\text{F}$ -FDG-PET(-CT) imaging for detecting a neuroblastoma tumour and its metastases, and to compare this to comparator test  $^{123}\text{I}$ -MIBG (SPECT-CT) scintigraphy, could not be calculated because of the limited available data at time of this search.

### 123I-MIBG scintigraphy and 18F-FDG-PET imaging for diagnosing neuroblastoma (Review)

At the start of this project, we did not expect to find only very limited data on specificity. We now consider it would have been more appropriate to use the term "the sensitivity to assess the presence of neuroblastoma" instead of "diagnostic accuracy" for the objectives.

## PLAIN LANGUAGE SUMMARY

### **<sup>123</sup>I-MIBG- and <sup>18</sup>F-FDG-PET-imaging, two nuclear imaging methods for diagnosing neuroblastoma tumours**

#### **Background and rationale**

Neuroblastoma is a childhood tumour that can be visualized by a specific nuclear imaging compound, called metaiodobenzylguanidine (<sup>123</sup>I-MIBG). <sup>123</sup>I-MIBG-imaging is not only important for the diagnosis of neuroblastoma, but also for localization of metastases (spread of the disease to other organs). Sometimes, the neuroblastoma does not take up <sup>123</sup>I-MIBG and as a result the neuroblastoma is not visible on the scan. In that case, another type of nuclear imaging might be useful to visualize the neuroblastoma: fluoro-deoxy-glucose – positron emission tomography (<sup>18</sup>F-FDG-PET)-imaging.

In the literature the ability to discriminate between neuroblastoma and non-neuroblastoma lesions for these two types of nuclear imaging methods vary.

Prognosis, treatment and response to therapy of patients with neuroblastoma are currently based on scoring the amount of metastases per body segment visible on <sup>123</sup>I-MIBG scans. Therefore, it is important to determine the exact ability to discriminate between neuroblastoma and non-neuroblastoma on <sup>123</sup>I-MIBG-imaging and <sup>18</sup>F-FDG-PET-imaging. We reviewed the evidence about the accuracy of <sup>123</sup>I-MIBG-imaging and <sup>18</sup>F-FDG-PET-imaging for the detection of a neuroblastoma in children suspected of this disease.

#### **Study characteristics**

We searched scientific databases for clinical studies comparing <sup>123</sup>I-MIBG or <sup>18</sup>F-FDG-PET imaging, or both, with microscopic examination of tissue suspected of neuroblastoma (histopathology). The evidence is current up to 11 September 2012.

We identified 11 eligible studies including 621 children that fulfilled our inclusion criteria: children < 18 years old with a neuroblastoma and <sup>123</sup>I-MIBG or <sup>18</sup>F-FDG-PET imaging or both.

All studies included proven neuroblastoma.

#### **Quality of the evidence**

All 11 included studies had methodological limitations. Only one included study provided data on specificity (the ability of a test to correctly classify an individual as 'disease-free') and therefore we could not perform all of the planned analyses.

#### **Key results**

When compared to histopathological results the sensitivity (the ability of a test to correctly classify an individual person as 'diseased') of <sup>123</sup>I-MIBG imaging varied from 67% to 100% in patients with histologically proven neuroblastoma. This means that in 100 children with proven neuroblastoma <sup>123</sup>I-MIBG imaging will correctly identify 67 to 100 of the neuroblastoma cases. Only one study, that reported on a lesion level, provided data to calculate the specificity (the ability of a test to correctly classify an individual as 'disease-free'): 68% in 115 lesions. This means that of 100 disease-free lesions in patients with proven neuroblastoma <sup>123</sup>I-MIBG imaging will correctly identify 68 lesions. So, in about 10% of the cases the neuroblastoma is not visible on <sup>123</sup>I-MIBG imaging (false negative results). For these cases, it is advisable to perform an additional test like <sup>18</sup>F-FDG-PET imaging, but to be certain of its clinical value, more evidence is needed.

Only one included study reported on false positive findings. This means that <sup>123</sup>I-MIBG imaging and <sup>18</sup>F-FDG-PET imaging incorrectly identified neuroblastoma lesions in patients which might result in wrongly classifying a patient with metastatic disease. It is important to keep in mind that false positive findings can occur, although more research is needed before definitive conclusions can be made.

We could not determine the diagnostic accuracy of <sup>18</sup>F-FDG-PET imaging, in case the neuroblastoma was incorrectly not identified with <sup>123</sup>I-MIBG, due to limited data. Also, we could not calculate the diagnostic accuracy of <sup>18</sup>F-FDG-PET imaging for detecting a neuroblastoma and compare this to <sup>123</sup>I-MIBG imaging because of the limited available data.

## SUMMARY OF FINDINGS

### Summary of findings 1. Summary of findings table 1

#### Objective 1.1 <sup>123</sup>I-MIBG scintigraphy for diagnosing a neuroblastoma and its metastases at first diagnosis or at recurrence

**Patients/population:** children from 0 to 18 years old with a suspected neuroblastoma of any stage at first diagnosis or at recurrence.

**Setting:** tertiary care centres of paediatric oncology.

**Index test:** <sup>123</sup>I-MIBG scintigraphy (whole-body(WB), SPECT or SPECT-CT).

**Reference test:** gold standard is histopathology and or bone marrow biopsies/trephine biopsies, but that was not always performed; so also: histopathology during or after treatment (e.g. tissue obtained during surgery), if urinary metabolites were elevated at diagnosis and additional imaging modalities (e.g. ultrasound, CT scan, MRI scan) suggested a neuroblastoma at diagnosis.

**Studies:** primary diagnostic cohort studies (retrospective and prospective), cross-sectional study.

Subgroup	Second covariate	Sensitivity	Specificity	Number of participants (studies) unless otherwise stated
Neuroblastoma at first diagnosis or at recurrence (all stages)	-	Range: 0.67 to 1.00	0.68 <sup>a</sup> (one study)	608 (11 studies)
Metastases (osteomedullary and soft tissue)	-	Range: 0.79 to 1.00	Range: 0.33 to 0.89 (two studies, 45 patients)	72 (3 studies)
Stage 1 and 2	-	Range: 0.60 to 0.76	b	43 (2 studies)
Stage 3	-	Range: 0.00 to 1.00	b	54 (3 studies)
Stage 4	-	Range: 0.80 to 1.00	b	344 (4 studies)
Stage 4	Osteomedullary metastases	Range: 0.79 to 0.90	Range: 0.40 to 0.67	37 (2 studies)
Stage 4S	-	1.00	b	13 (1 study)

<sup>a</sup>As only one study, [Pfluger 2003](#), reported on diseases other than neuroblastoma, the specificity could be calculated for only this one study. This should be kept in mind. This study is the only one reporting at lesion level instead of patient level.

<sup>b</sup>None of the included studies that distinguished stages of neuroblastoma reported on diseases other than neuroblastoma. Therefore, the specificity could not be calculated for any of these studies.

## Summary of findings 2. Summary of findings table 2

### Objective 2.1 Diagnostic accuracy of <sup>18</sup>F-FDG-PET(-CT) imaging for detecting a neuroblastoma and its metastases at first diagnosis or at recurrence

**Patients/population:** children from 0 to 18 years old with a neuroblastoma of any stage at first diagnosis or at recurrence.

**Setting:** tertiary care centres of paediatric oncology.

**Index test:** <sup>18</sup>F-FDG-PET(-CT) imaging.

**Reference test:** gold standard is histopathology and or bone marrow biopsies/trephine biopsies, but that was not always performed; so also: histopathology during or after treatment (e.g. tissue obtained during surgery), if urinary metabolites were elevated at diagnosis and additional imaging modalities (e.g. ultrasound, CT scan, MRI scan) suggested a neuroblastoma at diagnosis.

**Studies:** retrospective cohort study

Subgroup	Second covariate	Sensitivity	Specificity	Number of participants (studies)
Neuroblastoma (all stages) at first diagnosis	—	1.00	<i>a</i>	24 (1 study)
Stage 1 and 2	—	1.00	<i>a</i>	5 (1 study)
Stage 3	—	1.00	<i>a</i>	3 (1 study)
Stage 4	—	1.00	<i>a</i>	16 (1 study)

<sup>a</sup>Only one study reported on the diagnostic accuracy of <sup>18</sup>F-FDG-PET(-CT) imaging for detecting a neuroblastoma tumour and its metastases at first diagnosis or at recurrence in children from 0 to 18 years old (Sharp 2009a). As all patients had already proven neuroblastoma, true negative findings did not occur in this study and therefore specificity could not be analysed. The study did not demonstrate false negative findings at diagnosis, which suggests that patients might be selected based on uptake on their scan.

## BACKGROUND

### Target condition being diagnosed

Neuroblastoma is an embryonic tumour of childhood that originates in the neural crest. It is the second most common extracranial malignant solid tumour of childhood and the most common solid tumour of infancy (Brodeur 2003; Castleberry 1997; Park 2008). It accounts for 7% of all childhood cancers and for approximately 15% of cancer deaths in children (Castleberry 1997; Maris 2007; Park 2008; Spix 2006). A neuroblastoma might arise anywhere along the sympathetic nervous system (side chain), but is found most frequently in the abdomen (65%). Half of the neuroblastomas arise from the adrenal glands. Other common sites are the neck, chest and pelvis (Maris 2007; Maris 2010; Park 2008). They particularly occur in children at a young age, with a median age at diagnosis of 17 months (Maris 2010). Around 50% of patients present with disseminated disease at the time of diagnosis (Maris 2007; Maris 2010). Dissemination occurs through lymphatic and hematogenous routes, with involvement of bone, bone marrow and liver (Maris 2007; Maris 2010).

Neuroblastoma is staged according to the International Neuroblastoma Staging System (INSS) (Table 1) (Brodeur 1988b; Brodeur 1993). Stage 1 or 2 neuroblastoma is localised, stage 3 neuroblastoma consists of regional disease and stage 4 neuroblastoma is marked by distant metastases. A unique pattern of dissemination, limited to the liver, skin and less than 10% of bone marrow in children younger than one year old is defined as stage 4S, which has a potential for spontaneous regression (Brodeur 1988b; Brodeur 1993). The INSS system is a postsurgical staging system and therefore the International Neuroblastoma Risk Group (INRG) published a new clinical staging system in 2008: the INRG classification system (Table 2) (Monclair 2009).

The clinical course in patients with a neuroblastoma varies enormously, ranging from spontaneous regression to rapid and fatal tumour progression despite extensive treatment (Brodeur 2003; Castleberry 1997; Park 2008). Known predictors of poor prognosis are stage, age at diagnosis and chromosomal aberrations, such as MYCN (myc myelocytomatosis viral related oncogene, neuroblastoma derived) amplification and chromosomal loss of 1p36 (Brodeur 1984; Brodeur 1988a; Brodeur 1988b; Brodeur 1993; Cohn 2009).

Children with metastatic disease are quite ill at presentation. As the tumour disseminates to the bone, patients often present with bone pain, limping or both. Metastasis in the orbits can cause periorbital ecchymoses (raccoon eyes), sometimes accompanied by proptosis, caused by metastases in the bony orbit. Another symptom is abdominal distension caused by a large tumour. Paraspinal tumours may cause myelom compression, resulting in neurological symptoms, such as motor weakness, pain and sensory loss, which can be medical emergencies (Maris 2010; Park 2008).

The treatment of neuroblastoma patients generally consists of induction chemotherapy, surgery, myeloablative chemotherapy with stem cell rescue, radiotherapy or <sup>131</sup>Iodide-metaiodobenzylguanidine (<sup>131</sup>I-MIBG) therapy or both (Maris 2007; Maris 2010; Park 2008; Yalçın 2010; Yalçın 2013).

### Index test(s)

In this Cochrane review we assessed the diagnostic use of Iodine-123-metaiodobenzylguanidine (<sup>123</sup>I-MIBG) scintigraphy and fluorine-18-fluorodeoxy-glucose (<sup>18</sup>F-FDG) positron emission tomography (PET) in the detection of a neuroblastoma and its metastases at first diagnosis or at recurrence. <sup>123</sup>I-MIBG scintigraphy can be performed as a two-dimensional whole-body (WB) scan or a three-dimensional single photon emission computed tomography (SPECT) scan, with or without computed tomography (CT) for localisation of neuroblastoma lesions.

MIBG, a compound that is a structural analogue of the neurotransmitter norepinephrine, is actively taken up in neuroendocrine cells via the norepinephrine transporter (NET) and is stored in the neurosecretory granules, resulting in a specific concentration in the tumour in contrast to cells of other tissue (Taggart 2008; Vaidyanathan 2008). Once labelled with radioactive iodine (<sup>123</sup>I or <sup>131</sup>I), MIBG scintigraphy can be used for imaging of tumours of neuroendocrine origin, such as neuroblastoma, paraganglioma and pheochromocytoma (Boubaker 2008; Taggart 2008; Vaidyanathan 2008). In the past, both <sup>123</sup>I-MIBG and <sup>131</sup>I-MIBG were used for diagnostic purposes. However, <sup>123</sup>I-MIBG is considered first choice for imaging because it has a more favourable dosimetry and it was assumed that it provided a better image quality than <sup>131</sup>I-MIBG (Bombardieri 2003c; Boubaker 2008; Taggart 2008). Consequently, <sup>123</sup>I-MIBG is mainly used for diagnostic purposes in international protocols.

<sup>123</sup>I-MIBG WB or static scans visualise the primary tumour and its metastases two-dimensional. SPECT enables three-dimensional imaging of the primary tumour. However, in practice this imaging modality cannot replace WB imaging, because SPECT often does not fully visualise the whole body, but only a selected part of the body (Rufini 1996). MIBG-SPECT can be combined with CT to determine the exact localisation of the primary tumour and its relation to other organ structures (Rufini 1996; Taggart 2008).

Physiological distribution of <sup>123</sup>I-MIBG can be found in structures that excrete catecholamines, such as the bladder, urinary tract and gastrointestinal system. MIBG usually accumulates in the liver, myocardium, salivary glands and thyroid, and less frequently in the spleen, lungs, brown adipose tissue and skeletal muscles. It is essential to recognise this normal distribution to avoid false positive interpretation of MIBG scans (Bombardieri 2003c; Boubaker 2008).

Many drugs can interfere with the uptake or vesicular storage of <sup>123</sup>I-MIBG (or both) (Table 3; Bombardieri 2003c). Therefore, it is important to stop these medications before the procedure to prevent negative results of <sup>123</sup>I-MIBG scans. In cases of severe hypertension, antihypertensive medication is necessary and cannot be stopped. Consequently, the <sup>123</sup>I-MIBG scan may not be reliable, if the patient is treated with an antihypertensive agent that interferes with <sup>123</sup>I-MIBG. On the other hand, <sup>123</sup>I-MIBG scan test results can be negative because of low expression of the norepinephrine transporter (NET) (Boubaker 2008; Taggart 2008). Therefore, it is important to perform an additional test in case of a negative <sup>123</sup>I-MIBG scan.

Another imaging modality to diagnose neuroblastoma is PET(-CT) imaging, which uses the glucose metabolism to visualise the primary tumour and metastases with <sup>18</sup>F-FDG. In contrast to normal



cells, cancer cells avidly take up glucose and metabolise it to lactate even when oxygen is abundantly present. This glucose metabolism in cancer cells enables specific detection by PET with the glucose analogue FDG. Although in contrast to  $^{123}\text{I}$ -MIBG imaging,  $^{18}\text{F}$ -FDG PET(-CT) imaging is not specific for neuroblastoma tumours, it may be a useful additional imaging modality for diagnosing neuroblastoma (Bombardieri 2003b; Murphy 2008; Shore 2008). This imaging modality might have additional value in patients with (false) negative  $^{123}\text{I}$ -MIBG scans. In this case  $^{123}\text{I}$ -MIBG would be the comparator test.

### Alternative test(s)

The diagnosis neuroblastoma is being made using several tests. All patients suspected of neuroblastoma have a diagnostic work-up consisting of: clinical examination, testing of excretion of catecholamines in the urine, imaging of the tumour and its metastases and histopathological investigation of the tumour.

Excretion of catecholamines in the urine is a non-invasive test and it is used as a first screening in patients suspected of having a neuroblastoma. Increased excretion of urinary catecholamines indicates the presence of a neuroblastoma, but this test is not positive in all neuroblastoma patients (Strenger 2007).

Tumour biopsy (histopathology) is the gold standard. It is done not only to confirm the diagnosis, but also to investigate the histology of the neuroblastoma, the differentiation of the tumour and genetic abnormalities, which are all correlated with prognosis and play a role in staging the disease.

However, sometimes it is not feasible to perform this test (e.g. if the patient is seriously ill or if such a procedure can be life- or organ-threatening because of tumour localisation). In that case, a combination of tests, MIBG scintigraphy, testing of excretion of catecholamines in the urine and imaging of the tumour, is considered second best.

For detecting metastases, histopathology is not the optimal test. It is not feasible to confirm every metastatic lesion histologically, so other tests such as MIBG scintigraphy, MRI or CT, or both MRI and CT are needed.

Because MIBG scintigraphy is a functional imaging technique, actual measures of the primary tumour (and metastases) and close

relationship with other organs and structures (vessels) cannot be made.

Next to  $^{123}\text{I}$ -MIBG scintigraphy, other imaging methods, such as ultrasound, CT-scan or MRI-imaging, of the primary tumour are performed to measure the size of the tumour (three-dimensional) and its relation to other organs and structures in order to estimate risks of surgery. However, these imaging modalities are also not specific for neuroblastoma (Kaste 2008b).

As all these tests have their own added value to either the diagnosis or therapy decisions, they are all being used side-by-side in patients with a suspected neuroblastoma.

### Rationale

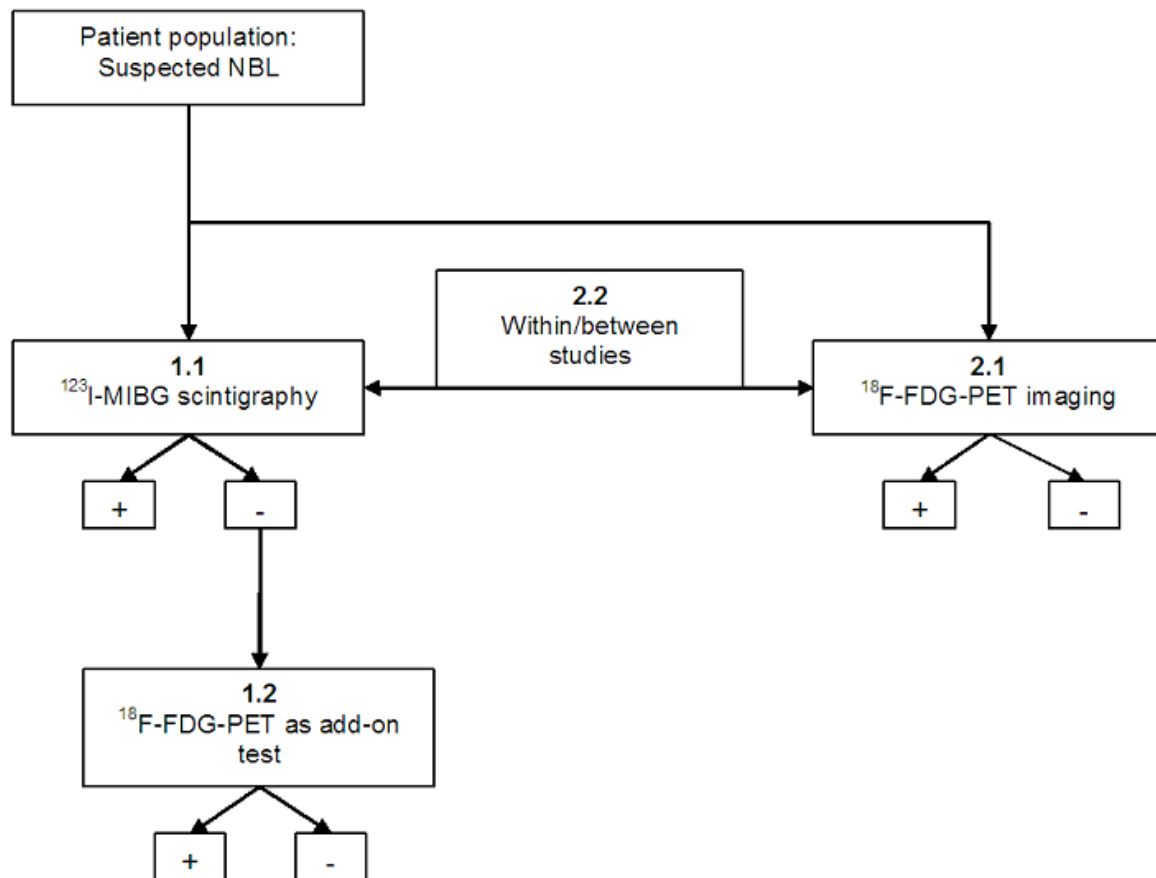
In clinical practice,  $^{123}\text{I}$ -MIBG and  $^{18}\text{F}$ -FDG-PET scintigraphy are performed if a neuroblastoma is strongly suspected and other tests, such as urinary catecholamines, are positive and suggestive for a neuroblastoma. Moreover,  $^{123}\text{I}$ -MIBG scintigraphy is not only important for the diagnosis of neuroblastoma, but also for staging and localisation of skeletal lesions. If these are present, MIBG follow-up scans are performed to assess response to therapy. In case of a MIBG-negative neuroblastoma, it is difficult to assess response to therapy, so the patients are being submitted to e.g.  $^{18}\text{F}$ -FDG-PET(-CT) scans and other imaging techniques, for which the diagnostic accuracy is not yet well established.

Prognosis, treatment and response to therapy of patients with neuroblastoma are currently based on extension scoring of  $^{123}\text{I}$ -MIBG scans (Decarolis 2013; Matthay 2010; Naranjo 2011; Yanik 2013). Therefore, it is important to have a good overview of the sensitivity and specificity of this diagnostic test. In this Cochrane diagnostic test accuracy (DTA) review we also evaluated the diagnostic accuracy of  $^{18}\text{F}$ -FDG-PET(-CT) as an add-on test in children with suspected neuroblastoma, as well as the diagnostic accuracy of this test as a single diagnostic test and compared with the diagnostic accuracy of  $^{123}\text{I}$ -MIBG (SPECT-CT) scintigraphy.

### OBJECTIVES

We reviewed three index test combinations: 1.  $^{123}\text{I}$ -MIBG scintigraphy, 2.  $^{18}\text{F}$ -FDG-PET(-CT), and 3.  $^{123}\text{I}$ -MIBG scintigraphy plus  $^{18}\text{F}$ -FDG-PET(-CT). See [Figure 1](#): flowchart of index tests.

**Figure 1. Flow chart index tests in patients with suspected neuroblastoma.**



**Clarification:**

- NBL: neuroblastoma.
- +: positive test result.
- : negative test result.
- 1.1: primary objective 1.
- 1.2: primary objective 2.
- 2.1: secondary objective 1.
- 2.2: secondary objective 2.

**Primary objective**

1.1 To determine the diagnostic accuracy of <sup>123</sup>I-MIBG (SPECT-CT) scintigraphy for detecting a neuroblastoma and its metastases at first diagnosis or at recurrence in children from 0 to 18 years old.

1.2 To determine the diagnostic accuracy of negative <sup>123</sup>I-MIBG scintigraphy in combination with <sup>18</sup>F-FDG-PET(-CT) imaging for detecting a neuroblastoma and its metastases at first diagnosis or at recurrence in children from 0 to 18 years old. In this case <sup>18</sup>F-FDG-PET(-CT) is an add-on test.

**Secondary objectives**

2.1 To determine the diagnostic accuracy of <sup>18</sup>F-FDG-PET(-CT) imaging for detecting a neuroblastoma and its metastases at first diagnosis or at recurrence in children from 0 to 18 years old.

2.2 To compare the diagnostic accuracy of <sup>123</sup>I-MIBG (SPECT-CT) scintigraphy and of <sup>18</sup>F-FDG-PET(-CT) imaging for detecting a neuroblastoma and its metastases at first diagnosis or at recurrence in children from 0 to 18 years old. This was performed within and between (objective 1.1 compared to objective 2.1) included studies. <sup>123</sup>I-MIBG (SPECT-CT) scintigraphy was the comparator test in this case.

**Investigation of sources of heterogeneity**

When assessing study results, we considered methodological and clinical sources of heterogeneity as well as variation in the criteria used to define a positive test result. Several factors may contribute to heterogeneity in diagnostic performance across studies. We investigated, where possible, the potential influence of differences in the following items:

#### Study population:

- Newly diagnosed versus recurrent neuroblastoma.
- Stage of disease (1 to 4 and 4S) as an ordinal variable. We reported stage 1 and 2 combined and stage 3, 4 and 4S separately.

#### Index test radio labelled MIBG (SPECT-CT) scintigraphy:

- Time span between injection and scanning (24 or 48 hours) (acquisition time).
- WB scan versus SPECT-CT.
- Interfering medication (Table 3).

#### Reference standard:

- Type of test: histopathology (reference test 1) versus bone marrow aspirate or trephine biopsy (reference test 2) versus histopathology in combination with excretion of catecholamines in the urine and additional imaging modalities (reference test 3).

## METHODS

### Criteria for considering studies for this review

#### Types of studies

We included primary diagnostic studies if they compared the results of  $^{123}\text{I}$ -MIBG (SPECT-CT) scintigraphy,  $^{18}\text{F}$ -FDG-PET(-CT) imaging, or both, with the tests described as reference standards (as defined below) and if they compared the results of both tests with each other. Studies needed to be of a cross-sectional design or a case series of proven neuroblastoma. Patient selection could be either retrospective or prospective. We excluded case reports, studies that described fewer than ten patients suspected for neuroblastoma and diagnostic case-control studies.

Studies had to report sufficient data to construct (part of) a two-by-two table, i.e. at least the absolute number of true positives and false negatives had to be available from the data reported in the primary studies or obtainable from the study authors to calculate the sensitivity and if possible the specificity.  $^{123}\text{I}$ -MIBG scintigraphy is only performed when there is a high suspicion of a neuroblastoma based on clinical information, excretion of catecholamines in the urine and different imaging methods. Therefore, it is expected that mainly the outcome of MIBG scans in patients with finally proven neuroblastoma will be reported and that thus often only sensitivity can be analysed.

#### Participants

Children from 0 to 18 years old with suspected neuroblastoma and its metastases of any stage at first diagnosis or at recurrence in a tertiary care centre of paediatric oncology. We excluded studies on animals, studies not performed in children with suspected neuroblastoma, studies performed in children with esthesioneuroblastoma and olfactory neuroblastoma, and studies on the therapeutic use of MIBG.

#### Index tests

- $^{123}\text{I}$ -MIBG scintigraphy (WB, SPECT or SPECT-CT) of a neuroblastoma and its metastases at first diagnosis or at recurrence.

- $^{18}\text{F}$ -FDG-PET(-CT) scans of a neuroblastoma and its metastases at first diagnosis or at recurrence.
- $^{123}\text{I}$ -MIBG scintigraphy plus  $^{18}\text{F}$ -FDG-PET(-CT).

#### Comparator tests

When  $^{18}\text{F}$ -FDG-PET(-CT) imaging was the index test:

- $^{123}\text{I}$ -MIBG scintigraphy (WB, SPECT or SPECT-CT) of a neuroblastoma and its metastases at first diagnosis or at recurrence.

#### Target conditions

Neuroblastoma at first diagnosis or at recurrence.

#### Reference standards

The optimal combination of reference tests is described below. However, we did not exclude studies that did not use the optimal combination of reference tests.

The reference tests for the diagnosis of the primary neuroblastoma tumour were as follows:

1. An unequivocal pathological diagnosis according to the Shimada classification or the International Neuroblastoma Pathology Classification (INPC) (Brodeur 1984; Joshi 2000; Peuchmaur 2003; Shimada 1984; Shimada 1993; Shimada 1999a; Shimada 1999b; Shimada 2003). Tumour tissue was examined by use of light or electron microscopy with immunohistochemistry. At least two of the following antigens had to be positive: neuron-specific enolase (NSE), synaptophysin or chromogranin A (CGA). Tissue had to be preferably obtained by the use of Trucut, core-needle biopsy. However, if this approach was contra-indicated, fine-needle aspiration could be used (Brodeur 1993).
2. A bone marrow aspirate or trephine biopsy containing unequivocal tumour cells. These are immunocytologically positive clumps of cells, containing antibodies against at least two of the following antigens: NSE, synaptophysin or CGA (Brodeur 1993).
3. Histopathology during or after treatment (e.g. tissue obtained during surgery), if excretion of catecholamines in the urine was elevated at diagnosis and additional imaging modalities (e.g. ultrasound, CT scan, MRI scan) suggested a neuroblastoma at diagnosis.

Three different tests were used as possible reference standards. If only one of the three reference standards had a positive result, the diagnosis neuroblastoma could be confirmed. However, to reject the diagnosis neuroblastoma all three had to give a negative result.

The reference tests for the diagnosis of neuroblastoma metastases (separately from the primary tumour) were as follows:

- Bone marrow metastases: To determine bone marrow invasion, at least two different puncture sites were mandatory (although four puncture sites should always be aimed for). Representative smears (five smears from each puncture site) and EDTA/heparin bone marrow (3 to 5 mL from each puncture site) had to be sampled for PCR or immunocytology, or both. Only if no fluid bone marrow in sufficient quality or quantity could be aspirated,

trephine biopsies from this puncture site are recommended (Beiske 2009).

- Bone metastases: Positive lesions on a <sup>99m</sup>Tc skeleton scintigraphy, MRI, CT scan, or a combination of these tests.
- Lymph node metastases: Histologically proven palpable nodes or ultrasound, MRI or CT scan for non-palpable nodes, or both.
- Liver metastases: Ultrasound, MRI, CT scan or a combination of these tests.

Diagnosis of neuroblastoma metastases resulted from at least one positive result of these reference tests. The result for the metastases was assumed negative if all reference tests were negative.

There are no inadequate reference standards in the diagnostic process of neuroblastoma. Histopathology is the gold standard, but it is not always possible to perform. Therefore other reference tests, when combined, are also needed in the diagnosis of neuroblastoma.

## Search methods for identification of studies

### Electronic searches

We searched the databases of MEDLINE/PubMed (from 1945 to 11 September 2012) and EMBASE/Ovid (from 1980 to 11 September 2012). The search strategies for the different electronic databases (using a combination of controlled vocabulary and text words) are presented in [Appendix 1](#) and [Appendix 2](#).

We did not impose language restrictions.

### Searching other resources

We located information about studies not registered in MEDLINE and EMBASE, either published or unpublished, by screening the reference lists of relevant articles and review articles. We also scanned the conference proceedings of the International Society for Paediatric Oncology (SIOP), the American Society of Clinical Oncology (ASCO), Advances in Neuroblastoma Research (ANR) and the Society of Nuclear Medicine (SNM) from 2006 to 2012. If studies were reported in abstracts or conference proceedings we searched for full publications. We checked for unpublished studies by contacting researchers involved in this area.

## Data collection and analysis

### Selection of studies

After employing the search strategy described previously, one review author performed the initial screening of identified references, excluding studies on animals, studies not performed in children with suspected neuroblastoma, studies performed in children with esthesioneuroblastoma and olfactory neuroblastoma, studies on the therapeutic use of MIBG, case reports and studies that described fewer than ten patients that were suspected of neuroblastoma. Next, two review authors independently identified studies from the remaining references that seemed to meet the inclusion criteria based on title, abstract, or both and screened these full-text studies. Only full-text studies that fulfilled all inclusion criteria for this review were eligible for inclusion. We clearly stated reasons for exclusion of any study considered for the review.

Both initial and definite selection needed consensus of both review authors. In case of disagreement, a third-party arbitrator achieved final resolution.

### Data extraction and management

Two review authors performed data extraction independently using standardised forms. Data were extracted either on patient or on lesion level when possible. We extracted data on the following items:

- Article: author, year of publication, journal.
- Study population: age, sex, neuroblastoma at first diagnosis or at recurrence, stage, inclusion and exclusion criteria, number of subjects (including number eligible for the study, number enrolled in the study, number subjected to the index test and reference standard, number for whom results were reported in the two-by-two-table, reasons for withdrawal).
- Index tests: <sup>123</sup>I-MIBG scintigraphy, <sup>18</sup>F-FDG-PET(-CT) imaging, or both.
- Comparator test: <sup>123</sup>I-MIBG scintigraphy, if <sup>18</sup>F-FDG-PET(-CT) imaging was the index test.
- Interfering medication in case of <sup>123</sup>I-MIBG scintigraphy ([Table 3](#)).
- Reference test: type of test.
- Study methods: basic design of the study (prospective cohort or historical cohort with data collection based on medical records or case-control study), time span between index test and reference test, treatment between index test and reference test.
- Data for the two-by-two table: true positive, false positive, true negative and false negative rates or, if not available, relevant parameters (sensitivity, specificity or predictive values) to reconstruct the two-by-two table.

To test whether the data extraction form worked well, two review authors piloted this form for two studies ([Hashimoto 2003](#); [Piccardo 2012](#)). There was a high concordance between the review authors, so we concluded that the form could be used for all included studies.

When data were missing in a published report, we attempted to contact the study authors for the missing information. In cases of disagreement, we re-examined the abstracts and articles and undertook discussion until we achieved consensus. If this was not possible, we achieved final resolution using a third-party arbitrator.

### Assessment of methodological quality

Two review authors independently assessed the methodological quality of each included study using the Quality Assessment of Diagnostic Accuracy Studies (QUADAS) items ([Table 4](#)) developed by the NHS Centre for Reviews and Dissemination at the University of York, UK ([Whiting 2003](#)). We scored each item as either 'yes', 'no' or 'unclear'. The QUADAS tool items and our scoring interpretations for each item are presented in [Table 4](#). We resolved discrepancies between review authors by consensus. If this was not possible, we sought final resolution using a third-party arbitrator. We did not calculate a summary score estimating the overall quality of an article since the interpretation of such summary scores is problematic and potentially misleading ([Jüni 1999](#); [Whiting 2003](#)). We presented results in the text, in a graph and in a table.

To test whether the QUADAS form worked well, two review authors piloted this form for three studies (Hashimoto 2003; Piccardo 2012; Sharp 2009a). There was a high concordance between the review authors, so we concluded that the form could be used for all included studies.

### Statistical analysis and data synthesis

For the diagnosis of neuroblastoma, we planned to perform a random-effects meta-analysis of sensitivity of all included studies. The logit transformed value of sensitivity was to be meta-analyzed using a random-effects model to estimate the amount of between-study variance across studies and the "exact" binomial distribution was to be used to account for the within-study variance of each study (i.e. the precision by which sensitivity has been measured). We planned to perform these analyses in SAS 9.1 (SAS 9.1 2004) using the non-linear mixed effect module (PROC NLMIXED). However, these analyses were not possible because only one study provided data on false positive results.

We aimed to extract from each included study the two-by-two tables (consisting of at least true positives and false negatives) to calculate the sensitivity and, if possible, the specificity. We generated a paired forest plot showing estimates of sensitivity and specificity. The forest plot provides a visual impression of the precision by which sensitivity and specificity have been measured in each study, as well as an indication of the amount of variability in these parameters across studies. We did not plot pairs of sensitivity and specificity from each study in receiver operating characteristic (ROC), because only one study provided data to calculate specificity for diagnosing neuroblastoma in general and only three studies provided data on both sensitivity and specificity for diagnosing metastases.

In the analyses we differentiated between lesions detected in several regions when possible.

### Investigations of heterogeneity

First, we investigated heterogeneity through visual inspection of the forest plots. We planned to more formally examine the effects of covariates on sensitivity, specificity, or both in the bivariate model, if sufficient data in the individual studies were available (data in at least four studies for each level of a covariate) to investigate heterogeneity. However, this was not possible.

### Sensitivity analyses

To assess whether methodological quality influenced the results we planned to perform sensitivity analyses for the following

individual quality items of QUADAS (Table 4). However, due to limited information on these items in these studies and a lack of discrimination within these items, it was not possible to do this.

- Item 1: different stages of the disease and newly diagnosed versus recurrent neuroblastoma may result in different groups.
- Item 4: partial verification bias.
- Item 5: differential verification bias.
- Item 11: withdrawals from the study may differ systematically from those who remain.
- Item 13: the execution of the index test may differ between clinical centres and may consequently lead to various results, e.g. the index test can be performed with different techniques, time of scanning after infusion (4h, 12h, 24h) or with different equipments. These differences might give different test results.

## RESULTS

### Results of the search

The electronic database searches yielded a total of 4693 references. We excluded 3204 references after initial screening of titles for the following reasons: studies described fewer than ten patients, were case reports, studies on animals, studies not performed in children with suspected neuroblastoma, studies performed in children with esthesioneuroblastoma and olfactory neuroblastoma or studies on the therapeutic use of MIBG (see Figure 2). After screening of titles and abstracts of the 1489 remaining references, we identified 246 studies that were assessed in full-text; we excluded 1243 studies because they did not meet the inclusion criteria (i.e. studies reporting fewer than ten patients, case reports, studies on animals, studies not performed in children with suspected neuroblastoma, studies performed in children with esthesioneuroblastoma and olfactory neuroblastoma, studies on the therapeutic use of MIBG and duplicate studies). Of the 246 full-text studies, 11 studies fulfilled the inclusion criteria (see the Characteristics of included studies table). For 24 studies we need additional information to assess whether they could be included and these are awaiting further assessment (see the Characteristics of studies awaiting classification table). Three studies were not in English and are yet to be translated (see the Characteristics of studies awaiting classification table). Six studies appeared to be conference proceedings that were not published as full-text yet and are awaiting further assessment (see the Characteristics of studies awaiting classification table). We excluded a total of 202 studies after assessing the full-text study for reasons described in the Excluded studies table.

**Figure 2. Flow diagram: Inclusion process.**

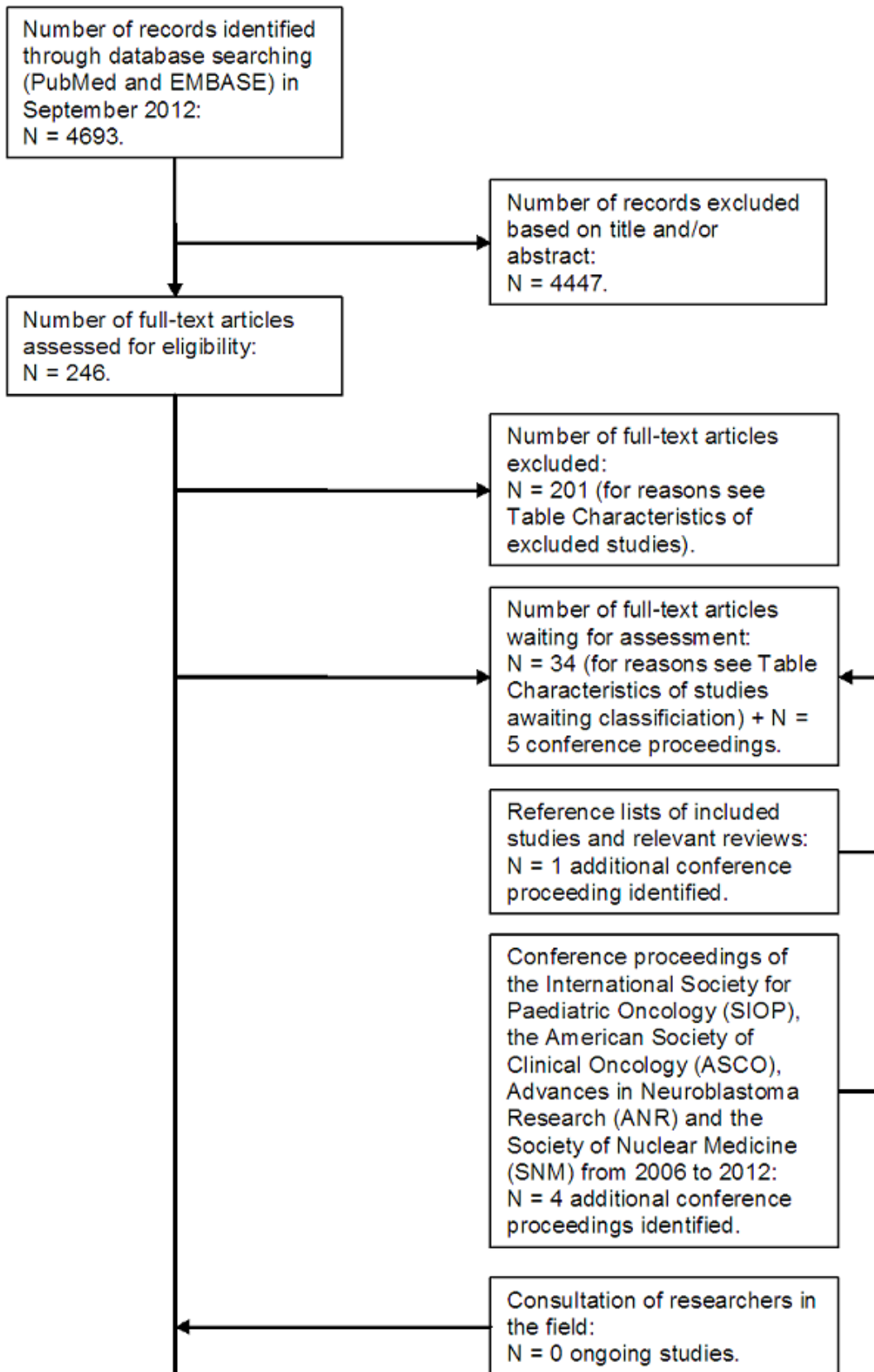


Figure 2. (Continued)



Additionally, we identified one conference proceeding after scanning the reference lists of relevant articles and reviews (see the [Characteristics of studies awaiting classification](#) table). Consultation of researchers in the field did not identify any ongoing studies. After scanning the conference proceedings of SIOP, ANR and SNM, we found four additional conference proceedings that have not been published as full-text yet and are awaiting further assessment (see the [Characteristics of studies awaiting classification](#) table). We did not identify any relevant conference proceedings after scanning the conference proceedings of ASCO.

### Included studies

We have summarised the characteristics of the included studies below. For more detailed information see the [Characteristics of included studies](#) table.

In total, the 11 studies included 844 participants. In this Cochrane DTA review we report only on 621 eligible patients that fulfilled the inclusion criteria for this review. We excluded patients from four studies that included both diagnostic and follow-up scans ([Gordon 1990](#); [Neuenschwander 1987](#); [Pfluger 2003](#); [Sharp 2009a](#)), from one study that included both  $^{123}\text{I}$ - and  $^{131}\text{I}$ -MIBG scans ([Naranjo 2011a](#)), from one study that included two adults ([Piccardo 2012](#)) and from one study that reported on neuroblastoma patients with and without MIBG scintigraphy ([Hugosson 1999](#)).

Five studies did not report on the median age of eligible patients for this review ([Gordon 1990](#); [Hugosson 1999](#); [Neuenschwander 1987](#); [Pfluger 2003](#); [Sharp 2009a](#)). Four studies reported an age range from 0 to 15.2 years ([Biasotti 2000](#); [Hashimoto 2003](#); [Naranjo 2011a](#); [Piccardo 2012](#)). One study reported a median age of four years ([Ivanova 2008](#)) and one a median of 0.4 years ([Labreuve de Cervens 1994](#)).

The sex distribution was often not reported for the 621 eligible patients separately from the other patients in the studies. Six studies did not report on the sex distribution of eligible patients for this review ([Biasotti 2000](#); [Gordon 1990](#); [Hugosson 1999](#); [Neuenschwander 1987](#); [Pfluger 2003](#); [Sharp 2009a](#)) and five studies did: [Hashimoto 2003](#) reported 20 boys (61%) and 13 girls (39%); [Labreuve de Cervens 1994](#) reported 10 boys (37%) and 17 girls (63%); [Ivanova 2008](#) reported 14 boys (64%) and eight girls (36%); [Naranjo 2011a](#) reported 124 boys (57%) and 94 girls (43%); and [Piccardo 2012](#) reported four boys (24%) and 13 girls (76%).

The INSS stage distribution was also frequently not reported separately for the 621 eligible patients from the other patients in the studies. Five studies did not report on the INSS stage distribution of patients eligible for this review ([Hugosson 1999](#); [Labreuve de Cervens 1994](#); [Ivanova 2008](#); [Neuenschwander 1987](#); [Pfluger 2003](#)). Two studies reported on patients with stage 1, 2, 3 and 4 neuroblastoma ([Gordon 1990](#); [Sharp 2009a](#)); two reported on patients with stage 1, 2, 3, 4 and 4S neuroblastoma ([Biasotti 2000](#); [Hashimoto 2003](#)); one reported on patients with stage 3 and 4 neuroblastoma ([Piccardo 2012](#)); and one reported on patients with stage 4 neuroblastoma only ([Naranjo 2011a](#)). Three of these studies ([Hashimoto 2003](#); [Naranjo 2011a](#); [Piccardo 2012](#)) reported the exact number per INSS stage: 16 patients with stage 1, five with stage 2, six with stage 3, 239 patients with stage 4 and two patients with stage 4S neuroblastoma.

Four studies were retrospective cohort studies ([Hashimoto 2003](#); [Labreuve de Cervens 1994](#); [Pfluger 2003](#); [Sharp 2009a](#)), two were prospective cohort studies ([Naranjo 2011a](#); [Piccardo 2012](#)), one was a retrospective cross-sectional study ([Ivanova 2008](#)) and of four the type of study was not reported ([Biasotti 2000](#); [Gordon 1990](#); [Hugosson 1999](#); [Neuenschwander 1987](#)).

The diagnosis neuroblastoma was confirmed by histopathology in all 11 studies. In three studies both histopathology and bone marrow biopsies were used for the diagnosis neuroblastoma ([Hugosson 1999](#); [Naranjo 2011a](#); [Sharp 2009a](#)). In one study 11 patients had bone marrow biopsies and contrast-enhanced CT or MRI, one patient had histopathology of the primary tumour and contrast-enhanced CT or MRI, and five patients had histopathology of the primary tumour, bone marrow biopsies and contrast-enhanced CT or MRI ([Piccardo 2012](#)). To evaluate metastatic disease on  $^{123}\text{I}$ -MIBG scans, bone marrow biopsies were used as gold standard in three studies ([Gordon 1990](#); [Hashimoto 2003](#); [Piccardo 2012](#)). One study reported on a lesion level and used histologic verification as a reference standard for most lesions ([Pfluger 2003](#)). However, for stage 4 patients histologic verification of all metastases was impossible. Therefore, another reference standard was used: a minimum of six months was used for verification of lesions on follow-up control examinations. A lesion was classified as a false-positive finding if it disappeared without tumour therapy during the observation period. A lesion was classified as a true-positive finding if it persisted or progressed during follow-up or if it showed clear regression under specific therapy.

$^{123}\text{I}$ -MIBG or  $^{18}\text{F}$ -FDG-PET scintigraphy was performed for 608 patients at the time of first diagnosis and for 13 patients at the time of a recurrence. Just one study reported on the 13 patients with a recurrent neuroblastoma (Piccardo 2012). All studies reported on  $^{123}\text{I}$ -MIBG scintigraphy as an index test; one study also reported on  $^{123}\text{I}$ -MIBG scintigraphy as a comparator test and  $^{18}\text{F}$ -FDG-PET scintigraphy as an index test (Sharp 2009a).

The administered activity of  $^{123}\text{I}$ -MIBG varied from 3.7 to 5.18 MBq/kg (Labreuve de Cervens 1994; Ivanova 2008; Neuenschwander 1987; Pfluger 2003; Piccardo 2012; Sharp 2009a), 185 to 370 MBq/1.73m<sup>2</sup> body surface (Hugosson 1999; Naranjo 2011a; Sharp 2009a) or was in total 111 to 370 MBq (Gordon 1990; Hashimoto 2003; Sharp 2009a). One study did not report on the administered activity of  $^{123}\text{I}$ -MIBG (Biasotti 2000).

$^{123}\text{I}$ -MIBG scintigraphy was performed 24 hours after administration of  $^{123}\text{I}$ -MIBG in six studies (Hashimoto 2003; Labreuve de Cervens 1994; Naranjo 2011a; Neuenschwander 1987; Pfluger 2003; Piccardo 2012). One study reported an acquisition time of 24 or 48 hours (Hugosson 1999) and one study of 18 to 24 hours (Gordon 1990). In three studies the acquisition time was not reported (Biasotti 2000; Ivanova 2008; Sharp 2009a).

In 91 patients only a WB  $^{123}\text{I}$ -MIBG scan was performed (Gordon 1990; Hashimoto 2003; Hugosson 1999; Pfluger 2003; Piccardo 2012), in 27 patients a  $^{123}\text{I}$ -MIBG WB scan with SPECT was performed (Hashimoto 2003; Piccardo 2012), in 264 patients it was unclear whether a  $^{123}\text{I}$ -MIBG WB scan was performed with or without SPECT (Ivanova 2008; Naranjo 2011a; Sharp 2009a) and of 239 patients it was not reported (Biasotti 2000; Labreuve de Cervens 1994; Neuenschwander 1987). The one study that reported on  $^{18}\text{F}$ -FDG-PET scintigraphy described WB scans (Sharp 2009a). However, it is

known that in studies concerning PET-scintigraphy the definition of WB may indicate from cranium to toe, but sometimes also from base of skull to knees. This information was not provided by any of the studies.

Four studies reported that interpretation of the  $^{123}\text{I}$ -MIBG or  $^{18}\text{F}$ -FDG PET scans was performed by two or more experienced observers (Hashimoto 2003; Naranjo 2011a; Pfluger 2003; Piccardo 2012), two studies reported one observer (Gordon 1990; Hugosson 1999) and five did not report on observers (Biasotti 2000; Labreuve de Cervens 1994; Ivanova 2008; Neuenschwander 1987; Sharp 2009a).

None of the included studies reported on treatment between index test and reference standard.

### Excluded studies

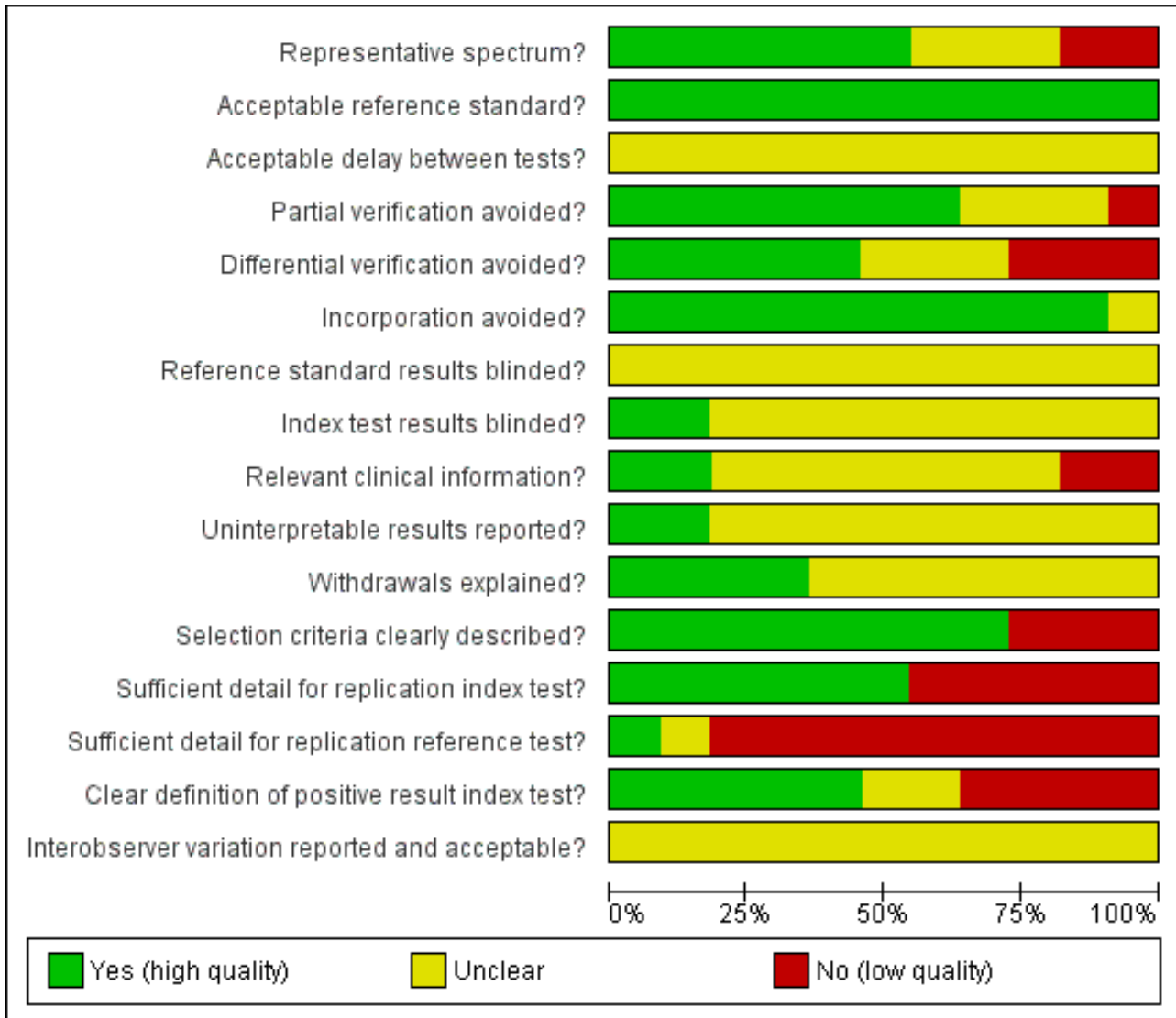
We excluded 202 studies (see [Characteristics of excluded studies](#) table): 85 studies did not report on original research; 55 studies reported on fewer than ten children with a  $^{123}\text{I}$ -MIBG scan at diagnosis; 19 studies reported on patients that were not suspected of having a neuroblastoma but another tumour; 18 studies were no primary diagnostic investigations; 13 studies reported on  $^{131}\text{I}$ -MIBG scintigraphy and one on bone scintigraphy, instead of  $^{123}\text{I}$ -MIBG scintigraphy; the selection criteria were unclear in five studies and authors were unable to clarify these; two studies reported on patients older than 18 years; one study did not report on humans; three studies were duplicates.

### Methodological quality of included studies

The quality assessment results for the individual studies can be found in the [Characteristics of included studies](#) table. [Figure 3](#) and [Figure 4](#) give an overview of all quality assessment items.



**Figure 3. Methodological quality graph: review authors' judgements about each methodological quality item presented as percentages across all included studies.**



**Figure 4. Methodological quality summary: review authors' judgements about each methodological quality item for each included study.**

	Representative spectrum?	Acceptable reference standard?	Acceptable delay between tests?	Partial verification avoided?	Differential verification avoided?	Incorporation avoided?	Reference standard results blinded?	Index test results blinded?	Relevant clinical information?	Uninterpretable results reported?	Withdrawals explained?	Selection criteria clearly described?	Sufficient detail for replication index test?	Sufficient detail for replication reference test?	Clear definition of positive result index test?	Interobserver variation reported and acceptable?
Biasotti 2000	+	+	?	?	?	?	?	?	?	?	?	-	-	-	+	?
Gordon 1990	+	+	?	+	+	+	?	?	?	?	?	+	+	-	-	?
Hashimoto 2003	-	+	?	+	+	+	?	?	+	?	+	+	+	?	+	?
Hugosson 1999	+	+	?	+	+	+	?	+	?	+	?	+	+	+	?	?
Ivanova 2008	?	+	?	?	?	+	?	?	?	?	?	-	-	-	-	?
Labreuve de Cervens 1994	-	+	?	+	-	+	?	?	?	?	+	-	-	-	?	?
Naranjo 2011a	+	+	?	+	+	+	?	+	-	?	?	+	+	-	+	?
Neuenschwander 1987	+	+	?	+	+	+	?	?	?	?	?	+	-	-	-	?
Pfluger 2003	?	+	?	-	-	+	?	?	+	+	?	+	+	-	+	?
Piccardo 2012	+	+	?	+	-	+	?	?	-	?	+	+	+	-	-	?
Sharp 2009a	?	+	?	?	?	+	?	?	?	?	+	+	-	-	+	?

In summary, in 55% of the included studies the patients were representative for the patients that will be subjected to the index test in practice, in 18% of the studies patients were not representative and it was unclear in 27% of the studies. All studies used an acceptable reference standard. The time between the index and the reference test, the index and the comparator test, the comparator and the reference test was not reported in any of the studies. Although only one study provided data on specificity, partial verification bias was avoided in 64% of the studies. These studies only reported on patients with proven neuroblastoma and they all received the same reference standard. Partial verification bias might have played a role in 9% of the studies and it was unclear in 27%. Differential verification bias was avoided in 46% and might have been present in 27% of the included studies; for 27% of the studies this was unclear. Incorporation bias was avoided in 91% and in 9% it was unclear.

It was unclear if the reference test results were blinded in all of the studies. The index test results were blinded in 18% of the studies. Observers were blinded for clinical data in 18%, in 18% of the studies clinical data were available to observers, and in 64% of studies it was unclear whether observers were blinded for clinical data.

Uninterpretable results were reported in 18% and in 82% this item was unclear. Withdrawals were reported in 36% of the studies and were not reported in 64%.

The selection criteria were provided in 73% of the studies and they were not reported in 27%.

In 55% of the studies the index test was described in sufficient detail to replicate the test and in 45% this was not the case. The reference

test was described in sufficient detail to replicate the test in just 9% of the studies, 82% of the studies did not report on this item and in 9% this item was unclear. A definition of a positive test result was reported in 46% of the studies, it was not reported in 36% of the studies, and in 18% there was no sufficient information about this item.

Inter-observer variation was not reported in any of the 11 studies.

### Findings

We were able to analyse the sensitivity and specificity of the diagnosis neuroblastoma for 608 of the 621 eligible patients. The remaining 13 patients were reported in two studies and had false positive or true negative results for neuroblastoma based just on negative bone marrow biopsies, which is not a valid method to detect neuroblastoma, but only to detect metastases (Gordon 1990; Piccardo 2012). Of these 13 patients, 12 had a stage 4 neuroblastoma and could therefore be analysed for diagnostic

accuracy of the presence of metastases (Gordon 1990; Piccardo 2012). One of the 13 patients had a stage 3 neuroblastoma and therefore could not be analysed for any of the diagnostic accuracies (Piccardo 2012).

We could not differentiate between lesions detected in several regions, because only one study reported on a lesion level (115 lesions in 22 patients) (Pfluger 2003). Because of the limited availability of data and because data at lesion level are important for staging and treatment allocation, we included this study.

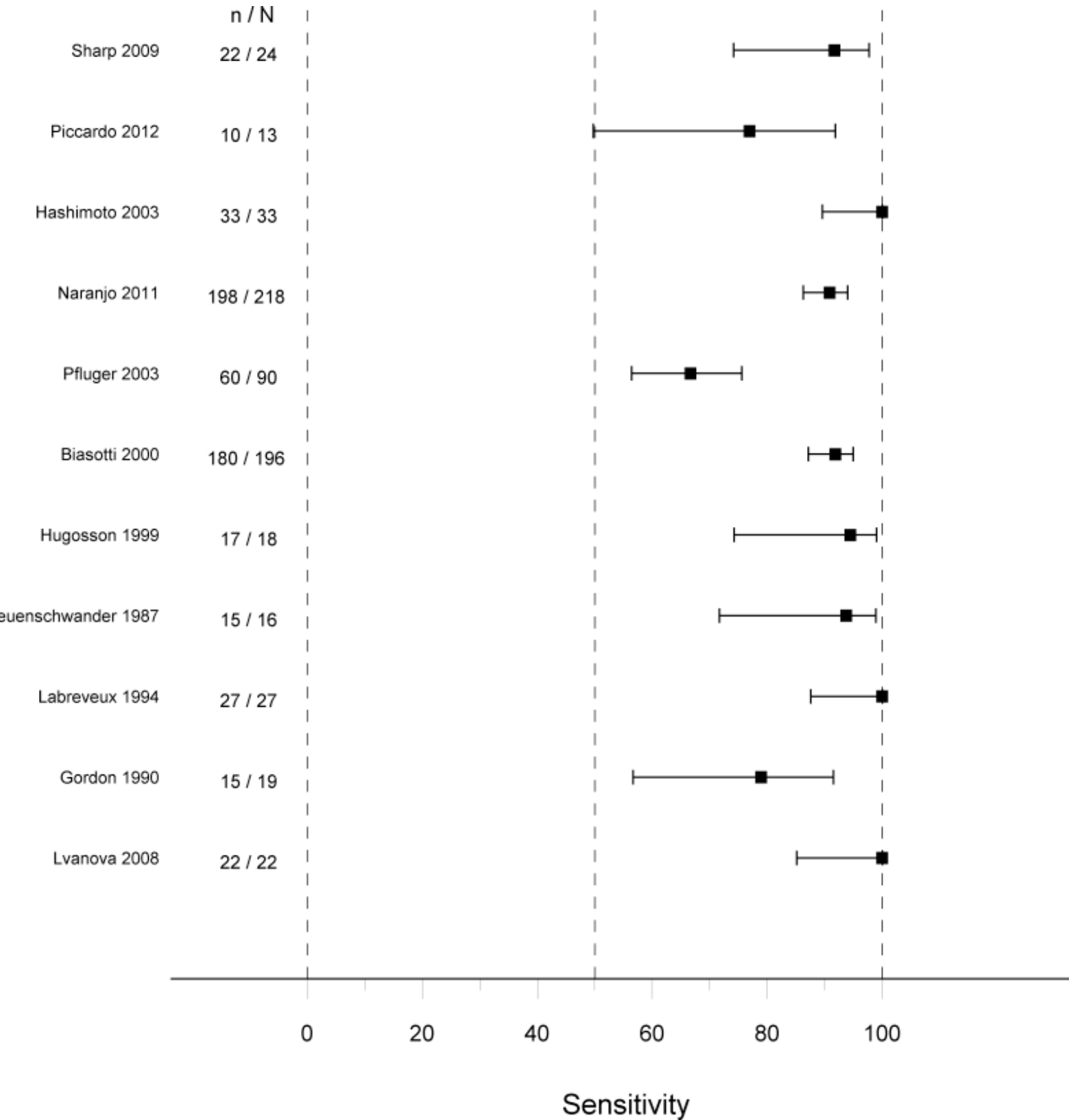
As all studies only included patients with histologically proven neuroblastoma, results do not apply to daily practice of diagnosing neuroblastoma.

The true positive fractions per study are represented in Figure 5 and the true negative fraction of one study, Pfluger 2003, is represented in Figure 6.

---

**Figure 5. Sensitivity of 123I-MIBG (SPECT-CT) scintigraphy for detecting a neuroblastoma tumour and its metastases at first diagnosis or at recurrence in children from 0 to 18 years old (with 95% confidence interval).**

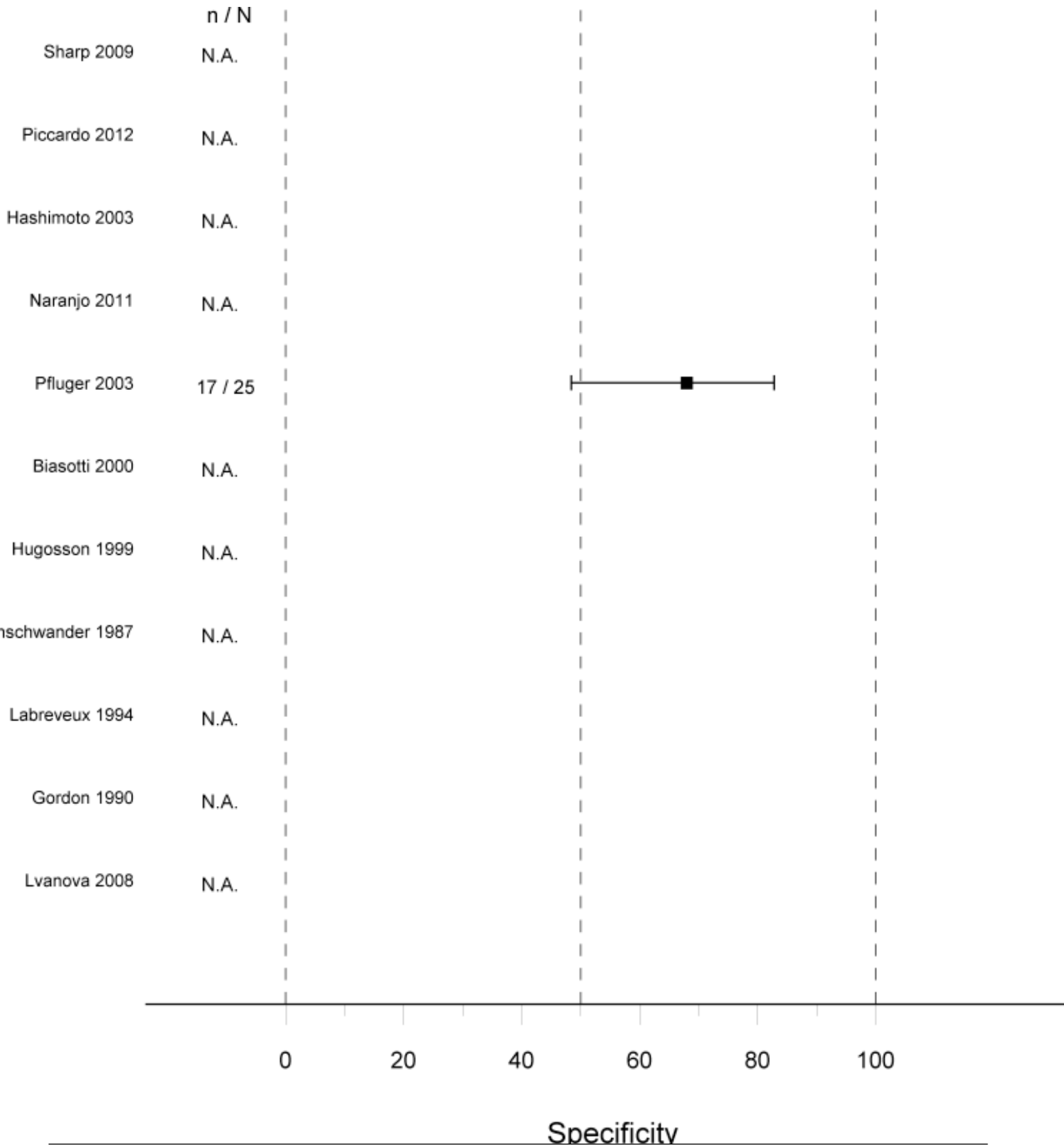
Abbreviations: n: number of patients with true positive results of <sup>123</sup>I-MIBG scintigraphy, for Pfluger 2003: number of lesions. N: total number of patients with <sup>123</sup>I-MIBG scintigraphy, for Pfluger 2003: total number of lesions.





**Figure 6. Specificity of <sup>123</sup>I-MIBG (SPECT-CT) scintigraphy for detecting a neuroblastoma tumour and its metastases at first diagnosis or at recurrence in children from 0 to 18 years old.**

**Abbreviations: n: number of lesions with true negative results of <sup>123</sup>I-MIBG scintigraphy. N: total number of lesions with <sup>123</sup>I-MIBG scintigraphy. N.A.: not available (no children without the target condition)**



### Objective 1.1 Diagnostic accuracy of $^{123}\text{I}$ -MIBG (SPECT-CT) scintigraphy for detecting a neuroblastoma and its metastases at first diagnosis or at recurrence in children from 0 to 18 years old

We analysed data of 608 patients out of 621 eligible patients. The sensitivity of the separate studies varied from 67% to 100% (see [Figure 5](#)). The total false negative rate was 11%. Only one study described patients with both suspected and already proven neuroblastoma ([Pfluger 2003](#)) and therefore specificity could only be evaluated in this study. It was 68% in 22 patients with 115 lesions (see [Figure 6](#)). The findings of this study were determined for each lesion (on a lesion level), while in all other studies they were determined per patient (on a patient level).

In [Pfluger 2003](#), the false positive findings of the  $^{123}\text{I}$ -MIBG scans at diagnosis ( $n = 8$  lesions) were due to: ganglioneuromas ( $n = 2$ ), hemangioma of the liver ( $n = 1$ ), focal nodular hyperplasia of the liver ( $n = 1$ ), normal liver ( $n = 1$ ), renal pelvis ( $n = 1$ ) and physiological activity in a normal adrenal gland, bowel or musculature ( $n = 2$ ), resulting in a specificity of 68%.

The diagnostic accuracy of detecting metastases (osteomedullary and soft tissue) separately from the primary tumour of neuroblastoma was analysed in three studies with all 72 eligible patients ([Gordon 1990](#); [Labreux de Cervens 1994](#); [Piccardo 2012](#)). In contrast to the diagnosis of the primary tumour, analyses for the diagnostic accuracy of the metastases did include false positive in two and true negative findings in all three studies and therefore sensitivity and specificity could be calculated for these three and two studies, respectively. The sensitivity of  $^{123}\text{I}$ -MIBG scintigraphy for detecting neuroblastoma metastases in the three studies ranged from 79% to 100%. The specificity could be calculated for two of these studies with 45 patients and ranged from 33% to 89%. Of the 72 patients 72% had true positive metastases on the  $^{123}\text{I}$ -MIBG scan, 7% false negative, 7% false positive and 14% true negative.

The detection of metastases was also analysed for osteomedullary, lymph node and liver metastases separately. The detection of osteomedullary metastases was reported in four studies with 105 eligible patients ([Gordon 1990](#); [Hashimoto 2003](#); [Labreux de Cervens 1994](#); [Piccardo 2012](#)). The sensitivity of these four studies ranged from 33% to 100% and the specificity from 57% to 100%. The detection of lymph node and liver metastases was reported in one study with 33 eligible patients ([Hashimoto 2003](#)). For the detection of liver metastases the sensitivity for 33 patients was 80% and the specificity 93%. For the detection of lymph node metastases this was 23% and 100%, respectively.

#### Subgroup analyses

For some items subgroup analyses were not possible at all (acquisition time and interfering medication), because insufficient data were given to identify subgroups.

#### Stages of disease

This item was used to compare the diagnostic accuracy of  $^{123}\text{I}$ -MIBG scintigraphy to diagnose the primary tumour in patients with stage 1-2 vs. stage 3 vs. stage 4 vs. stage 4S.

Two studies reported data on diagnostic accuracy of  $^{123}\text{I}$ -MIBG scintigraphy in all 43 eligible patients with stage 1 or 2

neuroblastoma ([Biasotti 2000](#); [Sharp 2009a](#)). The sensitivity of these studies ranged from 60% to 76%.

Three studies reported data on diagnostic accuracy of  $^{123}\text{I}$ -MIBG scintigraphy in 54 of all 55 eligible patients with stage 3 neuroblastoma ([Biasotti 2000](#); [Piccardo 2012](#); [Sharp 2009a](#)). The sensitivity of these studies ranged from 0% to 100%.

Four studies reported data on diagnostic accuracy of  $^{123}\text{I}$ -MIBG scintigraphy in all 344 eligible patients with stage 4 neuroblastoma ([Biasotti 2000](#); [Naranjo 2011a](#); [Piccardo 2012](#); [Sharp 2009a](#)). The sensitivity of these studies ranged from 80% to 100%.

Only one study reported data on diagnostic accuracy of  $^{123}\text{I}$ -MIBG scintigraphy in all 13 eligible patients with stage 4S neuroblastoma ([Biasotti 2000](#)). The sensitivity was 100%.

Two studies reported on diagnostic accuracy of  $^{123}\text{I}$ -MIBG scintigraphy for detecting osteomedullary metastases of stage 4 neuroblastoma separately from the other stages ([Gordon 1990](#); [Piccardo 2012](#)). For the 37 eligible patients with stage 4 disease described in these two studies, the sensitivity ranged from 79% to 90% and the specificity from 40% to 67%.

#### Newly diagnosed versus recurrent neuroblastoma

Data on the diagnostic accuracy of  $^{123}\text{I}$ -MIBG scintigraphy for detecting neuroblastoma in children from 0 to 18 years, newly diagnosed versus recurrent, were only available for 13 eligible patients in one study ([Piccardo 2012](#)). Of the four patients with a  $^{123}\text{I}$ -MIBG at first diagnosis, two had true positive and two had false negative findings (sensitivity 50%). Of the nine patients with a  $^{123}\text{I}$ -MIBG at recurrence, eight had true positive and one had false negative findings (sensitivity 89%).

#### Type of reference standard

Diagnostic accuracy of  $^{123}\text{I}$ -MIBG scintigraphy for detecting neuroblastoma in children from 0 to 18 years old per reference standard (histopathology versus bone marrow biopsies) was only provided in one study ([Piccardo 2012](#)). In six children, histopathology as the reference standard gave three true positive and three true negative results (sensitivity 50%). Bone marrow biopsies in all 17 children gave nine true positive, two false positive, two false negative and four true negative findings (sensitivity of 82% and specificity of 67%). The other studies did not give numbers for separate reference standards, so we could not perform any analyses on this item.

#### Plane WB versus WB SPECT/CT $^{123}\text{I}$ -MIBG scintigraphy

The sensitivity of  $^{123}\text{I}$ -MIBG scintigraphy for detecting neuroblastoma in children from 0 to 18 years for patients with WB  $^{123}\text{I}$ -MIBG scintigraphy could be analysed with the data of four studies with 62 of 85 eligible patients ([Gordon 1990](#); [Hugosson 1999](#); [Pfluger 2003](#); [Piccardo 2012](#)). The sensitivity ranged from 67% to 100%. The specificity was only provided in one study for all 115 lesions of 22 eligible patients and was 68% ([Pfluger 2003](#)).

Only one study, [Piccardo 2012](#), reported the sensitivity of WB  $^{123}\text{I}$ -MIBG scans with SPECT/CT separately from those without for 11 of 17 eligible patients and was 73%.



### Objective 1.2 Diagnostic accuracy of negative $^{123}\text{I}$ -MIBG scintigraphy in combination with $^{18}\text{F}$ -FDG-PET(-CT) imaging for detecting a neuroblastoma and its metastases at first diagnosis or at recurrence in children from 0 to 18 years old

Only one study reported on the diagnostic accuracy of negative  $^{123}\text{I}$ -MIBG scintigraphy in combination with  $^{18}\text{F}$ -FDG-PET(-CT) imaging for detecting a neuroblastoma and its metastases at first diagnosis or at recurrence in children 0 to 18 years (Sharp 2009a). Two of the 24 eligible patients with proven neuroblastoma had a negative  $^{123}\text{I}$ -MIBG scan and a positive  $^{18}\text{F}$ -FDG-PET(-CT) scan.

### Objective 2.1 Diagnostic accuracy of $^{18}\text{F}$ -FDG-PET(-CT) imaging for detecting a neuroblastoma and its metastases at first diagnosis or at recurrence in children from 0 to 18 years old

Only one study reported on the diagnostic accuracy of  $^{18}\text{F}$ -FDG-PET(-CT) imaging for detecting a neuroblastoma and its metastases at first diagnosis in children from 0 to 18 years (Sharp 2009a). This study described data on  $^{18}\text{F}$ -FDG-PET(-CT) scans of all 24 eligible patients with proven neuroblastoma with a sensitivity of 100%. Because all patients had already proven neuroblastoma, false positive and true negative findings did not occur in this study and therefore specificity could not be analysed.

#### Subgroup analyses

Pooled analyses were not possible, because only one study reported on this objective. However, data on diagnostic accuracy for subgroups of INSS stage within this study were available. For the other subgroups these data were not provided (newly diagnosed versus recurrent neuroblastoma, plane WB versus WB SPECT/CT  $^{123}\text{I}$ -MIBG scintigraphy, type of reference standard, acquisition time and interfering medication).

#### Stages of disease

The one study with 24 eligible patients that reported on the diagnostic accuracy of  $^{18}\text{F}$ -FDG-PET(-CT) imaging for detecting a primary neuroblastoma tumour and its metastases in children from 0 to 18 years old (Sharp 2009a), described only true positive findings for five patients with stage 1 or 2 disease, 3 patients with stage 3 disease and 16 patients with stage 4 tumours, so a sensitivity of 100%.

### Objective 2.2 Comparison of diagnostic accuracy of $^{123}\text{I}$ -MIBG (SPECT-CT) scintigraphy and of $^{18}\text{F}$ -FDG-PET(-CT) imaging for detecting a neuroblastoma and its metastases at first diagnosis or at recurrence in children from 0 to 18 years old

Only one study reported on the diagnostic accuracy of  $^{123}\text{I}$ -MIBG (SPECT-CT) scintigraphy versus  $^{18}\text{F}$ -FDG-PET(-CT) imaging for detecting a neuroblastoma and its metastases at first diagnosis or at recurrence in children from 0 to 18 years (Sharp 2009a). This study described data on all 24 eligible patients with proven neuroblastoma. The sensitivity of  $^{123}\text{I}$ -MIBG scintigraphy was 92% with two false negative results. The sensitivity of  $^{18}\text{F}$ -FDG-PET(-CT) imaging was 100%. The specificity could not be calculated, because only proven neuroblastoma patients were included. So,  $^{18}\text{F}$ -FDG-PET(-CT) imaging had a better sensitivity than  $^{123}\text{I}$ -MIBG scintigraphy. The two  $^{123}\text{I}$ -MIBG negative neuroblastoma were positive on  $^{18}\text{F}$ -FDG-PET(-CT) imaging.

#### Subgroup analyses

Pooled analyses were not possible because only one study reported on this objective. However, data on diagnostic accuracy for subgroups of INSS stage within this study were available. For the other subgroups these data were not provided (newly diagnosed versus recurrent neuroblastoma, plane WB versus WB SPECT/CT  $^{123}\text{I}$ -MIBG scintigraphy, type of reference standard, acquisition time and interfering medication).

#### Stages of disease

The one study with 24 eligible patients that compared the diagnostic accuracy of  $^{123}\text{I}$ -MIBG and  $^{18}\text{F}$ -FDG-PET(-CT) imaging for detecting a neuroblastoma and its metastases at first diagnosis in children from 0 to 18 years old (Sharp 2009a), described two false negative findings on  $^{123}\text{I}$ -MIBG scintigraphy of five patients with stage 1 or 2 disease, resulting in a sensitivity of 60%.  $^{18}\text{F}$ -FDG-PET(-CT) imaging was positive for all five patients with a sensitivity of 100%. Three patients with stage 3 disease and 16 patients with stage 4 tumour had all true positive findings on the  $^{123}\text{I}$ -MIBG scintigraphy and the  $^{18}\text{F}$ -FDG-PET(-CT) imaging, with sensitivities of 100%. We could not calculate specificity because only proven neuroblastoma was described.

## DISCUSSION

### Summary of main results

We assessed three index test combinations in this Cochrane DTA review: 1.  $^{123}\text{I}$ -MIBG scintigraphy, 2.  $^{18}\text{F}$ -FDG-PET(-CT), and 3.  $^{123}\text{I}$ -MIBG scintigraphy plus  $^{18}\text{F}$ -FDG-PET(-CT) (Figure 1).

### Objective 1.1 to determine the diagnostic accuracy of $^{123}\text{I}$ -MIBG (SPECT-CT) scintigraphy:

The sensitivity, determined in 608 of 621 eligible patients included in 11 studies, varied from 67% to 100% (Figure 5; Summary of findings 1). The specificity was 68% in 115 lesions in 22 patients and was described in only one study (Figure 6).

The sensitivity for the detection of stage 1 and 2 neuroblastoma with  $^{123}\text{I}$ -MIBG scintigraphy varied from 60 to 76% (two studies), for stage 3 neuroblastoma from 0% to 100% (three studies), for stage 4 neuroblastoma 80% to 100% (four studies), and for stage 4S neuroblastoma the sensitivity was 100% (one study) (Summary of findings 1). The range of the sensitivity of stage 3 tumours was quite broad in comparison to that for all tumours. An explanation might be that of the three studies included in this subgroup analysis, Piccardo 2012 reported on just one patient with a false negative scan, resulting in a sensitivity of 0%. The sensitivity of 100% for stage 4S tumours might also be explained by the small number of included patients, being 13 patients from only one study with all true positive investigations.

Three of the 11 studies (in total 72 patients) described the diagnostic accuracy of  $^{123}\text{I}$ -MIBG (SPECT-CT) scintigraphy for detecting metastases (soft tissue and osteomedullary) separately from the primary tumour in patients with all neuroblastoma stages (Summary of findings 1). The sensitivity ranged from 79% to 100% (three studies) and the specificity from 33% to 89% (two studies). For lymph node metastases the sensitivity was 23% and the specificity 100%; and for liver metastases this was 80% and 93%. Both types of metastases were reported in one study with

33 patients. Osteomedullary metastases were described in four studies with 105 patients. The sensitivity varied from 33% to 100% and the specificity from 57% to 100%. The sensitivity for osteomedullary metastases in only stage 4 neuroblastoma varied from 79% to 90% and a specificity from 40% to 67% (two studies) ([Summary of findings 1](#)).

**Objective 1.2 to determine the diagnostic accuracy of negative <sup>123</sup>I-MIBG scintigraphy in combination with <sup>18</sup>F-FDG-PET(-CT) imaging (<sup>18</sup>F-FDG-PET(-CT) as an add-on test):**

Only one study reported on this objective. For two of the 24 eligible patients with proven neuroblastoma <sup>18</sup>F-FDG-PET(-CT) imaging had additional value. Two patients with a negative <sup>123</sup>I-MIBG scan had a positive <sup>18</sup>F-FDG-PET(-CT) scan.

**Objective 2.1 to determine the diagnostic accuracy of <sup>18</sup>F-FDG-PET(-CT) imaging and Objective 2.2 to compare the diagnostic accuracy of <sup>123</sup>I-MIBG (SPECT-CT) scintigraphy and of <sup>18</sup>F-FDG-PET(-CT) imaging within and between included studies**

The sensitivity of <sup>123</sup>I-MIBG scintigraphy was 92% and of <sup>18</sup>F-FDG-PET(-CT) imaging 100%. We could not analyse the specificity because all patients had already proven neuroblastoma ([Summary of findings 2](#)). So, for the 24 eligible patients in this study, <sup>18</sup>F-FDG-PET(-CT) imaging had a better sensitivity than <sup>123</sup>I-MIBG (SPECT-CT) scintigraphy.

**Strengths and weaknesses of the review**

**Limited amount of available data**

Likelihood ratios are the most useful outcome parameters to judge the diagnostic test accuracy of the index tests. In the work-up of neuroblastoma, urine analysis for excretion of catecholamines (a non-invasive screening tool), diagnostic imaging and <sup>123</sup>I-MIBG-scintigraphy are generally performed, before the diagnosis is confirmed by the gold standard: histopathology.

Most studies included in our review were studies that investigated the performance of <sup>123</sup>I-MIBG-scintigraphy versus other imaging techniques, in a cohort of patients with histologically proven neuroblastoma. However, as is described above, this was not the case at the start of the diagnostic work-up. The <sup>123</sup>I-MIBG-scans in these studies were commonly assessed without knowing the results of the histopathology.

Of the 11 included studies, nine reported on case series of proven neuroblastoma. One study was a retrospective cross-sectional study. The final study was a prospective cross-sectional study that eventually identified only children with neuroblastoma.

Only one of the included studies provided data on false-positive results at a lesion level, not at a patient level. We believe in fact that this is a study of patients with proven neuroblastoma, in which the performance of the two imaging modalities (<sup>123</sup>I-MIBG-scintigraphy and <sup>18</sup>F-FDG-PET-scintigraphy) was tested for all lesions.

False-positive results of metastatic lesions are possible in patients with proven neuroblastoma. Thus we could not calculate likelihood ratios. It is not expected that future studies will assess specificity.

Few data were available to calculate the specificity, as no extensive data on true negative and false positive numbers were reported.

To calculate the diagnostic accuracy, we indeed need both data on sensitivity and specificity. At the start of this project, we did not expect to find only very limited data on specificity. Now that we know this, we think that the term "the sensitivity to assess the presence of neuroblastoma" for the objectives would have been more appropriate than "diagnostic accuracy".

However, we could collect data on true positive and false negative rates to calculate sensitivity.

Only few included studies are of a prospective design, but we feel that all of them are studies assessing the sensitivity of MIBG to detect neuroblastoma. Since there is only limited evidence available we included them in the review.

We excluded studies with fewer than ten patients suspected for neuroblastoma. There is neither evidence nor guidelines to decide which cut-off is justified, but generally systematic reviews published in high-impact journals use a cut-off of ten patients. Therefore we decided to use 10 as a cut-off point.

Furthermore, we feared for bias, if small patient numbers were selectively reported out of a larger population. Therefore we also excluded case reports.

The inclusion of a small number of patients in the studies of [Gordon 1990](#) and [Piccardo 2012](#) (19 and 13, respectively) might explain the minor sensitivity in comparison to the other studies. Due to small numbers, one scan more or less scored as false negative, might have a great effect on the sensitivity. For [Pfluger 2003](#) the minor sensitivity might be explained by the fact that the study results were based on a lesion level and not on a patient level. Just one positive lesion is enough for the diagnosis neuroblastoma and just one positive metastatic site is enough to define stage 4 disease. However, patients were probably included in this study with more than one positive lesion. Therefore, sensitivity may be overestimated.

Only one study with 24 eligible patients, [Sharp 2009a](#), reported on the diagnostic accuracy of <sup>18</sup>F-FDG-PET(-CT) imaging as a single diagnostic test (objective 2.1) and compared to <sup>123</sup>I-MIBG scintigraphy (objective 2.2). Therefore, it is difficult to draw reliable conclusions from analyses on this study. In this study only two patients with negative <sup>123</sup>I-MIBG scans were reported that were positive on <sup>18</sup>F-FDG-PET(-CT) scans (objective 1.2). <sup>18</sup>F-FDG-PET(-CT) imaging is an upcoming diagnostic imaging method for the detection of neuroblastoma and its metastases. It is already considered as an important additional diagnostic method if <sup>123</sup>I-MIBG scintigraphy is negative ([Piccardo 2013](#)). We hope that in an update of this Cochrane DTA review we can include more studies on this objective and provide more reliable information on the diagnostic accuracy of <sup>18</sup>F-FDG-PET(-CT) imaging.

For some items subgroup analyses were not possible at all (acquisition time and interfering medication), because insufficient data were given to identify subgroups.

In this review, the type of the <sup>123</sup>I-MIBG scans (WB, SPECT-CT or a combination) varied between the studies and not all studies reported on the distinction between these types of scans. The sensitivity of <sup>123</sup>I-MIBG WB scintigraphy ([Gordon 1990](#); [Hugosson 1999](#); [Pfluger 2003](#); [Piccardo 2012](#)), as well as of <sup>123</sup>I-MIBG WB SPECT-CT scintigraphy ([Piccardo 2012](#)), was 73%. So, there was

no difference in sensitivity for WB versus WB SPECT-CT scans. However, only one study described WB SPECT-CT scans of only 11 of 17 eligible patients. In the literature, the addition of SPECT-CT might change the diagnostic accuracy of  $^{123}\text{I}$ -MIBG scintigraphy (Gelfand 1994; Rozovsky 2008; Rufini 1995; Rufini 1996). Usually it improves the detection of neuroblastoma lesions and it is easier to differentiate pathological from physiological uptake. Therefore, although the sensitivity of both modalities did not differ in this review, it is still important to make a distinction between studies that used WB scintigraphy only and those that added SPECT-CT.

### Reference standards

Three different tests were used as possible reference standards. If only one of the three reference standards had a positive result, the diagnosis neuroblastoma could be confirmed. However, to reject the diagnosis neuroblastoma all three had to give a negative result. For some of the studies, only bone marrow biopsies, but not histopathology, was reported for some patients. Due to sampling error, a negative result of bone marrow aspirates or trephine biopsies does not exclude a primary neuroblastoma tumour or metastatic disease. If in this case no reliable conclusions could be drawn, we excluded these patients from sensitivity and specificity analyses.

One study reported on a lesion level (Pfluger 2003). Histologic verification of all lesions in stage 4 patients with metastases is impossible. Therefore, another reference standard was used: a minimum of six months was used for verification of lesions on follow-up control examinations. A lesion was classified as a false-positive finding if it disappeared without tumour therapy during the observation period. A lesion was classified as a true positive finding if it persisted or progressed during follow-up or if it showed clear regression under specific therapy. This might explain the fact that this study found more false positive and false negative results than the other studies. The other studies did not report on a lesion level, but on a patient level. Only one positive lesion is then enough to diagnose a neuroblastoma and only one metastatic lesion is enough to classify the patient as stage 4 or 4S. For the diagnosis of neuroblastoma in general, sensitivity and specificity on a lesion level is less important.

### Data extraction and quality assessment

The concordance between the review authors on the data extraction and the QUADAS was high. We disagreed on only 2.7% of the items on the data extraction form and on 3.7% of the QUADAS-form. So, we conclude that the data extraction and quality assessment were reliable.

### Limited possibility to assess the eligibility for this review for a substantial amount of studies

Unfortunately it was not possible to assess the eligibility for inclusion in this review for a substantial amount of studies ( $n = 38$ ). We tried to contact the study authors to obtain the necessary information and if necessary identify translators, but were unsuccessful. We don't know what the impact of this on the review results are.

### Applicability of findings to the review question

Although many studies report on  $^{123}\text{I}$ -MIBG scintigraphy, this is the first systematic review on diagnostic test accuracy of  $^{123}\text{I}$ -MIBG scintigraphy. In the literature it is often stated that 90% of

neuroblastoma tumours take up MIBG (MIBG-avid) and that around 10% do not (Boubaker 2008). In concordance with the literature, we reported 11% of the 608 patients in the 11 included studies with MIBG-non-avid neuroblastoma. The reasons for these MIBG-non-avid tumours are not entirely clear. Possible modifications in the uptake mechanism or interfering medication may play a role (Boubaker 2008), but most studies do not report on the reasons of MIBG-non-avid neuroblastoma lesions. Also intense radiotracer uptake in normal liver, myocardium, salivary glands and gut may blur the picture and small pathological lesions can be less visible. SPECT-CT might improve the detection of these lesions, but more research is needed before a definitive conclusion can be made.

The analyses in this review showed a false negative rate of around 7% for all types of metastases and for osteomedullary metastases specifically. So, investigation of bone marrow aspirates or trephine biopsies, as described in current protocols (Monclair 2009), are justified in all patients at diagnosis. However, these aspirates and biopsies are taken from the iliac crest, so distant metastases might still be missed. Therefore it is worthwhile to perform an additional test, in case of a negative result of WB  $^{123}\text{I}$ -MIBG scintigraphy. For metastases this is of great importance, because the presence of metastases classifies the patient as stage 4 or 4S and this has severe consequences for the prognosis and treatment. A possible candidate as add-on test might be  $^{18}\text{F}$ -FDG-PET(-CT) or MRI (Corbett 1991b; Siegel 2013). In this Cochrane DTA review we reviewed the diagnostic accuracy of  $^{18}\text{F}$ -FDG-PET(-CT). When comparing  $^{18}\text{F}$ -FDG-PET(CT) imaging to  $^{123}\text{I}$ -MIBG scintigraphy, the sensitivity of  $^{18}\text{F}$ -FDG-PET(CT) was better and it had additional value if  $^{123}\text{I}$ -MIBG scintigraphy was negative (all in one study). So, it is important to study this imaging method as a promising add-on test.

Although the specificity of  $^{123}\text{I}$ -MIBG scintigraphy was analysed in just one study, analyses were performed for 115 lesions in 22 patients (Pfluger 2003). The general assumption is that MIBG activity on an  $^{123}\text{I}$ -MIBG scan, that is not explained by physiological uptake, is most likely a neuroblastoma tumour. In contrast, Pfluger 2003 reported false positive findings. The specificity was 68%, but we believe that not all of these false positive results were justified. Some could be considered as physiological uptake, like normal liver ( $n = 1$ ), renal pelvis ( $n = 1$ ) and physiological activity of the normal gland, bowel or musculature ( $n = 2$ ) and then specificity would be 85%.

## AUTHORS' CONCLUSIONS

### Implications for practice

In this Cochrane DTA review, we included 11 studies and found a sensitivity of 67 to 100%. Although only one included study reported on false positive findings, it is important to keep in mind that false positive findings occur. Most reported false positive findings in this one study seemed to be physiological uptake. However, this implies that  $^{123}\text{I}$ -MIBG scans may not be evaluated as easily as is generally thought and that it is important to rule out physiological uptake, e.g. by using SPECT-CT scans. However, further research is needed before definitive conclusions can be made.

As described both in the literature and in this review, in about 10% of patients with histologically proven neuroblastoma the tumour does not accumulate  $^{123}\text{I}$ -MIBG (false negative results). For these

patients, it is advisable to perform an additional test for staging the neuroblastoma. Additional tests might for example be  $^{18}\text{F}$ -FDG-PET(-CT), but more evidence is necessary.

### Implications for research

In this Cochrane DTA review, only one study reported on the specificity of  $^{123}\text{I}$ -MIBG scintigraphy (Pfluger 2003). The other ten studies reported on patients with already proven neuroblastoma. Although the general assumption is that  $^{123}\text{I}$ -MIBG uptake outside the physiological areas proves neuroblastoma, this one study reported 7% false positive findings or 3% if cases with physiological uptake were excluded. It would be helpful to further and better assess the specificity in future studies.

Furthermore, it is important to study the possibilities of other additional diagnostic tests in case of negative results of  $^{123}\text{I}$ -MIBG scans in patients suspected of neuroblastoma or already diagnosed with neuroblastoma according to histopathology. One possible additional test is  $^{18}\text{F}$ -FDG-PET(-CT). Only one study concerning  $^{18}\text{F}$ -FDG imaging was included. Because more and more studies are performed with this diagnostic test for patients with neuroblastoma, we think that with the update of this review more studies on  $^{18}\text{F}$ -FDG PET(-CT) can be analysed and more robust conclusions can be drawn.

Furthermore, a promising test is the  $^{18}\text{F}$ -DOPA-PET-CT. This test also relies on the metabolism of catecholamines, but has the advantage of better performance due to PET-technology (Piccardo 2013). Future studies might reveal more details about the diagnostic accuracy of this test.

In this Cochrane systematic diagnostic test accuracy review some subgroup analyses were not possible, because studies did not report the data in sufficient detail to assign all patients to subgroups.

Only 11 studies were included in this diagnostic test accuracy review. The first reason for the small number of included studies is

that we excluded studies that performed  $^{131}\text{I}$ -MIBG instead of  $^{123}\text{I}$ -MIBG scintigraphy. However, a recent publication (Naranjo 2011) reported no evidence of a statistically significant difference in outcome by type of scan. Therefore, for an update of this review it would be advisable to take these  $^{131}\text{I}$ -MIBG scans also into account. A second reason for the small number of included studies was that many studies reported on  $^{123}\text{I}$ -MIBG scintigraphy of less than ten patients which was an exclusion criteria for our review, assuming that less than ten patients could not give robust results. However, if reported clearly, studies with less than ten patients might be able to give reliable data and pooling them would be an opportunity for an update of this review. A last reason is that the number of patients with a neuroblastoma per centre is small. In the past, many studies reported patients per centre, resulting in a small number of patients per study. Nowadays, more and more centres collaborate to publish results of their patients together, resulting in more robust data. For an update of this review, we hope that these kind of collaborations will result in many studies with a large number of patients and with robust results, so we can include more patients and do more reliable analyses.

### ACKNOWLEDGEMENTS

We thank Edith Leclercq, the Trials Search Co-ordinator of the Cochrane Childhood Cancer Group, for helping to design the search strategy and running the searches.

Also, we are grateful to E.M.C. Michiels, MD, PhD; A. Seniukovich, MD; P. Alonso-Coello, MD; K. Hayashi; and R.W.M. Vernooij, M.Sc. for their help with translating non-English studies.

We thank A.F. Jacobson, MD, PhD, and A. Naranjo, PhD for their additional information on studies that we had to assess; K. Matthey, MD, and B.L. Shulkin, MD for their information on ongoing studies; and H. Reitsma for performing data analyses.

The editorial base of the Cochrane Childhood Cancer Group is funded by Kinderen Kankervrij (KiKa).

## REFERENCES

## References to studies included in this review

**Biasotti 2000** {published data only}

Biasotti S, Garaventa A, Villavecchia GP, Cabria M, Nantron M, De Bernardi B. False-negative metaiodobenzylguanidine scintigraphy at diagnosis of neuroblastoma. *Medical and Pediatric Oncology* 2000;**35**(2):153-5.

**Gordon 1990** {published data only}

Gordon I, Peters AM, Gutman A, Morony S, Dicks-Mireaux C, Pritchard J. Skeletal assessment in neuroblastoma--the pitfalls of iodine-123-MIBG scans. *Journal of Nuclear Medicine* 1990;**31**(2):129-34.

**Hashimoto 2003** {published data only}

Hashimoto T, Koizumi K, Nishina T, Abe K. Clinical usefulness of iodine-123-MIBG scintigraphy for patients with neuroblastoma detected by a mass screening survey. *Annals of Nuclear Medicine* 2003;**17**(8):633-40.

**Hugosson 1999** {published data only}

Hugosson C, Nyman R, Jorulf H, McDonald P, Rifai A, Kofide A, et al. Imaging of abdominal neuroblastoma in children. *Acta Radiologica* 1999;**40**(5):534-42.

**Ivanova 2008** {published data only}

Ivanova AA, Sokolov AV, Yalifimov AN, Savchenko ON. Role of 123-I-metaiodobenzylguanidine imaging as a component in the diagnosis and treatment of neuroblastoma [Russian]. *Voprosy Onkologii* 2008;**54**(4):521-4.

**Labreuve de Cervens 1994** {published data only}

Labreuve de Cervens C, Hartmann O, Bonnifant F, Couanet D, Valteau-Couanet D, Lumbroso J, et al. What is the prognostic value of osteomedullary uptake on MIBG scan in neuroblastoma patients under one year of age?. *Medical and Pediatric Oncology* 1994;**22**(2):107-14.

**Naranjo 2011a** {published data only}

Naranjo A, Parisi MT, Shulkin BL, London WB, Matthay KK, Kreissman SG, et al. Comparison of <sup>123</sup>I-metaiodobenzylguanidine (MIBG) and <sup>131</sup>I-MIBG semi-quantitative scores in predicting survival in patients with stage 4 neuroblastoma: a report from the Children's Oncology Group. *Pediatric Blood and Cancer* 2011;**56**(7):1041-5.

**Neuenschwander 1987** {published data only}

Neuenschwander S, Ollivier L, Toubeau M, Nguyen-Tan T, Gongora G, Zucker JM. Local evaluation of abdominal neuroblastoma stage III and IV: use of US, CT, and 123 I-metaiodobenzylguanidine (MIBG) scintigraphy. *Annales de Radiologie (Paris)* 1987;**30**(7):491-6.

**Pfluger 2003** {published data only}

Pfluger T, Schmied C, Porn U, Leinsinger G, Vollmar C, Dresel S, et al. Integrated imaging using MRI and 123I metaiodobenzylguanidine scintigraphy to improve sensitivity and specificity in the diagnosis of pediatric neuroblastoma. *American Journal of Roentgenology* 2003;**181**(4):1115-24.

**Piccardo 2012** {published data only}

Piccardo A, Lopci E, Conte M, Garaventa A, Foppiani L, Altrinetti V, et al. Comparison of 18F-dopa PET/CT and 123I-MIBG scintigraphy in stage 3 and 4 neuroblastoma: a pilot study. *European Journal of Nuclear Medicine and Molecular Imaging* 2012;**39**(1):57-71.

**Sharp 2009a** {published data only}

Sharp SE, Shulkin BL, Gelfand MJ, Salisbury S, Furman WL. 123I-MIBG scintigraphy and 18F-FDG PET in neuroblastoma. *Journal of Nuclear Medicine* 2009;**50**(8):1237-43.

## References to studies excluded from this review

**Abramowsky 2009** {published data only}

Abramowsky CR, Katzenstein HM, Alvarado CS, Shehata BM. Anaplastic large cell neuroblastoma. *Pediatric and Developmental Pathology* 2009;**12**(1):1-5.

**Adam 2008** {published data only}

Adam M. Report on the Fifth International Symposium on Radiohalogens (Whistler, BC, Canada, September 11-15th, 2004). *Quarterly Journal of Nuclear Medicine and Molecular Imaging* 2008;**52**(2):203-6.

**Adolph 1989** {published data only}

Adolph J, Kimmig B. Diagnostic imaging and therapy of neuroectodermal neoplasms [German]. *Radiologe* 1989;**29**(1):32-42.

**Alessio 2011** {published data only}

Alessio AM, Sammer M, Phillips GS, Manchanda V, Mohr BC, Parisi MT. Evaluation of optimal acquisition duration or injected activity for pediatric 18F-FDG PET/CT. *Journal of Nuclear Medicine* 2011;**52**(7):1028-34.

**Andersen 2011** {published data only}

Andersen JB, Mortensen J, Bech BH, Højgaard L, Borgwardt L. First experiences from Copenhagen with paediatric single photon emission computed tomography/computed tomography. *Nuclear Medicine Communications* 2011;**32**(5):356-62.

**Angelini 2007** {published data only}

Angelini P, De Bernardi B, Granata C, Villavecchia G, Morbelli S, Luksch R, et al. Skeletal involvement in infants with neuroblastoma a quality control attempt. *Tumori* 2007;**93**(1):82-7.

**Arceci 1999** {published data only}

Arceci RJ. Comments from the Editor-in-Chief. *Journal of Pediatric Hematology/Oncology* 1999;**21**(1):1-2.

**Arceci 2003** {published data only}

Arceci RJ. Comments from the Editor-in-Chief. *Journal of Pediatric Hematology/Oncology* 2003;**25**(2):97-8.

**Arora 2010** {published data only}

Arora B, Parikh PM. PET-CT scan in pediatric oncology: Where, when, how and at what price. *Indian Journal of Cancer* 2010;**47**(4):355-9.

**Balaguer 2008** {published data only}

Balaguer J, Castel V. Oncology: Neuroblastoma. *Anales de Pediatría Continuada* 2008;**6**:276-83.

**Bardi 2009** {published data only}

Bardi E, Cska M, Kiss C, Kovcs G. Use of FDG-PET CT for staging and follow up in children with different cancers. 41st Annual Conference of the International Society of Paediatric Oncology SIOP; 2009 Oct 05-09; São Paulo. *Pediatric Blood and Cancer* 2009;**53**(5):888-9.

**Barliev 1988** {published data only}

Barliev G. Scintigraphic localization and treatment of catecholaminesecreting tumors with <sup>131</sup>I-meta-iodobenzylguanidine [Bulgarian]. *Rentgenologiya i Radiologiya* 1988;**27**:37-43.

**Baulieu 1984** {published data only}

Baulieu JL, Guilloteau D, Viel C. Meta-iodobenzylguanidine scintigraphy. A first year experience schedule [French]. *Journal de Biophysique et Medecine Nucleaire* 1984;**8**(1):27-33.

**Beierwaltes 1991** {published data only}

Beierwaltes WH. Endocrine imaging: parathyroid, adrenal cortex and medulla, and other endocrine tumors. Part II. *Journal of Nuclear Medicine* 1991;**32**(8):1627-39.

**Benz-Bohm 1990** {published data only}

Benz-Bohm G, Gross-Fengels W, Widemann B, Linden A. Bone marrow metastases of neuroblastoma: MRT in comparison with bone marrow cytology and MIBG scintigraphy. *RöFo* 1990;**152**(5):523-7.

**Berthold 1990** {published data only}

Berthold F, Waters W, Sieverts H, Linden A. Immunoscintigraphic imaging of MIBG-negative metastases in neuroblastoma. *American Journal of Pediatric Hematology/Oncology* 1990;**12**(1):61-2.

**Bian 2009** {published data only}

Bian X, Wang Z-C, Xian J-F, Li M, Yan F, Chen Q-H, et al. The imaging findings of metastatic neuroblastoma in the craniofacial bone in children. *Chinese Journal of Radiology* 2009;**43**:258-61.

**Biersack 2010** {published data only}

Biersack HJ. Guest editorial. *Seminars in Nuclear Medicine* 2010;**40**(2):77.

**Binderup 2010** {published data only}

Binderup T, Knigge U, Loft A, Federspiel B, Kjaer A. 18F-fluorodeoxyglucose positron emission tomography predicts survival of patients with neuroendocrine tumors. *Clinical Cancer Research* 2010;**16**(3):978-85.

**Bomanji 1987** {published data only}

Bomanji J, Levison DA, Flatman WD, Horne T, Bouloux PM, Ross G, et al. Uptake of iodine-123 MIBG by pheochromocytomas, paragangliomas, and neuroblastomas: a histopathological comparison. *Journal of Nuclear Medicine* 1987;**28**(6):973-8.

**Bomanji 1988** {published data only}

Bomanji J, Conry BG, Britton KE, Reznick RH. Imaging neural crest tumours with 123I-metaiodobenzylguanidine and X-ray computed tomography: a comparative study. *Clinical Radiology* 1988;**39**(5):502-6.

**Bomanji 1991** {published data only}

Bomanji J, Moyes J, Huneidi AHS, Solanki K, Hawkins L, Nimmon CC, et al. Cerebral uptake of MIBG: adrenoceptors visualized?. *Nuclear Medicine Communications* 1991;**12**(1):3-13.

**Bombardieri 2003a** {published data only}

Bombardieri E. Foreword. *Quarterly Journal of Nuclear Medicine* 2003;**47**:1-2.

**Bönisch 1994** {published data only}

Bönisch H, Brüß M. The noradrenaline transporter of the neuronal plasma membrane. *Annals of the New York Academy of Sciences* 1994;**733**:193-202.

**Bonnin 1994** {published data only}

Bonnin F, Lumbroso J, Tenenbaum F, Hartmann O, Parmentier C. Refining interpretation of MIBG scans in children. *Journal of Nuclear Medicine* 1994;**35**(5):803-10.

**Bourliere 1992** {published data only}

Bourliere Najean B, Siles S, Panuel M, Cammilleri S, Faure F, Devred P, et al. Value of MRI and MIBG-1123 scintigraphy in the diagnosis of spinal bone marrow involvement in neuroblastoma in children. *Pediatric Radiology* 1992;**22**(6):443-6.

**Brandon 2011** {published data only}

Brandon D, Alazraki A, Halkar RK, Alazraki NP. The role of single-photon emission computed tomography and SPECT/computed tomography in oncologic imaging. *Seminars in Oncology* 2011;**38**(1):87-108.

**Brendel 1986** {published data only}

Brendel AJ, Lambert B, Guyot M. Radioiodine-labelled metaiodobenzylguanidine (MIBG) for scintigraphic detection and treatment of pheochromocytomas and neuroblastomas [French]. *Semaine des Hopitaux* 1986;**62**(44):3567-72.

**Brisse 2009** {published data only}

Brisse HJ. Staging of common paediatric tumours. *Pediatric Radiology* 2009;**39**(Suppl 3):S482-90.

**Britton 1997** {published data only}

Britton KE. Positive MIBG scanning at the time of relapse in neuroblastoma which was MIBG negative at diagnosis. *British Journal of Radiology* 1997;**70**(837):969.

**Brodeur 1993** {published data only}

Brodeur GM, Pritchard J, Berthold F, Carlsen NL, Castel V, Castelberry RP, et al. Revisions of the international criteria for neuroblastoma diagnosis, staging, and response to treatment. *Journal of Clinical Oncology* 1993;**11**(8):1466-77.

**Brunklaus 2012** {published data only}

Brunklaus A, Pohl K, Zuberi SM, de Sousa C. Investigating neuroblastoma in childhood opsoclonus-myoclonus syndrome. *Archives of Disease in Childhood* 2012;**97**(5):461-3.

**Brunklaus 2012a** {published data only}

Brunklaus A, Pohl K, Zuberi SM, de Sousa C. Investigating neuroblastoma in childhood opsoclonus-myoclonus syndrome. *Archives of Disease in Childhood* 2012;**97**(5):461-3.

**Buck 2008** {published data only}

Buck AK, Nekolla S, Ziegler S, Beer A, Krause BJ, Herrmann K, et al. SPECT/CT. *Journal of Nuclear Medicine* 2008;**49**(8):1305-19.

**Calisti 2012** {published data only}

Calisti A, Oriolo L, Molle P, Miele V, Spagnol L. Neonatal adrenal masses: do we have reliable criteria for differential diagnosis and expectant management?. *Minerva Pediatrica* 2012;**64**(3):313-8.

**Carachi 2002** {published data only}

Carachi R. Perspectives on neuroblastoma. *Pediatric Surgery International* 2002;**18**(5-6):299-305.

**Caravel 2001** {published data only}

Caravel JP, Giammarile F. Scintiscans of neuroblastomas with meta-iodobenzylguanidine (MIBG) [French]. *Medecine Nucleaire* 2001;**25**(4):213-4.

**Castel 2006** {published data only}

Castel V, Grau E. Advances in neuroblastoma research. *Clinical and Translational Oncology* 2006;**8**(10):701-2.

**Cedenkayevna 2011** {published data only}

Cedenkayevna Bembeeva R, Ilyina E, Nikolayevich Zavadenko N, Stepanovna Ilyina E. Diagnosis of paraneoplastic opsoclonus-myoclonus syndrome in children. 9th Congress of the European Paediatric Neurology Society, EPNS; 2011 May 11-14; Cavtat, Croatia. *European Journal of Paediatric Neurology*. 2011:S55.

**Chan 2001** {published data only}

Chan GC, Leung YL, Shing MM, Luk CW, Ling SC, Lee AC. Does a "false negative" MIBG scan predict a better outcome in neuroblastoma patients?. *Medical and Pediatric Oncology* 2001;**37**(2):155.

**Chan 2001a** {published data only}

Chan GCF, Leung YL, Shing MMK, Luk CW, Ling SC, Lee ACW. Letter to the editor: Does a "false negative" MIBG scan predict a better outcome in neuroblastoma patients?. *Medical and Pediatric Oncology* 2001;**37**(2):155.

**Chatal 1984** {published data only}

Chatal JF, Coornaert S, Rialland X. Diagnostic scintigraphy of neuroblastomas with <sup>123</sup>I-labeled (3-iodobenzyl)guanidine [French]. *Journal de Biophysique et Médecine Nucléaire* 1984;**8**(2-3):156-7.

**Chu 2011** {published data only}

Chu CM, Rasalkar DD, Hu YJ, Cheng FWT, Li CK, Chu WCW. Clinical presentations and imaging findings of neuroblastoma beyond abdominal mass and a review of imaging algorithm. *British Journal of Radiology* 2011;**84**(997):81-91.

**Clarke 2001** {published data only}

Clarke SEM. Advances in radionuclide imaging: radionuclide imaging as a guide to therapy. *Imaging* 2001;**13**(3):171-84.

**Corbett 1991a** {published data only}

Corbett R, Fullbrook A, Meller S, Flower M. 123iodine meta-iodobenzylguanidine single photon emission computed tomography in the assessment of children with neuroblastoma. *Progress in Clinical and Biological Research* 1991;**366**:479-85.

**Corbett 1991b** {published data only}

Corbett R, Olliff J, Fairley N, Moyes J, Husband J, Pinkerton R, et al. A prospective comparison between magnetic resonance imaging, meta-iodobenzylguanidine scintigraphy and marrow histology/cytology in neuroblastoma. *European Journal of Cancer* 1991;**27**(12):1560-4.

**Dabasi 1989** {published data only}

Dabasi G, Duffek L. Scintigraphy of the adrenergic nervous system [Hungarian]. *Orvosi Hetilap* 1989;**130**(7):327-31.

**Dalmau 2008** {published data only}

Dalmau J, Rosenfeld MR. Paraneoplastic syndromes of the CNS. *Lancet Neurology* 2008;**7**(4):327-40.

**Dessner 1993** {published data only}

Dessner DA, DiPietro MA, Shulkin BL. MIBG detection of hepatic neuroblastoma: correlation with CT, US and surgical findings. *Pediatric Radiology* 1993;**23**(4):276-80.

**Dhir 2010** {published data only}

Dhir S, Wheeler K. Neonatal neuroblastoma. *Early Human Development* 2010;**86**(10):601-5.

**Díez 2006** {published data only}

Díez Jiménez L, Mitjavila Casanovas M. MIBG scintigraphy in neuroblastoma: Something more than an image [Spanish]. *Revista Española de Medicina Nuclear* 2006;**25**(2):118-43.

**Dirisamer 2008** {published data only}

Dirisamer A, Halpern BS, Schima W, Heinisch M, Wolf F, Beheshti M, et al. Dual-time-point FDG-PET/CT for the detection of hepatic metastases. *Molecular Imaging and Biology* 2008;**10**(6):335-40.

**Durak 2002** {published data only}

Durak H, Cuocolo A. 5th International Congress of Nuclear Oncology and 15th National Congress of Turkish Society of

Nuclear Medicine Kusadasi, Turkey, 1-5 May 2002. *Expert Review of Anticancer Therapy* 2002;**2**(4):361-3.

**Eckelman 2007** {published data only}

Eckelman WC, Vera DR. After bench to bedside: the impact of disease progression, commercial opportunities and available instrumentation on clinical outcome. *Nuclear Medicine and Biology* 2007;**34**(7):727-8.

**Edeling 1987** {published data only}

Edeling CJ, Frederiksen PB, Kamper J, Jeppesen P. Diagnosis and treatment of neuroblastoma using metaiodobenzylguanidine. *Clinical Nuclear Medicine* 1987;**12**(8):632-7.

**Ell 2006** {published data only}

Ell PJ. CME: Nuclear medicine. Editorial. *Clinical Medicine* 2006;**6**(3):239.

**Fischer 1993** {published data only}

Fischer M, Löhmer H. Nuclear medicine diagnosis of adrenal gland diseases. *Der Urologe A* 1993;**32**(2):128-32.

**Franzius 2006** {published data only}

Franzius C, Hermann K, Weckesser M, Kopka K, Juergens KU, Vormoor J, et al. Whole-body PET/CT with 11C-meta-hydroxyephedrine in tumors of the sympathetic nervous system: feasibility study and comparison with 123I-MIBG SPECT/CT. *Journal of Nuclear Medicine* 2006;**47**(10):1635-42.

**Franzius 2009** {published data only}

Franzius C, Juergens KU. PET/CT in paediatric oncology: Indications and pitfalls. *Pediatric Radiology* 2009;**39**(Suppl 3):S446-9.

**Frappaz 2000** {published data only}

Frappaz D, Bonneu A, Chauvot P, Edeline V, Giammarile F, Siles S, et al. Metaiodobenzylguanidine assessment of metastatic neuroblastoma: observer dependency and chemosensitivity evaluation. The SFOP Group. *Medical and Pediatric Oncology* 2000;**34**(4):237-41.

**Frappaz 2004** {published data only}

Frappaz D, Combaret V, Desuzinges C, Bouffet E, Bailly C, Favrot MC, et al. Can MIBG scan replace the need for bone marrow assessment at diagnosis and reassessment in stage 4 neuroblastomas?. *Bulletin du Cancer* 2004;**91**(7-8):E253-60.

**Freeman 2007** {published data only}

Freeman LM, Blaufox MD. Letter from the editors. *Seminars in Nuclear Medicine* 2007;**37**(3):241.

**Freeman 2011** {published data only}

Freeman LM, Blaufox MD. Letter from the editors. *Seminars in Nuclear Medicine* 2011;**41**(5):323.

**Fukuoka 2011** {published data only}

Fukuoka M, Taki J, Mochizuki T, Kinuya S. Comparison of diagnostic value of I-123 MIBG and high-dose I-131 MIBG scintigraphy including incremental value of SPECT/CT over planar image in patients with malignant pheochromocytoma/

paraganglioma and neuroblastoma. *Clinical Nuclear Medicine* 2011;**36**(1):1-7.

**Fukuoka 2011a** {published data only}

Fukuoka M, Taki J, Mochizuki T, Kinuya S. Comparison of diagnostic value of I-123 MIBG and high-dose I-131 MIBG scintigraphy including incremental value of SPECT/CT over planar image in patients with malignant pheochromocytoma/ paraganglioma and neuroblastoma. *Clinical Nuclear Medicine* 2011;**36**(1):1-7.

**Garaventa 2001** {published data only}

Garaventa A. Does a "false-negative" MIBG scan predict a better outcome in neuroblastoma patients?. *Medical and Pediatric Oncology* 2001;**37**(4):418.

**Garaventa 2008** {published data only}

Garaventa A, Sorrentino S. The neuroblastoma. *Haematologica Meeting Reports* 2008;**2**:47-9.

**García-Peña 2010** {published data only}

García-Peña P, Barber I. Pathology of the thoracic wall: Congenital and acquired. *Pediatric Radiology* 2010;**40**(6):859-68.

**Giammarile 1998** {published data only}

Giammarile F, Bohdiewicz PJ. The MIBG super scan (multiple letters) [2]. *Pediatric Radiology* 1998;**28**:487.

**Giammarile 2000** {published data only}

Giammarile F, Boneu A, Edeline V, Lumbroso J, Siles S, Wioland M. Guide lines for mIBG scintigraphy in paediatric onlogy [French]. *Medecine Nucleaire* 2000;**24**:35-42.

**Gilday 1990** {published data only}

Gilday DL, Greenberg M. The controversy about the nuclear medicine investigation of neuroblastoma. *Journal of Nuclear Medicine* 1990;**31**(2):135.

**Goo 2006** {published data only}

Goo HW. Reply [2]. *Pediatric Radiology* 2006;**36**:277-8.

**Gruner 1990** {published data only}

Gruner M, Larroquet M, Grapin C, Wioland M. Value of peroperative isotopic localization in some cases of neuroblastoma [French]. *Presse Médicale* 1990;**19**(42):1946.

**Guerra 1990** {published data only}

Guerra P. Diagnostic and therapeutic possibilities of metaiodobenzylguanidine in neuroblastoma [Italian]. *La Pediatria Medica e Chirurgica* 1990;**12**(6):663-8.

**Hahn 2003** {published data only}

Hahn K, Charron M, Shulkin BL. Role of MR imaging and iodine 123 MIBG scintigraphy in staging of pediatric neuroblastoma. *Radiology* 2003;**227**(3):908-9.

**Hahn 2004** {published data only}

Hahn K, Pfluger T. Has PET become an important clinical tool in paediatric imaging?. *European Journal of Nuclear Medicine and Molecular Imaging* 2004;**31**(5):615-21.



**Hammami 2007** {published data only}

Hammami H, Hassine L, Mhiri A, Sellem A, Oubich F, Gharssallah L, et al. Metaiodobenzylguanidine scintigraphy in the diagnosis and followup of neuroblastoma. Apropos of 16 cases [French]. *La Tunisie Médicale* 2007;**85**(5):413-6.

**Han 2007** {published data only}

Han SJ, Kim TS, Jeon SW, Jeong SJ, Yun M, Rhee Y, et al. Analysis of adrenal masses by 18F-FDG positron emission tomography scanning. *International Journal of Clinical Practice* 2007;**61**(5):802-9.

**Hattner 1988** {published data only}

Hattner RS. Metaiodobenzylguanidine in the diagnosis of pheochromocytoma and neuroblastoma. *Western Journal of Medicine* 1988;**148**(4):451.

**Hausegger 1989** {published data only}

Hausegger KA, Fueger GF, Ebner F, Urban C. Indications for MIBG scintigraphy in the diagnosis of neuroblastoma. *Nuklearmedizin* 1989;**28**(1):34-40.

**Haynie 1993** {published data only}

Haynie TP. Prognosis by nuclear medicine: Can functional staging of cancer patients predict therapeutic response and survival?. *Journal of Nuclear Medicine* 1993;**34**(7):1087-9.

**Hero 2001** {published data only}

Hero B, Hunneman DH, Gahr M, Berthold F. Evaluation of catecholamine metabolites, mIBG scan, and bone marrow cytology as response markers in stage 4 neuroblastoma. *Medical and Pediatric Oncology* 2001;**36**(1):220-3.

**Heston 2010** {published data only}

Heston TF. 123I-MIBG versus 18F-FDG: which is better, or which can be eliminated?. *Journal of Nuclear Medicine* 2010;**51**(2):330.

**Hildebrand 2007** {published data only}

Hildebrand J. Brain and nervous system. *Current Opinion in Oncology* 2007;**19**:596-7.

**Hoefnagel 1995** {published data only}

Hoefnagel CA. Specific diagnosis of neural crest tumours by MIBG scintigraphy. *Medecine Nucleaire* 1995;**19**:105-9.

**Ikekubo 1994** {published data only}

Ikekubo K, Hino M, Ootsuka H, Ito H, Yamaguchi H, Dan Y, et al. Detection of neural crest tumors by 123I-MIBG scintigraphy [Japanese]. *Kaku Igaku* 1994;**31**(11):1357-64.

**Jacobs 1990a** {published data only}

Jacobs A, Delrée M, Desprechins B, Otten J, Jonckheer MH, Mertens J, et al. Diagnostic use of I-MIBG in child neuroblastoma [Dutch]. *Journal Belge de Radiologie* 1990;**73**(3):173-9.

**Jadvar 2005** {published data only}

Jadvar H, Alavi A, Mavi A, Shulkin BL. PET in pediatric diseases. *Radiologic Clinics of North America* 2005;**43**(1):135-52.

**Jofré 2007** {published data only}

Jofré MMJ, Massardo VT, Canessa GJ, Sierralta CP, González EP, Humeres AP, et al. Utility of positron emission tomography in pediatric oncology. *Revista Chilena de Pediatría* 2007;**78**:301-10.

**Kairemo 1998** {published data only}

Kairemo KJ, Jekunen AP, Kestilä MS, Ramsay HA. Imaging of olfactory neuroblastoma--an analysis of 17 cases. *Auris, Nasus, Larynx* 1998;**25**(2):173-9.

**Kaste 2008a** {published data only}

Kaste SC. 18F-PET-CT in extracranial paediatric oncology: When and for whom is it useful?. *Pediatric Radiology* 2008;**38**(Suppl 3):S459-66.

**Kaste 2008b** {published data only}

Kaste SC, McCarville MB. Imaging pediatric abdominal tumors. *Seminars in Roentgenology* 2008;**43**(1):50-9.

**Keidar 2003** {published data only}

Keidar Z, Israel O, Krausz Y. SPECT/CT in tumor imaging: technical aspects and clinical applications. *Seminars in Nuclear Medicine* 2003;**33**(3):205-18.

**Kim 2006** {published data only}

Kim S, Chung DH. Pediatric solid malignancies: neuroblastoma and Wilms' tumor. *Surgical Clinics of North America* 2006;**86**(2):469-87.

**Kimmig 1984** {published data only}

Kimmig B, Brandeis WE, Eisenhut M, Bubeck B. Specific scintigraphy of neuroblastoma with meta-iodobenzylguanidine. *NUC Compact* 1984;**15**:42-8.

**Kimmig 1985a** {published data only}

Kimmig B, Brandeis WE, Adolph J. Diagnosis and treatment control of neuroblastoma with meta-iodine-benzylguanidine [German]. *Deutsche Medizinische Wochenschrift* 1985;**110**(5):175-9.

**Kimmig 1985b** {published data only}

Kimmig B, Brandeis WE, Eisenhut M. Scintiscan imaging of benign and malignant tumours of the sympathetic nervous system via metaiodine-benzyl-guanidine [German]. *Röntgen-Blätter* 1985;**38**(5):154-8.

**Kimmig 1985c** {published data only}

Kimmig B, Brandeis WE, Eisenhut M, Bubeck B, Georgi P. Scintigraphic imaging of benign and malignant tumors of the sympathetic nervous system with meta-iodobenzylguanidine [German]. *Röntgen-Blätter* 1985;**38**(5):154-8.

**Kleis 2009** {published data only}

Kleis M, Daldrup-Link H, Matthay K, Goldsby R, Lu Y, Schuster T, et al. Diagnostic value of PET/CT for the staging and restaging of pediatric tumors. *European Journal of Nuclear Medicine and Molecular Imaging* 2009;**36**(1):23-36.

**Klingebiel 1992** {published data only}

Klingebiel T, Reuland P, Feine U, Niethammer D. Follow-up evaluation of metastatic neuroblastoma using high dose

[131I-meta]iodobenzylguanidine [German]. *Nuklearmedizin* 1992;**31**(6):209-12.

**Knight 1996** {published data only}

Knight SB, Delbeke D, Stewart JR, Sandler MP. Evaluation of pulmonary lesions with FDG-PET. Comparison of findings in patients with and without a history of prior malignancy. *Chest* 1996;**109**(4):982-8.

**Koizumi 1994** {published data only}

Koizumi M, Sawada H, Goto M, Iijima A, Watari T, Kurosawa H, et al. 123I-MIBG scintigraphy in patients with neuroblastoma. *Kaku Igaku* 1994;**31**(5):507-11.

**Krausz 2006** {published data only}

Krausz Y, Israel O. Single-photon emission computed tomography/computed tomography in endocrinology. *Seminars in Nuclear Medicine* 2006;**36**(4):267-74.

**Kroiss 2011** {published data only}

Kroiss A, Putzer D, Uprimny C, Decristoforo C, Gabriel M, Santner W, et al. Functional imaging in pheochromocytoma and neuroblastoma with 68Ga-DOTA-Tyr 3-octreotide positron emission tomography and 123I-metaiodobenzylguanidine. *European Journal of Nuclear Medicine and Molecular Imaging* 2011;**38**(5):865-73.

**Kroiss 2012** {published data only}

Kroiss A, Putzer D, Uprimny C, Decristoforo C, Gabriel M, Santner W, et al. Functional imaging in pheochromocytoma and neuroblastoma with 68Ga-DOTA-Tyr3-octreotide positron emission tomography and 123I-metaiodobenzylguanidine: a clarification. *European Journal of Nuclear Medicine and Molecular Imaging* 2012;**39**(3):543.

**Kumar 1988** {published data only}

Kumar R, David R, Sayle BA, Lamki LM. Adrenal scintigraphy. *Seminars in Roentgenology* 1988;**23**(4):243-9.

**Kumar 2008** {published data only}

Kumar J, Seith A, Kumar A, Sharma R, Bakhshi S, Kumar R, et al. Whole-body MR imaging with the use of parallel imaging for detection of skeletal metastases in pediatric patients with small-cell neoplasms: Comparison with skeletal scintigraphy and FDG PET/CT. *Pediatric Radiology* 2008;**38**(9):953-62.

**Kumar 2010** {published data only}

Kumar A, Mayank M, Kandedia M, Mistry Y. Usefulness of whole body FDG18 PET-CT imaging in comprehensive oncologic management-initial experience. *Journal of Cancer Research and Therapeutics* 2010;**6**(3):290-5.

**Kumar 2011** {published data only}

Kumar R, Hawkins RA, Yeh BM, Wang ZJ. Focal fluorine-18 fluorodeoxyglucose-avid lesions without computed tomography correlate at whole-body positron emission tomography-computed tomography in oncology patients: How often are they malignant?. *Nuclear Medicine Communications* 2011;**32**(9):802-7.

**Kushner 2001** {published data only}

Kushner BH, Yeung HW, Larson SM, Kramer K, Cheung N-K. Extending Positron Emission Tomography scan utility to high-risk Neuroblastoma: Fluorine-18 Fluorodeoxyglucose Positron Emission Tomography as sole imaging modality in follow-up of patients. *Journal of Clinical Oncology* 2001;**19**(14):3397-405.

**Kushner 2006** {published data only}

Kushner BH, Cheung NK. Exploiting the MIBG-avidity of neuroblastoma for staging and treatment. *Pediatric Blood and Cancer* 2006;**47**(7):863-4.

**Kushner 2009a** {published data only}

Kushner BH, Kramer K, Modak S, Cheung NK. Reply to K. Satharasinghe et al. *Journal of Clinical Oncology* 2009;**27**:e235.

**Kushner 2009b** {published data only}

Kushner BH, Kramer K, Modak S, Cheung NK. Sensitivity of surveillance studies for detecting asymptomatic and unsuspected relapse of high-risk neuroblastoma. *Journal of Clinical Oncology* 2009;**27**(7):1041-6.

**Ladenstein 1993** {published data only}

Ladenstein R, Lasset C, Hartmann O, Garaventa A, Philip T. High-dose consolidation chemotherapy in infants with stage 4 neuroblastoma. *European Journal of Cancer Part A: General Topics* 1993;**29A**(11):1632.

**Ladenstein 2011** {published data only}

Ladenstein R, Potschger U, Boubaker A, Bar-Sever Z, Staudenherz A, Castellani MR, et al. The prognostic value of semi-quantitative I-123 mibg scintigraphy at diagnosis in high risk neuroblastoma: Validation of the SIOPEN score method. Jahrestagung der Österreichischen Gesellschaft für Kinder- und Jugendheilkunde; 2011 Nov 06-08; Villach Austria. *Monatsschrift für Kinderheilkunde*. 2011:328-9.

**Ladenstein 2012** {published data only}

Ladenstein R, Bomanji J, Hoffmann M, Forjaz De Lacerda A, Saran F, et al. Peripheral blood stem cell transplant to support dosimetry guided higher dose molecular radiotherapy with co-administration of topotecan as a radiosensitizer for metastatic neuroblastoma. A SIOPEN study. 38th Annual Meeting of the European Group for Blood and Marrow Transplantation, EBMT; 2012 April 01-04; Geneva. *Bone Marrow Transplantation*. 2012:S40.

**Larcos 1996** {published data only}

Larcos G, Maisey MN. FDG-PET screening for cerebral metastases in patients with suspected malignancy. *Nuclear Medicine Communications* 1996;**17**(3):197-8.

**Lastoria 1993** {published data only}

Lastoria S, Caraco C, Maurea S, Piroli C, Maurelli L, Vergara E, et al. Evaluation of orbital involvement by neuroblastoma using radiolabeled metaiodobenzylguanidine. *Italian Journal of Ophthalmology* 1993;**7**:147-52.

**Le Néel 1991** {published data only}

Le Néel JC, Bourseau JC, Guiberteau B, Kohen M, Borde L. Incidentally discovered adrenal tumors. Apropos of 20 cases [French]. *Chirurgie* 1991;**117**(5-6):405-11.

**Lesslie 2007** {published data only}

Lesslie M, Chasen MH, Munden RF. Imaging of the mediastinum in oncology. *Applied Radiology* 2007;**36**:8-19.

**Leung 1997** {published data only}

Leung A, Shapiro B, Hattner R, Kim E, de Kraker J, Ghazzar N, et al. Specificity of radioiodinated MIBG for neural crest tumors in childhood. *Journal of Nuclear Medicine* 1997;**38**(9):1352-7.

**Lewington 2009** {published data only}

Lewington V, Bar-Sever Z, Lynch T, McEwan AJB, Giammarile F, Staudenherz A, et al. Development of a semi-quantitative MIBG reporting method. 41st Annual Conference of the International Society of Paediatric Oncology SIOP; 2009 October 05-09; São Paulo. *Pediatric Blood and Cancer* 2009;**53**(5):808.

**Lewington 2011** {published data only}

Lewington V, Poetschger U, Boubaker A, Bar-Sever Z, Drake B, Staudenherz A, et al. The prognostic value of semi-quantitative 123I mIBG scintigraphy at diagnosis in high-risk neuroblastoma: Validation of the SIOPEN score method. *Journal of Clinical Oncology* 2011;**29**(Suppl):Abstract 9511.

**Ley 2011** {published data only}

Ley S, Ley-Zaporozhan J, Günther P, Deubzer HE, Witt O, Schenk J-P. Neuroblastoma imaging. *RöFo: Fortschritte auf dem Gebiet der Röntgenstrahlen und der Bildgebenden Verfahren* 2011;**183**(3):217-25.

**Limouris 1997** {published data only}

Limouris GS, Giannakopoulos V, Stavraka A, Toubanakis N, Vlahos L. Comparison of In-111 pentetretotide, Tc-99m (V)DMSA and I-123 mIBG scintigraphy in neural crest tumors. *Anticancer Research* 1997;**17**(3B):1589-92.

**Lucignani 2011** {published data only}

Lucignani G, De Palma D. PET/CT in paediatric oncology: clinical usefulness and dosimetric concerns. *European Journal of Nuclear Medicine and Molecular Imaging* 2011;**38**(1):179-84.

**Lumbroso 1988a** {published data only}

Lumbroso J, Guermazi F, Hartmann O, Coornaert S, Rabarison Y, Lemerle J, et al. Sensitivity and specificity of meta-iodobenzylguanidine (mIBG) scintigraphy in the evaluation of neuroblastoma: analysis of 115 cases [French]. *Bulletin du Cancer* 1988;**75**(1):97-106.

**Lumbroso 1990** {published data only}

Lumbroso J, Schlumberger M. Clinical applications of radio-labelled mIBG [French]. *La Revue du Praticien* 1990;**40**(2):140-2.

**Ma 2007** {published data only}

Ma JJ, Kang BK, Treves ST. Pediatric musculoskeletal nuclear medicine. *Seminars in Musculoskeletal Radiology* 2007;**11**(4):322-34.

**Mastrangelo 1987** {published data only}

Mastrangelo R, D'Angio GJ. Summary of discussion, conclusions, and recommendations: MIBG symposium. *Medical and Pediatric Oncology* 1987;**15**:227-9.

**Matheja 2001** {published data only}

Matheja P, Schober O. 123I-IMT SPET: introducing another research tool into clinical neuro-oncology?. *European Journal of Nuclear Medicine* 2001;**28**(1):1-4.

**Matthay 2003a** {published data only}

Matthay KK, Brisse H, Couanet D, Couturier J, Bénard J, Mosseri V, et al. Central nervous system metastases in neuroblastoma: radiologic, clinical, and biologic features in 23 patients. *Cancer* 2003;**98**(1):155-65.

**Matthay 2003b** {published data only}

Matthay KK, Edeline V, Lumbroso J, Tanguy ML, Asselain B, Zucker JM, et al. Correlation of early metastatic response by 123I-metaiodobenzylguanidine scintigraphy with overall response and event-free survival in stage IV neuroblastoma. *Journal of Clinical Oncology* 2003;**21**(13):2486-91.

**McCloskey 2010** {published data only}

McCloskey P, Moran M, Stewart DP, Primrose WJ, Napier S, Hughes SJ. The role of FDG PET-CT in diagnosis and management of olfactory neuroblastoma. 15th Congress of the European Society of Surgical Oncology; 2010 Sept 15-17; Bordeaux. *European Journal of Surgical Oncology*. 2010, issue 9:833.

**McEwan 1986** {published data only}

McEwan AJ, Wyeth P, Ackery D. Radioiodinated iodobenzylguanidines for diagnosis and therapy. *International Journal of Radiation Applications and Instrumentation - part A* 1986;**37**(8):765-75.

**Melino 1989** {published data only}

Melino G. Intracellular uptake and accumulation of metaiodobenzylguanidine in neuroblastoma and small cell lung carcinoma cells. *Minerva Pediatrica* 1989;**41**(3):123-8.

**Melzer 2011** {published data only}

Melzer HI, Coppenrath E, Schmid I, Albert MH, von Schweinitz D, Tudball C, et al. <sup>123</sup>I-MIBG scintigraphy/SPECT versus <sup>18</sup>F-FDG PET in paediatric neuroblastoma. *European Journal of Nuclear Medicine and Molecular Imaging* 2011;**38**(9):1648-58.

**Mena Bares 2009** {published data only}

Mena Bares LM, Benítez Velazco A, Pérez Cuenca E, Maza Muret FR, Hidalgo Ramos FJ, Pacheco Capote C, et al. Utility of the scintigraphy with (123)I MIBG in the diagnosis of neuroblastoma bone metastasis [Spanish]. *Revista Española de Medicina Nuclear* 2009;**28**(4):208-9.

**Messa 1992** {published data only}

Messa C, Choi Y, Hoh CK, Jacobs EL, Glaspy JA, Rege S, et al. Quantification of glucose utilization in liver metastases: parametric imaging of FDG uptake with PET. *Journal of Computer Assisted Tomography* 1992;**16**(5):684-9.

**123I-MIBG scintigraphy and 18F-FDG-PET imaging for diagnosing neuroblastoma (Review)**

**Messina 2006** {published data only}

Messina JA, Cheng SC, Franc BL, Charron M, Shulkin B, To B, et al. Evaluation of semi-quantitative scoring system for metaiodobenzylguanidine (MIBG) scans in patients with relapsed neuroblastoma. *Pediatric Blood and Cancer* 2006;**47**(7):865-74.

**Miceli 1986** {published data only}

Miceli A, Nespoli L, Aprils C, Burgio GR. VMA-negative, MIBG scan-positive neuroblastoma in children. *European Journal of Pediatrics* 1986;**145**(4):325.

**Mitjavila 1991** {published data only}

Mitjavila M, Crespo A, Diez L. Possibilities in the diagnosis and in the therapy of the MIBG. *Oncologia* 1991;**14**:309-15.

**Mitjavila 2002** {published data only}

Mitjavila M. Nuclear Medicine Communications: Editorial. *Nuclear Medicine Communications* 2002;**23**(1):3-4.

**Mitty 1985** {published data only}

Mitty HA, Cohen BA. Adrenal imaging. *Urologic Clinics of North America* 1985;**12**(4):771-85.

**Montravers 1993** {published data only}

Montravers F, Coutris G, Sarda L, Mensch B, Talbot JN. Utility of thallium-201 and iodine-123 metaiodobenzylguanidine in the scintigraphic detection of neuroendocrine neoplasia. *European Journal of Nuclear Medicine* 1993;**20**(11):1070-7.

**Murphy 2008** {published data only}

Murphy JJ, Tawfeeq M, Chang B, Nadel H. Early experience with PET/CT scan in the evaluation of pediatric abdominal neoplasms. *Journal of Pediatric Surgery* 2008;**43**(12):2186-92.

**Nakai 1997** {published data only}

Nakai T, Takekoshi K, Yashiro T. Evaluation of adrenal medullary function with scintigraphy [Japanese]. *Nippon Rinsho* 1997;**55**(Suppl 2):372-5.

**Ng 1993** {published data only}

Ng YY, Kingston JE. The role of radiology in the staging of neuroblastoma. *Clinical Radiology* 1993;**47**(4):226-35.

**Nguyen 2010** {published data only}

Nguyen NC, Bhatla D, Osman MM. 123I-MIBG scintigraphy and 18F-FDG PET in neuroblastoma. *Journal of Nuclear Medicine* 2010;**51**(2):330-1.

**O'Hara 1999** {published data only}

O'Hara SM, Donnelly LF, Coleman RE. Pediatric body applications of FDG PET. *American Journal of Roentgenology* 1999;**172**(4):1019-24.

**Okuyama 2001** {published data only}

Okuyama C, Ushijima Y, Nakamura T, Kikkawa M, Nishimura T. Thallium-201 scintigraphy of neuroblastoma: Different results for primary tumors and skeletal lesions. *Annals of Nuclear Medicine* 2001;**15**(2):171-7.

**Okuyama 2002** {published data only}

Okuyama C, Ushijima Y, Kubota T, Nakamura T, Kikkawa M, Nishimura T. Utility of follow-up studies using meta-[123 I]iodobenzylguanidine scintigraphy for detecting recurrent neuroblastoma. *Nuclear Medicine Communications* 2002;**23**(7):663-72.

**Okuyama 2003** {published data only}

Okuyama C, Ushijima Y, Kubota T, Yoshida T, Nakai T, Kobayashi K, et al. 123I-Metaiodobenzylguanidine uptake in the nape of the neck of children: likely visualization of brown adipose tissue. *Journal of Nuclear Medicine* 2003;**44**(9):1421-5.

**Pein 1995** {published data only}

Pein F, Hartmann O, Sakiroglu C, Bayle C, Terrier-Lacombe MJ, Valteau-Couanet D, et al. Detection of bone marrow involvement in pediatric solid tumors as diagnosis. Methods, results, and interpretation [French]. *Archives de Pédiatrie* 1995;**2**(6):580-8.

**Peng 2010** {published data only}

Peng Y, Wang J. European Journal of Radiology: Editorial. *European Journal of Radiology* 2010;**75**(3):277-8.

**Perel 1999** {published data only}

Perel Y, Conway J, Kletzel M, Goldman J, Weiss S, Feyler A, et al. Clinical impact and prognostic value of metaiodobenzylguanidine imaging in children with metastatic neuroblastoma. *Journal of Pediatric Hematology Oncology* 1999;**21**(1):13-8.

**Petjak 1997** {published data only}

Petjak M, Tiel-van Buul MM, Staalman CR, Greve JC, de Kraker J, van Royen EA. Diagnostic imaging in abdominal neuroblastoma: is there a complementary role of MIBG-scintigraphy and ultrasonography?. *European Journal of Pediatrics* 1997;**156**(8):610-5.

**Pinto 2010** {published data only}

Pinto N, Abe H, Appelbaum D, Hara T, Pu Y, Shiraishi J, et al. Development of an automated quantitative method for scoring metaiodobenzylguanidine (MIBG) scans in patients with neuroblastoma. 23rd Annual Meeting of the American Society of Pediatric Hematology/Oncology, ASPHO; 2010 April 07-10; Montreal. *Pediatric Blood and Cancer* 2010;**54**(6):843.

**Plowman 1997** {published data only}

Plowman PN. Positive MIBG scanning at the time of relapse in neuroblastoma which was MIBG negative at diagnosis. *British Journal of Radiology* 1997;**70**(837):969.

**Priestley 1993** {published data only}

Priestley BL, Harrison CJ, Gerrard MP, Gibson A. Paediatrics - Part II. *Postgraduate Medical Journal* 1993;**69**(810):268-81.

**Pritchard 1988** {published data only}

Pritchard J, Gordon I, Lashford L, Dicks-Mireaux C. Specificity of iodobenzylguanidine scanning in neuroblastoma. *Lancet* 1988;**1**(8583):479.

**Pritchard 2002** {published data only}

Pritchard J. Re: Commentary by G.J. D'Angio to the article by S. Biasotti et al. *Medical and Pediatric Oncology* 2002;**38**(2):152.

**Quigley 2005** {published data only}

Quigley AM, Buscombe JR, Shah T, Gnanasegaran G, Roberts D, Caplin ME, et al. Intertumoural variability in functional imaging within patients suffering from neuroendocrine tumours. An observational, cross-sectional study. *Neuroendocrinology* 2005;**82**(3-4):215-20.

**Reavey 2010** {published data only}

Reavey HE, Alazraki A, Simoneaux S. Non-Lymphomatous tumors in pediatric PET/CT imaging: a pictorial guide. 53rd Annual Meeting and Postgraduate Course of the Society for Pediatric Radiology, SPR; 2010 April 14-17; Boston. *Pediatric Radiology* 2010;**40**(4):624-5.

**Regelink 2002** {published data only}

Regelink G, Brouwer J, de Bree R, Pruim J, van der Laan BF, Vaalburg W, et al. Detection of unknown primary tumours and distant metastases in patients with cervical metastases: value of FDG-PET versus conventional modalities. *European Journal of Nuclear Medicine and Molecular Imaging* 2002;**29**(8):1024-30.

**Reuland 2001** {published data only}

Reuland P, Geiger L, Thelen MH, Handgretinger R, Haase B, Müller-Schauenburg W, et al. Follow-up in neuroblastoma: comparison of metaiodobenzylguanidine and a chimeric anti-GD2 antibody for detection of tumor relapse and therapy response. *Journal of Pediatric Hematology Oncology* 2001;**23**(7):437-42.

**Robbins 2000** {published data only}

Robbins KT. Otolaryngology. *Journal of the American College of Surgeons* 2000;**190**(2):187-95.

**Roh 2008** {published data only}

Roh JL, Moon BJ, Kim JS, Lee JH, Cho KJ, Choi SH, et al. Use of 18F-fluorodeoxyglucose positron emission tomography in patients with rare head and neck cancers. *Clinical and Experimental Otorhinolaryngology* 2008;**1**(2):103-9.

**Rozovsky 2008** {published data only}

Rozovsky K, Koplewitz BZ, Krausz Y, Revel-Vilk S, Weintraub M, Chisin R, et al. Added value of SPECT/CT for correlation of MIBG scintigraphy and diagnostic CT in neuroblastoma and pheochromocytoma. *American Journal of Roentgenology* 2008;**190**(4):1085-90.

**Rubello 2007** {published data only}

Rubello D, Nanni C, Rampin L, Gross MD, Al-Nahhas A, Fanti S. Paediatric oncology: Role of 18F-fluorodeoxyglucose positron emission tomography/computerized tomography. *Journal of Organ Dysfunction* 2007;**3**:55-63.

**Rufini 1995** {published data only}

Rufini V, Giordano A, Di Giuda D, Petrone A, Deb G, De Sio L, et al. (123I)MIBG scintigraphy in neuroblastoma: a comparison between planar and SPECT imaging. *Quarterly Journal of Nuclear Medicine* 1995;**39**(4 Suppl 1):25-8.

**Rufini 1996** {published data only}

Rufini V, Fisher GA, Shulkin BL, Sisson JC, Shapiro B. Iodine-123-MIBG imaging of neuroblastoma: utility of SPECT and delayed imaging. *Journal of Nuclear Medicine* 1996;**37**(9):1464-8.

**Saadullah 2009** {published data only}

Saadullah M, Nawaz MK, Khan MU, Zaidi A, Maaz AUR. Clinical utility of I-131 MIBG scan in patients with neuroblastoma: 8 years experience. 39th Annual Scientific Meeting of the Australian and New Zealand Society of Nuclear Medicine; 2009 April 23-27; Sydney. *Internal Medicine Journal* 2009;**39**(S4):A128.

**Sano 2012** {published data only}

Sano Y, Okuyama C, Iehara T, Matsushima S, Yamada K, Hosoi H, et al. New semi-quantitative (123I)-MIBG estimation method compared with scoring system in follow-up of advanced neuroblastoma: utility of total MIBG retention ratio versus scoring method. *Annals of Nuclear Medicine* 2012;**26**(6):462-70.

**Sasajima 2006** {published data only}

Sasajima T, Kinouchi H, Naitoh Y, Tomura N, Watarai J, Mizoi K. <sup>123</sup>I-metaiodobenzylguanidine single-photon emission computerized tomography in brain tumors - A preliminary study. *Journal of Neuro-Oncology* 2006;**77**(2):185-91.

**Satharasinghe 2009** {published data only}

Satharasinghe K, Trahair TN, Barbaric D, O'Brien TA, Russell SJ, Cohn RJ, et al. False-positive MIBG scans with normal computed tomography imaging in patients with high-risk neuroblastoma. *Journal of Clinical Oncology* 2009;**27**(34):e233-4.

**Sauer 1985** {published data only}

Sauer J. <sup>123</sup>I-Metaiodobenzylguanidine (MBIG) for diagnosis of neuroblastoma. *NUC Compact* 1985;**16**:97-102.

**Sautter-Bihl 1991** {published data only}

Sautter-Bihl ML, Bihl H, Heinze HG. The place of 99mTc-MDP skeletal scintigraphy in neuroblastoma. Is a new assessment necessary? [German]. *Nuklearmedizin* 1991;**30**(1):7-12.

**Scanga 2004** {published data only}

Scanga DR, Martin WH, Delbeke D. Value of FDG PET imaging in the management of patients with thyroid, neuroendocrine, and neural crest tumors. *Clinical Nuclear Medicine* 2004;**29**(2):86-90.

**Schäffer 1991** {published data only}

Schäffer M, Fölsch UR. A new imaging procedure for detecting endocrine tumors [German]. *Zeitschrift für Gastroenterologie* 1991;**29**(4):173-4.

**Shammas 2009** {published data only}

Shammas A. Nuclear medicine imaging of the pediatric musculoskeletal system. *Seminars in Musculoskeletal Radiology* 2009;**13**(3):159-80.

**Shapiro 1990** {published data only}

Shapiro B, Fig LM, Gross MD, Khafagi F. Contributions of nuclear endocrinology to the diagnosis of adrenal tumors. *Recent Results in Cancer Research* 1990;**118**:113-38.

**Shapiro 1993** {published data only}

Shapiro B. Imaging of catecholamine-secreting tumours: uses of MIBG in diagnosis and treatment. *Baillière's Clinical Endocrinology and Metabolism* 1993;**7**(2):491-507.

**Shapiro 1994** {published data only}

Shapiro B, Shulkin BL, Hutchinson RJ, Bass JC, Gross MD, Sisson JC. Locating neuroblastoma in the opsoclonus-myoclonus syndrome. *Journal of Nuclear Biology and Medicine* 1994;**38**(4):545-55.

**Sharp 2008** {published data only}

Sharp SE, Gelfand MJ, Shulkin BL. PET/CT in the evaluation of neuroblastoma. *PET Clinics* 2008;**3**:551-61.

**Shulkin 1995** {published data only}

Shulkin BL, Mitchell DS, Ungar DR, Prakash D, Dole MG, Castle VP, et al. Neoplasms in a pediatric population: 2-[F-18]-fluoro-2-deoxy-D-glucose PET studies. *Radiology* 1995;**194**(2):495-500.

**Shulkin 1996** {published data only}

Shulkin BL, Hutchinson RJ, Castle VP, Yanik GA, Shapiro B, Sisson JC. Neuroblastoma: positron emission tomography with 2-[fluorine-18]-fluoro-2-deoxy-D-glucose compared with metaiodobenzylguanidine scintigraphy. *Radiology* 1996;**199**(3):743-50.

**Sisson 1986** {published data only}

Sisson JC, Wieland DM. Radiolabeled metaiodobenzylguanidine: pharmacology and clinical studies. *American Journal of Physiological Imaging* 1986;**1**(2):96-103.

**Sutton 1982** {published data only}

Sutton H, Green C, Wyeth P, Ackery D. Iodine labelled metaiodobenzyl guanidine (mIBG) in the localisation and treatment of malignant pheochromocytoma and neuroblastoma. *Nuclear Medicine Communications* 1982;**3**:101.

**Taggart 2009** {published data only}

Taggart DR, Han M, Quach A, Groshen S, Ye W, Villablanca J, et al. PET-18 FDG and 123 I-MIBG scans are complementary in assessing response for relapsed neuroblastoma patients. American Society of Pediatric Hematology/Oncology 22nd Annual Meeting; 2009 April 22-25; San Diego. *Pediatric Blood and Cancer* 2009;**52**(6):732-3.

**Tahir 2009** {published data only}

Tahir N, Ramsden WH, Scarsbrook AF. The impact of the new international staging of paediatric neuroblastoma on multi-modality imaging. European Society of Paediatric Radiology 46th Annual Meeting and 32nd Postgraduate Course; 2009 May 31-Jun 04; Istanbul. *Pediatric Radiology* 2009;**39**(3):S586.

**Troncione 1990** {published data only}

Troncione L, Rufini V, Montemaggi P, Danza FM, Lasorella A, Mastrangelo R. The diagnostic and therapeutic utility of radioiodinated metaiodobenzylguanidine (MIBG). 5 years of experience. *European Journal of Nuclear Medicine* 1990;**16**(4-6):325-35.

**Vanchieri 1993** {published data only}

Vanchieri C. European cancer center links basic and clinical science. *Journal of the National Cancer Institute* 1993;**85**(17):1370-1.

**Vatankulu 2011** {published data only}

Vatankulu B, Bozkurt MF, Ugur O. I-123 MIBG SPECT/CT hybrid imaging in evaluation of neuroectodermal tumors. Annual Congress of the European Association of Nuclear Medicine; 2011 October 15-19; Birmingham UK. *European Journal of Nuclear Medicine and Molecular Imaging*. 2011:S379.

**Volchenboum 2009** {published data only}

Volchenboum SL, Cohn SL. Progress in defining and treating high-risk neuroblastoma: Lessons from the bench and bedside. *Journal of Clinical Oncology* 2009;**27**(7):1003-4.

**Wang 2010** {published data only}

Wang L, Wang S, Taylor J. Typical and atypical radiological findings of neuroblastoma – A pictorial review. 61st Annual Scientific Meeting of the Royal Australian and New Zealand College of Radiologists, RANZCR; 2010 Oct 14-17; Perth. *Journal of Medical Imaging and Radiation Oncology* 2010;**Supplement 1**:A144.

**Weckesser 2009** {published data only}

Weckesser M. Molecular imaging with positron emission tomography in paediatric oncology-FDG and beyond. *Pediatric Radiology* 2009;**39**(Suppl 3):S450-5.

**Yang 2003** {published data only}

Yang M, Martin DR, Karabulut N, Frick MP. Comparison of MR and PET imaging for the evaluation of liver metastases. *Journal of Magnetic Resonance Imaging* 2003;**17**(3):343-9.

**Yanik 2010** {published data only}

Yanik GA, Parisi MT, Naranjo A, Matthay KK, London WB, McGrady PW, et al. MIBG scoring as a prognostic indicator in patients with stage IV neuroblastoma: A COG study. Annual Meeting of the American Society of Clinical Oncology, ASCO; 2010 June 04-08; Chicago. *Journal of Clinical Oncology* 2010;**28**:S9516.

**Ythier 1987** {published data only}

Ythier H, Marchandise X, Deveaux M, Venel H, Verney F, Mazingue F, et al. Results of scintigraphy with m-[123I]iodobenzylguanidine in neuroblastoma in children [Resultats de la scintigraphie a la m-[123I]iodobenzylguanidine dans le neuroblastome de l'enfant]. *International journal of radiation applications and instrumentation. Part B, Nuclear medicine and biology* 1987;**14**(2):107-12.

**Zerva 2005** {published data only}

Zerva CA. Prospects for nuclear medicine. *Hellenic Journal of Nuclear Medicine* 2005;**8**(1):37-8.

**Zhang 2009** {published data only}

Zhang J-H, Wang R-F. Application of radionuclide tracing technique in neuroblastoma. *Chinese Journal of Medical Imaging Technology* 2009;**25**:1518-21.

## References to studies awaiting assessment

### Abrahamsen 1995 {published data only}

Abrahamsen J, Lyck B, Helgestad J, Frederiksen PB. The impact of 123I-meta-iodobenzylguanidine scintigraphy on diagnostics and follow-up of neuroblastoma. *Acta Oncologica* 1995;**34**(4):505-10.

### Ady 1995 {published data only}

Ady N, Zucker JM, Asselain B, Edeline V, Bonnin F, Michon J, et al. A new 123I-MIBG whole body scan scoring method-- application to the prediction of the response of metastases to induction chemotherapy in stage IV neuroblastoma. *European Journal of Cancer* 1995;**31A**(2):256-61.

### Boubaker 2012 {published data only}

Boubaker A, Pötschger U, Lewington V, Bar-Sever Z, Lambert B, Oudoux A, et al. [The prognostic value of the SIOPEN skeletal scoring method in high-risk stage 4 neuroblastoma by semi-quantitative I-123-mIBGscintigraphy]. *Advances in Neuroblastoma Research*. 2012:102.

### Claudiani 1995 {published data only}

Claudiani F, Stimamiglio P, Bertolazzi L, Cabria M, Conte M, Villavecchia GP, et al. Radioiodinated meta-iodobenzylguanidine in the diagnosis of childhood neuroblastoma. *Quarterly Journal of Nuclear Medicine* 1995;**39**(4 Suppl 1):21-4.

### Fania 2011 {published data only}

Fania P, Quartuccio N, Asaftei S, Barat V, Postini AM, Bianchi M, et al. Comparing FDG-PET/CT with MIBG scans for staging of relapse stage IV high-risk neuroblastoma. Annual Congress of the European Association of Nuclear Medicine; 2011 October 15-19; Birmingham, UK. *European Journal of Nuclear Medicine and Molecular Imaging*. 2011:S252.

### Feine 1987 {published data only}

Feine U, Müller-Schauenburg W, Treuner J, Klingebiel T. Metaiodobenzylguanidine (MIBG) labeled with 123I/131I in neuroblastoma diagnosis and follow-up treatment with a review of the diagnostic results of the International Workshop of Pediatric Oncology held in Rome, September 1986. *Medical and Pediatric Oncology* 1987;**15**(4):181-7.

### Ferris 1992 {published data only}

Ferris Tortajada J, Caballero Carpena O, Tasso Cereceda MJ, Fernandez Navarro JM, Ruiz Soler JG, Esquembre Menor C, et al. Sensitivity of radiological and scintigraphical methods in detecting bone metastases in neuroblastoma. *Oncologia* 1992;**15**:168-72.

### Fischer 1989 {published data only}

Fischer M. Diagnosis and treatment of pheochromocytoma and neuroblastoma with meta-iodobenzylguanidine [German]. *Bildgebung/Imaging* 1989;**56**(4):141-5.

### Gelfand 1994 {published data only}

Gelfand MJ, Elgazzar AH, Kriss VM, Masters PR, Golsch GJ. Iodine-123-MIBG SPECT versus planar imaging in children

with neural crest tumors. *Journal of Nuclear Medicine* 1994;**35**(11):1753-7.

### Ginsburg 2012 {published data only}

Ginsburg M, Hall A, Pu Y, Penney BC, Volchenboum SL, Pinto N, et al. Comparison of 4- and 24-hour delayed planar and SPECT iodine-123 MIBG images for optimal detection of bony and soft tissue tumors in neuroblastoma. World Molecular Imaging Congress, WMIC; 2011 Sept 07-10; San Diego. *Molecular Imaging and Biology*. 2012:S358.

### Goo 2005 {published data only}

Goo HW, Choi SH, Ghim T, Moon HN, Seo JJ. Whole-body MRI of paediatric malignant tumours: comparison with conventional oncological imaging methods. *Pediatric Radiology* 2005;**35**(8):766-73.

### Hadj-Djilani 1995 {published data only}

Hadj-Djilani NL, Lebtahi N-E, Bischof Delaloye A, Laurini R, Beck D. Diagnosis and follow-up of neuroblastoma by means of iodine-123 metaiodobenzylguanidine scintigraphy and bone scan, and the influence of histology. *European Journal of Nuclear Medicine* 1995;**22**(4):322-9.

### Hervas 2001 {published data only}

Hervás Benito I, Rivas Sánchez A, Bello Arques P, Cañete A, Fernández JM, Saura Quiles A, et al. Value of 123I-MIBG scanning, neuron-specific enolase and serum ferritin in the diagnosis and follow-up of patients with neuroblastoma. *Revista Española de Medicina Nuclear* 2001;**20**(5):369-76.

### Ishii 2000 {published data only}

Ishii K, Kubo A, Kusakabe K, Murata H, Masaki H, Horiike S, et al. Evaluation of clinical utility of 123I-MIBG scintigraphy in localization of tumors of sympathetic and adrenomedullary origin - A report of multicenter phase III clinical trials [Japanese]. *Kaku Igaku* 2000;**37**(1):43-59.

### Jacobs 1990b {published data only}

Jacobs A, Delree M, Desprechins B, Otten J, Ferster A, Jonckheer MH, et al. Consolidating the role of \*I-MIBG-scintigraphy in childhood neuroblastoma: five years of clinical experience. *Pediatric Radiology* 1990;**20**(3):157-9.

### Kurkure 2012 {published data only}

Kurkure P, Vora T, Qureshi S, Ramadwar M, Laskar S, Medhi S, et al. F18 FDG PET/CT: A possible one stop shop for staging of neuroblastoma. *Pediatric Blood and Cancer*. 2012; Vol. 59:1052.

### Lumbroso 1988b {published data only}

Lumbroso JD, Guermazi F, Hartmann O, Coornaert S, Rabarison Y, Leclère JG, et al. Meta-iodobenzylguanidine (mIBG) scans in neuroblastoma: sensitivity and specificity, a review of 115 scans. *Progress in Clinical and Biological Research* 1988;**271**:689-705.

### Moschogiannis 2011 {published data only}

Moschogiannis VG, Gavrililei M, Lyra M. I-123 meta-iodo-benzyl-guanidine (MIBG) whole body scan in children with probable neuroblastoma. Our experience in subtraction technique and SPECT imaging. Annual Congress of the European Association

of Nuclear Medicine; 2011 October 15-19; Birmingham, UK. *European Journal of Nuclear Medicine and Molecular Imaging*. 2011;S392-3.

**Muckle 2012** {published data only}

Muckle M, Sabet A, Simon B, Ezziddin S, Dilloo D, Jürgen H, et al. The significance of iodine 123 MIBG SPECT/CT for the diagnosis and treatment planning in neuroblastoma. *Journal of Nuclear Medicine*. 2012; Vol. 53(S1):2209.

**Müller-Gärtner 1985** {published data only}

Müller-Gärtner HW, Erttmann R, Helmke K. Scintigraphy with radioiodinated meta-iodobenzylguanidine in the diagnosis of neuroblastoma [German]. *Nuklearmedizin* 1985;**24**(5-6):222-6.

**Muller-Gartner 1986** {published data only}

Müller-Gärtner HW, Erttmann R, Helmke K. Meta-iodobenzylguanidine scintigraphy in neuroblastoma--a comparison with conventional X-ray and ultrasound. *Pediatric Hematology and Oncology* 1986;**3**(2):97-109.

**Okuyama 1998** {published data only}

Okuyama C, Ushijima Y, Sugihara H, Okitsu S, Maeda T. 123I-metaiodobenzylguanidine (MIBG) scintigraphy for the staging of neuroblastoma [Japanese]. *Kaku Igaku* 1998;**35**(9):835-42.

**Okuyama 1999** {published data only}

Okuyama C, Ushijima Y, Watanabe K, Sugihara H, Nishimura T. Iodine-123-MIBG scintigraphy in neuroblastoma; relationship between the intensity of uptake and tumor characteristics [Japanese]. *Kaku Igaku* 1999;**36**(8):827-34.

**Osmanagaoglu 1993** {published data only}

Osmanagaoglu K, Lippens M, Benoit Y, Obrie E, Schelstraete K, Simons M. A comparison of iodine-123 meta-iodobenzylguanidine scintigraphy and single bone marrow aspiration biopsy in the diagnosis and follow-up of 26 children with neuroblastoma. *Euroepan Journal of Nuclear Medicine* 1993;**20**(12):1154-60.

**Paltiel 1994** {published data only}

Paltiel HJ, Gelfand MJ, Elgazzar AH, Washburn LC, Harris RE, Masters PR, et al. Neural crest tumors: I-123 MIBG imaging in children. *Radiology* 1994;**190**(1):117-21.

**Papathanasiou 2011** {published data only}

Papathanasiou ND, Gaze MN, Sullivan K, Aldridge M, Waddington W, Almuhaideb A, et al. 18F-FDG PET/CT and 123I-metaiodobenzylguanidine imaging in high-risk neuroblastoma: diagnostic comparison and survival analysis. *Journal of Nuclear Medicine* 2011;**52**(4):519-25.

**Parisi 1992** {published data only}

Parisi MT, Greene MK, Dykes TM, Moraldo TV, Sandler ED, Hattner RS. Efficacy of metaiodobenzylguanidine as a scintigraphic agent for the detection of neuroblastoma. *Investigative Radiology* 1992;**27**(10):768-73.

**Rathore 2011** {published data only}

Rathore B, Lazenby A, DeVries M, Murdoch N, Millerd P, Hankins J, et al. Neuroendocrine tumors: Findings on

octreoscan and mibg scan, with correlation to mri, ct and histopathology. American College of Nurse-Midwives, ACNM Annual Meeting; 2011 May 24-28; San Antonio, Texas. *Clinical Nuclear Medicine*. 2011:625.

**Sarkadi 2011** {published data only}

Sarkadi M, Schmidt E, Szabo Zs, Szekeres S, Derczy K, Weninger Cs, et al. Significance of SPECT/CT in MIBG examinations of children's neuroblastoma. 17th Congress of the Hevesy Gyorgy Hungarian Society of Nuclear Medicine; 2011 Aug 25-27; Budapest. *Nuclear Medicine Review*. 2011:A5-6.

**Schilling 2000** {published data only}

Schilling FH, Bihl H, Jacobsson H, Ambros PF, Martinsson T, Borgström P, et al. Combined (111)In-pentetreotide scintigraphy and (123)I-mIBG scintigraphy in neuroblastoma provides prognostic information. *Medical and Pediatric Oncology* 2000;**35**(6):688-91.

**Schmiegelow 1989** {published data only}

Schmiegelow K, Simes MA, Agertoft L, Berglund G, Storm-Mathisen I, Andreassen M, et al. Radio-iodobenzylguanidine scintigraphy of neuroblastoma: conflicting results, when compared with standard investigations. *Medical and Pediatric Oncology* 1989;**17**(2):127-30.

**Sharp 2009b** {published data only}

Sharp S, Gelfand M. Utility of SPECT/CT imaging in neuroblastoma. *Journal of Nuclear Medicine*. 2009; Vol. 50:200.

**Suc 1996** {published data only}

Suc A, Lumbroso J, Rubie H, Hattchouel JM, Boneu A, Rodary C, et al. Metastatic neuroblastoma in children older than one year: prognostic significance of the initial metaiodobenzylguanidine scan and proposal for a scoring system. *Cancer* 1996;**77**(4):805-11.

**Tahir 2011** {published data only}

Tahir N, Malghan L, Ramsden W. MIBG scanning and bone scintigraphy in the staging of neuroblastoma. Are both required? International Congress of Pediatric Radiology, IPR; 2011 May 28-31; London, UK. *Pediatric Radiology*. 2011:S417.

**Turba 1993** {published data only}

Turba E, Fagioli G, Mancini AF, Rosito P, Galli A, Alvisi P. Evaluation of stage 4 neuroblastoma patients by means of MIBG and 99mTc-MDP scintigraphy. *Journal of Nuclear Biology and Medicine* 1993;**37**(3):107-14.

**Vik 2009** {published data only}

Vik TA, Pflugger T, Kadota R, Castel V, Tulchinsky M, Farto JC, et al. (123)I-mIBG scintigraphy in patients with known or suspected neuroblastoma: Results from a prospective multicenter trial. *Pediatric Blood and Cancer* 2009;**52**(7):784-90.

**Yang 2012** {published data only}

Yang J, Codreanu I, Servaes S, Zhuang H. I-131 MIBG post-therapy scan is more sensitive than I-123 MIBG pretherapy scan in the evaluation of metastatic neuroblastoma. *Nuclear Medicine Communications* 2012;**33**(11):1134-7.

**123I-MIBG scintigraphy and 18F-FDG-PET imaging for diagnosing neuroblastoma (Review)**



**Young-Seok 2006** {published data only}

Young-seok C, Kyung-Han L, KiWoong S, Su Jin L, Hyun Woo C, Joon Young C, et al. Correlation of initial and post-therapy MIBGscintigraphy with bone scintigraphy and biological prognostic markers in stage IV neuroblastoma. *Journal of Nuclear Medicine*. 2006; Vol. 47(S1):353P.

**Additional references**
**Beiske 2009**

Beiske K, Burchill SA, Cheung IY, Hiyama E, Seeger RC, Cohn SL, et al. Consensus criteria for sensitive detection of minimal neuroblastoma cells in bone marrow, blood and stem cell preparations by immunocytology and QRT-PCR: recommendations by the International Neuroblastoma Risk Group Task Force. *British Journal of Cancer* 2009;**100**(10):1627-37.

**Bombardieri 2003b**

Bombardieri E, Aktolun C, Baum RP, Bishof-Delaloye A, Buscombe J, Chatal JF, et al. FDG-PET: procedure guidelines for tumour imaging. *European Journal of Nuclear Medicine and Molecular Imaging* 2003;**30**(12):BP115-24.

**Bombardieri 2003c**

Bombardieri E, Aktolun C, Baum RP, Bishof-Delaloye A, Buscombe J, Chatal JF, et al. 131I/123I-metaiodobenzylguanidine (MIBG) scintigraphy: procedure guidelines for tumour imaging. *European Journal of Nuclear Medicine and Molecular Imaging* 2003;**30**(12):BP132-9.

**Boubaker 2008**

Boubaker A, Bischof Delaloye A. MIBG scintigraphy for the diagnosis and follow-up of children with neuroblastoma. *Quarterly Journal of Nuclear Medicine and Molecular Imaging* 2008;**52**(4):388-402.

**Brodeur 1984**

Brodeur GM, Seeger RC, Schwab M, Varmus HE, Bishop JM. Amplification of N-myc in untreated human neuroblastomas correlates with advanced disease stage. *Science* 1984;**224**(4653):1121-4.

**Brodeur 1988a**

Brodeur GM, Fong CT, Morita M, Griffith R, Hayes FA, Seeger RC. Molecular analysis and clinical significance of N-myc amplification and chromosome 1p monosomy in human neuroblastomas. *Progress in Clinical and Biological Research* 1988;**271**:3-15.

**Brodeur 1988b**

Brodeur GM, Seeger RC, Barrett A, Berthold F, Castleberry RP, D'Angio G, et al. International criteria for diagnosis, staging, and response to treatment in patients with neuroblastoma. *Journal of Clinical Oncology* 1988;**6**(12):1874-81.

**Brodeur 2003**

Brodeur GM. Neuroblastoma: biological insights into a clinical enigma. *Nature Reviews Cancer* 2003;**3**(3):203-16.

**Castleberry 1997**

Castleberry RP. Neuroblastoma. *European Journal of Cancer* 1997;**33**(9):1430-7.

**Cohn 2009**

Cohn SL, Pearson AD, London WB, Monclair T, Ambros PF, Brodeur GM, et al. The International Neuroblastoma Risk Group (INRG) classification system: an INRG task force report. *Journal of Clinical Oncology* 2009;**27**(2):289-97.

**Decarolis 2013**

Decarolis B, Schneider C, Hero B, Simon T, Volland R, Roels F, et al. Iodine-123 metaiodobenzylguanidine scintigraphy scoring allows prediction of outcome in patients with stage 4 neuroblastoma: results of the Cologne interscore comparison study. *Journal of Clinical Oncology* 2013;**31**(7):944-51.

**Joshi 2000**

Joshi VV. Peripheral neuroblastic tumors: pathologic classification based on recommendations of international neuroblastoma pathology committee (Modification of shimada classification). *Pediatric and Developmental Pathology* 2000;**3**(2):184-99.

**Jüni 1999**

Jüni P, Witschi A, Bloch R, Egger M. The hazards of scoring the quality of clinical trials for meta-analysis. *JAMA* 1999;**282**(11):1061-83.

**Maris 2007**

Maris JM, Hogarty MD, Bagatell R, Cohn SL. Neuroblastoma. *Lancet* 2007;**369**(9579):2106-20.

**Maris 2010**

Maris JM. Recent advances in neuroblastoma. *New England Journal of Medicine* 2010;**362**(23):2202-11.

**Matthay 2010**

Matthay KK, Shulkin B, Ladenstein R, Michon J, Giammarile F, Lewington V, et al. Criteria for evaluation of disease extent by (123)I-metaiodobenzylguanidine scans in neuroblastoma: a report for the International Neuroblastoma Risk Group (INRG) Task Force. *British Journal of Cancer* 2010;**102**(9):1319-26.

**Monclair 2009**

Monclair T, Brodeur GM, Ambros PF, Brisse HJ, Cecchetto G, Holmes K, et al. The International Neuroblastoma Risk Group (INRG) staging system: an INRG Task Force report. *Journal of Clinical Oncology* 2009;**27**(2):298-303.

**Naranjo 2011**

Naranjo A, Parisi MT, Shulkin BL, London WB, Matthay KK, Kreissman SG, et al. Comparison of <sup>123</sup>I-metaiodobenzylguanidine (MIBG) and <sup>131</sup>I-MIBG semi-quantitative scores in predicting survival in patients with stage 4 neuroblastoma: a report from the Children's Oncology Group. *Pediatric Blood & Cancer* 2011;**56**(7):1041-5.

**Park 2008**

Park JR, Eggert A, Caron H. Neuroblastoma: biology, prognosis, and treatment. *Pediatric Clinics of North America* 2008;**55**(1):97-120.

**Peuchmaur 2003**

Peuchmaur M, d'Amore ES, Joshi VV, Hata J, Roald B, Dehner LP, et al. Revision of the International Neuroblastoma Pathology Classification: confirmation of favorable and unfavorable prognostic subsets in ganglioneuroblastoma, nodular. *Cancer* 2003;**98**(10):2274-81.

**Piccardo 2013**

Piccardo A, Lopci E, Conte M, Foppiani L, Garaventa A, Cabria A, et al. PET/CT imaging in neuroblastoma. *Quarterly Journal of Nuclear Medicine and Molecular Imaging* 2013;**57**(1):29-39.

**RevMan 2014 [Computer program]**

The Nordic Cochrane Centre, The Cochrane Collaboration. Review Manager (RevMan). Version 5.3. Copenhagen: The Nordic Cochrane Centre, The Cochrane Collaboration, 2014.

**SAS 9.1 2004 [Computer program]**

SAS Institute Inc.. Statistical Analysis System (SAS) 9.1. Cary, NC, USA: SAS Institute Inc., 2004..

**Shimada 1984**

Shimada H, Chatten J, Newton WA Jr, Sachs N, Hamoudi AB, Chiba T, et al. Histopathologic prognostic factors in neuroblastic tumors: definition of subtypes of ganglioneuroblastoma and an age-linked classification of neuroblastomas. *Journal of the National Cancer Institute* 1984;**73**(2):405-16.

**Shimada 1993**

Shimada H. Tumors of the neuroblastoma group. *Pathology (Philadelphia, Pa.)* 1993;**2**(1):43-59.

**Shimada 1999a**

Shimada H, Ambros IM, Dehner LP, Hata J, Joshi VV, Roald B. Terminology and morphologic criteria of neuroblastic tumors: recommendations by the International Neuroblastoma Pathology Committee. *Cancer* 1999;**86**(2):349-63.

**Shimada 1999b**

Shimada H, Ambros IM, Dehner LP, Hata J, Joshi VV, Roald B, et al. The International Neuroblastoma Pathology Classification (the Shimada system). *Cancer* 1999;**86**(2):364-72.

**Shimada 2003**

Shimada H. The International Neuroblastoma Pathology Classification. *Pathologica* 2003;**95**(5):240-1.

**Shore 2008**

Shore RM. Positron emission tomography/computed tomography (PET/CT) in children. *Pediatric Annals* 2008;**37**(6):404-12.

**Siegel 2013**

Siegel MJ, Acharyya S, Hoffer FA, Wyly JB, Friedmann AM, Snyder BS, et al. Whole-body MR imaging for staging of

malignant tumors in pediatric patients: results of the American College of Radiology Imaging Network 6660 Trial. *Radiology* 2013;**266**(2):599-609.

**Solanki 1992**

Solanki KK, Bomanji J, Moyes J, Mather SJ, Trainer PJ, Britton KE. A pharmacological guide to medicines which interfere with the biodistribution of radiolabelled meta-iodobenzylguanidine (MIBG). *Nuclear Medicine Communications* 1992;**13**(7):513-21.

**Spix 2006**

Spix C, Pastore G, Sankila R, Stiller CA, Steliarova-Foucher E. Neuroblastoma incidence and survival in European children (1978-1997): report from the Automated Childhood Cancer Information System project. *European Journal of Cancer* 2006;**42**(13):2081-91.

**Strenger 2007**

Strenger V, Kerbl R, Dornbusch HJ, Ladenstein R, Ambros PF, Ambros IM, et al. Diagnostic and prognostic impact of urinary catecholamines in neuroblastoma patients. *Pediatric Blood and Cancer* 2007;**48**(5):504-9.

**Taggart 2008**

Taggart D, Dubois S, Matthay KK. Radiolabeled metaiodobenzylguanidine for imaging and therapy of neuroblastoma. *Quarterly Journal of Nuclear Medicine and Molecular Imaging* 2008;**52**(4):403-18.

**Vaidyanathan 2008**

Vaidyanathan G. Meta-iodobenzylguanidine and analogues: chemistry and biology. *Quarterly Journal of Nuclear Medicine and Molecular Imaging* 2008;**52**(4):351-68.

**Whiting 2003**

Whiting P, Rutjes AW, Reitsma JB, Bossuyt PM, Kleijnen J. The development of QUADAS: a tool for the quality assessment of studies of diagnostic accuracy included in systematic reviews. *BMC Medical Research Methodology* 2003;**3**:25.

**Yalçın 2010**

Yalçın B, Kremer LC, Caron HN, van Dalen EC. High-dose chemotherapy and autologous haematopoietic stem cell rescue for children with high-risk neuroblastoma. *Cochrane Database of Systematic Reviews* 2010, Issue 5. [DOI: [10.1002/14651858.CD006301.pub2](https://doi.org/10.1002/14651858.CD006301.pub2)]

**Yalçın 2013**

Yalçın B, Kremer LCM, Caron HN, van Dalen EC. High-dose chemotherapy and autologous haematopoietic stem cell rescue for children with high-risk neuroblastoma. *Cochrane Database of Systematic Reviews* 2013, Issue 8. [DOI: [10.1002/14651858.CD006301.pub3](https://doi.org/10.1002/14651858.CD006301.pub3)]

**Yanik 2013**

Yanik GA, Parisi MT, Shulkin BL, Naranjo A, Kreissman SG, London WB, et al. Semiquantitative mIBG scoring as a prognostic indicator in patients with stage 4 neuroblastoma: a report from the Children's oncology group. *Journal of Nuclear Medicine* 2013;**54**(4):541-8.

## CHARACTERISTICS OF STUDIES

### Characteristics of included studies [ordered by study ID]

#### Biasotti 2000

Clinical features and settings	<p>Inclusion period: 1985 to 1998.</p> <p>Patient population: 196 children with suspected neuroblastoma prior to chemotherapy and surgery were included.</p> <p>Consecutive series: not reported.</p> <p>Diagnostic work-up: CT or MRI or both, <sup>123</sup>I-MIBG or <sup>99m</sup>Tc-MDP or both scans, one to four bone marrow aspirations and at least one bone marrow biopsy (limited to children ≥ 1 year of age), urinary catecholamines, serum ferritin, neuro specific enolase and lactate dehydrogenase.</p> <p>Time spans symptoms-index test, symptoms-reference standard and index test-reference standard: n.r.</p> <p>Treatment between index test-reference standard: n.r.</p>
Participants	<p>Included patients: 196 children with a neuroblastoma and <sup>123</sup>I-MIBG scan at first diagnosis.</p> <p>Median age at diagnosis: 31 months (range 8 to 65 months).</p> <p>Sex distribution: not reported.</p> <p>INSS stage: 38 stage 1 or 2, 50 stage 3, 95 stage 4 and 13 stage 4S.</p>
Study design	<p>Case series with pathologically proven neuroblastoma (histopathology not known at the time of MIBG-scintigraphy).</p>
Target condition and reference standard(s)	<p>Target condition: newly diagnosed neuroblastoma.</p> <p>Reference standard: histopathology according to Joshi nomenclature.</p>
Index and comparator tests	<p>Assessed primary objective 1.1: to determine the diagnostic accuracy of <sup>123</sup>I-MIBG (SPECT-CT) scintigraphy for detecting a neuroblastoma and its metastases at first diagnosis or at recurrence in children from 0 to 18 years old.</p> <p>Index test: <sup>123</sup>I-MIBG scintigraphy.</p> <p>Radiofarmacon: <sup>123</sup>I-MIBG.</p> <p>Dose: n.r.</p> <p>Collimator: n.r.</p> <p>Matrix: n.r.</p> <p>Acquisition protocol: n.r.</p> <p>Acquisition time: n.r.</p> <p>Acquisition duration: n.r.</p> <p>Interfering medication: n.r.</p> <p>Thyroid prophylaxis: n.r.</p> <p>Positive test result: pathologic <sup>123</sup>I-MIBG uptake.</p> <p>Number and expertise of observers: n.r.</p>

**Biasotti 2000** (Continued)

Interobserver concordance: n.r.

Follow-up Median follow-up: n.r.; for some patients: up to five years.

Notes

**Table of Methodological Quality**

Item	Authors' judgement	Description
Representative spectrum? All tests	Yes	Patients with a neuroblastoma at first diagnosis, age 8 to 65 months and stage distribution were reported.
Acceptable reference standard? All tests	Yes	Histopathology according to the Joshi nomenclature.
Acceptable delay between tests? All tests	Unclear	n.r.
Partial verification avoided? All tests	Unclear	n.r.
Differential verification avoided? All tests	Unclear	n.r.
Incorporation avoided? All tests	Unclear	n.r.
Reference standard results blinded? All tests	Unclear	n.r.
Index test results blinded? All tests	Unclear	n.r.
Relevant clinical information? All tests	Unclear	n.r.
Uninterpretable results reported? All tests	Unclear	n.r.
Withdrawals explained? All tests	Unclear	n.r.
Selection criteria clearly described? All tests	No	n.r.
Sufficient detail for replication index test? All tests	No	Performance and equipment of <sup>123</sup> I-MIBG scintigraphy: n.r.  Radiofarmakon, dose, collimator, matrix, acquisition protocol, acquisition time and acquisition duration were n.r.

**123I-MIBG scintigraphy and 18F-FDG-PET imaging for diagnosing neuroblastoma (Review)**

**Biasotti 2000** (Continued)

Sufficient detail for replication reference test? All tests	No	n.r.
Clear definition of positive result index test? All tests	Yes	Pathologic isotope accumulation of <sup>123</sup> I-MIBG.
Interobserver variation reported and acceptable? All tests	Unclear	n.r.

**Gordon 1990**

Clinical features and settings	<p>Inclusion period: January 1986 to March 1988.</p> <p>Patient population: 44 unselected eligible patients with histologically proven neuroblastoma and with a <sup>123</sup>I-MIBG scan; <sup>99m</sup>Tc-MDP and <sup>123</sup>I-MIBG scans were completed within four weeks of each other. Three patients were excluded due to incorrect timing of the studies and another five because the images were missing from the file. So 36 of 44 patients were included, of which 28 had a <sup>123</sup>I-MIBG scan at diagnosis and thus were included in this review.</p> <p>Consecutive series: n.r.</p> <p>Diagnostic work-up: n.r.</p> <p>Time spans symptoms-index test, symptoms-reference standard and index test-reference standard: n.r.</p> <p>Treatment between index test-reference standard: n.r.</p>
Participants	<p>Included patients: 28 children with a neuroblastoma and a <sup>123</sup>I-MIBG scan at first diagnosis.</p> <p>Median age at diagnosis: n.r. for these 28 included patients; for all 36 patients: 3.0 years (range 1 week to 11.5 years).</p> <p>Sex distribution: n.r. for these 28 included patients; for all 36 patients: 23 boys (62%), 13 girls (38%).</p> <p>INSS stage: six stage 1 to 3 and 22 stage 4.</p>
Study design	Case series with pathologically proven neuroblastoma (histopathology not known at the time of MIBG-scintigraphy).
Target condition and reference standard(s)	<p>Target condition: Newly diagnosed neuroblastoma.</p> <p>Reference standard: histopathology or bilateral aspirates of bone marrow and trephine biopsy.</p>
Index and comparator tests	<p>Assessed primary objective 1.1: to determine the diagnostic accuracy of <sup>123</sup>I-MIBG (SPECT-CT) scintigraphy for detecting a neuroblastoma and its metastases at first diagnosis or at recurrence in children from 0 to 18 years old.</p> <p>Index test: <sup>123</sup>I-MIBG scintigraphy.</p> <p>Radiofarmakon: <sup>123</sup>I-MIBG.</p> <p>Dose: 120 MBq for children aged under two years and 160 MBq for those over two years.</p> <p>Collimator: n.r.</p> <p>Matrix: n.r.</p>

**123I-MIBG scintigraphy and 18F-FDG-PET imaging for diagnosing neuroblastoma (Review)**

**Gordon 1990** (Continued)

Acquisition protocol: WB scans. The children were sedated, if necessary.

Acquisition time: 18 to 24 hours after injection.

Acquisition duration: 5 minutes for WB scans.

Interfering medication: n.r.; parents received a list of drugs known to inhibit <sup>123</sup>I-MIBG uptake.

Thyroid prophylaxis: oral potassium iodide three days before the examination.

Positive test result: n.r.

Number of observers: one author blinded for the results of the <sup>99m</sup>Tc-MDP scan.

Expertise of observers: n.r.

Interobserver concordance: n.r.

Follow-up n.r.; some patients were followed up to 64 months.

Notes The sensitivity and specificity of the diagnosis neuroblastoma could be analysed for 19 of the 28 eligible patients. The remaining nine patients could be analysed concerning sensitivity and specificity of metastases only. These patients had false positive results for neuroblastoma based just on negative bone marrow biopsies which is not a valid method to detect neuroblastoma, but only to detect metastases. As stated in the methods, neuroblastoma was assumed not present if all three reference tests were negative.

**Table of Methodological Quality**

Item	Authors' judgement	Description
Representative spectrum? All tests	Yes	Patients with a neuroblastoma at first diagnosis, age 1 week to 11.5 years and stage distribution is reported.
Acceptable reference standard? All tests	Yes	Histopathology.
Acceptable delay between tests? All tests	Unclear	n.r.
Partial verification avoided? All tests	Yes	Diagnosis confirmed by histopathology in all patients.
Differential verification avoided? All tests	Yes	Diagnosis confirmed by histopathology in all patients.
Incorporation avoided? All tests	Yes	Index test not a part of the reference test.
Reference standard results blinded? All tests	Unclear	n.r.
Index test results blinded? All tests	Unclear	n.r.

**123I-MIBG scintigraphy and 18F-FDG-PET imaging for diagnosing neuroblastoma (Review)**

**Gordon 1990** (Continued)

Relevant clinical information? All tests	Unclear	n.r.
Uninterpretable results reported? All tests	Unclear	n.r.
Withdrawals explained? All tests	Unclear	n.r.
Selection criteria clearly described? All tests	Yes	Patients with histologically proven neuroblastoma and with a <sup>123</sup> I-MIBG scan. Three patients were excluded due to incorrect timing of the studies and another five because the images were missing from the file.
Sufficient detail for replication index test? All tests	Yes	Radiofarmakon, dose, acquisition protocol, acquisition time and acquisition duration were reported.
Sufficient detail for replication reference test? All tests	No	n.r.
Clear definition of positive result index test? All tests	No	n.r.
Interobserver variation reported and acceptable? All tests	Unclear	n.r.

**Hashimoto 2003**

Clinical features and settings	<p>Inclusion period: n.r.</p> <p>Patient population: 33 patients younger than one year of age suspected of having a first neuroblastoma by mass screening of urinary VMA and HVA in their sixth month after birth with a <sup>123</sup>I-MIBG scan.</p> <p>Consecutive series: n.r.</p> <p>Diagnostic work-up: abdominal US, abdominal CT or MRI or both, <sup>123</sup>I-MIBG scintigraphy and final confirmation of the diagnosis by surgery.</p> <p>Time spans symptoms-index test, symptoms-reference standard and index test-reference standard: n.r.</p> <p>Treatment between index test-reference standard: n.r.</p> <p>The flow chart did not show treatment between index test and reference standard, but this was not reported in the text.</p>
Participants	<p>Included patients: 33 children &lt; one year of age with a neuroblastoma and a <sup>123</sup>I-MIBG scan at first diagnosis .</p> <p>Median age at diagnosis: 6 months and 27 days (range 6 months and 12 days to 10 months and three days).</p> <p>Sex distribution: 20 boys (61%), 13 girls (39%).</p>

**Hashimoto 2003** (Continued)

INSS stage: 16 patients stage 1, 5 patients stage 2, 4 patients stage 3, 6 patients stage 4 and 2 patients stage 4S.

Study design	Case series with pathologically proven neuroblastoma (histopathology not known at the time of MIBG-scintigraphy).
Target condition and reference standard(s)	<p>Target condition: newly diagnosed neuroblastoma.</p> <p>Reference standard: histopathology.</p> <p>Primary and metastatic foci in the liver, lymph nodes and bone marrow were confirmed by histopathology (surgery or biopsy) or other imaging modalities;</p> <p>Bone marrow infiltration was defined as positive if there were tumour cells in the specimen from the ilium and negative bone scintigraphy and bone X-ray pictures;</p> <p>Liver metastases were confirmed by abdominal CT or MRI, or both;</p> <p>Lymph node metastases were confirmed by histopathology (surgery).</p>
Index and comparator tests	<p>Assessed primary objective 1.1: to determine the diagnostic accuracy of <sup>123</sup>I-MIBG (SPECT-CT) scintigraphy for detecting a neuroblastoma and its metastases at first diagnosis or at recurrence in children from 0 to 18 years old.</p> <p>Index test: <sup>123</sup>I-MIBG scintigraphy.</p> <p>Radiofarmacon: <sup>123</sup>I-MIBG.</p> <p>Dose: 111 MBq, without changing the dose according to the body size.</p> <p>Collimator: low-energy, high-resolution.</p> <p>Matrix: n.r.</p> <p>Acquisition protocol: WB scans and SPECT of chest and abdomen or abdomen and pelvis.</p> <p>SPECT: low-energy, high-resolution collimator in a 128 × 128 matrix, rotated through 120 degrees in 30 steps of 10 to 30 seconds.</p> <p>Acquisition time: 24 hours after injection.</p> <p>Acquisition duration: 15 minutes for WB scans.</p> <p>Interfering medication: n.r.</p> <p>Thyroid prophylaxis: n.r.</p> <p>Positive test result: abnormal <sup>123</sup>I-MIBG uptake.</p> <p>Number and expertise of observers: two radiologists familiar with these nuclear medicine procedures judged independently if supplemental SPECT images provided additional information compared with planar WB <sup>123</sup>I-MIBG scans; it was not reported whether these two radiologists evaluated all <sup>123</sup>I-MIBG scans for diagnosing neuroblastoma.</p> <p>Interobserver concordance: n.r.</p>
Follow-up	n.r.
Notes	

**Table of Methodological Quality**

Item	Authors' judgement	Description
------	--------------------	-------------

**123I-MIBG scintigraphy and 18F-FDG-PET imaging for diagnosing neuroblastoma (Review)**



**Hashimoto 2003** (Continued)

Representative spectrum? All tests	No	Patients younger than one year of age.
Acceptable reference standard? All tests	Yes	Histopathology.
Acceptable delay between tests? All tests	Unclear	n.r.
Partial verification avoided? All tests	Yes	Diagnosis confirmed by histopathology in all patients.
Differential verification avoided? All tests	Yes	Diagnosis confirmed by histopathology in all patients.
Incorporation avoided? All tests	Yes	Index test was not a part of the reference test.
Reference standard results blinded? All tests	Unclear	n.r.
Index test results blinded? All tests	Unclear	n.r.
Relevant clinical information? All tests	Yes	In the flow chart it is clear that urinary catecholamines and CT were performed before <sup>123</sup> I-MIBG scintigraphy and it is stated that everyone was examined by abdominal US and chest and abdominal X-ray before <sup>123</sup> I-MIBG scintigraphy.
Uninterpretable results reported? All tests	Unclear	Unclear whether all results were reported.
Withdrawals explained? All tests	Yes	All 33 patients had an index and a reference test.
Selection criteria clearly described? All tests	Yes	Patients younger than one year that were suspected of having a first neuroblastoma after the mass screening of urinary VMA and HVA in their sixth month after birth.
Sufficient detail for replication index test? All tests	Yes	Radiofarmacon, dose, collimator, matrix, acquisition protocol, acquisition time and acquisition duration were reported.
Sufficient detail for replication reference test? All tests	Unclear	Primary tumour: n.r.  Metastasis: Primary and metastatic foci in the liver, lymph nodes and bone marrow were confirmed by histopathology (surgery or biopsy) or other imaging modalities. Bone marrow infiltration was defined as positive if there were tumour cells in the specimen from the ilium and negative bone scintigraphy and bone X-ray pictures. Liver metastases were confirmed by abdominal CT or MRI, or both. Lymph node metastases were confirmed by histopathology (surgery).

**Hashimoto 2003** (Continued)

Clear definition of positive result index test? All tests	Yes	Abnormal <sup>123</sup> I-MIBG accumulation.
Interobserver variation reported and acceptable? All tests	Unclear	n.r.

**Hugosson 1999**

Clinical features and settings	<p>Inclusion period: July 1988 to October 1993.</p> <p>Patient population: 31 patients suspected for a primary abdominal neuroblastoma in one hospital.</p> <p>Consecutive series: yes.</p> <p>Diagnostic work-up: US of the abdomen, CT of the thorax and abdomen, MRI of the abdomen and sometimes the spine, skeletal survey, chest radiography, bone scintigraphy and <sup>123</sup>I-MIBG scintigraphy.</p> <p>Time spans symptoms-index test, symptoms-reference standard and index test-reference standard: n.r.</p> <p>Treatment between index test-reference standard: n.r.</p>
Participants	<p>Included patients: 18 children with an abdominal neuroblastoma and a <sup>123</sup>I-MIBG scan at first diagnosis; thoraco-abdominal and pelvic tumours were excluded.</p> <p>Median age at diagnosis: n.r. for these 18 included patients; for all 31 patients: 2 years (range 1 month to 9 years).</p> <p>Sex distribution: n.r. for these 18 included patients; for all 31 patients: 17 boys (55%), 14 girls (38%).</p> <p>INSS stage: n.r. for these 18 included patients; for all 31 patients: five with stage 1/2, three stage 3 and 16 stage 4.</p>
Study design	Case series with pathologically proven neuroblastoma (histopathology not known at the time of MIBG-scintigraphy).
Target condition and reference standard(s)	<p>Target condition: newly diagnosed abdominal neuroblastoma.</p> <p>Reference standard: cytology, using fine-needle aspiration of the tumour, in 23 patients; histopathological examination of a surgical biopsy specimen in seven patients; and bone marrow aspirates with cytology in one patient. It is not clear which reference test the 18 included patients received.</p>
Index and comparator tests	<p>Assessed primary objective 1.1: to determine the diagnostic accuracy of <sup>123</sup>I-MIBG (SPECT-CT) scintigraphy for detecting a neuroblastoma and its metastases at first diagnosis or at recurrence in children from 0 to 18 years old.</p> <p>Index test: <sup>123</sup>I-MIBG scintigraphy.</p> <p>Radiofarmakon: <sup>123</sup>I-MIBG.</p> <p>Dose: 185 MBq per 1.73 m<sup>2</sup> and this adult dose was adjusted in proportion to the body area.</p> <p>Collimator: medium energy.</p> <p>Matrix: n.r.</p> <p>Acquisition protocol: WB scans.</p> <p>Acquisition time: 24 and sometimes 48 hours after injection.</p>

**123I-MIBG scintigraphy and 18F-FDG-PET imaging for diagnosing neuroblastoma (Review)**

**Hugosson 1999** (Continued)

Acquisition duration: n.r.

Interfering medication: n.r.

Thyroid prophylaxis: Lugol solution one day before until three days after the examination.

Positive test result: in general n.r.; for metastases: an area of increased uptake outside the primary tumour.

 Number and expertise of observers: <sup>123</sup>I-MIBG scans were interpreted by a radiologist without knowledge of previous examinations.

Interobserver concordance: n.r.

Follow-up n.r.; some patients were followed up to five years.

Notes

**Table of Methodological Quality**

Item	Authors' judgement	Description
Representative spectrum? All tests	Yes	Patients with a neuroblastoma at first diagnosis, age 1 month to 9 years and stage distribution is reported.
Acceptable reference standard? All tests	Yes	Histopathology and cytology.
Acceptable delay between tests? All tests	Unclear	n.r.
Partial verification avoided? All tests	Yes	Diagnosis confirmed by histopathology/cytology in all patients.
Differential verification avoided? All tests	Yes	Diagnosis confirmed by histopathology/cytology in all patients.
Incorporation avoided? All tests	Yes	Index test was not a part of the reference test.
Reference standard results blinded? All tests	Unclear	n.r.
Index test results blinded? All tests	Yes	Radiologist blinded for results of previous examinations.
Relevant clinical information? All tests	Unclear	n.r., but blinded for previous examinations.
Uninterpretable results reported? All tests	Yes	Faint uptake of <sup>123</sup> I-MIBG was reported.
Withdrawals explained?	Unclear	n.r.

**123I-MIBG scintigraphy and 18F-FDG-PET imaging for diagnosing neuroblastoma (Review)**

**Hugosson 1999** (Continued)

Selection criteria clearly described? All tests	Yes	Children with primary abdominal neuroblastoma were included and patients with thoraco-abdominal or pelvic tumours excluded.
Sufficient detail for replication index test? All tests	Yes	Radiofarmacon, dose, collimator, matrix, acquisition protocol and acquisition time.
Sufficient detail for replication reference test? All tests	Yes	Cytology on fine-needle aspiration or bone marrow aspirates of the tumour and histopathology of a surgical biopsy specimen.
Clear definition of positive result index test? All tests	Unclear	In general: n.r. For metastases: an area of increased uptake outside the primary tumour.
Interobserver variation reported and acceptable? All tests	Unclear	n.r.

**Ivanova 2008**

Clinical features and settings	<p>Inclusion period: n.r.</p> <p>Patient population: 22 patients with histologically proven neuroblastoma at first diagnosis and 22 <sup>123</sup>I-MIBG scans.</p> <p>Consecutive series: yes.</p> <p>Diagnostic work-up: pathology, blood chemistry, US, abdominal CT or MRI.</p> <p>Time spans symptoms-index test, symptoms-reference standard and index test-reference standard: n.r.</p> <p>Treatment between index test-reference standard: n.r.</p>
Participants	<p>Included patients: 22 children with neuroblastoma and a <sup>123</sup>I-MIBG scan at first diagnosis.</p> <p>Median age at diagnosis: 48 months (± 42 months).</p> <p>Sex distribution: 14 boys (64%), 8 girls (36%).</p> <p>INSS stage: n.r.</p>
Study design	Retrospective cross-sectional study.
Target condition and reference standard(s)	<p>Target condition: newly diagnosed neuroblastoma.</p> <p>Reference standard: histopathology obtained prior to the index test.</p>
Index and comparator tests	<p>Assessed primary objective 1.1: to determine the diagnostic accuracy of <sup>123</sup>I-MIBG (SPECT-CT) scintigraphy for detecting a neuroblastoma and its metastases at first diagnosis or at recurrence in children from 0 to 18 years old.</p> <p>Index test: <sup>123</sup>I-MIBG scintigraphy.</p> <p>Radiofarmacon: <sup>123</sup>I-MIBG.</p> <p>Dose: 4 MBq/kg.</p>

**123I-MIBG scintigraphy and 18F-FDG-PET imaging for diagnosing neuroblastoma (Review)**

**Ivanova 2008** (Continued)

Collimator: n.r.

Matrix: n.r.

Acquisition protocol: WB scans with or without SPECT.

Acquisition time: n.r.

Acquisition duration: n.r.

Interfering medication: n.r.

Thyroid prophylaxis: n.r.

A description of a positive test result for <sup>123</sup>I-MIBG scans was not reported.

Number and expertise of investigators: n.r.

Interobserver concordance: n.r.

Follow-up	n.r.
Notes	Data-extraction performed by a translator.

**Table of Methodological Quality**

Item	Authors' judgement	Description
Representative spectrum? All tests	Unclear	INSS stage not reported.
Acceptable reference standard? All tests	Yes	Histopathology.
Acceptable delay between tests? All tests	Unclear	n.r.
Partial verification avoided? All tests	Unclear	n.r.
Differential verification avoided? All tests	Unclear	n.r.
Incorporation avoided? All tests	Yes	Index test was not a part of the reference test.
Reference standard results blinded? All tests	Unclear	n.r.
Index test results blinded? All tests	Unclear	Histopathology obtained prior to Index test.
Relevant clinical information? All tests	Unclear	n.r.

**123I-MIBG scintigraphy and 18F-FDG-PET imaging for diagnosing neuroblastoma (Review)**

**Ivanova 2008** (Continued)

Uninterpretable results reported? All tests	Unclear	n.r.
Withdrawals explained? All tests	Unclear	n.r.
Selection criteria clearly described? All tests	No	In- and exclusion criteria n.r.
Sufficient detail for replication index test? All tests	No	Execution of the index test n.r.
Sufficient detail for replication reference test? All tests	No	n.r.
Clear definition of positive result index test? All tests	No	n.r.
Interobserver variation reported and acceptable? All tests	Unclear	n.r.

**Labreuve de Cervens 1994**

Clinical features and settings	<p>Inclusion period: 1984 to 1991.</p> <p>Patient population: 41 patients younger than one year with a histologically proven neuroblastoma at first diagnosis.</p> <p>Consecutive series: yes.</p> <p>Diagnostic work-up: urinary catecholamines (VMA, HVA, dopamine), US of abdomen, CT of thorax or abdomen, extensive bone marrow examination (ten bone marrow aspirates and two trephine biopsies), complete evaluation of the skeleton by skeletal X-ray and <sup>123</sup>I-MIBG scintigraphy and when necessary a CT of the skull if bone lesions of the skull were difficult to appreciate on standard X-ray</p> <p>Time spans symptoms-index test, symptoms-reference standard and index test-reference standard: n.r.</p> <p>Treatment between index test-reference standard: n.r.</p>
Participants	<p>Included patients: 27 children with a neuroblastoma and metastatic abnormalities on one or several imaging methods and a <sup>123</sup>I-MIBG scan at first diagnosis; these patients were divided in three groups: Group 1. eight patients with bone lesions by X-ray and an abnormal <sup>123</sup>I-MIBG scan; Group 2. 13 patients with bone lesions not detected by X-ray or <sup>123</sup>I-MIBG scan; Group 3. six patients with normal X-ray and an abnormal <sup>123</sup>I-MIBG scan.</p> <p>Median age at diagnosis: 0.4 years (range 0 to 0.8 years). Group 1: 10 months (range of 4 to 11 months); Group 2: 3 months (range 0 to 8 months); Group 3: 7.5 months (range 0 to 10 months).</p> <p>Sex distribution: 10 boys (37%), 17 girls (63%). Group 1: 2 boys (25%), 6 girls (75%); Group 2: 5 boys (38%), 8 girls (62%); Group 3: 3 boys (50%), 3 girls (50%).</p> <p>INSS stage: n.r.; all patients had either stage 4 or stage 4S.</p>

**123I-MIBG scintigraphy and 18F-FDG-PET imaging for diagnosing neuroblastoma (Review)**

**Labreuveux de Cervens 1994** (Continued)

Study design	Case series with pathologically proven neuroblastoma (histopathology not known at the time of MIBG-scintigraphy).
Target condition and reference standard(s)	Target condition: newly diagnosed neuroblastoma. Reference standard: histology or cytology.
Index and comparator tests	Assessed primary objective 1.1: to determine the diagnostic accuracy of <sup>123</sup> I-MIBG (SPECT-CT) scintigraphy for detecting a neuroblastoma and its metastases at first diagnosis or at recurrence in children from 0 to 18 years old.  Index test: <sup>123</sup> I-MIBG scintigraphy.  Radiofarmacon: <sup>123</sup> I-MIBG.  Dose: 3.7 MBq/kg.  Collimator: n.r.  Matrix: n.r.  Acquisition protocol: WB scans.  Acquisition time: 24 hours after injection.  Acquisition duration: n.r.  Interfering medication: n.r.  Thyroid prophylaxis: Lugol administered three days before and five days after the examination.  Positive test result: in general n.r.; for metastases: osteo medullary uptake.  Number and expertise of investigators: n.r.  Interobserver concordance: n.r.
Follow-up	n.r.; In Group 1 some patients were followed up to five years; in Group 2 up to eight years; and in Group 3 up to six years.

Notes

**Table of Methodological Quality**

Item	Authors' judgement	Description
Representative spectrum? All tests	No	Patients younger than one year old with a stage 4 or 4S neuroblastoma at first diagnosis.
Acceptable reference standard? All tests	Yes	Histopathology or cytology.
Acceptable delay between tests? All tests	Unclear	n.r.
Partial verification avoided? All tests	Yes	Diagnosis confirmed by histopathology in all patients.

**123I-MIBG scintigraphy and 18F-FDG-PET imaging for diagnosing neuroblastoma (Review)**

**Labreuveux de Cervens 1994** (Continued)

Differential verification avoided? All tests	No	Diagnosis confirmed by histopathology or cytology, or both.
Incorporation avoided? All tests	Yes	Index test was not a part of the reference test.
Reference standard results blinded? All tests	Unclear	n.r.
Index test results blinded? All tests	Unclear	n.r.
Relevant clinical information? All tests	Unclear	n.r.
Uninterpretable results reported? All tests	Unclear	n.r.
Withdrawals explained? All tests	Yes	14 patients excluded because of no osteo medullary uptake.
Selection criteria clearly described? All tests	No	n.r.
Sufficient detail for replication index test? All tests	No	Equipment was not reported. Acquisition protocol was not completely reported (dimensions).
Sufficient detail for replication reference test? All tests	No	n.r.
Clear definition of positive result index test? All tests	Unclear	Description of a positive test result for metastases was reported: osteo medullary uptake. A description of a positive test result in general: n.r.
Interobserver variation reported and acceptable? All tests	Unclear	n.r.

**Naranjo 2011a**

Clinical features and settings	Inclusion period: February 2001 to March 2006.  Patient population: 350 patients with newly diagnosed histologically proven stage 4 neuroblastoma and with 926 <sup>123</sup> I-MIBG scans of which 218 with a <sup>123</sup> I-MIBG scan at first diagnosis. Patients were enrolled on COG protocol A3973 and had completed <sup>123</sup> I-MIBG or <sup>131</sup> I-MIBG scans at one or more of the following time points: diagnosis, post-induction, post-transplant or post biotherapy. To be eligible for COG A3973, patients with stage 4 neuroblastoma had to be aged 30 years or younger at the time of initial diagnosis. If younger than 12 months, MYCN amplification (> 10 copies) was required; if between 12 and 18 months of age, any unfavourable (MYCN amplification, unfavourable histology, and diploid) or	
--------------------------------	--	--

**123I-MIBG scintigraphy and 18F-FDG-PET imaging for diagnosing neuroblastoma (Review)**



**Naranjo 2011a** (Continued)

unknown biologic feature was required. Patients were excluded when pregnant or lactating. Patients of childbearing potential had to practice an effective method of birth control while participating on this study. Normal renal, cardiac, hepatic, and hematopoietic function was required, as well as no prior systemic therapy.

Consecutive series: n.r.

Diagnostic work-up: <sup>123</sup>I-MIBG or <sup>131</sup>I-MIBG scans, histopathology.

Time spans symptoms-index test, symptoms-reference standard and index test-reference standard: n.r.

Treatment between index test-reference standard: n.r.

Participants	<p>Included patients: 218 children with stage 4 neuroblastoma and with a <sup>123</sup>I-MIBG scan at first diagnosis.</p> <p>Median age at diagnosis: 3.1 years (range 6.8 months to 15.2 years).</p> <p>Sex distribution: 124 boys (57%), 94 girls (43%).</p> <p>INSS stage: all stage 4 .</p>
Study design	<p>Case series with pathologically proven neuroblastoma (histopathology not known at the time of MIBG-scintigraphy).</p>
Target condition and reference standard(s)	<p>Target condition: newly diagnosed stage 4 neuroblastoma.</p> <p>Reference standard: histopathology (biopsy of soft tissue or bone marrow).</p>
Index and comparator tests	<p>Assessed primary objective 1.1: to determine the diagnostic accuracy of <sup>123</sup>I-MIBG (SPECT-CT) scintigraphy for detecting a neuroblastoma and its metastases at first diagnosis or at recurrence in children from 0 to 18 years old.</p> <p>Index test: <sup>123</sup>I-MIBG scintigraphy.</p> <p>Radiofarmakon: <sup>123</sup>I-MIBG.</p> <p>Dose: 370 MBq/1.7 m<sup>2</sup> of body surface area.</p> <p>Collimator: low-energy.</p> <p>Matrix: n.r.</p> <p>Acquisition protocol: overlapping anterior and posterior spot views for planar imaging or WB scans.</p> <p>The exact number of patients per dimension: n.r.</p> <p>SPECT: a low-energy collimator, rotated 360° with 120 projections at 20 seconds per stop; filtered back-projection with a Butterworth filter and a cut-off frequency of 0.2 to 0.5 to reconstruct the images</p> <p>Acquisition time: 24 hours after injection.</p> <p>Acquisition duration: 10 minutes per spot view and low-speed for WB scans.</p> <p>Interfering medication: n.r.</p> <p>Thyroid prophylaxis: supersaturated potassium iodide generally 24 hours prior to the diagnostic <sup>123</sup>I-MIBG injection and for three to seven days following the injection.</p> <p>Description of positive test result: Skeletal sites were individually scored: 0 = no MIBG involvement; 1 = one MIBG-avid lesion present; 2 = greater than one MIBG-avid lesion present; and 3 = MIBG-avidity present in &gt; 50% of an individual site. Soft tissue lesions were scored: 0 = no MIBG involvement; 1 = one MIBG-avid soft tissue lesion present; 2 = greater than one MIBG-avid soft tissue lesion present; and 3 = MIBG-avidity in a soft tissue lesion occupying &gt; 50% of the chest or abdomen. A patient's Curie score at each time point was calculated as the sum of his/her scores over all individual sites.</p>

**Naranjo 2011a** (Continued)

Number and expertise of observers:  $^{123}\text{I}$ -MIBG scans were centrally reviewed by two nuclear medicine physicians without knowledge of the original scan reports or other clinical or imaging information.

Interobserver concordance: n.r.

Follow-up n.r.; some patients were followed for approximately seven years.

Notes We received additional data from the author to fill in the two-by-two-table of objective 1.1.

**Table of Methodological Quality**

Item	Authors' judgement	Description
Representative spectrum? All tests	Yes	Children with stage 4 neuroblastoma at first diagnosis.
Acceptable reference standard? All tests	Yes	Histopathology.
Acceptable delay between tests? All tests	Unclear	n.r.
Partial verification avoided? All tests	Yes	Diagnosis confirmed by histopathology in all patients.
Differential verification avoided? All tests	Yes	Diagnosis confirmed by histopathology.
Incorporation avoided? All tests	Yes	Index test was not a part of the reference test.
Reference standard results blinded? All tests	Unclear	n.r.
Index test results blinded? All tests	Yes	$^{123}\text{I}$ -MIBG scans were centrally reviewed by two nuclear medicine physicians without knowledge of other clinical information (like histopathology).
Relevant clinical information? All tests	No	Clinical data, like demographic factors (sex and age), patient history and physical examination (e.g. abdominal extension, bone pains, respiratory distress); additional tests (urinary catecholamines, ferritin, LDH, other imaging modalities) were not available when the test results were interpreted.
Uninterpretable results reported? All tests	Unclear	n.r.
Withdrawals explained? All tests	Unclear	n.r.
Selection criteria clearly described? All tests	Yes	Newly diagnosed high-risk patients with INSS stage 4 neuroblastoma enrolled on COG protocol A3973 who had completed $^{123}\text{I}$ -MIBG or $^{131}\text{I}$ -MIBG scans at one or more of the following time points: diagnosis, post-induction, post-transplant, or post biotherapy. To be eligible for COG A3973, patients with stage 4 disease had to be aged 30 years or younger at the time of initial diagnosis. If

**123I-MIBG scintigraphy and 18F-FDG-PET imaging for diagnosing neuroblastoma (Review)**

56

**Naranjo 2011a** (Continued)

younger than 12 months, MYCN amplification (> 10 copies) was required; if between 12 and 18 months of age, any unfavourable (MYCN amplification, unfavourable histology, and diploid) or unknown biologic feature was required. Normal renal, cardiac, hepatic, and hematopoietic function was required, as well as no prior systemic therapy.

Sufficient detail for replication index test? All tests	Yes	Radiofarmacon, dose, collimator, matrix, acquisition protocol, acquisition time and acquisition duration were reported.
Sufficient detail for replication reference test? All tests	No	n.r.
Clear definition of positive result index test? All tests	Yes	Skeletal sites: 0 = no MIBG involvement; 1 = one MIBG-avid lesion present; 2 = greater than one MIBG-avid lesion present; and 3 = MIBG-avidity present in > 50% of an individual site. Soft tissue lesions: 0 = no MIBG involvement; 1 = one MIBG-avid soft tissue lesion present; 2 = greater than one MIBG-avid soft tissue lesion present; and 3 = MIBG-avidity in a soft tissue lesion occupying > 50% of the chest or abdomen. A patient's Curie score at each time point was calculated as the sum of his/her scores over all individual sites.
Interobserver variation reported and acceptable? All tests	Unclear	n.r.

**Neuenschwander 1987**

Clinical features and settings	<p>Inclusion period: July 1984 to May 1987.</p> <p>Patient population: 20 patients with histologically proven advanced abdominal neuroblastoma and a <sup>123</sup>I-MIBG scan of which 16 at first diagnosis.</p> <p>Consecutive series: n.r.</p> <p>Diagnostic work-up: at least urinary catecholamines, US and <sup>123</sup>I-MIBG scintigraphy.</p> <p>Time spans symptoms-index test, symptoms-reference standard and index test-reference standard: n.r.</p> <p>Treatment between index test-reference standard: n.r.</p>
Participants	<p>Included patients: 16 children with primary advanced abdominal neuroblastoma and a <sup>123</sup>I-MIBG scan at first diagnosis.</p> <p>Median age at diagnosis: n.r. for these 16 included patients; for all 20 patients mean age: 42 months (range 15 to 77 months).</p> <p>Sex distribution: n.r. for these 16 included patients; for all 20 patients: 12 boys (60%), 8 girls (40%).</p> <p>INSS stage: n.r. for these 16 included patients; for all 20 patients: four stage 3 and 16 stage 4.</p>
Study design	Case series with pathologically proven neuroblastoma (histopathology not known at the time of MIBG-scintigraphy).
Target condition and reference standard(s)	<p>Target condition: newly diagnosed neuroblastoma.</p> <p>Reference standard: histopathology (biopsy or surgical resection).</p>

**Neuenschwander 1987** (Continued)

Index and comparator tests	<p>Assessed primary objective 1.1: to determine the diagnostic accuracy of <sup>123</sup>I-MIBG (SPECT-CT) scintigraphy for detecting a neuroblastoma and its metastases at first diagnosis or at recurrence in children from 0 to 18 years old.</p> <p>Index test: <sup>123</sup>I-MIBG scintigraphy.</p> <p>Radiofarmacon: <sup>123</sup>I-MIBG.</p> <p>Dose: 3.7 MBq/kg.</p> <p>Collimator: n.r.</p> <p>Matrix: n.r.</p> <p>Acquisition protocol: n.r.</p> <p>Acquisition time: 24 hours after injection.</p> <p>Acquisition duration: n.r.</p> <p>The exact number of patients per dimension: n.r.</p> <p>Interfering medication: n.r.</p> <p>Thyroid prophylaxis: n.r.</p> <p>Positive test result: n.r.</p> <p>Number and expertise of investigators: n.r.</p> <p>Interobserver concordance: n.r.</p>
----------------------------	---

Follow-up	n.r.
-----------	------

Notes

**Table of Methodological Quality**

Item	Authors' judgement	Description
Representative spectrum? All tests	Yes	Age, stage and primary disease were described. Stage 4S excluded.
Acceptable reference standard? All tests	Yes	Histopathology.
Acceptable delay between tests? All tests	Unclear	n.r.
Partial verification avoided? All tests	Yes	Diagnosis confirmed by histopathology in all patients.
Differential verification avoided? All tests	Yes	Diagnosis confirmed by histopathology.
Incorporation avoided? All tests	Yes	Index test was not a part of the reference test.

**123I-MIBG scintigraphy and 18F-FDG-PET imaging for diagnosing neuroblastoma (Review)**

**Neuenschwander 1987** (Continued)

Reference standard results blinded? All tests	Unclear	n.r.
Index test results blinded? All tests	Unclear	n.r.
Relevant clinical information? All tests	Unclear	Urinary catecholamines available. Further information n.r.
Uninterpretable results reported? All tests	Unclear	n.r.
Withdrawals explained? All tests	Unclear	n.r.
Selection criteria clearly described? All tests	Yes	Patients with advanced abdominal neuroblastoma; stage 4S neuroblastoma excluded.
Sufficient detail for replication index test? All tests	No	Dimensions and imaged body parts: n.r. Equipment was not reported. Radiofarmakon, dose and acquisition time reported. Equipment, acquisition protocol and acquisition n.r.
Sufficient detail for replication reference test? All tests	No	n.r.
Clear definition of positive result index test? All tests	No	n.r.
Interobserver variation reported and acceptable? All tests	Unclear	n.r.

**Pfluger 2003**

Clinical features and settings	<p>Inclusion period: five years and nine months for all studies (including follow-up and MRI).</p> <p>Patient population: 28 patients with suspected or histologically proven neuroblastoma and a total of 50 <sup>123</sup>I-MIBG scans and 50 MRI examinations</p> <p>Inclusion criteria: suspected or histologically proven neuroblastoma and a maximum time frame of 30 days between <sup>123</sup>I-MIBG scintigraphy and MRI. Suspect tumour lesions were included only if they were in the field of view on images from both modalities. Exclusion criteria were not reported. Image analyses were performed on a lesion-related basis. A total of 115 lesions were evaluated.</p> <p>Consecutive series: n.r.</p> <p>Diagnostic work-up: <sup>123</sup>I-MIBG scintigraphy and MRI examinations.</p> <p>Time spans symptoms-index test, symptoms-reference standard and index test-reference standard: n.r.</p>
--------------------------------	---

**123I-MIBG scintigraphy and 18F-FDG-PET imaging for diagnosing neuroblastoma (Review)**

**Pfluger 2003** (Continued)

	Treatment between index test-reference standard: n.r.
Participants	<p>Included patients: 22 children with neuroblastoma and a <sup>123</sup>I-MIBG scan at first diagnosis.</p> <p>Median age at diagnosis: n.r. for these 22 included patients; for all 28 patients: mean age of 3.2 years (range 1 week to 11 years).</p> <p>Sex distribution: n.r. for these 22 included patients; for all 28 patients: 18 boys (64%), 10 girls (36%).</p> <p>INSS stage: n.r.</p>
Study design	Case series with pathologically proven neuroblastoma (histopathology not known at the time of MIBG-scintigraphy).
Target condition and reference standard(s)	<p>Target condition: newly diagnosed neuroblastoma.</p> <p>Reference standard: histopathology. For patients with stage 4 neuroblastoma, histologic verification of all metastases is impossible. Therefore, on follow-up control examinations, a minimum of six months was used for verification of lesions. In these cases, a lesion was classified as a false-positive finding if it disappeared without tumour therapy during the observation period. A lesion was classified as a true-positive finding if it persisted or progressed during follow-up or if it showed clear regression under specific therapy.</p>
Index and comparator tests	<p>Assessed primary objective 1.1: to determine the diagnostic accuracy of <sup>123</sup>I-MIBG (SPECT-CT) scintigraphy for detecting a neuroblastoma and its metastases at first diagnosis or at recurrence in children from 0 to 18 years old.</p> <p>Index test: <sup>123</sup>I-MIBG scintigraphy.</p> <p>Radiofarmakon: <sup>123</sup>I-MIBG.</p> <p>Dose: 3.7 MBq/kg.</p> <p>Collimator: medium energy.</p> <p>Matrix: 256 × 256.</p> <p>Acquisition protocol: anterior and posterior images of the WB and SPECT.</p> <p>Acquisition time: 24 hours after injection.</p> <p>Acquisition duration: n.r.</p> <p>Interfering medication: n.r.</p> <p>Thyroid prophylaxis: supersaturated potassium iodide one day before the examination and for three days.</p> <p>Positive test result: non-physiologic focal uptake.</p> <p>Number and expertise of observers: <sup>123</sup>I-MIBG scans were interpreted by two experienced observers with knowledge of clinical data, but blinded for the results on the MRI.</p> <p>Interobserver concordance: On both <sup>123</sup>I-MIBG scans and MRI scans, each lesion was judged either positive or negative with regard to neuroblastoma involvement. For observers to reach a decision about lesions with discrepant results on both modalities, a diagnostic confidence score of three levels was established for each modality: 1. both observers were uncertain about a positive or negative finding; 2. one observer was uncertain and one observer was certain; and 3. both observers were certain. This diagnostic confidence score was assigned to each suspect lesion on <sup>123</sup>I-MIBG scintigraphy and MRI separately. For lesions with discrepant findings on both modalities, the finding of the modality with the higher diagnostic confidence score was accepted. If results from both modalities were discrepant and had the same diagnostic confidence score value, the lesion was judged positive. Interobserver concor-</p>

**Pfluger 2003** (Continued)

dance was unclear for the 22 participants; for all 115 lesions (28 patients) the mean diagnostic confidence score was 2.7 with a SD of 0.6.

Follow-up n.r.; follow-up of a minimum of six months was used for verification of lesions.

Notes

**Table of Methodological Quality**

Item	Authors' judgement	Description
Representative spectrum? All tests	Unclear	Distribution of stage n.r.
Acceptable reference standard? All tests	Yes	Histopathology.
Acceptable delay between tests? All tests	Unclear	n.r.
Partial verification avoided? All tests	No	For patients with stage 4 neuroblastoma, histological verification of all metastases is impossible. Therefore, on follow-up control examinations, a minimum of 6 months was used for verification of lesions. In these cases, a lesion was classified as a false-positive finding if it disappeared without tumour therapy during the observation period.
Differential verification avoided? All tests	No	For patients with stage 4 neuroblastoma, histologic verification of all metastases is impossible. Therefore, on follow-up control examinations, a minimum of 6 months was used for verification of lesions. In these cases, a lesion was classified as a false-positive finding if it disappeared without tumour therapy during the observation period.
Incorporation avoided? All tests	Yes	Index test was not a part of the reference test.
Reference standard results blinded? All tests	Unclear	n.r.
Index test results blinded? All tests	Unclear	n.r.
Relevant clinical information? All tests	Yes	Analysis was performed with knowledge of clinical data.
Uninterpretable results reported? All tests	Yes	For observers to reach a decision about lesions with discrepant results on both modalities, a diagnostic confidence score of three levels was established for each modality: 1. both observers were uncertain about a positive or negative finding; 2. one observer was uncertain and one observer was certain; and 3. both observers were certain. This diagnostic confidence score was assigned to each suspect lesion on MIBG scintigraphy separately.
Withdrawals explained? All tests	Unclear	n.r.

### Pfluger 2003 (Continued)

Selection criteria clearly described? All tests	Yes	Inclusion criteria: suspected or proven neuroblastoma; maximum time frame of 10 days between <sup>123</sup> I-MIBG scan and MRI scan.
Sufficient detail for replication index test? All tests	Yes	<sup>123</sup> I-MIBGscans were acquired 24 hours after injection of tracer with an administered activity of 3.7 MBq/kg. SPECT images were acquired at intervals of 24 hours only. The dual-headed gamma camera was equipped with a medium-energy collimator, 256 × 256 matrix]. MIBG scans were reviewed on a Hermes workstation.
Sufficient detail for replication reference test? All tests	No	n.r.
Clear definition of positive result index test? All tests	Yes	Non-physiological focal uptake.
Interobserver variation reported and acceptable? All tests	Unclear	n.r.

### Piccardo 2012

Clinical features and settings	<p>Inclusion period: n.r.</p> <p>Patient population: 19 patients with stage 3 and 4 neuroblastoma and a total of 28 paired <sup>123</sup>I-MIBG and <sup>18</sup>F-dopa-PET/CT scans.</p> <p>Consecutive series: yes.</p> <p>Diagnostic work-up: urinary catecholamines, <sup>123</sup>I-MIBG scans, CT, MRI and dopa-PET scans, histopathology and bone marrow biopsies.</p> <p>Time spans symptoms-index test, symptoms-reference standard and index test-reference standard: n.r.</p> <p>Treatment between index test-reference standard: n.r.</p>
Participants	<p>Included patients: 17 children with a stage 3 or 4 neuroblastoma and a <sup>123</sup>I-MIBG scan at first diagnosis or at recurrence. Four had their first diagnosis and 13 a recurrence.</p> <p>Median age at diagnosis: 6 years (range 1 to 9 years).</p> <p>Sex distribution: 4 boys (24%), 13 girls (76%).</p> <p>INSS stage: two stage 3 and 15 stage 4.</p>
Study design	Prospective cross-sectional study.
Target condition and reference standard(s)	<p>Target condition: newly diagnosed and recurrent neuroblastoma.</p> <p>Reference standard: all patients had histopathology, bone marrow biopsies, or both, with contrast-enhanced CT or MRI (one patient had histopathology of the primary tumour and contrast-enhanced CT or MRI and five patients had histopathology of the primary tumour, bone marrow biopsies and contrast-enhanced CT or MRI).</p>



**Piccardo 2012** (Continued)

Index and comparator tests	<p>Assessed primary objective 1: to determine the diagnostic accuracy of <sup>123</sup>I-MIBG (SPECT-CT) scintigraphy for detecting a neuroblastoma and its metastases at first diagnosis or at recurrence in children from 0 to 18 years old.</p> <p>Index test: <sup>123</sup>I-MIBG scintigraphy.</p> <p>Radiofarmacon: <sup>123</sup>I-MIBG.</p> <p>Dose: 5.18 MBq/kg.</p> <p>Collimator: low-energy high-resolution parallel-hole collimator.</p> <p>Matrix: n.r.</p> <p>Acquisition protocol: WB scans and SPECT.</p> <p>SPECT: 64 projections, 128 × 128 matrix, 40 seconds acquisition time per projection; standard filtered backprojection using a Butterworth filter.</p> <p>Acquisition time: 24 hours after injection.</p> <p>Acquisition duration: 6 cm/min for WB scans.</p> <p>Interfering medication: n.r.</p> <p>Thyroid prophylaxis: n.r.</p> <p>Positive test result: n.r.</p> <p>Number and expertise of observers: <sup>123</sup>I-MIBG scans were interpreted after a consensus reading by two nuclear medicine physicians in each institute with knowledge of the patient's clinical history but blinded to any results of the anatomical imaging modalities.</p> <p>Interobserver concordance: n.r.</p>
Follow-up	n.r.; at least four months of clinical and imaging follow-up data were available for all patients.
Notes	The sensitivity and specificity of the diagnosis neuroblastoma could be analysed for 13 of the 17 eligible patients. The remaining four patients had false positive results for neuroblastoma based just on negative bone marrow biopsies which is not a valid method to detect neuroblastoma, but only to detect metastases. Of these four patients, three had a stage 4 neuroblastoma and could therefore be analysed for diagnostic accuracy of the presence of metastases. One of the four patients had a stage 3 neuroblastoma and therefore could not be analysed for any of the diagnostic accuracies.

**Table of Methodological Quality**

Item	Authors' judgement	Description
Representative spectrum? All tests	Yes	Age, stage and disease at first diagnosis or at recurrence were reported.
Acceptable reference standard? All tests	Yes	<p>Tumour at first diagnosis or at recurrence and locoregional soft tissue recurrence/metastases: histopathology, diagnostic contrast-enhanced CT, MRI findings, or a combination of these tests.</p> <p>Bone and bone marrow metastases: bone marrow biopsy, MRI, or both, when available.</p>
Acceptable delay between tests? All tests	Unclear	n.r.

**123I-MIBG scintigraphy and 18F-FDG-PET imaging for diagnosing neuroblastoma (Review)**

**Piccardo 2012** (Continued)

Partial verification avoided? All tests	Yes	Histopathology and bone marrow biopsy in four patients and bone marrow biopsy only in 13 patients.
Differential verification avoided? All tests	No	Histopathology and bone marrow biopsy in four patients and bone marrow biopsy only in 13 patients.
Incorporation avoided? All tests	Yes	Index test was not a part of the reference test.
Reference standard results blinded? All tests	Unclear	Investigators blinded for any results of the anatomical imaging modalities (MRI/CT). The other parts of the reference standard (histopathology and bone marrow biopsy) were n.r.
Index test results blinded? All tests	Unclear	n.r.
Relevant clinical information? All tests	No	Investigators blinded for any results of the anatomical imaging modalities (MRI/CT).
Uninterpretable results reported? All tests	Unclear	n.r.
Withdrawals explained? All tests	Yes	One patient was reported as lost to follow-up.
Selection criteria clearly described? All tests	Yes	Patients older than one year with a stage 3 or 4 neuroblastoma at first diagnosis or at recurrence were included.
Sufficient detail for replication index test? All tests	Yes	<sup>123</sup> I-MIBG scans were acquired 24 hours after injection of tracer with an administered activity of 5.18 MBq/kg. SPECT images were acquired at intervals of 24 hours only. The scan speed for WB imaging was 6 cm/min. The dual-head gamma scintillation camera was equipped with a low-energy high-resolution parallel-hole collimator. For SPECT acquisitions the following parameters were used: 64 projections, 128 × 128 matrix, 40 seconds acquisition time per projection. SPECT data were reconstructed by standard filtered backprojection using a Butterworth filter.  Radiofarmakon, dose, collimator, acquisition protocol, acquisition time and acquisition duration were reported.
Sufficient detail for replication reference test? All tests	No	n.r.
Clear definition of positive result index test? All tests	No	n.r.
Interobserver variation reported and acceptable? All tests	Unclear	n.r.

**123I-MIBG scintigraphy and 18F-FDG-PET imaging for diagnosing neuroblastoma (Review)**

## Sharp 2009a

Clinical features and settings	<p>Inclusion period: January 2003 to October 2007.</p> <p>Patient population: 60 patients with histologically proven neuroblastoma and a total of 113 paired <sup>123</sup>I-MIBG and <sup>18</sup>F-FDG-PET scans.</p> <p>Consecutive series: no; paired scans at one hospital were acquired for research purposes after informed consent was obtained; paired scans at the second hospital were obtained when requested by the oncology service for clinical reasons.</p> <p>Diagnostic work-up: n.r.</p> <p>Time spans symptoms-index test, symptoms-reference standard and index test-reference standard: n.r.</p> <p>Treatment between index test-reference standard: n.r.</p>
Participants	<p>Included patients: 24 children with a neuroblastoma and a <sup>123</sup>I-MIBG scan at first diagnosis.</p> <p>Median age at diagnosis: n.r. for these 24 included patients; for all 60 patients: 3.1 years.</p> <p>Sex distribution: n.r. for these 24 included patients; for all 60 patients: 37 boys (62%), 23 girls (38%).</p> <p>INSS stage: 5 patients stage 1/2, 3 patients stage 3 and 16 patients stage 4.</p>
Study design	Case series with pathologically proven neuroblastoma (histopathology not known at the time of MIBG-scintigraphy).
Target condition and reference standard(s)	<p>Target condition: newly diagnosed neuroblastoma.</p> <p>Reference standard: histopathology. If both <sup>123</sup>I-MIBG and <sup>18</sup>F-FDG-PET scans were negative: information concerning bone marrow biopsies and urinary catecholamines were provided.</p>
Index and comparator tests	<p>Assessed primary objectives:</p> <p>1.1 To determine the diagnostic accuracy of <sup>123</sup>I-MIBG (SPECT-CT) scintigraphy for detecting a neuroblastoma and its metastases at first diagnosis or at recurrence in children from 0 to 18 years old.</p> <p>1.2 To determine the diagnostic accuracy of negative <sup>123</sup>I-MIBG scintigraphy in combination with <sup>18</sup>F-FDG-PET(-CT) imaging for detecting a neuroblastoma and its metastases at first diagnosis or at recurrence in children from 0 to 18 years old. In this case <sup>18</sup>F-FDG-PET(-CT) is an add-on test.</p> <p>Assessed secondary objectives:</p> <p>2.1 To determine the diagnostic accuracy of <sup>18</sup>F-FDG-PET(-CT) imaging for detecting a neuroblastoma and its metastases at first diagnosis or at recurrence in children from 0 to 18 years old.</p> <p>2.2 To compare the diagnostic accuracy of <sup>123</sup>I-MIBG (SPECT-CT) scintigraphy and of <sup>18</sup>F-FDG-PET(-CT) imaging for detecting a neuroblastoma and its metastases at first diagnosis or at recurrence in children from 0 to 18 years old.</p> <p>Positive test result for both <sup>123</sup>I-MIBG and <sup>18</sup>F-FDG-PET scans: uptake in primary and residual tumour, local and regional soft-tissue (local/regional) metastases, and bone and bone marrow (bone/marrow) metastases.</p> <p><b>1. <sup>123</sup>I-MIBG scintigraphy:</b></p> <p>Three <sup>123</sup>I-MIBG WB scans without SPECT and 110 <sup>123</sup>I-MIBG WB scans with SPECT. The number of each dimension was n.r. for the 24 included patients only.</p> <p>Radiofarmakon: <sup>123</sup>I-MIBG.</p> <p>Dose: 5.18 MBq/kg or 370 MBq/1.7 m<sup>2</sup> body surface area, depending on the institution, with a maximum dose of 370 MBq.</p>

**Sharp 2009a** (Continued)

Collimator: n.r.

Matrix: 256 256.

Acquisition protocol: WB scans and SPECT.

SPECT: n.r.

Acquisition time: n.r.

Acquisition duration: n.r.

Interfering medication: n.r.

Thyroid prophylaxis: n.r.

Number and expertise of investigators: n.r.

Interobserver concordance: n.r.

**<sup>18</sup>F-FDG-PET scintigraphy:**

13 <sup>18</sup>F-FDG-PET only scans and 100 <sup>18</sup>F-FDG-PET scans with CT. The number of each dimension was n.r for the 24 included patients only.

Radiofarmacon: <sup>18</sup>F-FDG-PET.

Dose: 5.18 or 5.55 MBq/kg, depending on the institution, with a maximum dosage of 444 MBq.

Equipment: LS Discovery PET/CT scanner (GE Healthcare), Siemens Exact or Accel PET scanners, DSTE PET/CT scanner (GE Healthcare) or not reported.

Acquisition protocol: n.r.

Acquisition time: n.r.

Acquisition duration: n.r.

Number and expertise of investigators: n.r.

Interobserver concordance: n.r.

Blood glucose levels: n.r.

Follow-up

n.a.

Notes

We received additional data from the author to fill in the two-by-two-table of objective 1.1, 1.2, 2.1 and 2.2.

**Table of Methodological Quality**

Item	Authors' judgement	Description
Representative spectrum? All tests	Unclear	Patients with proven stage 1 to 4 neuroblastoma were included, but age range n.r.
Acceptable reference standard? All tests	Yes	Histopathology.
Acceptable delay between tests? All tests	Unclear	n.r.

**123I-MIBG scintigraphy and 18F-FDG-PET imaging for diagnosing neuroblastoma (Review)**

**Sharp 2009a** (Continued)

Partial verification avoided? All tests	Unclear	n.r.
Differential verification avoided? All tests	Unclear	Insufficient information regarding the different reference tests.
Incorporation avoided? All tests	Yes	Index test was not a part of the reference test.
Reference standard results blinded? All tests	Unclear	n.r.
Index test results blinded? All tests	Unclear	n.r.
Relevant clinical information? All tests	Unclear	n.r.
Uninterpretable results reported? All tests	Unclear	n.r.
Withdrawals explained? All tests	Yes	Results of all patients reported.
Selection criteria clearly described? All tests	Yes	Relevant information reported.
Sufficient detail for replication index test? All tests	No	SPECT, acquisition time and acquisition duration of <sup>123</sup> I-MIBG scintigraphy n.r. Acquisition protocol, acquisition time and acquisition duration of <sup>18</sup> F-FDG-PET scintigraphy n.r.
Sufficient detail for replication reference test? All tests	No	n.r.
Clear definition of positive result index test? All tests	Yes	Uptake in primary and residual tumour, local and regional soft-tissue (local/regional) metastases, and bone and bone marrow (bone/marrow) metastases.
Interobserver variation reported and acceptable? All tests	Unclear	n.r.

## Abbreviations:

<sup>123</sup>I-MIBG: Iodine-123-metaiodobenzylguanidine; <sup>131</sup>I-MIBG: Iodine-131-metaiodobenzylguanidine; <sup>18</sup>F-FDG-PET: fluorine-18-fluorodeoxy-glucose positron emission tomography; <sup>18</sup>F-dopa PET: fluorine-18-dihydroxyphenylalanine positron emission tomography; <sup>99m</sup>Tc-MDP: metastable-technetium-99-methyldiphosphanate; cm: centimetre; COG: children's oncology group; CT: computed tomography; dopa PET: dihydroxyphenylalanine positron emission tomography; HVA: homovanillic acid; INSS: international neuroblastoma staging system; keV: kilo-electron volt; kg: kilogram; m<sup>2</sup>: square metre; MBq: mega becquerel; MIBG: metaiodobenzylguanidine; min: minute; mm: millimetre; MRI: magnetic resonance imaging; n.a.: not applicable; n.r.: not reported; SD: standard deviation; SPECT: single photon emission computed tomography; US: ultrasound; VMA: vanillylmandelic acid; WB: whole-body.

**123I-MIBG scintigraphy and 18F-FDG-PET imaging for diagnosing neuroblastoma (Review)**

Copyright © 2019 The Authors. Cochrane Database of Systematic Reviews published by John Wiley &amp; Sons, Ltd. on behalf of The Cochrane Collaboration.

**Characteristics of excluded studies** [ordered by study ID]

Study	Reason for exclusion
<a href="#">Abramowsky 2009</a>	Included patients not suspected for neuroblastoma.
<a href="#">Adam 2008</a>	No original research: review.
<a href="#">Adolph 1989</a>	Less than 10 patients with a <sup>123</sup> I-MIBG scan at diagnosis.
<a href="#">Alessio 2011</a>	Less than 10 patients with a <sup>123</sup> I-MIBG scan at diagnosis.
<a href="#">Andersen 2011</a>	Less than 10 patients with a <sup>123</sup> I-MIBG scan at diagnosis.
<a href="#">Angelini 2007</a>	Study was not primary diagnostic.
<a href="#">Arceci 1999</a>	No original research: comments from the editor-in-chief.
<a href="#">Arceci 2003</a>	No original research: comments from the editor-in-chief.
<a href="#">Arora 2010</a>	No original research: guest editorial/review.
<a href="#">Balaguer 2008</a>	No original research: review.
<a href="#">Bardi 2009</a>	Fewer than 10 patients with a <sup>123</sup> I-MIBG scan at diagnosis.
<a href="#">Barliev 1988</a>	<sup>131</sup> I-MIBG.
<a href="#">Baulieu 1984</a>	Less than 10 patients with a <sup>123</sup> I-MIBG scan at diagnosis.
<a href="#">Beierwaltes 1991</a>	No original research: review.
<a href="#">Benz-Bohm 1990</a>	Fewer than 10 patients with a <sup>123</sup> I-MIBG scan at diagnosis.
<a href="#">Berthold 1990</a>	Fewer than 10 patients with a <sup>123</sup> I-MIBG scan at diagnosis.
<a href="#">Bian 2009</a>	Bone scintigraphy.
<a href="#">Biersack 2010</a>	No original research: guest editorial.
<a href="#">Binderup 2010</a>	Included patients not suspected for neuroblastoma.
<a href="#">Bomanji 1987</a>	Fewer than 10 patients with a <sup>123</sup> I-MIBG scan at diagnosis.
<a href="#">Bomanji 1988</a>	Fewer than 10 patients with a <sup>123</sup> I-MIBG scan at diagnosis.
<a href="#">Bomanji 1991</a>	Study was not primary diagnostic.
<a href="#">Bombardieri 2003a</a>	No original research: foreword.
<a href="#">Bonnin 1994</a>	Not primary diagnostic.
<a href="#">Bourliere 1992</a>	Study was not primary diagnostic.
<a href="#">Brandon 2011</a>	No original research: review (no eligible studies identified).

Study	Reason for exclusion
<a href="#">Brendel 1986</a>	No original research: review.
<a href="#">Brisse 2009</a>	No original research: review.
<a href="#">Britton 1997</a>	Letter to the editor (comment).
<a href="#">Brodeur 1993</a>	No original research: guideline.
<a href="#">Brunklaus 2012</a>	Same publication as <a href="#">Brunklaus 2012a</a> .
<a href="#">Brunklaus 2012a</a>	Unclear which MIBG-scans were <sup>123</sup> I-labelled; upon consultation the study authors were unable to clarify this.
<a href="#">Buck 2008</a>	No original research: review.
<a href="#">Bönisch 1994</a>	No original research: review.
<a href="#">Calisti 2012</a>	Study was not primary diagnostic.
<a href="#">Carachi 2002</a>	No original research: review.
<a href="#">Caravel 2001</a>	No original research: review.
<a href="#">Castel 2006</a>	No original research: editorial.
<a href="#">Cedenkayevna 2011</a>	Fewer than 10 patients with a <sup>123</sup> I-MIBG scan at diagnosis.
<a href="#">Chan 2001</a>	<sup>131</sup> I-MIBG.
<a href="#">Chan 2001a</a>	<sup>131</sup> I-MIBG.
<a href="#">Chatal 1984</a>	Fewer than 10 patients with a <sup>123</sup> I-MIBG scan at diagnosis.
<a href="#">Chu 2011</a>	Case report.
<a href="#">Clarke 2001</a>	No original research: review.
<a href="#">Corbett 1991a</a>	Fewer than 10 patients with a <sup>123</sup> I-MIBG scan at diagnosis.
<a href="#">Corbett 1991b</a>	Fewer than 10 patients with a <sup>123</sup> I-MIBG scan at diagnosis.
<a href="#">Dabasi 1989</a>	<sup>131</sup> I-MIBG
<a href="#">Dalmau 2008</a>	No original research: review.
<a href="#">Dessner 1993</a>	Fewer than 10 patients with a <sup>123</sup> I-MIBG scan at diagnosis.
<a href="#">Dhir 2010</a>	No original research: review.
<a href="#">Diez 2006</a>	Case report.
<a href="#">Dirisamer 2008</a>	Patients older than 18 years old.
<a href="#">Durak 2002</a>	No original research: meeting report.

Study	Reason for exclusion
<a href="#">Eckelman 2007</a>	No original research: editorial.
<a href="#">Edeling 1987</a>	Fewer than 10 patients with a <sup>123</sup> I-MIBG scan at diagnosis.
<a href="#">Ell 2006</a>	No original research: editorial.
<a href="#">Fischer 1993</a>	Included patients not suspected for neuroblastoma.
<a href="#">Franzius 2006</a>	Fewer than 10 patients with a <sup>123</sup> I-MIBG scan at diagnosis.
<a href="#">Franzius 2009</a>	No original research: review.
<a href="#">Frappaz 2000</a>	Unclear which MIBG-scans were <sup>123</sup> I-labelled; upon consultation the study authors were unable to clarify this.
<a href="#">Frappaz 2004</a>	Fewer than 10 patients with a <sup>123</sup> I-MIBG scan at diagnosis.
<a href="#">Freeman 2007</a>	No original research: letter from the editors.
<a href="#">Freeman 2011</a>	No original research: letter from the editors.
<a href="#">Fukuoka 2011</a>	Less than 10 patients with a <sup>123</sup> I-MIBG scan at diagnosis.
<a href="#">Fukuoka 2011a</a>	Duplicate publication of <a href="#">Fukuoka 2011</a> .
<a href="#">Garaventa 2001</a>	Letter to the editor (comment on two studies already assessed in this review ( <a href="#">Biasotti 2000</a> ; <a href="#">Chan 2001</a> )).
<a href="#">Garaventa 2008</a>	No original research: meeting report.
<a href="#">García-Peña 2010</a>	No original research: review.
<a href="#">Giammarile 1998</a>	No original research: letter to the editor.
<a href="#">Giammarile 2000</a>	Letter to the editor (comment on two studies that described cases).
<a href="#">Gilday 1990</a>	No original research: editorial.
<a href="#">Goo 2006</a>	Letter to the editor (comment on a study already assessed in this review ( <a href="#">Goo 2005</a> )).
<a href="#">Gruner 1990</a>	Fewer than 10 patients with a <sup>123</sup> I-MIBG scan at diagnosis.
<a href="#">Guerra 1990</a>	No original research: review.
<a href="#">Hahn 2003</a>	Letter to the editor (comment on a study not reporting on <sup>123</sup> I-MIBG).
<a href="#">Hahn 2004</a>	No original research: review.
<a href="#">Hammami 2007</a>	<sup>131</sup> I-MIBG.
<a href="#">Han 2007</a>	No original research: review.
<a href="#">Hattner 1988</a>	No original research: review (no eligible studies identified).
<a href="#">Hausegger 1989</a>	Fewer than 10 patients with a <sup>123</sup> I-MIBG scan at diagnosis.



Study	Reason for exclusion
Haynie 1993	No original research: editorial.
Hero 2001	Unclear which MIBG-scans were <sup>123</sup> I-labelled; upon consultation the authors were unable to clarify this.
Heston 2010	Letter to the editor (comment on a study already assessed in this review ( <a href="#">Sharp 2009a</a> )).
Hildebrand 2007	No original research: editorial.
Hoefnagel 1995	No original research: review.
Ikekubo 1994	Fewer than 10 patients with a <sup>123</sup> I-MIBG scan at diagnosis.
Jacobs 1990a	Fewer than 10 patients with a <sup>123</sup> I-MIBG scan at diagnosis.
Jadvar 2005	No original research: review.
Jofré 2007	No original research: review.
Kairemo 1998	Included patients not suspected for neuroblastoma.
Kaste 2008a	No original research: review.
Kaste 2008b	No original research: review.
Keidar 2003	No original research: review.
Kim 2006	No original research: review.
Kimmig 1984	<sup>131</sup> I-MIBG.
Kimmig 1985a	Fewer than 10 patients with a <sup>123</sup> I-MIBG scan at diagnosis.
Kimmig 1985b	Fewer than 10 patients with a <sup>123</sup> I-MIBG scan at diagnosis.
Kimmig 1985c	Fewer than 10 patients with a <sup>123</sup> I-MIBG scan at diagnosis.
Kleis 2009	Fewer than 10 patients with a <sup>123</sup> I-MIBG scan at diagnosis.
Klingebiel 1992	Fewer than 10 patients with a <sup>123</sup> I-MIBG scan at diagnosis.
Knight 1996	Included patients not suspected for neuroblastoma.
Koizumi 1994	Fewer than 10 patients with a <sup>123</sup> I-MIBG scan at diagnosis.
Krausz 2006	No original research: review.
Kroiss 2011	Fewer than 10 patients with a <sup>123</sup> I-MIBG scan at diagnosis.
Kroiss 2012	Letter to the editor (comment on a study already assessed in this review ( <a href="#">Kroiss 2011</a> )).
Kumar 1988	<sup>131</sup> I-MIBG.
Kumar 2008	Fewer than 10 patients with a <sup>123</sup> I-MIBG scan at diagnosis.

Study	Reason for exclusion
<a href="#">Kumar 2010</a>	Included patients not suspected for neuroblastoma.
<a href="#">Kumar 2011</a>	Patients older than 18 years old.
<a href="#">Kushner 2001</a>	Fewer than 10 patients with a MIBG scan at diagnosis.
<a href="#">Kushner 2006</a>	No original research: highlight.
<a href="#">Kushner 2009a</a>	No original research: reply.
<a href="#">Kushner 2009b</a>	Included patients not suspected for neuroblastoma.
<a href="#">Ladenstein 1993</a>	Study was not primary diagnostic (therapy).
<a href="#">Ladenstein 2011</a>	The same study as <a href="#">Lewington 2011</a> .
<a href="#">Ladenstein 2012</a>	<sup>131</sup> I-MIBG.
<a href="#">Larcos 1996</a>	Included patients not suspected for neuroblastoma.
<a href="#">Lastoria 1993</a>	Fewer than 10 patients with a <sup>123</sup> I-MIBG scan at diagnosis.
<a href="#">Le Néel 1991</a>	Included patients not suspected for neuroblastoma.
<a href="#">Lesslie 2007</a>	No original research: review.
<a href="#">Leung 1997</a>	Included patients not suspected for neuroblastoma.
<a href="#">Lewington 2009</a>	Study was not primary diagnostic.
<a href="#">Lewington 2011</a>	Study was not primary diagnostic.
<a href="#">Ley 2011</a>	No original research: review.
<a href="#">Limouris 1997</a>	Fewer than 10 patients with a <sup>123</sup> I-MIBG scan at diagnosis.
<a href="#">Lucignani 2011</a>	No original research: review (no eligible studies identified).
<a href="#">Lumbroso 1988a</a>	Duplicate publication of <a href="#">Lumbroso 1988b</a> .
<a href="#">Lumbroso 1990</a>	No original research: review.
<a href="#">Ma 2007</a>	No original research: review.
<a href="#">Mastrangelo 1987</a>	No original research: summary MIBG symposium.
<a href="#">Matheja 2001</a>	Included patients not suspected for neuroblastoma.
<a href="#">Matthay 2003a</a>	<sup>131</sup> I-MIBG.
<a href="#">Matthay 2003b</a>	Study was not primary diagnostic.
<a href="#">McCloskey 2010</a>	Included patients not suspected for neuroblastoma.
<a href="#">McEwan 1986</a>	No original research: review.

Study	Reason for exclusion
Melino 1989	Not human: in vitro.
Melzer 2011	Fewer than 10 patients with a <sup>123</sup> I-MIBG scan at diagnosis.
Mena Bares 2009	Fewer than 10 patients with a <sup>123</sup> I-MIBG scan at diagnosis.
Messa 1992	Included patients not suspected for neuroblastoma.
Messina 2006	Study was not primary diagnostic.
Miceli 1986	<sup>131</sup> I-MIBG.
Mitjavila 1991	No original research: review.
Mitjavila 2002	No original research: editorial.
Mitty 1985	No original research: review.
Montravers 1993	Fewer than 10 patients with a <sup>123</sup> I-MIBG scan at diagnosis.
Murphy 2008	Fewer than 10 patients with a <sup>123</sup> I-MIBG scan at diagnosis.
Nakai 1997	<sup>131</sup> I-MIBG.
Ng 1993	No original research: review.
Nguyen 2010	Letter to the editor (comment on a study already assessed in this review ( <a href="#">Sharp 2009a</a> )).
O'Hara 1999	No original research: review.
Okuyama 2001	Fewer than 10 patients with a <sup>123</sup> I-MIBG scan at diagnosis.
Okuyama 2002	Study was not primary diagnostic.
Okuyama 2003	Study was not primary diagnostic.
Pein 1995	No original research: review.
Peng 2010	No original research: review.
Perel 1999	Unclear which MIBG-scans were <sup>123</sup> I-labelled; upon consultation the authors were unable to clarify this.
Petjak 1997	Study was not primary diagnostic.
Pinto 2010	Study was not primary diagnostic.
Plowman 1997	Letter to the editor (comment).
Priestley 1993	No original research: review.
Pritchard 1988	Fewer than 10 patients with a <sup>123</sup> I-MIBG scan at diagnosis.
Pritchard 2002	Letter to the editor (comment on a study already assessed in this review ( <a href="#">Brodeur 1993</a> )).

Study	Reason for exclusion
Quigley 2005	Included patients not suspected for neuroblastoma.
Reavey 2010	Fewer than 10 patients with a <sup>123</sup> I-MIBG scan at diagnosis.
Regelink 2002	Included patients not suspected for neuroblastoma.
Reuland 2001	Fewer than 10 patients with a <sup>123</sup> I-MIBG scan at diagnosis.
Robbins 2000	No original research: review.
Roh 2008	Included patients not suspected for neuroblastoma.
Rozovsky 2008	Fewer than 10 patients with a <sup>123</sup> I-MIBG scan at diagnosis.
Rubello 2007	No original research: review.
Rufini 1995	Fewer than 10 patients with a <sup>123</sup> I-MIBG scan at diagnosis.
Rufini 1996	Fewer than 10 patients with a <sup>123</sup> I-MIBG scan at diagnosis.
Saadullah 2009	<sup>131</sup> I-MIBG.
Sano 2012	Study was not primary diagnostic.
Sasajima 2006	Fewer than 10 patients with a <sup>123</sup> I-MIBG scan at diagnosis.
Satharasinghe 2009	Fewer than 10 patients with a <sup>123</sup> I-MIBG scan at diagnosis.
Sauer 1985	Fewer than 10 patients with a <sup>123</sup> I-MIBG scan at diagnosis.
Sautter-Bihl 1991	Unclear which MIBG-scans were <sup>123</sup> I-labelled; upon consultation the authors were unable to clarify this.
Scanga 2004	Less than 10 patients with a <sup>123</sup> I-MIBG scan at diagnosis.
Schäffer 1991	Included patients not suspected for neuroblastoma.
Shammas 2009	No original research: review.
Shapiro 1990	No original research: review.
Shapiro 1993	No original research: review.
Shapiro 1994	Fewer than 10 patients with a <sup>123</sup> I-MIBG scan at diagnosis.
Sharp 2008	No original research: review (no eligible studies identified).
Shulkin 1995	Fewer than 10 patients with a <sup>123</sup> I-MIBG scan at diagnosis.
Shulkin 1996	Fewer than 10 patients with a <sup>123</sup> I-MIBG scan at diagnosis.
Sisson 1986	No original research: review.
Sutton 1982	No original research: review.

Study	Reason for exclusion
Taggart 2009	Study was not primary diagnostic.
Tahir 2009	No original research: review.
Troncone 1990	<sup>131</sup> I-MIBG.
Vanchieri 1993	No original research: review.
Vatankulu 2011	Included patients not suspected for neuroblastoma.
Volchenboum 2009	No original research: review.
Wang 2010	Fewer than 10 patients with a <sup>123</sup> I-MIBG scan at diagnosis.
Weckesser 2009	No original research: review.
Yang 2003	Included patients not suspected for neuroblastoma.
Yanik 2010	Study was not primary diagnostic.
Ythier 1987	Fewer than 10 patients with a neuroblastoma at diagnosis.
Zerva 2005	No original research: review.
Zhang 2009	No original research: review.

### Characteristics of studies awaiting classification [ordered by study ID]

#### Abrahamsen 1995

Clinical features and settings	<p>Inclusion period: September 1984 to December 1993.</p> <p>Patient population: 36 patients with suspected neuroblastoma and 125 <sup>123</sup>I- and <sup>131</sup>I-MIBG scans</p> <p>Consecutive series: yes.</p> <p>Diagnostic work-up: standard investigations like CT and US.</p> <p>Time spans symptoms-index test, symptoms-reference standard and index test-reference standard: n.r.</p> <p>Treatment between index test-reference standard: n.r.</p>
Participants	<p>Included patients: 36 children with suspected neuroblastoma and a <sup>123</sup>I- or <sup>131</sup>I-MIBG scan at diagnosis; in 19 patients the diagnosis was confirmed by histopathology, in 17 patients it was not.</p> <p>Median age at diagnosis: n.r. for patients with <sup>123</sup>I-MIBG scans separate from those with <sup>131</sup>I-MIBG scans; for all 36 patients: 2 years and 10 months (range 1 month to 14 years and 10 months); for the 19 patients with confirmed neuroblastoma at first diagnosis: 2 years and 9 months (range 1 to 10 years and 10 months); for the 17 patients without neuroblastoma: 2 years and 10.5 months (range 9 months to 14 years and 10 months).</p> <p>Sex distribution: 20 boys (56%), 16 girls (44%); for the 19 patients with confirmed neuroblastoma at first diagnosis: 9 boys (47%), 10 girls (53%); for the 17 patients without neuroblastoma: 11 boys (65%), 6 girls (35%).</p>

**Abrahamsen 1995** (Continued)

	INSS stage for the 19 patients with confirmed neuroblastoma: 1 patient stage 1, 7 patients stage 3, 8 patients stage 4 and 3 patients stage 4S.
Study design	Retrospective cohort study.
Target condition and reference standard(s)	Target condition: newly diagnosed neuroblastoma. Reference standard: histopathology in 19 patients.
Index and comparator tests	<p>Index test: <math>^{123}\text{I}</math>-MIBG and <math>^{131}\text{I}</math>-scintigraphy.</p> <p>Radiofarmakon: <math>^{123}\text{I}</math>- and <math>^{131}\text{I}</math>-MIBG.</p> <p>Dose: 74 MBq for children weighing less than 8 kg, 111 MBq for children weighing more than 20 kg and 185 MBq for children weighing more than 20 kg.</p> <p>Collimator: n.r.</p> <p>Matrix: 64 x 64.</p> <p>Acquisition protocol: anterior and posterior images of the head and the whole truncus.</p> <p>Acquisition time: 4, 24 and 48 hours after injection.</p> <p>Acquisition duration: 300 seconds, 300,000 to 400,000 counts.</p> <p>Interfering medication: n.r.</p> <p>Thyroid prophylaxis: supersaturated potassium iodide twice daily starting one day before the examination and for three days.</p> <p>Positive test result: the level of tumour uptake similar to or higher than that in the salivary glands, myocardium and liver.</p> <p>Number of observers: <math>^{123}\text{I}</math>-MIBG scans were interpreted by one specialist, without knowledge of the diagnosis at the time of the first <math>^{123}\text{I}</math>-MIBG scan.</p> <p>Expertise of observers: n.r.</p> <p>Interobserver concordance: n.r.</p>
Follow-up	n.r.
Notes	<p>Results not reported for <math>^{123}\text{I}</math>-MIBG scans separately from the <math>^{131}\text{I}</math>-MIBG scans.</p> <p>Contact information of the authors: not available.</p>

**Ady 1995**

Clinical features and settings	<p>Inclusion period: June 1989 to December 1992.</p> <p>Patient population: 37 patients with newly diagnosed stage 4 neuroblastoma of which 27 were included in this study; nine children were excluded because of unavailable data at mid-course and one other for lack of <math>^{123}\text{I}</math>-MIBG uptake (negative scan).</p> <p>Consecutive series: yes.</p> <p>Diagnostic work-up: clinical examination, bone marrow status and all imaging data: at least CT scan and <math>^{123}\text{I}</math>-MIBG scan, and in certain cases bone scan, X-rays and MRI scan to explore metastases to bone and bone marrow, liver, distant lymph nodes, skin, lungs and central nervous system.</p>
--------------------------------	---

**123I-MIBG scintigraphy and 18F-FDG-PET imaging for diagnosing neuroblastoma (Review)**

**Ady 1995** (Continued)

	<p>Time spans symptoms-index test, symptoms-reference standard and index test-reference standard: n.r.</p> <p>Treatment between index test-reference standard: n.r.</p>
Participants	<p>Included patients: 27 children with neuroblastoma at first diagnosis.</p> <p>Median age at diagnosis: n.r.; mean age at diagnosis: 37 months (range 10 to 97 months).</p> <p>Sex distribution: 19 boys (70%), 8 girls (30%).</p> <p>INSS stage: all stage 4 neuroblastoma.</p>
Study design	<p>Cohort study. N.r. whether the study was retrospective or prospective.</p>
Target condition and reference standard(s)	<p>Target condition: newly diagnosed neuroblastoma.</p> <p>Reference standard: n.r. for the primary tumour.</p> <p>For metastases: bone marrow status by bone marrow cytology, bone histology (at least four samples) and immunocytology. In case of discrepant results from different methods, the most abnormal data were considered as definitive.</p>
Index and comparator tests	<p>Index test: <sup>123</sup>I-MIBG scintigraphy.</p> <p>Radiofarmakon: <sup>123</sup>I-MIBG.</p> <p>Dose: 3.7 MBq/kg, with a maximum of 110 MBq</p> <p>Collimator: low energy, high definition.</p> <p>Matrix: 256 x 1024 for WB scans and 256 x 256 for lateral views (4 mid-frame).</p> <p>Acquisition protocol: anterior and posterior WB scans and lateral views of the head.</p> <p>Acquisition time: 2.2 to 26 hours after injection.</p> <p>Acquisition duration: 12 min/m for WB scans.</p> <p>Interfering medication: not reported.</p> <p>Thyroid prophylaxis: not reported.</p> <p>Positive test result: n.r.</p> <p>Number of observers: two independent specialists; to assess reproducibility of the method, images of 16/27 patients were interpreted independently by four investigators (including the previous two specialists).</p> <p>Expertise of investigators: n.r.</p> <p>Interobserver concordance: n.r.</p>
Follow-up	<p>Median follow-up: 18 months (range 1 to 52 months) after diagnosis.</p>
Notes	<p>Results were n.r. for <sup>123</sup>I-MIBG scans at first diagnosis separately from <sup>123</sup>I-MIBG scans during follow-up.</p> <p>Contact information of the study authors: not available.</p>

**Boubaker 2012**

Clinical features and settings	<p>Inclusion period: n.r.</p> <p>Patient population: 357 patients with newly diagnosed high risk stage 4 neuroblastoma (HR-NBL1/SIOPEN trial).</p> <p>Consecutive series: n.r.</p> <p>Diagnostic work-up: n.r.</p> <p>Time spans symptoms-index test, symptoms-reference standard and index test-reference standard: n.r.</p> <p>Treatment between index test-reference standard: n.r.</p>
Participants	<p>Included patients: 357 patients with newly diagnosed high risk stage 4 neuroblastoma.</p> <p>Median age at first diagnosis: n.r.</p> <p>Sex distribution: n.r.</p> <p>INSS stage: n.r.</p>
Study design	<p>Cohort study with patients from the (HR-NBL1/SIOPEN trial). N.r. whether the study was retrospective or prospective.</p>
Target condition and reference standard(s)	<p>Target condition: newly diagnosed high risk stage 4 neuroblastoma.</p> <p>Reference standard: n.r.</p>
Index and comparator tests	<p>Index test: <sup>123</sup>I-MIBG scintigraphy.</p> <p>Radiofarmakon: <sup>123</sup>I-MIBG.</p> <p>Dose: n.r.</p> <p>Collimator: n.r.</p> <p>Matrix: n.r.</p> <p>Acquisition protocol: n.r.</p> <p>Acquisition time: n.r.</p> <p>Acquisition duration: n.r.</p> <p>Interfering medication: not reported.</p> <p>Thyroid prophylaxis: not reported.</p> <p>Positive test result: skeletal <sup>123</sup>I-MIBG uptake.</p> <p>Number and expertise of observers: eight nuclear medicine experts in four groups.</p> <p>Interobserver concordance: n.r.</p>
Follow-up	<p>n.r.; some patients were followed for approximately five years.</p>
Notes	<p>This study has not been published in full-text (as of December 2012), but has been presented at the ANR conference 2012.</p> <p>Results not reported for <sup>123</sup>I-MIBG scans at first diagnosis separately from the <sup>123</sup>I-MIBG scans during follow-up.</p> <p>We could not get in contact with the study authors.</p>



**Claudiani 1995**

Clinical features and settings	<p>Stuy period: beginning of 1985 to the middle of 1993.</p> <p>Patient population: 97 patients with suspected or histologically proven neural crest tumours of which 46 with a <sup>123</sup>I-MIBG scan.</p> <p>Consecutive series: n.r.</p> <p>Diagnostic work-up: US, X-ray, CT or MRI, or a combination of these tests, within a short period before or after <sup>123</sup>I-MIBG scintigraphy.</p> <p>Time spans symptoms-index test, symptoms-reference standard and index test-reference standard: n.r.</p> <p>Treatment between index test-reference standard: n.r.</p>
Participants	<p>Included patients: 46 of 97 children with suspected or histologically proven neural crest tumours had a <sup>123</sup>I-MIBG scan.</p> <p>Median age: n.r. for these 46 included patients; for all 97 patients the range : 6 months to 12 years.</p> <p>Sex distribution:n.r. for these 46 included patients; for all 97 patients:50 boys (52%), 47 girls (48%).</p> <p>INSS stage: n.r. According to the Italian Association of Paediatric Hematology and Oncology (AIEOP) staging criteria and on the basis of the biopsy results staging for all 97 patients was: 3 group 1 neuroblastoma, 12 group 2 neuroblastoma, 25 group 3 neuroblastoma, 45 group 4 neuroblastoma, 2 group 5 neuroblastoma, 5 group 2 to 4 ganglioneuroblastoma and 5 ganglioneuromas.</p>
Study design	<p>Cohort study with patients from the HR-NBL1/SIOPEN trial. N.r. whether the study was retrospective or prospective.</p>
Target condition and reference standard(s)	<p>Target condition: newly diagnosed neuroblastoma.</p> <p>Reference standard: histopathology (tumour biopsy with cytological and histological examination).</p>
Index and comparator tests	<p>Index test: <sup>123</sup>I-MIBG and <sup>131</sup>I-MIBG scintigraphy.</p> <p>Radiofarmacon: <sup>123</sup>I-MIBG.</p> <p>Dose: 1.85 MBq/kg.</p> <p>Collimator: low-energy, all-purpose.</p> <p>Matrix: not reported.</p> <p>Acquisition protocol: n.r.</p> <p>Acquisition time: 24 hours after injection.</p> <p>Acquisition duration: n.r.</p> <p>Interfering medication: not reported.</p> <p>Thyroid prophylaxis: not reported.</p> <p>Positive test result: n.r</p> <p>Number and expertise of observers: n.r.</p> <p>Interobserver concordance: n.r.</p>
Follow-up	<p>n.r.</p>

**Claudiani 1995** (Continued)

Notes Results n.r. for  $^{123}\text{I}$ -MIBG scans separately from the  $^{131}\text{I}$ -MIBG scans.  
 Contact information of the authors: not available.

**Fania 2011**

Clinical features and settings Study period: n.r.  
 Patient population: 11 patients with recurrent INSS stage 4 neuroblastoma previously treated with first line therapy according European protocol NB-HR 01.  
 Consecutive series: n.r.  
 Diagnostic work-up: n.r.  
 Time spans symptoms-index test, symptoms-reference standard and index test-reference standard: n.r.  
 Treatment between index test-reference standard: n.r.

Participants Included patients: 11 patients with recurrent neuroblastoma.  
 Mediang age: n.r.; mean age was 10.8 years (range 3 to 15 years).  
 Sex distribution: 7 boys (64%), 4 girls (36%).  
 INSS stage: all stage 4.

Study design Cohort study. N.r. whether the study was retrospective or prospective.

Target condition and reference standard(s) Target condition: recurrent INSS stage 4 neuroblastoma.  
 Reference standard of the primary tumour: n.r.  
 Reference standard of metastases: histopathology (bone marrow aspirates and trephine biopsies), clinical imaging, or both.

Index and comparator tests Index test: FDG-PET scintigraphy.  
 Comparator test: MIBG scintigraphy.  
 Radiofarmacon: FDG-PET and MIBG.  
 Dose: n.r.  
 Equipment: n.r.  
 Acquisition protocol:n.r.  
 Acquisition time: n.r.  
 Acquisition duration: n.r.  
 Interfering medication: n.r.  
 Thyroid prophylaxis: n.r.  
 Positive test result: n.r.  
 Number and expertise of observers: n.r.

**Fania 2011** (Continued)

	Interobserver concordance: n.r.
Follow-up	n.r.
Notes	<p>Not published in full-text (as of December 2012), but presented at the EANM 2011.</p> <p>It was n.r. which tracers were used for MIBG- and FDG-PET scintigraphy.</p> <p>We could not get in contact with the authors.</p>

**Feine 1987**

Clinical features and settings	<p>Study period: n.r.</p> <p>Patient population: 37 patients with suspected or histologically proven neuroblastoma with <math>^{123}\text{I}</math>- (n = 49) and <math>^{131}\text{I}</math>-MIBG scans (n = 66).</p> <p>Consecutive series: no; multicenter study, no further information reported.</p> <p>Diagnostic work-up: n.r.</p> <p>Time spans symptoms-index test, symptoms-reference standard and index test-reference standard: n.r.</p> <p>Treatment between index test-reference standard: n.r.</p>
Participants	<p>Included patients; 37 patients with suspected or histologically proven neuroblastoma.</p> <p>Median age: n.r.</p> <p>Sex distribution: n.r.</p> <p>INSS stage: n.r.</p>
Study design	Multicenter study. No further information reported.
Target condition and reference standard(s)	<p>Target condition: newly diagnosed or recurrent neuroblastoma.</p> <p>Reference standard: histopathology.</p>
Index and comparator tests	<p>Index test: MIBG scintigraphy.</p> <p>Radiofarmacon: MIBG.</p> <p>Dose: n.r.</p> <p>Collimator: n.r.</p> <p>Matrix: n.r.</p> <p>Acquisition protocol: n.r.</p> <p>Acquisition time: n.r.</p> <p>Acquisition duration: n.r.</p> <p>Interfering medication: n.r.</p> <p>Thyroid prophylaxis: n.r.</p> <p>Positive test result: n.r.</p>

**Feine 1987** (Continued)

	Number and expertise of observers: n.r.
	Interobserver concordance: n.r.
Follow-up	Length of follow-up: n.r.
Notes	Results were n.r. for <sup>123</sup> I-MIBG scans separately from the <sup>131</sup> I-MIBG scans.
	Contact information: not available.

**Ferris 1992**

Clinical features and settings	Study period: September 1984 to February 1989. Patient population: 23 patients considered to have stage 4 neuroblastoma. Consecutive series: n.r. Diagnostic work-up: n.r. Time spans symptoms-index test, symptoms-reference standard and index test-reference standard: n.r. Treatment between index test-reference standard: n.r.
Participants	Included patients: 23 patients with suspected neuroblastoma. Median age: n.r. Sex distribution: n.r. INSS stage: all stage 4 .
Study design	Prospective.
Target condition and reference standard(s)	n.r.
Index and comparator tests	Index test: <sup>123</sup> I-MIBG scintigraphy. Radiofarmakon: <sup>123</sup> I-MIBG. Dose: 0.1 mCi/kg. Collimator: n.r. Matrix: n.r. Acquisition protocol: images of the head, thorax, abdomen, and extremities. Acquisition time: 3, 24, and 48 hours after injection. Acquisition duration: n.r. Interfering medication: n.r. Thyroid prophylaxis: n.r. Positive test result: n.r. Number and expertise of observers: n.r.

**Ferris 1992** (Continued)

	Interobserver concordance: n.r.
	.
Follow-up	n.r.
Notes	Age distribution of 23 patients with neuroblastoma n.r. We could not get into contact with the authors.

**Fischer 1989**

Clinical features and settings	<p>Study period: since 1981.</p> <p>Patient population: 300 patients suspected for having a catecholamine producing tumour of which 21 patients with suspected neuroblastoma after elevated urinary catecholamines.</p> <p>Consecutive series: yes.</p> <p>Diagnostic work-up: n.r.</p> <p>Time spans symptoms-index test, symptoms-reference standard and index test-reference standard: n.r.</p> <p>Treatment between index test-reference standard: n.r.</p>
Participants	<p>Included patients: 21 children with suspected neuroblastoma.</p> <p>Median age: n.r.</p> <p>Sex distribution: n.r.</p> <p>INSS stage: n.r; all stage 3 or 4.</p>
Study design	n.r.
Target condition and reference standard(s)	<p>Target condition: newly diagnosed neuroblastoma.</p> <p>Reference standard: n.r.</p>
Index and comparator tests	<p>Index test: <sup>123</sup>I-MIBG and <sup>131</sup>I-MIBG scintigraphy.</p> <p>Radiofarmakon: <sup>123</sup>I-MIBG.</p> <p>Dose: 185 MBq.</p> <p>Collimator: n.r.</p> <p>Matrix: n.r.</p> <p>Acquisition protocol: posterior scans of the head, neck, thorax and abdomen; anterior scans of the pelvis; images of the upper and lower extremities in children suspected of neuroblastoma.</p> <p>Acquisition time: 2 to 24 hours after injection.</p> <p>Acquisition duration: n.r.</p> <p>Interfering medication: n.r.</p> <p>Tyroid prophylaxis: n.r.</p> <p>Positive test result: n.r.</p>

**123I-MIBG scintigraphy and 18F-FDG-PET imaging for diagnosing neuroblastoma (Review)**

**Fischer 1989** (Continued)

	Number and expertise of observers: n.r.
	Interobserver concordance: n.r.
Follow-up	n.r.
Notes	Results n.r. for <sup>123</sup> I-MIBG scans separately from the <sup>131</sup> I-MIBG scans. Contact information of the authors: not available.

**Gelfand 1994**

Clinical features and settings	Study period: n.r. Patient population: 25 patients with neural crest tumours of which 20 with neuroblastoma Consecutive series: n.r. Diagnosis work-up: n.r. Time spans symptoms-index test, symptoms-reference standard and index test-reference standard: n.r. Treatment between index test-reference standard: n.r.
Participants	Included patients: children with suspected neuroblastoma and a <sup>123</sup> I-MIBG scan at diagnosis. Median age: n.r. Sex distribution: n.r. INSS stage: n.r.
Study design	Retrospective cohort study.
Target condition and reference standard(s)	Target condition: newly diagnosed neuroblastoma. Reference standard: n.r.
Index and comparator tests	Index test: <sup>123</sup> I-MIBG scintigraphy. The diagnostic utility of <sup>123</sup> I-MIBG SPECT was evaluated as a supplement to planar imaging. Radiofarmacon: <sup>123</sup> I-MIBG. Dose: 0.140 mCi/kg. Collimator: high-resolution. Matrix: n.r. Acquisition protocol: WB planar and SPECT scans; and for the 48 hours post injection images: 10-minutes images of the abdomen, chest (particularly if the primary tumour arose in the chest) and any other locations where the findings on the planar study at 24 hours were difficult to interpret. Acquisition time: 24 hours after injection and 48 hours after injection in all patients who were able to return for repeat imaging. Acquisition duration: 300,000 counts/image or 7.2 cm/min. SPECT: Triad triple-detector SPECT camera, 40 increments, 40 sec/frame (24.5 cm axial field of view) or 30 sec/frame (49 cm axial field of view), body contouring, 20% window around 159 keV and low-energy, ultrahigh-resolution collimator.

**Gelfand 1994** (Continued)

Processing parameters of SPECT imaging: Hanning filter, 0.70 to 0.80 cycles/cm cutoff, coronal, sagittal and transaxial displays and cine and static displays of volume-rendered images.

Interfering medication: n.r.

Thyroid prophylaxis: n.r.

A description of a positive test result was not reported.

Number of observers: two experienced readers enumerated the number of abnormal sites on the planar and SPECT studies and rated the certainty of interpretation for each study on a scale from 0.1 (low certainty) to 1.0 (high).

Expertise of observers: n.r.

Interobserver concordance: n.r.

Follow-up	n.r.
Notes	<p>Results n.r. for 20 patients with neuroblastoma separately for those with other tumours. Results n.r. for <sup>123</sup>I-MIBG scans at first diagnosis separately from <sup>123</sup>I-MIBG scans during follow-up.</p> <p>We could not get into contact with the authors.</p>

**Ginsburg 2012**

Clinical features and settings	<p>Study period: n.r.</p> <p>Patient population: 49 patients with neuroblastoma and 86 <sup>123</sup>I-MIBG scans.</p> <p>Consecutive series: yes.</p> <p>Diagnosis work-up: n.r.</p> <p>Time spans symptoms-index test, symptoms-reference standard and index test-reference standard: n.r.</p> <p>Treatment between index test-reference standard: n.r.</p>
Participants	<p>Included patients: children with neuroblastoma at first diagnosis.</p> <p>Median age: n.r.</p> <p>Sex distribution: n.r.</p> <p>INSS stage: n.r.</p>
Study design	Retrospective cohort study.
Target condition and reference standard(s)	<p>Target condition: newly diagnosed neuroblastoma.</p> <p>Reference standard: n.r.</p>
Index and comparator tests	<p>Index test: <sup>123</sup>I-MIBG scintigraphy.</p> <p>Radiofarmacon: <sup>123</sup>I-MIBG.</p> <p>Dose: 0.140 mCi/kg.</p> <p>Collimator: n.r.</p> <p>Matrix: n.r.</p>

**123I-MIBG scintigraphy and 18F-FDG-PET imaging for diagnosing neuroblastoma (Review)**

**Ginsburg 2012** (Continued)

Acquisition protocol: WB and SPECT scans.

Acquisition time: 24 hours after injection.

Acquisition duration: n.r.

SPECT: n.r.

Interfering medication: n.r.

Thyroid prophylaxis: n.r.

Positive test result: n.r.

Number and expertise of observers: two radiologists visually compared the tumour detectability on four and 24 hours delayed planar images for bony and soft tissue lesions, as well as the detectability of soft tissue tumour on four and 24 hours delayed SPECT images.

Interobserver concordance: the agreement between the two radiologists was moderate for the detection of bony ( $\kappa = 0.49$ ) and soft tissue tumours ( $\kappa = 0.50$ ) on planar images as well as for the detection of soft tissue tumour with SPECT ( $\kappa = 0.49$ ).

Follow-up	n.r.
Notes	<p>Not published in full-text (as of December 2012), but presented at the WMIC conference 2011.</p> <p>Results n.r. for <math>^{123}\text{I}</math>-MIBG scans at first diagnosis separately from the <math>^{123}\text{I}</math>-MIBG scans during follow-up.</p> <p>We could not get in contact with the authors.</p>

**Goo 2005**

Clinical features and settings	<p>Study period: May 2003 to September 2004.</p> <p>Patient population: 41 children with a WB MRI scan of which thirty-six had conventional oncological imaging within 15 days (26 <math>^{123}\text{I}</math> MIBG scans)</p> <p>Consecutive series: n.r.</p> <p>Time spans symptoms-index test, symptoms-reference standard and index test-reference standard: n.r.</p> <p>Treatment between index test-reference standard: n.r.</p>
Participants	<p>Included patients: 11 children with a neuroblastoma and a <math>^{123}\text{I}</math>-MIBG scan at first diagnosis.</p> <p>Median age: n.r. for these 11 included patients; for all 36 patients: 3.5 years (range 4 months to 12 years).</p> <p>Sex distribution: n.r. for these 11 included patients; for all 36 patients: 21 boys (58%), 15 girls (42%).</p> <p>INSS stage: n.r.</p>
Study design	n.r.
Target condition and reference standard(s)	<p>Target condition: newly diagnosed neuroblastoma.</p> <p>Reference standard: n.r.</p>
Index and comparator tests	Index test: $^{123}\text{I}$ -MIBG scintigraphy.

**123I-MIBG scintigraphy and 18F-FDG-PET imaging for diagnosing neuroblastoma (Review)**



**Goo 2005** (Continued)

	<p>Radiofarmakon: <math>^{123}\text{I}</math>-MIBG.</p> <p>Dose: n.r.</p> <p>Collimator: n.r.</p> <p>Matrix: n.r.</p> <p>Acquisition protocol: standard protocols of the Asian Medical Centre in Seoul.</p> <p>Acquisition time: n.r.</p> <p>Acquisition duration: n.r.</p> <p>Interfering medication: not reported.</p> <p>Thyroid prophylaxis: not reported.</p> <p>Positive test result: n.r.</p> <p>Number and expertise of observers: one paediatric radiologist.</p> <p>Interobserver concordance: n.r.</p>
Follow-up	n.r.
Notes	<p>Results n.r. for 11 patients with neuroblastoma separately for those with other tumours.</p> <p>We could not get into contact with the authors.</p>

**Hadj-Djilani 1995**

Clinical features and settings	<p>Study period: n.r.</p> <p>Patient population: 27 patients with neuroblastoma.</p> <p>Consecutive series: n.r.</p> <p>Diagnostic work-up: physical examinations, urinary catecholamines, bone marrow biopsies and smears and radiological studies.</p> <p>Time span between <math>^{123}\text{I}</math>-MIBG scintigraphy and bone marrow biopsy: two to 15 days. Time spans between symptoms and index test, between symptoms and reference standard and between index test and reference standard: n.r.</p> <p>Treatment between index test and reference standard: n.r.</p>
Participants	<p>Included patients: 24 children with neuroblastoma and a <math>^{123}\text{I}</math>-MIBG scan at first diagnosis.</p> <p>Median age: n.r. for these 24 included patients; for all 27 patients the mean age: 3.5 years (range ten days to 24 years).</p> <p>Sex distribution: n.r. for these 24 included patients; for all 27 patients: 19 boys (70%), 8 girls (30%).</p> <p>INSS stage: n.r. for these 24 included patients; for all 27 patients: 2 stage 1, 6 stage 2, 7 stage 3, 9 stage 4 and 3 stage 4.</p>
Study design	Retrospective cohort study.
Target condition and reference standard(s)	<p>Target condition: newly diagnosed neuroblastoma.</p> <p>Reference standard of primary tumour: histopathology.</p>

**123I-MIBG scintigraphy and 18F-FDG-PET imaging for diagnosing neuroblastoma (Review)**

**Hadj-Djilani 1995** (Continued)

Reference standard of metastases: bone marrow biopsy or aspiration.

Index and comparator tests

Index test: <sup>123</sup>I-MIBG scintigraphy.

Radiofarmacon: <sup>123</sup>I-MIBG.

Dose: 3.7 MBq/kg.

Collimator: n.r.

Matrix: n.r.

Acquisition protocol: WB planar scans. Anterior and posterior images of the whole-body and spot images were recorded with a dual-head gamma camera (both heads had a 3/4 inch thick crystal, 37 photo multipliers (PM) and low-energy all-purpose collimators). Average acquisition counts were 300 kcounts for the head (anterior, posterior and left and right lateral views), 500 kcounts for the anterior and posterior thorax, abdomen and pelvis, and 200 kcounts for the lower extremities. In the case of insufficient count rates, a minimum acquisition time of 20 minutes was preset for the views of the trunk, and of 10 minutes for the head and lower extremities. In some cases, single-photon emission tomography (SPET) of a given area was performed 24 hours post injection.

Acquisition time: 6, 24 and 48 hours after injection.

Acquisition duration: n.r.

Interfering medication: n.r.

Thyroid prophylaxis: lugol solution one day before and three days after <sup>123</sup>I-MIBG injection.

Positive test result: n.r.

Number and expertise of observers: n.r.

Interobserver concordance: n.r.

Follow-up

n.r.

Notes

Results n.r. for children between younger than 18 years separately from two adults. Results n.r. for <sup>123</sup>I-MIBG scans separately from <sup>131</sup>I-MIBG scans.

Contact information of the authors: not available.

**Hervas 2001**

Clinical features and settings

Study period: n.r.

Patient population: 20 patients with neuroblastoma with 47 <sup>123</sup>I-MIBG scans.

Consecutive series: n.r.

Diagnostic work-up: n.r.

Time spans between symptoms and index test, between symptoms and reference standard and between index test and reference standard: n.r.

Treatment between index test and reference standard: n.r.

Participants

Included patients: children with newly diagnosed neuroblastoma.

Median age: n.r.; mean age: 4.4 years (SD 2.45).

Sex distribution: 12 boys (60%), 8 girls (40%).

**123I-MIBG scintigraphy and 18F-FDG-PET imaging for diagnosing neuroblastoma (Review)**

**Hervas 2001** (Continued)

	INSS stage: two stage 1, three stage 2, three stage 3 and 12 stage 4.
Study design	Retrospective.
Target condition and reference standard(s)	Target condition: neuroblastoma. Reference standard: histology.
Index and comparator tests	Index test: <sup>123</sup> I-MIBG scintigraphy. Radiofarmakon: <sup>123</sup> I-MIBG. Dose: 3,7 MBq/Kg. Collimator: low energy. Matrix: n.r. Acquisition protocol: thorax, abdomen, lateral skull, and occasionally the extremities. Acquisition time: 3, 24, and 48 hours after injection. Acquisition duration: n.r. Interfering medication: n.r. Thyroid prophylaxis: n.r., Positive test result: when abnormal foci were observed (adrenal or extradrenals, or both) with increased uptake. Number and expertise of observers: n.r. Interobserver concordance: n.r.
Follow-up	n.r.
Notes	Results n.r. for 20 patients with neuroblastoma at diagnosis separately from those during treatment. We could not get into contact with the authors.

**Ishii 2000**

Clinical features and settings	Currently unclear.
Participants	Currently unclear.
Study design	Currently unclear.
Target condition and reference standard(s)	Currently unclear.
Index and comparator tests	Currently unclear.
Follow-up	Currently unclear.
Notes	Study in Japanese. We did not find a translator yet. Based on currently available information unclear whether this study fulfils the inclusion criteria.

**123I-MIBG scintigraphy and 18F-FDG-PET imaging for diagnosing neuroblastoma (Review)**

**Jacobs 1990b**

Clinical features and settings	<p>Study period: n.r.</p> <p>Patient population: 16 patients with neuroblastoma, three with retinoblastoma and one with a malignant paraganglioma; with 30 <sup>123</sup>I- (n = 17) and <sup>131</sup>I- (n = 13) MIBG scans.</p> <p>Consecutive series: n.r.</p> <p>Diagnostic work-up: n.r.</p> <p>Time spans between symptoms and index test, between symptoms and reference standard and between index test and reference standard: n.r.</p> <p>Treatment between index test and reference standard: n.r.</p>
Participants	<p>Included patients: 12 children with a neuroblastoma and a <sup>123</sup>I-MIBG scan at first diagnosis.</p> <p>Median age: n.r. for these 12 included patients; for all 16 patients: 17.5 months (range 1 to 72 months).</p> <p>Sex distribution: n.r. for these 12 included patients; for all 16 patients: 13 boys (81%), 3 girls (19%).</p> <p>INSS stage: n.r. for these 12 included patients; all 16 patients with neuroblastoma: 2 stage 1, 2 stage 2, 4 stage 3, 5 stage 4 and 3 stage 4S.</p>
Study design	Cohort study. N.r. whether the study was retrospective or prospective.
Target condition and reference standard(s)	n.r.
Index and comparator tests	<p>Index test: <sup>123</sup>I- and <sup>131</sup>I-MIBG scintigraphy.</p> <p>Radiofarmacon: <sup>123</sup>I- and <sup>131</sup>I-MIBG.</p> <p>Dose: around 2 mCi.</p> <p>Collimator: n.r.</p> <p>Matrix: n.r.</p> <p>Acquisition protocol: WB planar scans.</p> <p>Acquisition time: 24 hours after injection and 48 hours after injection in case of doubtful cases.</p> <p>Acquisition duration: n.r.</p> <p>Interfering medication: n.r.</p> <p>Thyroid prophylaxis: potassium perchlorate or lugol solution before and after <sup>123</sup>I-MIBG injection.</p> <p>Positive test result: n.r.</p> <p>Number and expertise of observers: n.r.</p> <p>Interobserver concordance: n.r.</p>
Follow-up	n.r.
Notes	<p>Results n.r. for <sup>123</sup>I-MIBG scans separately from <sup>131</sup>I-MIBG scans.</p> <p>Contact information of the authors: not available.</p>

**Kurkure 2012**

Clinical features and settings	<p>Study period: n.r.</p> <p>Patient population: 22 patients with neuroblastoma and <sup>18</sup>F-FDG-PET scans and <sup>131</sup>I-MIBG scans within a time span of three days.</p> <p>Consecutive series: n.r.</p> <p>Diagnostic work-up: n.r.</p> <p>Time spans between symptoms and index test, between symptoms and reference standard and between index test and reference standard: n.r.</p> <p>Treatment between index test and reference standard: n.r.</p>
Participants	<p>Included patients: 22 children with neuroblastoma and a <sup>18</sup>F-FDG-PET scan at first diagnosis.</p> <p>Median age: n.r.</p> <p>Sex distribution: n.r.</p> <p>INSS stage: n.r.</p>
Study design	n.r.
Target condition and reference standard(s)	<p>Target condition: newly diagnosed neuroblastoma.</p> <p>Reference standard: n.r.</p>
Index and comparator tests	<p>Index test: <sup>18</sup>F-FDG-PET scintigraphy.</p> <p>Radiofarmacon: <sup>18</sup>F-FDG-PET.</p> <p>Dose: n.r.</p> <p>Equipment: n.r.</p> <p>Acquisition protocol: n.r.</p> <p>Acquisition time: n.r.</p> <p>Acquisition duration: n.r.</p> <p>Interfering medication: n.r.</p> <p>Thyroid prophylaxis: n.r.</p> <p>Positive test result: n.r.</p> <p>Number and expertise of observers: n.r.</p> <p>Interobserver concordance: n.r.</p>
Follow-up	n.r.
Notes	<p>Not published in full-text (as of December 2012), but presented at the SIOP conference 2012.</p> <p>The abstract did not contain relevant results for this review and based on the currently available information it is unclear whether this study fulfills the inclusion criteria for this review.</p> <p>We could not get in contact with the study authors.</p>

**Lumbroso 1988b**

Clinical features and settings	<p>Study period: n.r.</p> <p>Patient population: 70 patients with neuroblastoma or ganglioneuroblastoma and with 83 <sup>123</sup>I-MIBG and 32 <sup>131</sup>I-MIBG scans.</p> <p>Consecutive series: n.r.</p> <p>Diagnostic work-up: urinary catecholamines, <sup>99m</sup>Tc-MDP bone scans, US, CT, surgery, bone marrow aspirates or biopsies, or a combination of these tests.</p> <p>Time spans between symptoms and index test and between symptoms and reference standard: n.r.</p> <p>Time span between index test and reference standard: less than 14 days.</p> <p>Treatment between index test and reference standard: n.r.</p>
Participants	<p>Included patients: children with confirmed neuroblastoma with <sup>123</sup>I-MIBG scintigraphy at first diagnosis.</p> <p>Median age: n.r. for the included patients with confirmed neuroblastoma; for all 70 patients: range of 3.7 ± 3.3 years.</p> <p>Further information currently unclear.</p>
Study design	Prospective cohort study.
Target condition and reference standard(s)	<p>Target condition: newly diagnosed neuroblastoma.</p> <p>Reference standard: combination of US, x-ray, CT, MRI and surgery.</p> <p>Reference standard of bone marrow metastases: cytological and histological examination of bone marrow aspirates or trephine biopsies of iliac bones, or both.</p>
Index and comparator tests	<p>Index test: <sup>123</sup>I-MIBG scintigraphy.</p> <p>Radiofarmacon: <sup>123</sup>I-MIBG.</p> <p>Dose: 3.7 MBq/kg.</p> <p>Collimator: n.r.</p> <p>Matrix: n.r.</p> <p>Acquisition protocol: n.r.</p> <p>Acquisition time: 24 hours after injection.</p> <p>Acquisition duration: n.r.</p> <p>Interfering medication: n.r.</p> <p>Thyroid prophylaxis: n.r.</p> <p>Positive test result: non-physiological uptake area or any bone uptake of <sup>123</sup>I-MIBG, even in the metaphyseal complex.</p> <p>Number and expertise of observers: two independent observers that were trained for 6 months.</p> <p>Interobserver concordance: n.r.</p>
Follow-up	n.r.

**Lumbroso 1988b** *(Continued)*

Notes Results n.r. for  $^{123}\text{I}$ -MIBG scans separately from the  $^{131}\text{I}$ -MIBG scans.  
 Contact information of the authors: not available.

**Moschogiannis 2011**

Clinical features and settings	Study period: 2009 to 2010. Patient population: 99 patients with suspected neuroblastoma with $^{123}\text{I}$ -MIBG scans. Consecutive series: n.r. Time spans between symptoms and index test, between symptoms and reference standard and between index test and reference standard: n.r. Treatment between index test and reference standard: n.r.
Participants	Included patients: 32 children with suspected neuroblastoma and a $^{123}\text{I}$ -MIBG scan at diagnosis. Median age: n.r. for these 32 included patients; for all 99 patients: range of 1 month to 8 years. Sex distribution: n.r. for these 32 included patients; for all 99 patients: 52 boys (53%), 47 girls (47%). INSS stage: n.r.
Study design	Cohort study. N.r. whether the study was retrospective or prospective.
Target condition and reference standard(s)	Target condition: newly diagnosed neuroblastoma. Reference standard: n.r.
Index and comparator tests	Index test: $^{123}\text{I}$ -MIBG scintigraphy. Radiofarmakon: $^{123}\text{I}$ -MIBG. Dose: n.r. Collimator: n.r. Matrix: n.r. Acquisition protocol: planar and SPECT images; a subtraction technique was applied (a kidney's image using $^{99\text{m}}\text{Tc}$ -DMSA subtracted from the $^{123}\text{I}$ -MIBG scan, achieving a better localization of the adrenal medulla as well as a more exact determination of adrenal uptake). Acquisition time: 24 hours after injection. Acquisition duration: n.r. SPECT: n.r. Interfering medication: n.r. Thyroid prophylaxis: stable iodide. Positive test result: pathological uptake. Number and expertise of observers: n.r. Interobserver concordance: n.r.

**Moschogiannis 2011** (Continued)

Follow-up	n.r.
Notes	<p>Not published in full-text (as of December 2012), but presented at the EANM conference 2011.</p> <p>Results n.r. for <sup>123</sup>I-MIBG scans at first diagnosis separately from the <sup>123</sup>I-MIBG scans during follow-up.</p> <p>Contact information of the authors: not available.</p>

**Muckle 2012**

Clinical features and settings	<p>Study period: n.r.</p> <p>Patient population: 18 patients with neuroblastoma with 44 <sup>123</sup>I-MIBG scans</p> <p>Consecutive series: n.r.</p> <p>Diagnostic work-up: n.r.</p> <p>Time spans between symptoms and index test, between symptoms and reference standard and between index test and reference standard: n.r.</p> <p>Treatment between index test and reference standard: n.r.</p>
Participants	<p>Included patients: children with newly diagnosed neuroblastoma and <sup>123</sup>I-MIBG scintigraphy at diagnosis.</p> <p>Median age: n.r. for these included patient with newly diagnosed neuroblastoma; for all 18 patients: a range of 1 month to 15 years.</p> <p>Sex distribution: n.r.</p> <p>INSS stage: n.r.</p>
Study design	n.r.
Target condition and reference standard(s)	<p>Target condition: newly diagnosed neuroblastoma.</p> <p>Reference standard: histopathology, follow-up of the patients and conventional radiological imaging, especially MRI served as reference standard. For clarification of suspected MRI findings SPECT and MRI images were fused using CT anatomical landmarks.</p>
Index and comparator tests	<p>Index test: <sup>123</sup>I-MIBG scintigraphy.</p> <p>Radiofarmacon: <sup>123</sup>I-MIBG.</p> <p>Dose: n.r.</p> <p>Collimator: n.r.</p> <p>Matrix: n.r.</p> <p>Acquisition protocol: n.r.</p> <p>Acquisition time: n.r.</p> <p>Acquisition duration: n.r.</p> <p>Interfering medication: n.r.</p> <p>Thyroid prophylaxis: n.r.</p>



**Muckle 2012** (Continued)

	<p>Positive test result: n.r.</p> <p>Number and expertise of observers: n.r.</p> <p>Interobserver concordance: n.r.</p>
Follow-up	n.r.
Notes	<p>Not published in full-text (as of December 2012), but presented at the SNM conference 2012.</p> <p>Results n.r. for <sup>123</sup>I-MIBG scans at first diagnosis separately from the <sup>123</sup>I-MIBG scans during follow-up.</p> <p>We could not get in contact with the authors.</p>

**Muller-Gartner 1986**

Clinical features and settings	<p>Study period: July 1984 to May 1985.</p> <p>Patient population: 15 patients with confirmed neuroblastoma with 21 <sup>123</sup>I-MIBG and <sup>131</sup>I-MIBG scans.</p> <p>Consecutive series: yes.</p> <p>Diagnostic work-up: n.r.</p> <p>Time spans between symptoms and index test, between symptoms and reference standard and between index test and reference standard: n.r.</p> <p>Treatment between index test and reference standard: n.r.</p>
Participants	<p>Included patients: 15 children with newly diagnosed neuroblastoma with <sup>123</sup>I-MIBG scintigraphy at diagnosis.</p> <p>Median age: 3 years (range 0.2 to 14 years).</p> <p>Sex distribution: n.r.</p> <p>INSS stage: 3 stage 2, 2 stage 3, 9 stage 4 and 1 stage 4S.</p>
Study design	Cohort study. N.r. whether the study was retrospective or prospective.
Target condition and reference standard(s)	<p>Target condition: newly diagnosed neuroblastoma.</p> <p>Reference standard of primary tumour: histopathology.</p> <p>If neuroblastoma could be excluded by US, radiological examinations, urinary catecholamines and bone marrow biopsy, a pathological <sup>123</sup>I-MIBG uptake was deemed to be false-positive and a physiological <sup>123</sup>I-MIBG distribution right-negative.</p>
Index and comparator tests	<p>Index test: <sup>123</sup>I-MIBG and <sup>131</sup>I-MIBG scintigraphy.</p> <p>Radiofarmacon: <sup>123</sup>I- and <sup>131</sup>I-MIBG.</p> <p>Dose: 111 to 185 MBq.</p> <p>Collimator: n.r.</p> <p>Matrix: n.r.</p>

**Muller-Gartner 1986** (Continued)

Acquisition protocol: anterior and posterior spot images of head; thorax, neck and upper arms; abdomen; upper legs and proximal tibiae; and SPECT scans.

Acquisition time: 24 and 48 hours after injection.

Acquisition duration: 200 kcounts for the head (lateral views); 400 to 1000 kcounts for the thorax, neck and upper arms (anterior and posterior views); 400 to 1000 kcounts for the abdomen (anterior and posterior views); 100 to 200 kcounts for the upper legs and proximal tibiae (anterior or posterior views).

SPECT: n.r.

Interfering medication: n.r.

Thyroid prophylaxis: 200 µg Iodide one day before and three days after tracer injection.

Positive test: pathological <sup>123</sup>I-MIBG uptake.

Number and expertise of observers: n.r.

Interobserver concordance: n.r.

Follow-up	n.r.
Notes	<p>Results n.r. for <sup>123</sup>I-MIBG scans separately from the <sup>131</sup>I-MIBG scans. And results n.r. for <sup>123</sup>I-MIBG scans at first diagnosis separately from the <sup>123</sup>I-MIBG scans during follow-up.</p> <p>Contact information of the authors: not available.</p>

**Müller-Gärtner 1985**

Clinical features and settings	<p>Study period: July 1984 to August 1985.</p> <p>Patient population: 19 patients with confirmed (n = 18) or suspected neuroblastoma (n = 1) with 35 <sup>123</sup>I-MIBG and <sup>131</sup>I-MIBG scans.</p> <p>Consecutive series: n.r.</p> <p>Diagnostic work-up: n.r.</p> <p>Time spans between symptoms and index test, between symptoms and reference standard and between index test and reference standard: n.r.</p> <p>Treatment between index test and reference standard: n.r.</p>
Participants	<p>Included patients: 18 children with newly diagnosed neuroblastoma and one child with suspected neuroblastoma with a <sup>123</sup>I-MIBG scan at diagnosis.</p> <p>Median age: 30 months (range 1 to 144 months).</p> <p>Sex distribution: n.r.</p> <p>INSS stage (n = 18): 1 stage 1, 1 stage 3, 14 stage 4 and 2 stage 4S.</p>
Study design	Cohort study. N.r. whether the study was retrospective or prospective.
Target condition and reference standard(s)	<p>Target condition: newly diagnosed neuroblastoma.</p> <p>Reference standard of primary tumour: histopathology.</p> <p>Reference standard of bone marrow metastases: bone marrow biopsies.</p>

**123I-MIBG scintigraphy and 18F-FDG-PET imaging for diagnosing neuroblastoma (Review)**

### Müller-Gärtner 1985 (Continued)

Index and comparator tests	<p>Index test: <math>^{123}\text{I}</math>-MIBG and <math>^{131}\text{I}</math>-MIBG scintigraphy.</p> <p>Radiofarmacon: <math>^{123}\text{I}</math>- and <math>^{131}\text{I}</math>-MIBG.</p> <p>Dose: 111 to 185 MBq.</p> <p>Collimator: n.r.</p> <p>Matrix: n.r.</p> <p>Acquisition protocol: anterior and posterior spot images of head; thorax, neck and upper arms; abdomen; upper legs and proximal tibiae.</p> <p>Acquisition time: 24 and 48 hours after injection.</p> <p>Acquisition duration: 200 kcounts for the head (lateral views); 400 to 1000 kcounts for the thorax, neck and upper arms (anterior and posterior views); 400 to 1000 kcounts for the abdomen (anterior and posterior views); 100 to 200 kcounts for the upper legs and proximal tibiae (anterior or posterior views).</p> <p>Interfering medication: n.r.</p> <p>Thyroid prophylaxis: 200 µg Iodide.</p> <p>Positive test: non-physiological <math>^{123}\text{I}</math>-MIBG uptake.</p> <p>Number and expertise of observers: n.r.</p> <p>Interobserver concordance: n.r.</p>
Follow-up	n.r.
Notes	<p>Results n.r. for <math>^{123}\text{I}</math>-MIBG scans separately from <math>^{131}\text{I}</math>-MIBG scans. And results n.r. for <math>^{123}\text{I}</math>-MIBG scans at first diagnosis separately from <math>^{123}\text{I}</math>-MIBG scans during follow-up.</p> <p>Contact information of the authors: not available.</p>

### Okuyama 1998

Clinical features and settings	<p>Patient population: 19 patients with neuroblastoma and with <math>^{123}\text{I}</math>-MIBG scans.</p> <p>Further information currently unclear.</p>
Participants	<p>Included patients: 19 children with neuroblastoma and a <math>^{123}\text{I}</math>-MIBG scan at first diagnosis.</p> <p>Median age: 8 months (range 2 weeks to 7 years).</p> <p>Sex distribution: 10 boys (53%), 9 girls (47%).</p> <p>INSS stage: 6 stage 1, 1 stage 2, 5 stage 3, 4 stage 4 and 3 stage 4S.</p>
Study design	Currently unclear.
Target condition and reference standard(s)	<p>Target condition: newly diagnosed neuroblastoma.</p> <p>Further information currently unclear.</p>
Index and comparator tests	<p>Index test: <math>^{123}\text{I}</math>-MIBG scintigraphy.</p> <p>Radiofarmacon: <math>^{123}\text{I}</math>-MIBG.</p>

### 123I-MIBG scintigraphy and 18F-FDG-PET imaging for diagnosing neuroblastoma (Review)

### Okuyama 1998 (Continued)

Acquisition protocol: WB, truncal and SPECT scans.

Acquisition time: six and 24 hours after injection.

<sup>123</sup>I-MIBG scintigraphy was compared to CT or MRI and bone scintigraphy to investigate which imaging modality could demonstrate the extent of disease most exactly.

Further information currently unclear.

Follow-up	Currently unclear.
Notes	Study in Japanese. We did not find a translator yet. Based on currently available information unclear whether this study fulfills the inclusion criteria.

### Okuyama 1999

Clinical features and settings	<p>Patient population: 23 patients with neuroblastoma at first diagnosis and with <sup>123</sup>I-MIBG scans.</p> <p>Further information currently unclear.</p>
Participants	<p>Included patients: 22 children with newly diagnosed neuroblastoma and with <sup>123</sup>I-MIBG scintigraphy at first diagnosis.</p> <p>Median age: 9 months (range 0.5 month to 86 months).</p> <p>Sex distribution: 12 boys (55%), 10 girls (45%).</p> <p>INSS stage: 4 stage 1, 5 stage 2, 7 stage 3 and 6 stage 4.</p> <p>Further information currently unclear.</p>
Study design	Currently unclear.
Target condition and reference standard(s)	<p>Target condition: newly diagnosed neuroblastoma.</p> <p>Reference standard: histopathology.</p>
Index and comparator tests	<p>Index test: <sup>123</sup>I-MIBG scintigraphy.</p> <p>Further information currently unclear.</p>
Follow-up	Currently unclear.
Notes	Study was in Japanese. We did not find a translator yet. Based on currently available information unclear whether this study fulfils the inclusion criteria.

### Osmanagaoglu 1993

Clinical features and settings	<p>Study period: 1987 to 1993.</p> <p>Patient population: 26 patients with neuroblastoma and with 148 <sup>123</sup>I-MIBG scans.</p> <p>Consecutive series: n.r.</p> <p>Diagnostic work-up: urinary catecholamines, US, CT, MRI, <sup>123</sup>I-MIBG scintigraphy, <sup>99m</sup>Tc-MDP-bone scintigraphy and cytological examination of bone marrow aspiration biopsy specimen.</p>
--------------------------------	--

**Osmanagaoglu 1993** (Continued)

Time span between <sup>123</sup>I-MIBG scintigraphy and routine cytological bone marrow aspiration: four weeks.

Time spans between symptoms and index test and between symptoms and reference standard: n.r.

Treatment between index test and reference standard: n.r.

Participants	<p>Included patients: 26 children with newly diagnosed neuroblastoma and with a <sup>123</sup>I-MIBG scan at diagnosis.</p> <p>Median age: n.r.; mean age: 3.3 years (range 1 month to 13 years).</p> <p>Sex distribution: 14 boys (54%), 12 girls (46%).</p> <p>INSS stage: 2 stage 1, 4 stage 3, 17 stage 4 and 3 stage 4S.</p>
Study design	Retrospective cohort study.
Target condition and reference standard(s)	<p>Target condition: newly diagnosed neuroblastoma.</p> <p>Reference standard of primary tumour: histopathology.</p> <p>Reference standard of metastases: unguided, unilateral bone marrow aspiration biopsies at the anterior iliac crest and various smear samples from the aspiration material; cytologically analysed by an experienced haemato-oncologist. May-Grünwald-Giemsa staining was employed for morphological evaluation of the cells.</p>
Index and comparator tests	<p>Index test: <sup>123</sup>I-MIBG scintigraphy.</p> <p>Radiofarmacon: <sup>123</sup>I-MIBG.</p> <p>Dose: 111 MBq.</p> <p>Collimator: n.r.</p> <p>Matrix: n.r.</p> <p>Acquisition protocol: WB scans and additional spot views if necessary.</p> <p>Acquisition time: six and 24 hours after injection.</p> <p>Acquisition duration: n.r.</p> <p>Interfering medication: n.r.</p> <p>Thyroid prophylaxis: potassium iodide (30 mg/day) three days before <sup>123</sup>I-MIBG injection.</p> <p>Positive test: <sup>123</sup>I-MIBG uptake in skeleton and bone marrow.</p> <p>Number and expertise of observers: two residents and two experienced nuclear medicine physicians; interpretations were compared in order to reach a consensus.</p> <p>Interobserver concordance: n.r.</p>
Follow-up	Follow-up time: minimally two years.
Notes	<p>Results not reported for <sup>123</sup>I-MIBG scans at first diagnosis separately from <sup>123</sup>I-MIBG scans during follow-up.</p> <p>Contact information of the authors: not available.</p>

**Paltiel 1994**

Clinical features and settings	<p>Study period: March 1991 to February 1992.</p> <p>Patient population: 33 patients with a suspected neural crest tumour and with 77 consecutive <sup>123</sup>I-MIBG scans.</p> <p>Consecutive series: yes.</p> <p>Diagnostic work-up: US, CT, MRI, <sup>99m</sup>Tc-bone scintigraphy, skeletal surveys, bone marrow aspiration/biopsy or histopathology.</p> <p>Results of the <sup>123</sup>I-MIBG scans were compared with those of other imaging studies and any biopsy studies performed in the three months before and after each <sup>123</sup>I-MIBG scan.</p> <p>Time spans between symptoms and index test and between symptoms and reference standard: n.r.</p> <p>Treatment between index test and reference standard: n.r.</p>
Participants	<p>Included patients: 28 children with newly diagnosed neuroblastoma and with a <sup>123</sup>I-MIBG scan at first diagnosis.</p> <p>Median age: n.r. for these included patients; for all 33 patients the mean age: 5.6 years (range 2 weeks to 14.8 years).</p> <p>Sex distribution: n.r. for these included patients; for all 33 patients:: 18 boys (55%), 15 girls (45%).</p> <p>INSS stage: n.r. for these included patients; for all 33 patients: 2 stage 1, 4 stage 3, 17 stage 4 and 3 stage 4S.</p>
Study design	Cohort study. N.r. whether the study was retrospective or prospective.
Target condition and reference standard(s)	<p>Target condition: newly diagnosed neuroblastoma.</p> <p>Reference standard: histopathology.</p>
Index and comparator tests	<p>Index test: <sup>123</sup>I-MIBG scintigraphy.</p> <p>Radiofarmakon: <sup>123</sup>I-MIBG.</p> <p>Dose: 0.07 mCi/kg for patients with stage 1 or 2 neuroblastoma, 0.14 mCi/kg for patients with stage 3 or 4 neuroblastoma and 0.07 mCi/kg for patients with other proved or suspected neural crest tumours; with a maximum of 5.0 mCi.</p> <p>Collimator: general-purpose.</p> <p>Matrix: n.r.</p> <p>Acquisition protocol: anterior and posterior planar scans.</p> <p>Acquisition time: 24 and 48 hours after injection.</p> <p>Acquisition duration: 300 kcount for images over the torso; the same time per image (usually 2 to 2.5 minutes) for WB scans in anterior and posterior projections; and 6-minute images of the torso, shoulders, and hips in anterior and posterior projections; the skull and extremity sites were re-imaged only if equivocal lesions were seen at 24 hours.</p> <p>Interfering medication: n.r.</p> <p>Thyroid prophylaxis: saturated potassium iodide solution (30 mg/day) prior to until two days after <sup>123</sup>I-MIBG injection.</p> <p>Positive test: abnormally increased <sup>123</sup>I-MIBG uptake.</p> <p>Number and expertise of observers: all scans were retrospectively and separately interpreted by 3 nuclear medicine specialists with 2 serving as primary reviewers of each study and the third as a "tie</p>

**Paltiel 1994** (Continued)

	breaker," when needed.
	Interobserver concordance: n.r.
Follow-up	Follow-up time: up to two years.
Notes	Results not reported for patients with neuroblastoma separately from patients with other neural crest tumours.
	Contact information of the authors: not available.

**Papathanasiou 2011**

Clinical features and settings	<p>Study period: November 2004 to October 2008.</p> <p>Patient population: 28 patients with refractory or relapsed high-risk neuroblastoma.</p> <p>Consecutive series: n.r.</p> <p>Diagnostic work-up: each patient underwent a pair of <sup>18</sup>F-FDG and <sup>123</sup>I-MIBG scans, performed within two weeks before treatment.</p> <p>Time spans between symptoms and index test, between symptoms and reference standard and between index test and reference standard:</p> <p>Treatment between index test and reference standard:</p>
Participants	<p>Included patients: 28 patients with refractory or relapsed high-risk neuroblastoma.</p> <p>Median age: 7.5 years (range 2 to 45 years).</p> <p>Sex distribution: 16 boys (57%), 12 girls (43%).</p> <p>INSS stage: all stage 4.</p>
Study design	Prospective cohort study.
Target condition and reference standard(s)	<p>Target condition: recurrent neuroblastoma.</p> <p>Reference standard: histopathology.</p>
Index and comparator tests	<p>Index test: <sup>18</sup>F-FDG PET scintigraphy; comparator test: <sup>123</sup>I-MIBG scintigraphy.</p> <p>Paired scans obtained within 14 days before treatment.</p> <p>When necessary, sedation was used in accordance with guidelines before <sup>18</sup>F-FDG-PET/CT or <sup>123</sup>I-MIBG scintigraphy to ensure patient immobilization and adequate image quality.</p> <p><b><sup>18</sup>F-FDG-PET scintigraphy:</b></p> <p>Radiofarmacon: <sup>18</sup>F-FDG-PET.</p> <p>Dose: 5.5 to 7.7 MBq/kg (maximum 440 MBq).</p> <p>Equipment: CT data were acquired using four 3.75-mm detectors, a pitch of 1.5-, and 5-mm collimation (5 minutes per bed position). The CT exposure factors were 120–140 kVp and 80 mA.</p> <p>Acquisition protocol: PET images were reconstructed using CT data for attenuation correction. Transaxial PET emission images of 4.3 x 4.3 x 4.25 mm were reconstructed using ordered subsets expectation maximization, with two iterations and 28 subsets.</p>

**Papathanasiou 2011** (Continued)

Acquisition time: 50 to 75 minutes after injection.

Acquisition duration: not reported.

Positive test: any focal, superior-to-background  $^{18}\text{F}$ -FDG uptake in the primary mass, lymph nodes, liver, or skeleton and inhomogeneous  $^{18}\text{F}$ -FDG uptake in the bone marrow, especially in the absence of recent chemotherapy or hematopoietic stimulating factors.

**$^{123}\text{I}$ -MIBG scintigraphy:**

Radiofarmakon:  $^{123}\text{I}$ -MIBG.

Dose: 5.20 MBq/kg (maximum 370 MBq).

Collimator: n.r.

Matrix: n.r.

Acquisition protocol: planar WB images were supplemented with spot views or  $^{123}\text{I}$ -MIBG SPECT-CT of the chest and abdomen, if deemed necessary for anatomic localization of the lesion or clarification of equivocal findings.

Acquisition time: 24 and 48 hours after injection.

Acquisition duration:

SPECT: n.r.

Interfering medication: n.r.

Thyroid prophylaxis: potassium perchlorate or potassium iodide before and two days after  $^{123}\text{I}$ -MIBG injection.

Positive test: n.r.

Number and expertise of observers: n.r.

Interobserver concordance: n.r.

Follow-up	Median observation time from imaging: 1.03 years (range 0.27 to 3.5 years).
Notes	Results not reported for children separately from adults. We could not get in contact with the authors.

**Parisi 1992**

Clinical features and settings	<p>Study period: 1983 through April 1991.</p> <p>Patient population: 20 patients with known or suspected neuroblastoma and with 26 paired <math>^{123}\text{I}</math>-MIBG (n = 20), <math>^{131}\text{I}</math>-MIBG (n = 6) and <math>^{99\text{m}}\text{Tc}</math>-MDP bone scans less than four weeks apart.</p> <p>Consecutive series: no, the pairs were randomly chosen from a pool of over 86 similar pairs representing all the paired studies performed in neuroblastoma patients.</p> <p>Diagnostic work-up: n.r.</p> <p>Time spans between symptoms and index test, between symptoms and reference standard and between index test and reference standard: n.r.</p> <p>Treatment between index test and reference standard: n.r.</p>
--------------------------------	--

**123I-MIBG scintigraphy and 18F-FDG-PET imaging for diagnosing neuroblastoma (Review)**



**Parisi 1992** (Continued)

Participants	<p>Included patients: 14 patients with neuroblastoma and with a <sup>123</sup>I-MIBG scan.</p> <p>Median age: n.r.</p> <p>Sex distribution: n.r.</p> <p>INSS stage: n.r.; for all 20 patients: 3 stage 2, 1 stage 3, 15 stage 4 and 1 not specified.</p>
Study design	Cohort study. N.r. whether the study was retrospective or prospective.
Target condition and reference standard(s)	<p>Target condition: newly diagnosed neuroblastoma.</p> <p>Reference standard: For the purposes of statistical analysis, the scores of the experienced observers were considered the "gold standard," as occurs in clinical practice. However, experienced observer scores were 100% correlated with concomitant available bone marrow aspirates as well as other clinical, biochemical, and radiographic indicators of disease status.</p>
Index and comparator tests	<p>Index test: <sup>123</sup>I-MIBG scintigraphy.</p> <p>Radiofarmakon: <sup>123</sup>I-MIBG.</p> <p>Dose: n.r.</p> <p>Collimator: n.r.</p> <p>Matrix: n.r.</p> <p>Acquisition protocol: n.r.</p> <p>Acquisition time: n.r.</p> <p>Acquisition duration: n.r.</p> <p>Interfering medication: n.r.</p> <p>Thyroid prophylaxis: n.r.</p> <p>Positive test: n.r.</p> <p>Number and expertise of observers: each study was evaluated independently of its counterpart by six separate observers (three experienced and three inexperienced in MIBG scintigraphy) to determine the presence or absence of disease and the tumour burden.</p> <p>Finally, inexperienced observers submitted level of confidence scores (1 = true-negative; 5 = true-positive) for each study evaluated. Analysis of confidence levels using a paired Student's test confirmed that the residents were significantly more confident using, and more confident of, their interpretations on <sup>99m</sup>Tc-MDP bone scans. However, despite their familiarity and confidence with <sup>99m</sup>Tc-MDP scans, inexperienced observers identified only 52% and 57% of the lesions and regions of disease involvement, respectively, found by the experienced observers on the radionuclide bone scans.</p> <p>Interobserver concordance: identifying lesions and regions of disease extent between inexperienced and experienced observers increased appreciably on MIBG scans to 66% and 83%, respectively.</p>
Follow-up	n.r.; some patients were followed for approximately 33 months.
Notes	<p>Results not reported for <sup>123</sup>I-MIBG scans separately from <sup>131</sup>I-MIBG scans. Unclear whether <sup>123</sup>I-MIBG scans were performed at first diagnosis, recurrence or refractory neuroblastoma.</p> <p>Contact information of the authors: not available.</p>

**Rathore 2011**

Clinical features and settings	<p>Study period: 2003 to 2009.</p> <p>Patient population: 168 patients with neuroendocrine tumours and with 100 MIBG scans.</p> <p>Consecutive series: n.r.</p> <p>Diagnostic work-up: CT, MRI and histopathology.</p> <p>Time spans between symptoms and index test, between symptoms and reference standard and between index test and reference standard: n.r.</p> <p>Treatment between index test and reference standard: n.r.</p>
Participants	<p>Included patients: 168 patients with neuroendocrine tumours.</p> <p>Median age: n.r.</p> <p>Sex distribution: n.r.</p> <p>INSS stage: n.r.</p>
Study design	Cohort study. N.r. whether the study was retrospective or prospective.
Target condition and reference standard(s)	<p>Target condition: neuroblastoma.</p> <p>Reference standard: histopathology.</p>
Index and comparator tests	<p>Index test: <sup>123</sup>I-MIBG.</p> <p>Radiofarmakon: <sup>123</sup>I-MIBG.</p> <p>Dose: n.r.</p> <p>Collimator: n.r.</p> <p>Matrix: n.r.</p> <p>Acquisition protocol: planar and SPECT scans.</p> <p>Acquisition time: n.r.</p> <p>Acquisition duration: n.r.</p> <p>SPECT: n.r.</p> <p>Interfering medication: n.r.</p> <p>Thyroid prophylaxis: n.r.</p> <p>Positive test: n.r.</p> <p>Number and expertise of observers: n.r.</p> <p>Interobserver concordance: n.r.</p>
Follow-up	n.r.
Notes	<p>Not published in full-text (as of December 2012), but presented at the ACNM conference 2011.</p> <p>Unclear how many patients were diagnosed with neuroblastoma, whether <sup>123</sup>I- or <sup>131</sup>I-MIBG scintigraphy was performed and whether MIBG scintigraphy was performed at first diagnosis or at follow-up.</p>

**Rathore 2011** (Continued)

Contact information of the authors: not available.

**Sarkadi 2011**

Clinical features and settings	Currently unclear.
Participants	Currently unclear.
Study design	Currently unclear.
Target condition and reference standard(s)	Currently unclear.
Index and comparator tests	Currently unclear.
Follow-up	Currently unclear.
Notes	<p>Not published in full-text (as of December 2012), but presented at a Hungarian conference.</p> <p>We could not find the abstract, so we were not able to evaluate the eligibility of this study.</p>

**Schilling 2000**

Clinical features and settings	<p>Study period: n.r.</p> <p>Patient population: 88 patients with histologically proven neuroblastoma at first diagnosis or recurrence and with <sup>123</sup>I-MIBG scans.</p> <p>Consecutive series: n.r.</p> <p>Diagnostic work-up: urinary catecholamines, US, CT, MRI, <sup>123</sup>I-MIBG scintigraphy and multiple bone marrow biopsies.</p> <p>Time spans between symptoms and index test, between symptoms and reference standard and between index test and reference standard: n.r.</p> <p>Treatment between index test and reference standard: n.r.</p>
Participants	<p>Included patients: children with newly diagnosed or recurrent neuroblastoma and with a <sup>123</sup>I-MIBG scan at first diagnosis.</p> <p>Median age: n.r. for these included patients; for all 88 patients: 14 months (range 0 to 290 months).</p> <p>Sex distribution: n.r. for these included patients; for all 88 patients: 48 boys (55%), 40 girls (45%).</p> <p>INSS stage: n.r. for these included patients; for all 88 patients: 58 stage 1, 2, 3 or 4S and 30 stage 4.</p>
Study design	Cohort study. N.r. whether the study was retrospective or prospective.
Target condition and reference standard(s)	<p>Target condition: newly diagnosed or recurrent neuroblastoma.</p> <p>Reference standard: histopathology.</p>
Index and comparator tests	<p>Index test: <sup>123</sup>I-MIBG scintigraphy.</p> <p>Radiofarmakon: <sup>123</sup>I-MIBG.</p>

**123I-MIBG scintigraphy and 18F-FDG-PET imaging for diagnosing neuroblastoma (Review)**

105

**Schilling 2000** (Continued)

Dose: 110 MBq.  
Collimator: n.r.  
Matrix: n.r.  
Acquisition protocol: n.r.  
Acquisition time: 24 hours after injection.  
Acquisition duration: n.r.  
Interfering medication: n.r.  
Thyroid prophylaxis: n.r.  
Positive test: n.r.  
Number and expertise of observers: n.r.  
Interobserver concordance: n.r.

---

Follow-up	Median follow-up: 35 months (range 1 to 88 months).
-----------	---

---

Notes	Results not reported for children separately from adults. We could not get contact with the authors.
-------	---

---

**Schmiegelow 1989**

---

Clinical features and settings	Study period: n.r.  Patient population: 96 patients with confirmed neuroblastoma (n = 71) or suspected neuroblastoma (n = 25) and with <sup>123</sup> I- and <sup>131</sup> I-MIBG scans.  Consecutive series: n.r.  Diagnostic work-up: urinary catecholamines, US, CT, radiological examinations, <sup>99m</sup> Tc-MDP-bone scan.  Time spans between symptoms and index test, between symptoms and reference standard and between index test and reference standard: n.r.  Treatment between index test and reference standard: n.r.
--------------------------------	--

---

Participants	Included patients: 31 children younger than 15 years old with neuroblastoma and with a <sup>123</sup> I-MIBG scan at first diagnosis.  Median age: n.r. for these 31 included patients; for all 71 patients with a neuroblastoma: 2 years (range 0 to 15 years).  Sex distribution: n.r. for these 31 included patients; for all 71 patients with a neuroblastoma: 42 boys (59%), 29 girls (41%).  INSS stage: n.r. for these 31 included patients; for all 71 patients: 7 stage 1, 9 stage 2, 13 stage 3 and 42 stage 4.
--------------	---

---

Study design	Cohort study. N.r. whether the study was retrospective or prospective.
--------------	--

---

Target condition and reference standard(s)	Target condition: newly diagnosed neuroblastoma.
--	--

### Schmiegelow 1989 (Continued)

	Reference standard: histopathology (and US, CT, radiological examinations, <sup>99m</sup> Tc-bone scan, urinary catecholamines).
Index and comparator tests	<p>Index test: <sup>123</sup>I-MIBG scintigraphy.</p> <p>Radiofarmakon: <sup>123</sup>I-MIBG.</p> <p>Dose: 30 (+10*age in years) MBq in children younger than eight years and 70 to 80 MBq in two adolescents of 16 years.</p> <p>Collimator: n.r.</p> <p>Matrix: n.r.</p> <p>Acquisition protocol: n.r.</p> <p>Acquisition time: 24 hours after injection.</p> <p>Acquisition duration: n.r.</p> <p>Interfering medication: n.r.</p> <p>Thyroid prophylaxis: Lugol's solution, potassium iodide or perchlorate less than 24 hours before injection of <sup>123</sup>I-MIBG.</p> <p>Positive test: pathological <sup>123</sup>I-MIBG uptake.</p> <p>Number and expertise of observers: n.r.</p> <p>Interobserver concordance: n.r.</p>
Follow-up	n.r.; some patients were followed for approximately 44 months.
Notes	<p>Results not reported for <sup>123</sup>I-MIBG scans separately from <sup>131</sup>I-MIBG scans.</p> <p>We could not get contact with the authors.</p>

### Sharp 2009b

Clinical features and settings	<p>Study period: n.r.</p> <p>Patient population: 23 patients with neuroblastoma.</p> <p>Consecutive series: n.r.</p> <p>Diagnostic work-up: n.r.</p> <p>Time spans between symptoms and index test, between symptoms and reference standard and between index test and reference standard: n.r.</p> <p>Treatment between index test and reference standard: n.r.</p>
Participants	<p>Included patients: 23 patients with neuroblastoma.</p> <p>Median age: n.r.</p> <p>Sex distribution: n.r.</p> <p>INSS stage: n.r.</p>
Study design	n.r.

### 123I-MIBG scintigraphy and 18F-FDG-PET imaging for diagnosing neuroblastoma (Review)

**Sharp 2009b** (Continued)

Target condition and reference standard(s)	Target condition: n.r. Reference standard: n.r.
Index and comparator tests	Index test: <sup>123</sup> I-MIBG SPECT/CT. Radiofarmakon: <sup>123</sup> I-MIBG. Dose: 0.14 mCi/kg. Equipment: two different SPECT/CT scanners A and B (with diagnostic CT unit), details n.r. Acquisition protocol: WB planar MIBG scintigraphy, SPECT, and co-registered low-dose CT imaging Acquisition time: n.r. Acquisition duration: n.r. Interfering medication: n.r. Thyroid prophylaxis: n.r. Positive test result: foci of uptake. Number and expertise of observers: n.r. Interobserver concordance: n.r.
Follow-up	n.r.
Notes	Not published in full-text (as of 2009), but presented at the SIOP conference 2012. Results n.r. for <sup>123</sup> I-MIBG scans at first diagnosis separately from the <sup>123</sup> I-MIBG scans during follow-up. We did not get contact with the authors.

**Suc 1996**

Clinical features and settings	Study period: 1984 to 1991. Patient population: 129 consecutive patients with neuroblastoma; thirty-two not enrolled in the study because MIBG scans were unavailable (n = 26) or because patients were treated before their first MIBG scan (n = 6); of the remaining 97 children 86 had a positive MIBG scan and were included in this study; 11 were excluded, because their first MIBG scan did not show any skeletal metastases. Five-hundred-twenty-two MIBG scans were performed in these patients; 519 with <sup>123</sup> I-MIG and three with <sup>131</sup> I-MIBG. Diagnostic work-up: urinary catecholamines, CT, MRI, MIBG scintigraphy, two trephine biopsies and ten bone marrow aspirates. Time spans between symptoms and index test, between symptoms and reference standard and between index test and reference standard: n.r. Treatment between index test and reference standard: n.r.
Participants	Included patients: 86 children with newly diagnosed neuroblastoma and with a <sup>123</sup> I-MIBG scan at first diagnosis. Median age: 3 years (range 1 to 14 years).

**Suc 1996** (Continued)

Sex distribution: 54 boys (63%) and 32 girls (37%).

INSS stage: all stage 4.

Study design	Retrospective cohort study.
Target condition and reference standard(s)	<p>Target condition: primary neuroblastoma.</p> <p>Reference standard of primary tumour: histopathology.</p> <p>Reference standard of metastases: two trephine biopsies and ten bone marrow aspirates; examination of spread films of aspirated material and stained by May-Grunwald-Giemsa stain (all slides were examined for evidence of gross disease or for small clumps of tumour cells); sections of formalin fixed trephine biopsies obtained with a Jamshidi needle were examined systematically at low and high magnifications. Bone marrow involvement was defined by any positive cytologic or histologic findings, or both.</p>
Index and comparator tests	<p>Index test: <math>^{123}\text{I}</math>-MIBG scintigraphy.</p> <p>Radiofarmacon: <math>^{123}\text{I}</math>-MIBG.</p> <p>Dose: 4 MBq/kg.</p> <p>Collimator: n.r.</p> <p>Matrix: n.r.</p> <p>Acquisition protocol: n.r.</p> <p>Acquisition time: 24 hours after injection.</p> <p>Acquisition duration: n.r.</p> <p>Interfering medication: n.r.</p> <p>Thyroid prophylaxis: potassium iodide four days before the injection of <math>^{123}\text{I}</math>-MIBG and for the next 3 days.</p> <p>Positive test: focal <math>^{123}\text{I}</math>-MIBG uptake or diffuse <math>^{123}\text{I}</math>-MIBG uptake throughout the skeleton, including the metaphyseal complex.</p> <p>Number of observers: two independent observers.</p> <p>Expertise of observers: n.r.</p> <p>Interobserver concordance: n.r.</p>
Follow-up	n.r.
Notes	<p>Results not reported for <math>^{123}\text{I}</math>-MIBG scans separately from <math>^{131}\text{I}</math>-MIBG scans.</p> <p>Contact information of the authors: not available.</p>

**Tahir 2011**

Clinical features and settings	<p>Study period: five-year period.</p> <p>Patient population: 23 patients with MIBG and bone scans.</p> <p>Further information n.r.</p>
--------------------------------	---

**123I-MIBG scintigraphy and 18F-FDG-PET imaging for diagnosing neuroblastoma (Review)**

**Tahir 2011** (Continued)

Participants	<p>Included patients: 23 patients with neuroblastoma.</p> <p>Median age: n.r.</p> <p>Sex distribution: 13 boys (57%), 10 girls (43%).</p> <p>INSS stage: n.r.</p>
Study design	Prospective cohort study.
Target condition and reference standard(s)	<p>Target condition: patients with neuroblastoma.</p> <p>Reference standard: n.r.</p>
Index and comparator tests	<p>Index test: MIBG scintigraphy.</p> <p>Further information n.r.</p>
Follow-up	n.r
Notes	<p>Not published in full-text (as of December 2012), but presented at the RSNA conference 2012.</p> <p>Unclear whether patients were younger than 18 years, whether <sup>123</sup>I- or <sup>131</sup>I-MIBG scintigraphy was performed and whether MIBG scintigraphy was performed at first diagnosis or at follow-up.</p> <p>Contact information of the authors: not available.</p>

**Turba 1993**

Clinical features and settings	<p>Study period: April 1986 to November 1991.</p> <p>Study population: 22 consecutive patients with histopathologically confirmed stage 4 neuroblastoma and with <sup>123</sup>I-MIBG and <sup>131</sup>I-MIBG scans at first diagnosis.</p> <p>Diagnostic work-up: urinary catecholamines, other imaging modalities, bone marrow aspirates and bone biopsies.</p> <p>Time spans between symptoms and index test, between symptoms and reference standard and between index test and reference standard: n.r.</p> <p>Treatment between index test and reference standard: n.r.</p>
Participants	<p>Included patients: 14 children with newly diagnosed stage 4 neuroblastoma and with a <sup>123</sup>I-MIBG scan at first diagnosis.</p> <p>Median age: n.r. for these 14 included patients; for all 22 patients: 2.9 years (range 8 months to 8 years).</p> <p>Sex distribution: n.r. for these 14 included patients; for all 22 patients: 11 boys (50%), 11 girls (50%).</p> <p>INSS stage: all stage 4.</p>
Study design	Cohort study. N.r. whether the study was retrospective or prospective.
Target condition and reference standard(s)	<p>Target condition: newly diagnosed stage 4 neuroblastoma.</p> <p>Reference standard: histopathology (bone marrow aspirate or trephine biopsy, or both) and urinary catecholamines.</p>
Index and comparator tests	Index test: <sup>123</sup> I-MIBG scintigraphy.

**123I-MIBG scintigraphy and 18F-FDG-PET imaging for diagnosing neuroblastoma (Review)**



**Turba 1993** (Continued)

Radiofarmakon:  $^{123}\text{I}$ -MIBG.

Dose: 120 to 160 MBq/kg.

Collimator: medium-energy.

Matrix: 256 x 256.

Acquisition protocol: WB scans.

Acquisition time: 24 hours after injection; in selected cases also 48 hours after injection.

Acquisition duration: 20 min/view or 500 kcounts.

Interfering medication: n.r.

Thyroid prophylaxis: Lugol's solution and potassium perchlorate.

Positive test: n.r.

Number of observers: two independent observers.

Expertise of observers: n.r.

Interobserver concordance: n.r.

---

Follow-up	Mean follow-up time: 26 months from diagnosis (range 11 to 42 months).
-----------	--

---

Notes	<p>Results not reported for <math>^{123}\text{I}</math>-MIBG scans separately from <math>^{131}\text{I}</math>-MIBG scans.</p> <p>Contact information of the authors: not available.</p>
-------	--

---

**Vik 2009**


---

Clinical features and settings	<p>Study period: n.r.</p> <p>Patient population: 100 patients with known or suspected neuroblastoma with <math>^{123}\text{I}</math>-MIBG scans at first diagnosis.</p> <p>Consecutive series of patients: no, patients from ten centres in the US and seven in Europe participated.</p> <p>Diagnostic work-up: urinary catecholamines, other imaging modalities, bone marrow aspirates and bone biopsies.</p> <p>Time spans between symptoms and index test, between symptoms and reference standard and between index test and reference standard: n.r.</p> <p>Treatment between index test and reference standard: n.r.</p>
--------------------------------	--

---

Participants	<p>Included patients: 62 children with newly diagnosed neuroblastoma and with a <math>^{123}\text{I}</math>-MIBG scan at first diagnosis.</p> <p>Median age: n.r. for these 62 included patients; for all 100 patients the mean age: 4.7 years (range 0.08 years to 58 years).</p> <p>Sex distribution: n.r. for these 62 included patients; for all 100 patients: 57 boys (57%), 43 girls (43%).</p> <p>INSS stage: all stage 4.</p>
--------------	---

---

**Vik 2009** (Continued)

Study design	Prospective trial: open-label phase 3 scintigraphy study designed to document that <sup>123</sup> I-MIBG was effective for imaging of subjects being evaluated for known or suspected neuroblastoma.
Target condition and reference standard(s)	<p>Target condition: newly diagnosed stage 4 neuroblastoma.</p> <p>Reference standard: histopathology from biopsy or surgical specimens. For patients with no definitive histopathology, the final diagnosis was based upon the combination of data from available histopathology (e.g. bone marrow biopsy, surgery following chemotherapy), results of recent imaging procedures (CT, MRI, scintigraphy), urinary and blood catecholamines and clinical follow-up.</p> <p>The final diagnosis for neuroblastoma was confirmed in 64 patients (62 children), not confirmed in 30 patients and indeterminate in six patients.</p>
Index and comparator tests	<p>Index test: <sup>123</sup>I-MIBG scintigraphy.</p> <p>Radiofarmacon: <sup>123</sup>I-MIBG.</p> <p>Dose: 37 MBq for a 3 kg infant to 185 MBq for a 22 kg child and 370 MBq for a 70 kg adolescent.</p> <p>Collimator: n.r.</p> <p>Matrix: n.r.</p> <p>Acquisition protocol: anterior and posterior WB or multiple overlapping spot images from the head to below the knees; supplemental spot images as deemed appropriate by the investigator.</p> <p>Acquisition time: 24 hours after injection. SPECT imaging of the thorax and abdomen was acquired unless the investigator determined that either the subject could not tolerate the procedure or the information that might be obtained would be of negligible clinical value.</p> <p>Acquisition duration: n.r.</p> <p>SPECT: n.r.</p> <p><sup>123</sup>I-MIBG WB scans were acquired for 93 patients and <sup>123</sup>I-MIBG SPECT scans for 45 patients (of 94 patients with a confirmed diagnosis).</p> <p>Interfering medication: n.r</p> <p>Thyroid prophylaxis: n.r.</p> <p>Positive test: n.r.</p> <p>Number and expertise of observers: three blinded readers that were experienced nuclear imagers. The readers were blinded to the protocol and to all clinical data except for the diagnostic purpose of the imaging examination. All evaluations were performed independently (all planar images first, followed by SPECT if that procedure had been performed). Based upon the independent results for each reader, a derived consensus regarding presence or absence of neuroblastoma (agreement of at least two readers) was obtained for the planar and planar+SPECT interpretations.</p> <p>Interobserver concordance: all three observers agreed on the diagnosis in 64 of the 94 subjects (67%) with confirmed diagnosis. The kappa statistic among each pair of readers: &gt; 0.60. With regard to the contribution of SPECT, the readers indicated that this study clarified the location of findings on planar images in 49 to 65% of patients and provided additional diagnostic value in 31 to 59% of studies examined.</p>
Follow-up	n.r.
Notes	<p>Results not reported for children younger than 18 years separately from adults.</p> <p>We did not get additional information on age from the authors yet.</p>

**Yang 2012**

Clinical features and settings	<p>Study period: January 2006 to December 2011.</p> <p>Patient population: 126 paediatric patients with malignant neuroblastoma and with pre-therapy <sup>123</sup>I-MIBG and post-therapy <sup>131</sup>I-MIBG scans.</p> <p>Diagnostic work-up: n.r.</p> <p>Time spans between symptoms and index test, between symptoms and reference standard and between index test and reference standard: n.r.</p> <p>For every patient, the <sup>123</sup>I-MIBG and <sup>131</sup>I-MIBG scans were acquired within two weeks.</p> <p>Treatment between index test and reference standard: n.r.</p>
Participants	<p>Included patients: 126 patients with malignant neuroblastoma and with a <sup>123</sup>I-MIBG scan before <sup>131</sup>I-MIBG therapy.</p> <p>Median age: n.r. mean age: 8.8 years (range 2 years to 25 years).</p> <p>Sex distribution: n.r.</p> <p>INSS stage: n.r.</p>
Study design	Retrospective cohort study.
Target condition and reference standard(s)	<p>Target condition: malignant neuroblastoma.</p> <p>Reference standard: n.r.</p>
Index and comparator tests	<p>Index test: <sup>123</sup>I-MIBG scintigraphy.</p> <p>Radiofarmacon: <sup>123</sup>I-MIBG.</p> <p>Dose: n.r.</p> <p>Collimator: n.r.</p> <p>Matrix: n.r.</p> <p>Acquisition protocol: n.r.</p> <p>Acquisition time: n.r.</p> <p>Acquisition duration: n.r.</p> <p>Interfering medication: n.r.</p> <p>Thyroid prophylaxis: not reported.</p> <p>Positive test: n.r.</p> <p>Number and expertise of observers: n.r.</p> <p>Interobserver concordance: n.r.</p>
Follow-up	n.r.
Notes	<p>Results not reported for children younger than 18 years separately from adults. Unclear whether all <sup>123</sup>I-MIBG scans were performed at first diagnosis.</p> <p>We did not get contact with the authors.</p>

**Young-Seok 2006**

Clinical features and settings	<p>Study period: n.r.</p> <p>Patient population: 19 patients older than one year with stage 4 neuroblastoma and with <sup>123</sup>I-MIBG and <sup>131</sup>I-MIBG scans.</p> <p>Consecutive series: n.r.</p> <p>Time spans between symptoms and index test, between symptoms and reference standard and between index test and reference standard: n.r.</p> <p>Treatment between index test and reference standard: n.r.</p>
Participants	<p>Included patients: 13 patients with neuroblastoma and with a <sup>123</sup>I-MIBG scan.</p> <p>Median age: n.r. for these 13 included patients; for all 19 patients mean age: 45.9 months.</p> <p>Sex distribution: n.r. for these 13 included patients; for all 19 patients: 12 boys (63%), 7 girls (37%).</p> <p>INSS stage: all stage 4.</p>
Study design	n.r.
Target condition and reference standard(s)	<p>Target condition: stage 4 neuroblastoma.</p> <p>Reference standard: n.r.</p>
Index and comparator tests	<p>Index test: <sup>123</sup>I-MIBG scintigraphy.</p> <p>Radiofarmacon: <sup>123</sup>I-MIBG.</p> <p>Dose: n.r.</p> <p>Collimator: n.r.</p> <p>Matrix: n.r.</p> <p>Acquisition protocol: n.r.</p> <p>Acquisition time: n.r.</p> <p>Acquisition duration: n.r.</p> <p>Interfering medication: n.r.</p> <p>Thyroid prophylaxis: n.r.</p> <p>Positive test: n.r.</p> <p>Number and expertise of observers: n.r.</p> <p>Interobserver concordance: n.r.</p>
Follow-up	n.r.
Notes	<p>Not published in full-text (as of December 2012), but presented at the SNM conference 2006.</p> <p>Results not reported for <sup>123</sup>I-MIBG scans separately from <sup>131</sup>I-MIBG scans.</p> <p>Contact information of the authors: not available.</p>

<sup>123</sup>I-MIBG: Iodine-123-metaiodobenzylguanidine; <sup>131</sup>I-MIBG: Iodine-131-metaiodobenzylguanidine; <sup>18</sup>F-FDG-PET: fluorine-18-fluorodeoxy-glucose positron emission tomography; <sup>99m</sup>Tc-DMSA: metastable-technetium-99-dimercaptosuccinic acid; <sup>99m</sup>Tc-MDP: metastable-technetium-99-methylidiphosphanate; AIEOP: Italian Association of Paediatric Hematology and Oncology; ANR: advances in neuroblastoma research; cm: centimetre; CT: computed tomography; EANM: European association of nuclear medicine; e.g.: exempli gratia; FDG-PET: fluoro-deoxy-glucose positron emission tomography; HR-NBL1: high risk-neuroblastoma 1; INSS: international neuroblastoma staging system; kcount: kilo count; keV: kilo-electron volt; kg: kilogram; kVp: kilovolt peak; mA: milli Ampère; m: metre; µg: microgram; mCi: milliCurie; mg: milligram; MBq: mega becquerel; MIBG: metaiodobenzylguanidine; min: minute; MRI: magnetic resonance imaging; NB-HR 01: neuroblastoma-high risk 01; n.r.: not reported; PET: positron emission tomography; RSNA: radiological society of North America; sec: second; SIOp: société internationale d'oncologie pédiatrique; SIOpEN: Society of Paediatric Oncology European Neuroblastoma Group; SNM: society of nuclear medicine; SPECT: single photon emission computed tomography; SPECT-CT: single photon emission tomography - computed tomography; US: ultrasound; WB: whole-body; WMIC: World Molecular Imaging Congress.

## ADDITIONAL TABLES

**Table 1. International Neuroblastoma Staging System (INSS)**

Stage	Explanation
1	Localised tumour with complete gross excision with or without microscopic residual disease; representative ipsilateral lymph nodes negative for tumour microscopically (nodes attached to and removed with the primary tumour may be positive).
2A	Localised tumour with incomplete gross resection; representative ipsilateral non-adherent lymph nodes negative for tumour microscopically.
2B	Localised tumour with or without complete gross excision with ipsilateral non-adherent lymph nodes positive for tumour; enlarged contralateral lymph nodes must be negative microscopically.
3	Unresectable unilateral tumour infiltrating across the midline <sup>a</sup> with or without regional lymph node involvement, localised unilateral tumour with contralateral regional lymph node involvement, or midline tumour with bilateral extension by infiltration (unresectable) or by lymph node involvement.
4	Any primary tumour with dissemination to distant lymph nodes, bone, bone marrow, liver, skin or other organs (except as defined for stage 4S).
4S	Localised primary tumour (as defined for stage 1, 2A or 2B) with dissemination limited to skin, liver or < 10% of bone marrow (limited to infants < 1 year of age). <sup>b</sup>

Multifocal primary tumours (e.g. bilateral adrenal primary tumours) should be staged according to the greatest extent of disease, as defined in the table, and followed by a subscript 'M' (e.g. 3M).

<sup>a</sup>The midline is defined as the vertebral column. Tumours originating on one side and crossing the midline must infiltrate to or beyond the opposite side of the vertebral column.

<sup>b</sup>Marrow involvement in stage 4S should be minimal (i.e. < 10% of total nucleated cells identified as malignant on bone marrow biopsy or marrow aspirate). More extensive marrow involvement would be considered to be stage 4. The metaiodobenzylguanidine scan (if performed) should be negative in the marrow (Brodeur 1988b; Brodeur 1993).

**Table 2. International Neuroblastoma Risk Group Staging System**

Stage	Explanation
L1	Localised tumour not involving vital structures as defined by the list of image-defined risk factors and confined to one body compartment.
L2	Locoregional tumour with presence of one or more image-defined risk factors.

**Table 2. International Neuroblastoma Risk Group Staging System** (Continued)

M	Distant metastatic disease (except stage MS).
MS	Metastatic disease in children younger than 18 months with metastases confined to skin, liver or bone marrow, or a combination.

Patients with multifocal primary tumours should be staged according to the greatest extent of disease as defined in the table (Monclair 2009).

**Table 3. Medication interfering with MIBG uptake**

<b>Opioids</b>	—
<b>Cocaine</b>	—
<b>Tramadol</b>	—
<b>Tricyclic antidepressants:</b>	Amitriptyline, amoxapine, butriptyline, clomipramine, desipramine, doxepine, dothiepin, imipramine, iprindole, lofepramine, loxapine, maprotiline, mazindol, protriptyline, salbutamol, trimipramine
<b>Sympathomimetics (components of bronchodilators, decongestants and diet aids):</b>	Amphetamine, dopamine, dobutamine, ephedrine, fenoterol, guanethidine, isoetharine, isoprenaline, isoproterenol, metaraminol, methylephedrine, metoserpidine, methoxamine, noradrenaline, nortriptyline, orciprenaline, oxymethazoline, phenoterol, phenylephrine, phenylpropanolamine, pirbuterol, pseudoephedrine, rimiterol, reproterol, salbutamol, terbutaline, trimazoline, xylometazoline
<b>Antihypertensive/cardiovascular agents:</b>	Amiodarone, bretylium, debrisoquin, guanethidine, labetalol, methoserpidine, metoprolol, reserpine  Calcium channel blockers: amlodipine, diltiazem, isradipine, lidoflazine, nicardipine, nifedipine, nimodipine, verapamil.  ACE inhibitors: captopril, enalapril
<b>Antipsychotics (frequent components of anti-emetic and anti-allergic agents):</b>	Phenothiazines: chlorpromazine, fluphenazine, loxapine, methotrimeprazine, pericyazine, perphenazine, prochlorperazine, promethazine, thiethylperazine, thioridazine, trifluoperazine  Thioxanthenes: flupenthixol, maprotiline, trazodone, zuclopenthixol  Butyrophenones: benperidol, droperidol, haloperidol, trifluoperidol

Bombardieri 2003c; Solanki 1992

**Table 4. QUADAS tool items and their interpretation**

<b>Item and guide to classification</b>
<b>1. Was the spectrum of patients representative of the patients who will receive the test in practice? Is it a selective sample of patients?</b>
Differences in demographic or clinical features between the study population and the source population may lead to selection bias or spectrum variation. In this item we will focus on selection bias: is a selective sample of patients included? The age group and method of patient recruitment will be assessed. Classify as:
<ul style="list-style-type: none"> <li>'yes' if the study describes a cohort of children 0 to 18 years old; if the study describes whether a suspected primary or relapsed neuroblastoma is concerned; if the study describes stage of the disease (1 to 4 and 4S).</li> </ul>

**Table 4. QUADAS tool items and their interpretation** (Continued)

- 'no' if the study describes patients older than 18 years old; if the study does not describe stage of the disease (1 to 4 and 4S); if the study recruited a group of healthy controls and a group known to have the target disorder.
- 'unclear' if there is insufficient information on these items.

---

**2. Is the reference standard likely to classify the target condition correctly?**

Estimates of test performance are based on the assumption that the reference standard will identify neuroblastoma with 100% sensitivity and 100% specificity. Such reference standards are rare. Errors due to an imperfect reference standard may bias the estimation of diagnostic performance. For this review acceptable reference standards are: 1) histopathology of primary tumour; or 2) bone marrow aspirates or trephine biopsies; or 3) histopathology during or after treatment, if urinary metabolites are elevated at diagnosis and additional imaging modalities suggest neuroblastoma at diagnosis (Brodeur 1993). Classify as:

- 'yes' if one of these tests is described as the reference test.
- 'no' if one or more reference standards used do not meet the pre-stated criteria.
- 'unclear' if there is insufficient information on the reference standard.

---

**3. Is the time period between reference standard and index test short enough to be reasonably sure that the target condition did not change between the two tests?**

Ideally the index test and the reference standard should be performed at the same time. If there is a considerable delay, misclassification due to treatment, spontaneous recovery or progression to a more advanced stage of disease may occur. Classify as:

- 'yes' if the time period between index test and reference standard is two weeks or less and no treatment was given in between.
- 'no' if the time period between index test and reference standard is longer than two weeks or if treatment was given in between.
- 'unclear' if there is insufficient information on the time period between index test and reference standard.

---

**4. Did the whole sample or a random selection of the sample receive verification using a reference standard?**

Partial verification bias occurs when not all of the study group receive confirmation of the diagnosis by the reference standard. Partial verification bias is very likely if the results of the index test influence the decision to perform the reference standard. Classify as:

- 'yes' if it is clear that all patients or a random selection of patients, that received the index test, went on to the reference standard, even if the reference standard is not the same for all patients.
- 'no' if not all patients, that received the index test, went on to the reference standard or if the selection of patients receiving the reference standard was not random.
- 'unclear' if there is insufficient information on this item.

---

**5. Did patients receive the same reference standard regardless of the index test result?**

Differential verification bias occurs when some of the index test results are verified by different reference standards. This is not unlikely in this review. Classify as:

- 'yes' if the same reference standard is used to verify the true disease status in  $\geq 90\%$  of the patients.
- 'no' if different reference standards are used to verify the true disease status in  $\geq 10\%$  of the patients.
- 'unclear' if there is insufficient information on this item.

---

**6. Was the reference standard independent of the index test (i.e. the index test did not form part of the reference standard)?**

Incorporation bias occurs when the result of the index test is used in establishing the final diagnosis. This will probably increase the amount of agreement between index test result and the outcome of the reference standard, and hence overestimate the various measures of diagnostic accuracy. Score:

- 'yes' if the index test is no part of the reference standard.
- 'no' if the index test is part of the reference standard.
- 'unclear' if there is insufficient information on this item.

---

**7. Were the reference standard results interpreted without knowledge of the results of the index test?**

Review bias occurs when interpretation of the results of the index test may be influenced by knowledge of the results of the reference standard, and vice versa. This may lead to inflated measures of diagnostic accuracy. Classify as:

**Table 4. QUADAS tool items and their interpretation** (Continued)

- 'yes' if the reference test results were interpreted blind to the results of the index test or blinding is dictated by the test order.
- 'no' if reference test results were interpreted with knowledge of the index test results.
- 'unclear' if there is insufficient information on this item.

---

**8. Were the index test results interpreted without knowledge of the results of the reference standard?**

Review bias occurs when interpretation of the results of the index test may be influenced by knowledge of the results of the reference standard, and vice versa. This may lead to inflated measures of diagnostic accuracy. Classify as:

- 'yes' if the test index test results are interpreted blind to the results of the reference test or blinding is dictated by the test order.
- 'no' if the index test results were interpreted with knowledge of reference test results.
- 'unclear' if there is insufficient information on this item.

---

**9. Were the same clinical data available when the test results were interpreted as would be available when the test is used in practice?**

The availability of clinical data during interpretation of test results may affect estimates of test performance. Classify as:

- 'yes' if clinical data, like demographic factors (sex and age); patient history and physical examination (e.g. abdominal extension, bone pains, respiratory distress); additional tests (urine catecholamines, ferritin, lactate dehydrogenase (LDH), other imaging modalities) are available when the test results are interpreted.
- 'no' if clinical data, like demographic factors (sex and age), patient history and physical examination (e.g. abdominal extension, bone pains, respiratory distress); additional tests (urine catecholamines, ferritin, LDH, other imaging modalities) are not available when the test results are interpreted.
- 'unclear' if there is insufficient information on which clinical information was available at the time of assessment.

---

**10. Were uninterpretable/intermediate test results reported?**

Uninterpretable or intermediate test results are often not reported in diagnostic accuracy studies. These uninterpretable or intermediate results are simply removed from the analysis. This may lead to biased assessment of test characteristics. If uninterpretable or intermediate test results occur randomly and are not related to disease status, bias is unlikely. Whatever the cause of uninterpretable results they should be reported in order to estimate their potential influence on diagnostic performance. Classify as:

- 'yes' if all test results are reported for all patients, including uninterpretable, indeterminate or intermediate results.
- 'no' if not all test results are reported for all patients, including uninterpretable, indeterminate or intermediate results.
- 'unclear' if it is unclear whether all results have been reported.

---

**11. Were withdrawals from the study explained?**

If patients lost to follow-up differ systematically from those who remain, for whatever reason, estimates of test performance may be biased. Classify as:

- 'yes' if it is clear what happened to all patients who entered the study (e.g. if a flow diagram is reported).
- 'no' if it is clear that not all patients completed the study (did not receive both index test and reference standard).
- 'unclear' if it is unclear whether all patients who entered the study received both index test and reference standard.

---

**12. Were selection criteria clearly described?**

This refers to whether studies have provided a clear definition of the criteria used as inclusion (0 to 18 years, primary or relapsed neuroblastoma of any stage) or exclusion criteria (> 18 years, pheochromocytoma, ganglioneuroma only) for entry into the study. Classify as:

- 'yes' if there is a description of how patients were selected for the study.
- 'no' if study selection criteria are not reported.
- 'unclear' if selection criteria are partially reported and there is not enough information to score this item.

---

**13. Was the execution of the index test described in sufficient detail to permit its replication?**

If tests are executed in different ways, this would be expected to impact on test performance. Details that should be described are: <sup>123</sup>I radioactive labelling, <sup>18</sup>F radioactive labelling, dosage, time between infusion and scanning. Score:



**Table 4. QUADAS tool items and their interpretation** (Continued)

- 'yes' if sufficient details or citations to permit replication of the index test are described or if this is done according to protocol.
- 'no' if sufficient details or citations to permit replication of the index test are not described.
- 'unclear' if there is insufficient information on this item.

---

**14. Was the execution of the reference standard described in sufficient detail to permit its replication?**

If tests are executed in different ways, this would be expected to impact on test performance.

Details that should be described for diagnosing the primary tumour are: pathologic diagnosis by a biopsy OR bone marrow aspirate or trephine biopsy; Shimada or INPCC classification.

Details that should be described for diagnosing metastases are: positive bone marrow or trephine aspirates; OR positive lesions on <sup>99m</sup>Tc skeleton scintigraphy, MRI or CT scan, or both; OR histologically proven palpable nodes or positive lesions on ultrasound, MRI or CT scan for non-palpable nodes, or both; OR positive liver lesions on ultrasound, MRI or CT scan, or both. Score:

- 'yes' if sufficient details or citations to permit replication of the reference standard are described or if this is done according to protocol.
- 'no' if sufficient details or citations to permit replication of the reference standard are not described.
- 'unclear' if there is insufficient information on this item.

---

**15. Did the study provide a clear definition of what was considered to be a 'positive' result of the index test?**

Classify as:

- 'yes' if the study describes what a positive or a negative result, or both, is.
- 'no' if the study does not describe what a positive or a negative result, or both is.
- Classify as 'unclear' if there is insufficient information on this item.

---

**16. Were data on inter-observer variation reported and within acceptable range?**

There may be considerable interobserver variation in scoring a MIBG scan. This may influence the diagnostic performance of the index test. It is difficult to give minimal cut-off scores for inter-observer agreement. A kappa or intra-class correlation coefficient (ICC) of 0.70 is considered to be acceptable. Classify as:

- 'yes' if information on inter-observer variation is given, and the results are acceptable.
  - 'no' if information on inter-observer variation is given, and the results demonstrate poor agreement.
  - 'unclear' if there is insufficient information on inter-observer variation.
- 

## APPENDICES

### Appendix 1. PubMed search strategy

#### 1. For neuroblastoma the following MeSH headings and text words were used:

(((neuroblastoma) OR (neuroblastomas) OR (neuroblast\*)) OR ((ganglioneuroblastoma) OR (ganglioneuroblastomas) OR (ganglioneuroblast\*)) OR ((neuroepithelioma) OR (neuroepitheliomas) OR (neuroepitheliom\*)) OR ((esthesioneuroblastoma) OR (esthesioneuroblastomas) OR (esthesioneuroblastom\*)) OR (Peripheral Primitive Neuroectodermal Tumors OR Peripheral Primitive Neuroectodermal Tumours OR Peripheral Primitive Neuroectodermal Neoplasm OR Primitive Neuroectodermal Tumor, Extracranial OR Neuroectodermal Tumor, Peripheral OR Neuroectodermal Tumors, Peripheral OR Peripheral Neuroectodermal Tumor OR Peripheral Neuroectodermal Tumors OR Tumor, Peripheral Neuroectodermal OR Tumors, Peripheral Neuroectodermal OR (pPNET OR PNET OR PNET\*)) OR Peripheral Primitive Neuroectodermal Tumor OR Peripheral Primitive Neuroectodermal Tumour OR Extracranial Primitive Neuroectodermal Tumor OR Extracranial Primitive Neuroectodermal Tumour OR Extracranial Primitive Neuroectodermal Tumors OR Extracranial Primitive Neuroectodermal Tumours OR Neuroectodermal Neoplasm, Peripheral Primitive OR Neuroectodermal Tumor, Peripheral Primitive) OR (Esthesioneuroblastomas, Olfactory OR Olfactory Esthesioneuroblastoma OR Olfactory Esthesioneuroblastomas OR Esthesioneuroblastoma, Paranasal Sinus-Nasal Cavity OR Esthesioneuroblastoma, Paranasal Sinus Nasal Cavity OR Neuroblastoma, Olfactory OR Neuroblastomas, Olfactory OR Olfactory Neuroblastomas OR Paranasal Sinus-Nasal Cavity Esthesioneuroblastoma

OR Paranasal Sinus Nasal Cavity Esthesioneuroblastoma OR Aesthesioneuroblastoma OR Aesthesioneuroblastomas OR Olfactory Neuroblastoma)

## 2. For MIBG scintigraphy or PET imaging the following MeSH headings and text words were used:

(MIBG OR Iodine-123 Metaiodobenzylguanidine Imaging OR Iodine-123 Metaiodobenzylguanidine Imag\* OR Metaiodobenzylguanidine OR Metaiodobenzylguanidin\* OR Metaiodobenzylguanidine scintigraphy OR Metaiodobenzylguanidine scintigraph\*)

OR  
 (123I-mIBG) OR (3 Iodobenzylguanidine OR meta-Iodobenzylguanidine OR meta Iodobenzylguanidine OR Iobenguane OR m-Iodobenzylguanidine OR m Iodobenzylguanidine OR (Iobenguane AND (131I) OR (3-Iodo- AND (131I) AND benzyl) AND guanidine) OR 3-Iodobenzylguanidine, 123I Labeled OR 123I Labeled 3-Iodobenzylguanidine OR 3 Iodobenzylguanidine, 123I Labeled OR meta-Iodobenzylguanidine OR meta Iodobenzylguanidine OR m-Iodobenzylguanidine OR m Iodobenzylguanidine OR Iobenguane (131I) OR (3-Iodo-(131I)benzyl)guanidine) OR (77679-27-7[rn])

OR  
 (Positron Emission Tomography OR Positron Emission Tomograph\* OR Tomography, Positron-Emission OR Tomography, Positron Emission OR PET Scan OR PET Scans OR Scan, PET OR Scans, PET OR PET Scan\* OR PET)

OR  
 (SPECT OR SPECT-CT OR 18F-FDG-PET-CT OR Single Photon Emission Computed Tomography OR Single photon emission computerized tomography OR Single photon emission computerised tomography OR Tomography, Emission-Computed, Single-Photon)

OR  
 (Single Photon Emission Computed Radionuclide Tomography OR Single Photon Emission CT Scan OR Single Photon Emission CAT scan OR Single Photon Emission Computer Assisted Tomography OR 18 F-FDG-PET OR 18-fluorodeoxy\* OR 18fluorodeoxy\* OR fdgpet OR fdg pet OR 18f fdg\* OR Single Photon Emission Computed Radionuclide Tomograph\* OR Single Photon Emission CT Scan\* OR Single Photon Emission CAT scan\* OR Single Photon Emission Computer Assisted Tomograph\* OR Single Photon Emission Computed Tomograph\* OR Single photon emission computerized tomograph\* OR Single photon emission computerised tomograph\* OR fluorodeoxyglucose f18)

## 3. (1 AND 2) NOT case reports [pt]

\* = zero or more characters

## Appendix 2. EMBASE search strategy

### 1. For neuroblastoma the following Emtree terms and text words were used:

1. exp neuroblastoma/
2. (neuroblastoma or neuroblastomas or neuroblast\$).mp.
3. (ganglioneuroblastoma or ganglioneuroblastomas or ganglioneuroblast\$).mp.
4. exp olfactory neuroepithelioma/ or exp neuroepithelioma/
5. (neuroepithelioma or neuroepitheliomas or neuroepitheliom\$).mp.
6. exp esthesioneuroblastoma/
7. (esthesioneuroblastoma or esthesioneuroblastomas or esthesioneuroblastom\$).mp.
8. exp neuroectoderm tumor/ or (peripheral primitive neuroectodermal tumors or peripheral primitive neuroectodermal tumours).mp.
9. (peripheral primitive neuroectodermal neoplasm or peripheral primitive neuroectodermal neoplasms).mp.
10. (peripheral neuroectodermal tumor or peripheral neuroectodermal tumors or peripheral neuroectodermal tumour or peripheral neuroectodermal tumours).mp.
11. (pPNET or PNET or PNET\$).mp.
12. (peripheral primitive neuroectodermal tumor or peripheral primitive neuroectodermal tumour).mp.
13. (extracranial primitive neuroectodermal tumor or extracranial primitive neuroectodermal tumors or extracranial primitive neuroectodermal tumour or extracranial primitive neuroectodermal tumours).mp.
14. (olfactory esthesioneuroblastoma or olfactory esthesioneuroblastomas).mp.
15. (olfactory neuroblastoma or olfactory neuroblastomas).mp.
16. (paranasal sinus-nasal cavity esthesioneuroblastoma or paranasal sinus nasal cavity esthesioneuroblastoma).mp.
17. (aesthesioneuroblastoma or aesthesioneuroblastomas).mp.
18. or/1-17

### 2. For MIBG scintigraphy or PET imaging the following Emtree terms and text words were used:

1. exp "(3 iodobenzyl)guanidine i 123"/ or exp "(3 iodobenzyl)guanidine"/ or exp "(3 iodobenzyl)guanidine i 131"/
2. MIBG.mp.
3. (Iodine-123 Metaiodobenzylguanidine Imaging or Iodine-123 Metaiodobenzylguanidine Imag\$).mp.
4. (Metaiodobenzylguanidine or Metaiodobenzylguanidin\$).mp.
5. (Metaiodobenzylguanidine scintigraphy or Metaiodobenzylguanidine scintigraph\$).mp.
6. 123I-mIBG.mp.
7. 3 Iodobenzylguanidine.mp.

### 123I-MIBG scintigraphy and 18F-FDG-PET imaging for diagnosing neuroblastoma (Review)

8. (meta-Iodobenzylguanidine or meta Iodobenzylguanidine).mp.
9. lobenguane.mp.
10. (m-Iodobenzylguanidine or m Iodobenzylguanidine).mp.
11. (3-Iodo- and 131I and benzyl and guanidine).mp.
12. 123I Labeled 3-Iodobenzylguanidine.mp.
13. (meta-Iodobenzylguanidine or meta Iodobenzylguanidine).mp.
14. (m Iodobenzylguanidine or m-Iodobenzylguanidine).mp.
15. 77679-27-7.rn.
16. or/1-15
17. exp positron emission tomography/ or exp fluorodeoxyglucose f18/
18. (positron emission tomography or positron emission tomograph\$).mp.
19. (PET scan or PET scans or PET scan\$ or PET).mp.
20. (SPECT or SPECT-CT or 18F-FDG-PET-CT).mp.
21. exp single photon emission computer tomography/
22. (single photon emission computed tomography or single photon emission computerized tomography or single photon emission computerised tomography).mp.
23. single photon emission computed radionuclide tomography.mp.
24. (Single Photon Emission CT Scan or Single Photon Emission CT Scan\$).mp.
25. (Single Photon Emission CAT scan or Single Photon Emission CAT scan\$).mp.
26. (Single Photon Emission Computer Assisted Tomography or Single Photon Emission Computer Assisted Tomograph\$).mp.
27. 18 F-FDG-PET or 18-fluorodeoxy\$ or 18fluorodeoxy\$ or fdgpet or fdg pet or 18f fdg\$).mp.
28. Single Photon Emission Computed Radionuclide Tomograph\$.mp.
29. Single Photon Emission Computed Tomograph\$.mp.
30. (Single photon emission computerized tomograph\$ or Single photon emission computerised tomograph\$).mp.
32. or/17-30
33. 16 or 31

### 3. (1 AND 2) not (case report or case reports)

mp = title, abstract, subject headings, heading word, drug trade name, original title, device manufacturer, drug manufacturer name

\$ = zero or more characters

/ = Emtree term

## CONTRIBUTIONS OF AUTHORS

Lieve Tytgat, Gitta Bleeker and Elvira van Dalen conceived the review.

Gitta Bleeker, Godelieve Tytgat, Judit Adam, Huib Caron, Lotty Hooft, Leontien Kremer and Elvira van Dalen designed the review.

Elvira van Dalen co-ordinated the review.

Gitta Bleeker, Godelieve Tytgat, Judit Adam, Lotty Hooft, Leontien Kremer and Elvira van Dalen collected data for the review.

Elvira van Dalen and Gitta Bleeker (with help of Edith Leclercq, Trials Search Co-ordinator) designed the search strategies.

Edith Leclercq (Trials Search Co-ordinator) performed literature searches.

Gitta Bleeker, Godelieve Tytgat and Elvira van Dalen screened the search results.

Gitta Bleeker, Godelieve Tytgat and Elvira van Dalen screened retrieved papers against inclusion criteria.

Gitta Bleeker, Godelieve Tytgat, Judit Adam, Leontien Kremer and Elvira van Dalen appraised the quality of papers.

Gitta Bleeker, Godelieve Tytgat, Judit Adam, Leontien Kremer and Elvira van Dalen extracted data from papers.

Lotty Hooft and Elvira van Dalen performed third party arbitration.

Gitta Bleeker organised retrieval of papers; wrote to authors of papers for additional information; obtained and screened data from unpublished studies; managed data for the review; entered data into [RevMan 2014](#); and wrote the review.

Gitta Bleeker, Lotty Hooft and Hans Reitsma analysed the data.

Gitta Bleeker, Godelieve Tytgat, Judit Adam, Huib Caron, Lotty Hooft, Leontien Kremer and Elvira van Dalen interpreted the data.

Gitta Bleeker, Lotty Hooft, Leontien Kremer and Elvira van Dalen provided a methodological perspective.

Gitta Bleeker, Godelieve Tytgat, Judit Adam and Huib Caron provided a clinical perspective.

Gitta Bleeker, Godelieve Tytgat, Judit Adam, Huib Caron, Lotty Hooft, Leontien Kremer and Elvira van Dalen provided general advice on the review.

## DECLARATIONS OF INTEREST

The review authors declare that they have no known conflict of interest.

Huib N. Caron was not employed by F. Hoffmann-LaRoche AG until after the work on the review was complete, and will not participate in any updates.

## SOURCES OF SUPPORT

### Internal sources

- Dutch Cochrane Center, Netherlands.

### External sources

- Stichting Kinderen Kankervrij (KIKa), Netherlands.

## DIFFERENCES BETWEEN PROTOCOL AND REVIEW

1. In the [Methods](#) section we added two reasons for exclusion:
  - a. Types of studies: we excluded studies that reported < ten eligible patients, because we assumed that these studies would not give robust results. If the test results of just one patient changes, the sensitivity or specificity, or both, can be totally different. Therefore, these studies might over- or underestimate the sensitivity or specificity, or both, by chance. Including many of these studies might enlarge this overestimating effect enormously.
  - b. Participants: we excluded studies performed in children with esthesioneuroblastoma and olfactory neuroblastoma, because these diseases are other disease entities. Neuroblastoma arises from the sympathetic nervous system. Esthesioneuroblastoma/olfactory neuroblastoma arises from the olfactory epithelium.
2. In the [Statistical analysis and data synthesis](#) section we reported that we analysed data on patient level and lesion level. Only one study provided data at lesion level. We included this study because data at lesion level are important for staging and treatment allocation.
3. In the [Types of studies](#) section we changed "Studies had to report sufficient data to construct a two-by-two table" into "Studies had to report sufficient data to construct (part of) a two-by-two table". We also added: "Considering the nature of the disease it is expected that mainly proven neuroblastoma will be reported and that thus often only sensitivity can be analysed".
4. In the [Types of studies](#) section we added case series of proven neuroblastoma.

## INDEX TERMS

### Medical Subject Headings (MeSH)

\*3-Iodobenzylguanidine; \*Positron-Emission Tomography; \*Tomography, Emission-Computed, Single-Photon; Neuroblastoma [\*diagnostic imaging] [pathology] [secondary]; Sensitivity and Specificity

### MeSH check words

Adolescent; Child; Child, Preschool; Humans; Infant; Infant, Newborn