

Primary Thymic Mucinous Adenocarcinoma: A Case Report

Jamshid Abdul-Ghafar
Suk-Joong Yong¹ · Woocheol Kwon²
Il Hwan Park³ · Soon-Hee Jung

Departments of Pathology, ¹Internal Medicine, ²Radiology, and ³Thoracic Surgery, Yonsei University Wonju College of Medicine, Wonju, Korea

Received: August 31, 2011
Revised: September 29, 2011
Accepted: November 1, 2011

Corresponding Author

Soon-Hee Jung, M.D.
Department of Pathology, Yonsei University Wonju College of Medicine, 20 Ilisan-ro, Wonju 220-701, Korea
Tel: +82-33-741-1551
Fax: +82-33-731-6590
E-mail: soonheej@yonsei.ac.kr

Primary thymic mucinous adenocarcinoma is an extremely rare aggressive subtype of thymic carcinoma. With a review of literatures, only nine cases have been reported up to present. A 36-year-old woman was admitted for further evaluation and treatment of a mediastinal mass. The patient had no medical history of cancer. The clinicoradiological examination disclosed no tumor elsewhere. After the surgical excision of mediastinal mass, it was grossly a round semi-solid mass with mucin-filled cystic areas. Microscopically solid areas showed cords, small nests and dilated glands infiltrating the fibrotic parenchyma, while the cystic areas were lined by mucinous epithelium with tumor cells floating in extracellular-mucin pools. Some cystic walls underwent malignant transformation of the benign thymic epithelium. Immunohistochemically, the tumor cells were positive for cytokeratin (CK) 7, CK20, CD5, and CDX-2, and negative for thyroid transcription factor-1. In conclusion, the mucinous thymic adenocarcinoma should be recognized as a separate histopathological entity and considered in the differential diagnosis of mediastinal carcinomas.

Key Words: Thymus gland; Adenocarcinoma, mucinous; Mediastinal cyst; Immunohistochemistry

Thymic carcinomas have attracted much attention in the recent literature not only because they are morphologically heterogeneous but also because they pose a diagnostic and therapeutic challenge for both clinicians and pathologists.^{1,2} Primary thymic carcinomas that include squamous cell, basaloid, mucoepidermoid, lymphoepithelioma-like, sarcomatoid, clear cell and neuroendocrine carcinomas, as well as papillary ones, are rare epithelial neoplasms as categorized in the latest World Health Organization (WHO) classification of thymic epithelial tumors.¹⁻⁹ Primary thymic adenocarcinoma, that of mucinous type in particular, is an extremely rare entity. Thymic mucinous adenocarcinoma was first reported by Choi *et al.*⁴ in 2003. To date, only eight cases, including one Japanese case, have been documented in the literature.²⁻⁷

In the current report, we describe a case of mucinous adenocarcinoma arising from a thymic cyst. We also discuss the clinicopathologic features and follow-up in a patient with primary thymic mucinous adenocarcinoma. Here, we report our case with a review of literatures.

CASE REPORT

A 36-year-old woman was admitted to our hospital for further evaluation and treatment of a mediastinal mass. The patient had no notable medical history. On chest radiography and computed tomography (CT) scans, the patient had a round, 5.6×4.4 cm-sized lobulated cystic mass in the anterior mediastinum (Fig. 1A). To exclude a metastatic neoplasm to the mediastinum, we performed a comprehensive examination, including a detailed history taking; physical examinations including breast and pelvic examinations; upper and lower gastrointestinal endoscopic examinations; a CT examination of the chest, abdomen and pelvis; and a positron emission tomography and bone scans (Fig. 1B). But this disclosed no evidence of primary tumor elsewhere. The patient received a surgical excision of mediastinal mass, showing that the resected mediastinal mass consisted of a 9×6×5 cm-sized, round, tan-to-white, fairly well-circumscribed, lobulated mass (Fig. 1C). The cut surface revealed multiple, variable sized, multiloculated cysts separated by solid and semi-solid areas. The cysts had smooth walls and were filled with mucinous fluid (Fig. 1D). Microscopically, there was

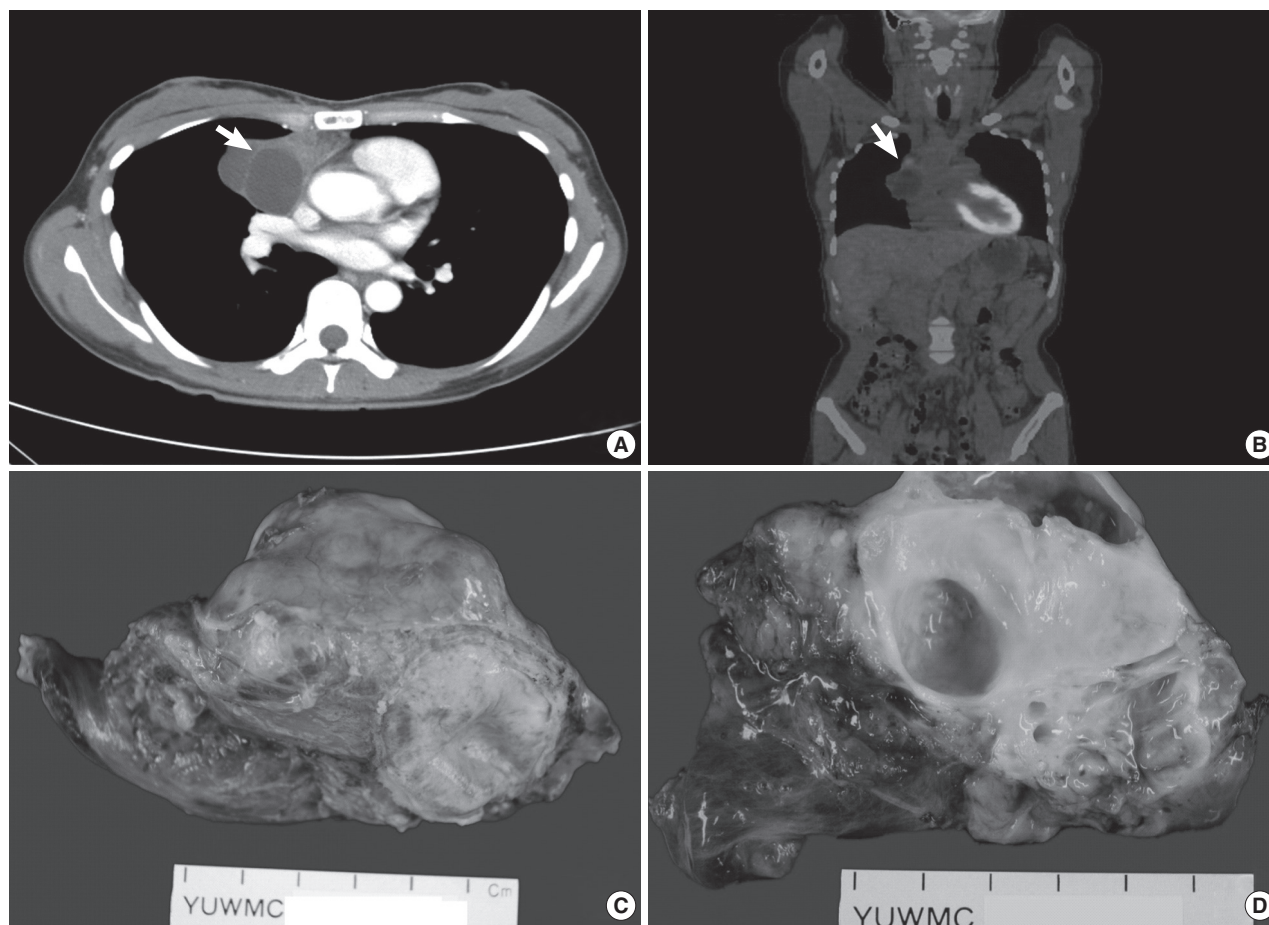


Fig. 1. Radiologic and gross findings. (A) The chest computed tomography (CT) shows a 5.6×4.4 cm sized, multiloculated cystic mass (arrow) with heterogenous enhancing septa (37–57 hounsfield unit) in the right anterior mediastinum. (B) On positron emission tomography-CT scans, the solid part of the mass shows nodular F-18 fluorodeoxyglucose (FDG) uptake. There is no remarkable FDG uptake in the entire body. (C) A round mass with a smooth, lobulated external surface. (D) The cut surface reveals yellow-white solid mass with multiple cysts of variable sizes, filled with mucinous fluid.

a residual presence of the normal thymic tissue with fatty replacement in the periphery of the lesion (Fig. 2A). The tumor showed solid and cystic areas that are lined by cuboidal to pseudostratified columnar epithelial cells. Some cystic walls underwent malignant transformation from the benign thymic epithelium (Fig. 2B). The solid area showed dilated glands, cords and small nests that infiltrated the fibrotic parenchyma (Fig. 2C). The neoplastic cells were abundant in mucinous cytoplasm with basally-located, mild-to-moderately pleomorphic, slightly hyperchromatic nuclei, which was accompanied by the presence of small nucleoli. In addition, there were also occasional mitoses with atypical forms. There were floating tumor cells in extracellular mucin pools (Fig. 2D). We performed an immunohistochemical staining using antibodies to cytokeratin (CK) 7, CK20, CD5, CDX-2 and thyroid transcription factor-1 (TTF-1) by serving appropriate negative and positive controls. This showed

that the tumor cells were diffuse cytoplasmic and membranous positive for CK7, CK20 and focal nuclear positive for CDX-2 (Fig. 3A-C). Some tumor cells and normal thymic tissue were positive for CD5 (Fig. 3D). The primary pulmonary marker, TTF-1, was negative in both tumor cells and normal thymic tissue.

Postoperatively, the patient was followed up after receiving radical-aimed radiotherapy and chemotherapy (six cycles of Taxol/CDDP regimen). On chest CT scans at a 1-year follow-up, the patient had multiple metastatic nodules in both lungs with malignant pleural effusion. On postoperative month 15, the patient died of disease.

DISCUSSION

Primary thymic carcinoma is a rare entity that poses a diag-

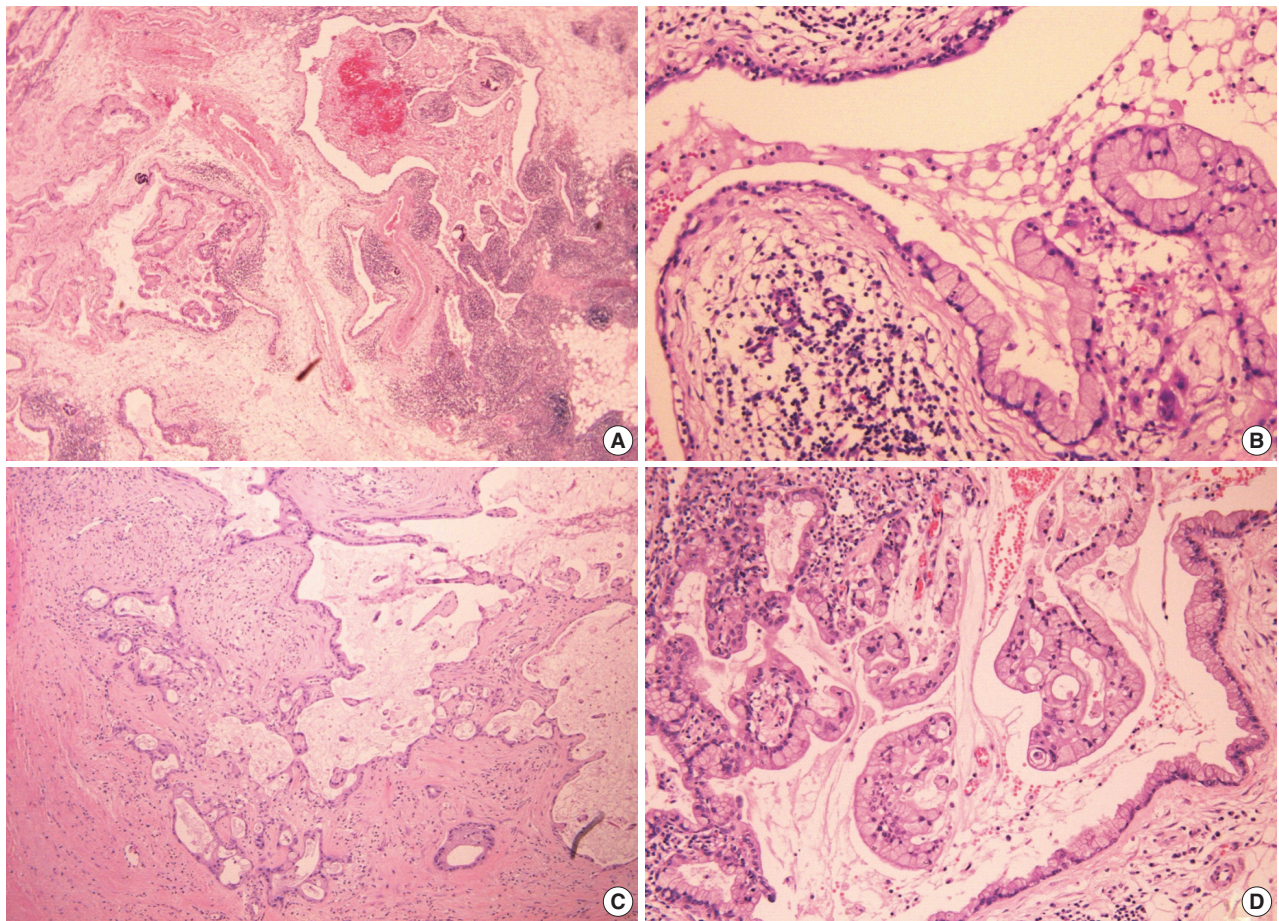


Fig. 2. Microscopic findings. (A) The low microscopic field shows the residual thymic tissue in lymphocyte-rich cortex (right lower) and multifocal cyst formation. (B) The cyst is lined by malignant mucinous epithelium undergoing the transition from the benign flattened thymic epithelium of the cyst wall. (C) The malignant mucinous glands infiltrates in the fibrotic parenchyma of tumor. (D) Island of atypical cells floats in pools of extracellular mucin.

nostic challenge for both clinicians and pathologists because of their infrequent occurrence and variable histological features.² The majority of reported cases of primary thymic carcinomas are squamous cell carcinoma or its variants.⁶ Of the primary adenocarcinomas, mucinous adenocarcinoma is the rarest histologic subtype. Only nine cases have been documented since it was first reported by Choi *et al.*⁴ in 2003.^{2,3,5-7}

In making a proper diagnosis of primary thymic mucinous adenocarcinoma, the clinicopathologic and radiological findings are needed. Clinically, the tumor should be confined to the anterior mediastinum with no evidence of tumor in other organs.³ Histopathologically, the malignant transformation of benign epithelial cells of the thymic cyst is essential for making a correct diagnosis of the primary thymic adenocarcinoma. These lining epithelial cells, whether they are benign or malignant, are positive for CD5, a marker of thymic epithelial cells. In our case, there was a transitional zone where the CD5-positive, be-

nign epithelial cells lining the cyst underwent malignant transformation.

Primary mucinous adenocarcinoma of the thymus is a diagnosis of exclusion. On routine microscopic examination alone, the tumor is suggestive of mucinous adenocarcinoma occurring in the gastrointestinal tract, pancreaticobiliary tract, lung, breast and ovary.⁷ In addition, adenocarcinoma arising in a mediastinal teratoma, thymic carcinoid tumor with prominent mucinous stroma or mucoepidermoid carcinoma should be considered in the differential diagnosis.⁶ The carcinoid tumor with prominent mucinous stroma is composed of a conventional neuroendocrine morphology such as an organoid pattern and a delicate fibrovascular septum. In establishing a diagnosis as mucoepidermoid carcinoma, the histological findings should include both the squamous and the mucin-producing components. In addition, all the three germ cell layers should also be present for making a diagnosis of mediastinal teratoma. But these findings were

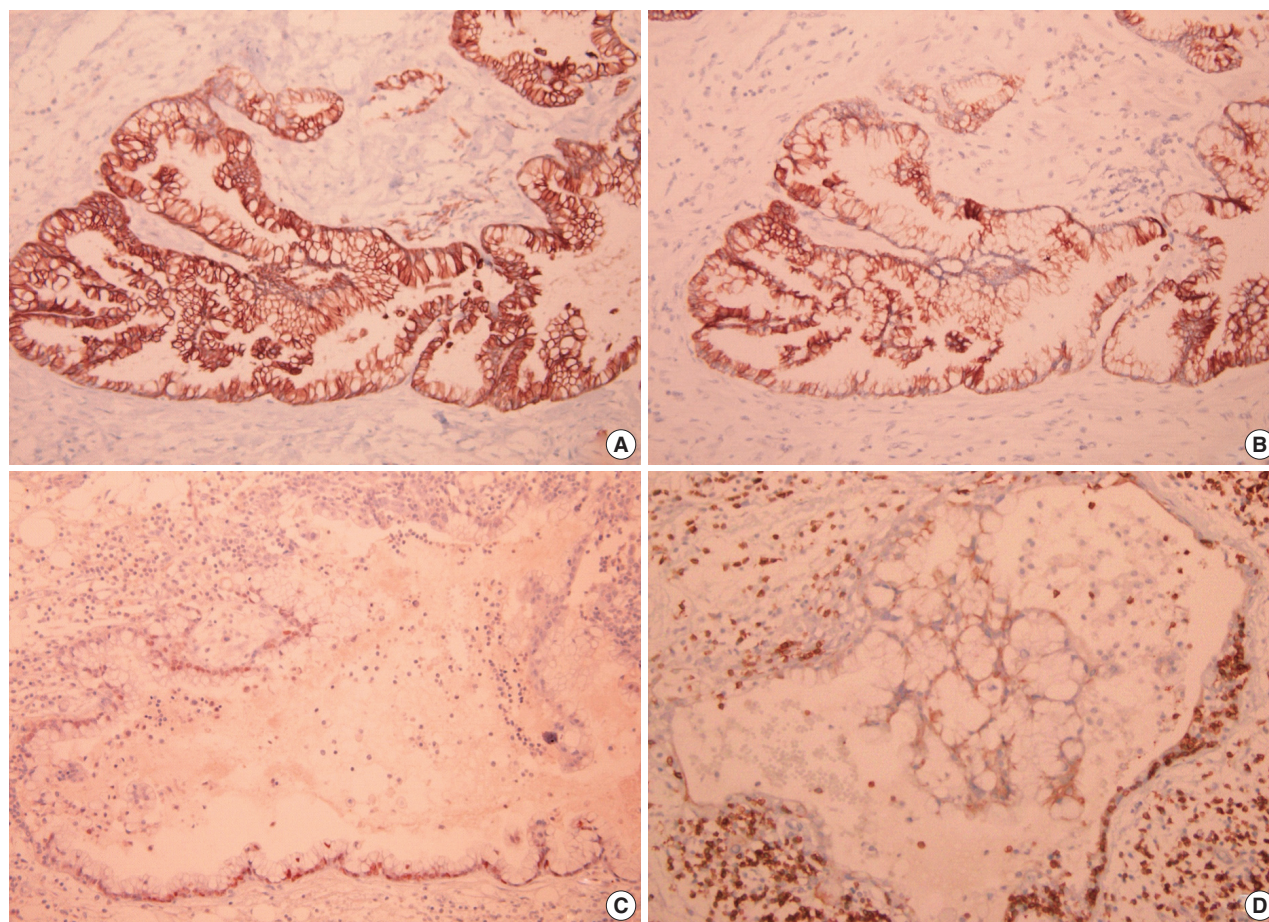


Fig. 3. Immunohistochemical stains. (A) The immunohistochemical stains reveal strong positivity for cytokeratin (CK) 7 and (B) CK20 and focal positivity for (C) CDX-2. (D) The thymic tissue and epithelium lining the thymic (benign) cyst shows a positive reaction for CD5.

not found in our case.

Presumably, the respiratory tract might be one of the most common primary sites of the occurrence of metastatic mediastinal adenocarcinoma.² It is known that TTF-1 is a very specific marker for the primary pulmonary adenocarcinoma.⁶ It is not expressed in cases of thymic mucinous adenocarcinoma. But it is expressed in 77-100% of total cases of pulmonary mucinous adenocarcinoma.² We think that TTF-1 is a very useful marker for differentiating thymic and primary pulmonary mucinous adenocarcinomas.

There are no specific immunohistochemical markers for the tumors of thymic origin. CD5, a lymphocytic marker, is expressed in approximately 70% of all cases of thymic adenocarcinoma and it is relatively uncommon in non-thymic carcinomas.⁶

Immunostaining for CK7, CK20, and CDX-2 is helpful for the differential diagnosis of mucinous adenocarcinoma from other thymic carcinomas, such as adenocarcinoma with mucinous differentiation arising in a mediastinal teratoma, thymic

carcinoid tumor with prominent mucinous stroma or mucoepithelioid carcinoma with mucinous differentiation. However, these immunostains are not helpful for differentiation of primary thymic mucinous adenocarcinomas from metastatic mucinous one. This is due to the positive staining of those markers in pulmonary, gastrointestinal and ovarian mucinous adenocarcinomas. In our case, immunohistochemical stains of tumor cells were diffuse positive for CK7 and CK20; focal positive for CD5 and CDX-2; and negative for TTF-1. These findings are close to those seen in a case reported by Choi *et al.*⁴ In our case, the cysts met all the diagnostic criteria for an acquired multilocular thymic cyst.⁷ It has been postulated that the thymic epithelium would potentially undergo glandular differentiation, as evidenced by the presence of ciliated and mucinous cells in the epithelium of the cysts.⁴ A rare instance of malignant transformation of thymic cyst had also been described,^{2,4,7} and it was focally present in our case. It is difficult to describe the prognosis of this rare entity because of a smaller number of cases. It ap-

Table 1. Summary of the reported cases of thymic mucinous adenocarcinoma

Reference	Sex/Age (yr)	Tumor size (cm)	Associated thymic cyst	Treatment	Clinical course/Follow-up
Current case	F/36	9.0×6.0×5.0	(+)	S, RTx, CTx	CT: lung nodules, malignant pleural effusion; DOD at 15 mo
Seki <i>et al.</i> ⁵	F/34	13×10×8.0	(-)	N/A	N/A
Maeda <i>et al.</i> ² (case 1)	F/52	9.5×6.0×5.5	(+)	S, RTx, CTx	MTS: lung, cervical lymph node; AWD at 11 mo
Maeda <i>et al.</i> ² (case 2)	M/38	8.0×7.0×3.5	(-)	S, RTx, CTx	MTS: bone; DOD at 12 mo
Maeda <i>et al.</i> ² (case 3)	M/55	13.0×7.0×4.5	(-)	S, RTx, CTx	MTS: bone, liver, lungs, adrenal gland; Diss: pleura, meninges; DOD at 24 mo
Choi <i>et al.</i> ⁴	M/15	8.0×5.0×4.0	(+)	S, RTx	MTS: bone; DOD at 26 mo
Takahashi <i>et al.</i> ⁶	M/59	Exceeding 10	(-)	RTx	DOD at 11 mo
Kapur <i>et al.</i> ⁷	M/38	10.5×8.0×2.5	(+)	S, RTx, CTx	MTS: lung (resected); NED at 12 mo
Ra <i>et al.</i> ³ (case 1)	F/61	5.2×3.9	(-)	S, RTx	MTS: retroperitoneal lymph nodes (at 5 mo)
Ra <i>et al.</i> ³ (case 2)	F/82	14.5×7.0	(+)	S	Passed away from complication of surgery

F, female; S, resection; RTx, radiotherapy; CTx, chemotherapy; CT, computed tomography; DOD, died of disease; N/A, no information available; MTS, metastasis; AWD, alive with disease; M, male; Diss, dissemination; NED, no evidence of disease.

pears, however, that the thymic mucinous adenocarcinoma may behave aggressively than the non-mucinous one.⁷ With a review of literatures and based on our case, it can be concluded that thymic mucinous adenocarcinoma occurs in relatively young age with an average age of 47 years (range, 15 to 82 years) and with a male-to-female ratio of 1:1. The tumor size is large with an average size of 10.27 cm (range, 5.2 to 14.5 cm) and 50% (5/10) of cases are associated with cystic change. All of the patients with mucinous thymic adenocarcinoma died of disease or had metastatic lesions few months after the diagnosis (Table 1).

In conclusion, we believe that this aggressive subtype of thymic adenocarcinoma should be regarded as a distinct variant of thymic carcinoma. It is an extremely rare tumor for which a comprehensive, clinical, radiological and pathological work-up should be done to make a correct diagnosis of and to promptly manage it.

Conflicts of Interest

No potential conflict of interest relevant to this article was reported.

REFERENCES

- Suster S. Thymic carcinoma: update of current diagnostic criteria and histologic types. *Semin Diagn Pathol* 2005; 22: 198-212.
- Maeda D, Ota S, Ikeda S, *et al.* Mucinous adenocarcinoma of the thymus: a distinct variant of thymic carcinoma. *Lung Cancer* 2009; 64: 22-7.
- Ra SH, Fishbein MC, Baruch-Oren T, *et al.* Mucinous adenocarcinomas of the thymus: report of 2 cases and review of the literature. *Am J Surg Pathol* 2007; 31: 1330-6.
- Choi WW, Lui YH, Lau WH, Crowley P, Khan A, Chan JK. Adenocarcinoma of the thymus: report of two cases, including a previously undescribed mucinous subtype. *Am J Surg Pathol* 2003; 27: 124-30.
- Seki Y, Imaizumi M, Shigemitsu K, Yoshioka H, Ueda Y. Mucinous adenocarcinoma of the anterior mediastinum. *Kyobu Geka* 2004; 57: 413-6.
- Takahashi F, Tsuta K, Matsuno Y, *et al.* Adenocarcinoma of the thymus: mucinous subtype. *Hum Pathol* 2005; 36: 219-23.
- Kapur P, Rakheja D, Bastasch M, Molberg KH, Sarode VR. Primary mucinous adenocarcinoma of the thymus: a case report and review of the literature. *Arch Pathol Lab Med* 2006; 130: 201-4.
- Okuda M, Huang CL, Haba R, Yokomise H. Clear cell carcinoma originating from ectopic thymus. *Gen Thorac Cardiovasc Surg* 2009; 57: 269-71.
- Morikawa H, Tanaka T, Hamaji M, Ueno Y, Hara A. Papillary adenocarcinoma developed in a thymic cyst. *Gen Thorac Cardiovasc Surg* 2010; 58: 295-7.