

Multiple myeloma with crystal-storing histiocytosis, crystalline podocytopathy, and light chain proximal tubulopathy, revealed by retinal abnormalities

A case report

Idris Boudhabhay, MD^a, Chérif Titah, MD^b, Alexis Talbot, MD^a, Stéphanie Harel, MD^a, Jérôme Verine, MD, PhD^c, Guy Touchard, MD, PhD^d, Sihem Kaaki^d, Eric Gabison, MD, PhD^b, Vivien Vasseur^e, Martine Mauget-Faÿsse, MD^e, Thomas Sené, MD^{f,*}

Abstract

Rationale: Crystal sorting histiocytosis (CSH) is a rare disorder that is morphologically characterized by the accumulation of monoclonal immunoglobulin crystals, predominantly of a kappa light chain type, within lysosomes of macrophages. CSH may result in a variety of clinical manifestations depending on the involved organs. In this case report, we aim to describe a patient with ophthalmic manifestations which lead to the diagnosis of multiple myeloma with crystal-storing histiocytosis, crystalline podocytopathy, and light chain proximal tubulopathy.

Patient concerns: A 60-year-old male patient presented with progressive bilateral decreased vision for 2 years.

Diagnosis: Ophthalmic explorations showed bilateral macular and papillary edema, and multiple crystalline deposits in the anterior stromal cornea and in the retina. Laboratory tests showed nephrotic syndrome and renal dysfunction. Further work-up revealed IgG kappa multiple myeloma, with biopsy-proven combined crystalline podocytopathy and tubulopathy.

Interventions: The patient received chemotherapy (bortezomib, cyclophosphamide, and dexamethasone for 3 cycles, then bortezomib, lenalidomide, and dexamethasone).

Outcomes: Despite partial hematologic response and improvement of the papilledema and macular edema, the patient developed dialysis-dependent end-stage renal failure.

Lessons: This report, highlighting the protean presentation of paraprotein-mediated injuries, provides additional information on the ocular anomalies not previously described that may be associated with crystal-storing histiocytosis.

Abbreviations: CSH = crystal-storing histiocytosis, FLC = free light chain, FS = Fanconi syndrome, FSGS = focal segmental glomerulosclerosis, Ig = immunoglobulin (s), LC = light chain, LCDD = light chain deposition disease, LCPT = light chain proximal tubulopathy, LE = left eye, M = monoclonal, MGCS = monoclonal gammopathy of clinical significance, MGRS = monoclonal gammopathy of renal significance, MM = multiple myeloma, MRI = magnetic resonance imaging, OCT = optical coherence tomography, RE = right eye.

Keywords: crystalline podocytopathy, crystalline tubulopathy, crystal-storing histiocytosis, eye, light chain proximal tubulopathy, macular edema, multiple myeloma, papillary edema

Editor: N/A.

The authors report no conflict of interest.

^a Department of Immuno-Hematology, Hôpital Saint-Louis, ^b Department of Ophthalmology, Fondation Ophthalmologique Adolphe de Rothschild, ^c Department of Pathology, Hôpital Saint Louis, Paris, ^d Department of Pathology, Centre Hospitalier Universitaire de Poitiers, Poitiers, ^e Department of Clinical Research, Fondation Ophthalmologique Adolphe de Rothschild, ^f Department of Internal Medicine, Fondation Ophthalmologique Adolphe de Rothschild, Paris, France.

* Correspondence: Thomas Sené, Service de Médecine Interne, Fondation Ophthalmologique Adolphe de Rothschild, 29 Rue Manin, 75019 Paris, France (e-mail : tsene@for.paris).

Copyright © 2018 the Author(s). Published by Wolters Kluwer Health, Inc. This is an open access article distributed under the terms of the Creative Commons Attribution-Non Commercial-No Derivatives License 4.0 (CCBY-NC-ND), where it is permissible to download and share the work provided it is properly cited. The work cannot be changed in any way or used commercially without permission from the journal.

Medicine (2018) 97:52(e13638)

Received: 30 August 2018 / Accepted: 20 November 2018

<http://dx.doi.org/10.1097/MD.0000000000013638>

1. Introduction

Multiple myeloma (MM) is a clonal plasma cell malignancy typically accompanied by the secretion of monoclonal (M) immunoglobulins (Ig). Sometimes, even a small clone can lead to severe organ damage through the production and deposition of this M-protein leading to monoclonal gammopathy of clinical significance (MGCS) such as monoclonal gammopathy of renal significance (MGRS).^[1–3] On rare occasions, paraproteins can crystallize intracellularly within proximal tubular cells (crystalline tubulopathy or light chain proximal tubulopathy [LCPT]),^[4,5] podocytes (crystalline podocytopathy),^[6–8] or interstitial histiocytes (crystal-storing histiocytosis [CSH]).^[9–11]

We describe a patient with multiple myeloma, associated with CSH and combined crystalline tubulopathy and podocytopathy, revealed by ophthalmologic anomalies not previously reported.

2. Case report

A 60-year-old pseudophakic male of African origin was referred to our hospital for progressive decreased vision for 2 years. Snellen visual acuity was 20/63 in the right eye (RE) and 20/32 in the left eye (LE). On slit lamp examination, he had diffuse intracorneal crystalline deposits in both eyes (Fig. 1A). In vivo confocal microscopy revealed granular and squarish hyperintense deposits in the anterior stromal cornea (Fig. 1B). There were no cells or flare in the anterior chamber. His pupillary reflex was normal. He had no relative afferent pupillary defects. Fundus examination revealed discrete vitreous inflammation with whitish papillary edema and some tiny crystals mostly in his RE. Multicolor (Fig. 2A) and infrared (Fig. 2B) imaging revealed the crystals as tiny bright spots on the papilla and macula of both fundii. Fluorescein angiography showed macular and papillary leakage predominantly in his right eye with a discrete vasculitis (Fig. 3). No choroidal granuloma was observed on indocyanine green angiography. Optical coherence tomography (OCT) B scan showed bilateral macular and papillary edema (Fig. 4A). This edema was whitish on OCT B and C scans with panretinal distribution of hyperreflective spots corresponding

to the crystals detected on fundus examination. These hyper-reflective spots were particularly dense at the level of the inner plexiform/ganglion cell layers (Fig. 4A). Goldmann visual fields revealed an enlarged blind spot in the RE. Magnetic resonance imaging (MRI) did not show any vascular malformation or abnormality of the optic nerve tract.

Laboratory results were indicative of renal dysfunction (creatinine 7 mg/dL, blood urea nitrogen 0.6 g/L, chronic kidney disease – epidemiology collaboration (CKD-EPI) estimated glomerular filtration rate 8 mL/min/1.73 m², glomerular filtration rate measured by (51)Cr-EDTA clearance 18 mL/min/1.73 m²) and nephrotic syndrome (albumin 23.8 g/L, proteinuria 6.02 g/24 h). Urine protein electrophoresis revealed mixed tubular and glomerular proteinuria with 22% of Bence-Jones proteinuria. Elevated fraction excretion of uric acid (25.79%) was the only sign of proximal tubular dysfunction (eg, normal kaliemia, no metabolic acidosis, normal phosphoremia, no glycosuria nor aminoaciduria).

Serum electrophoresis showed monoclonal gammopathy with an IgG kappa monoclonal protein on immunofixation. The level of serum M-protein was 18.9 g/L. Serum-free light chain (sFLC)

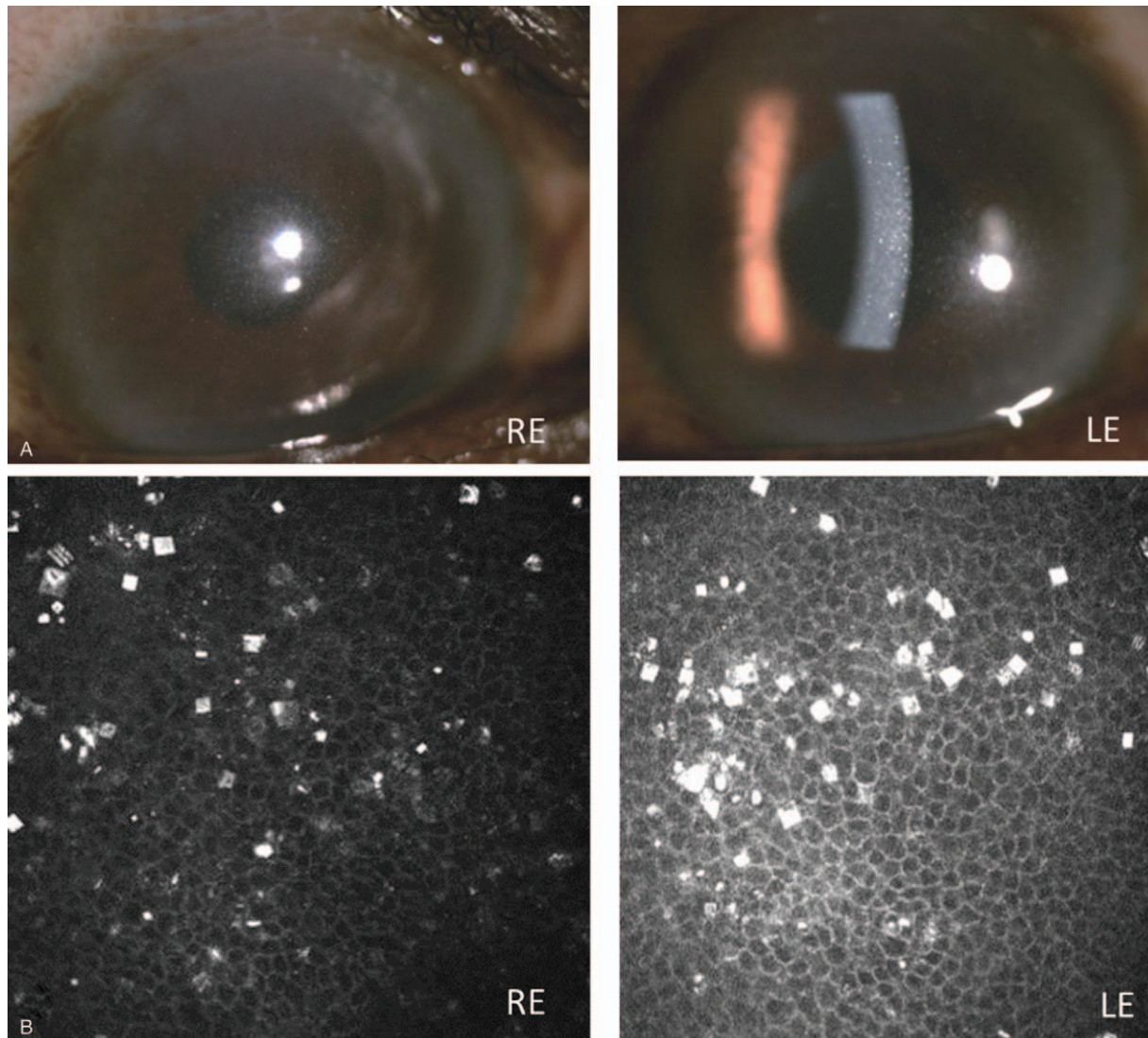


Figure 1. (A) RE and LE (slit lamp examination): diffuse intracorneal crystalline deposits; (B) RE and LE (in vivo confocal microscopy): granular and squarish hyperintense deposits in the anterior stromal cornea. LE=left eye, RE=right eye.

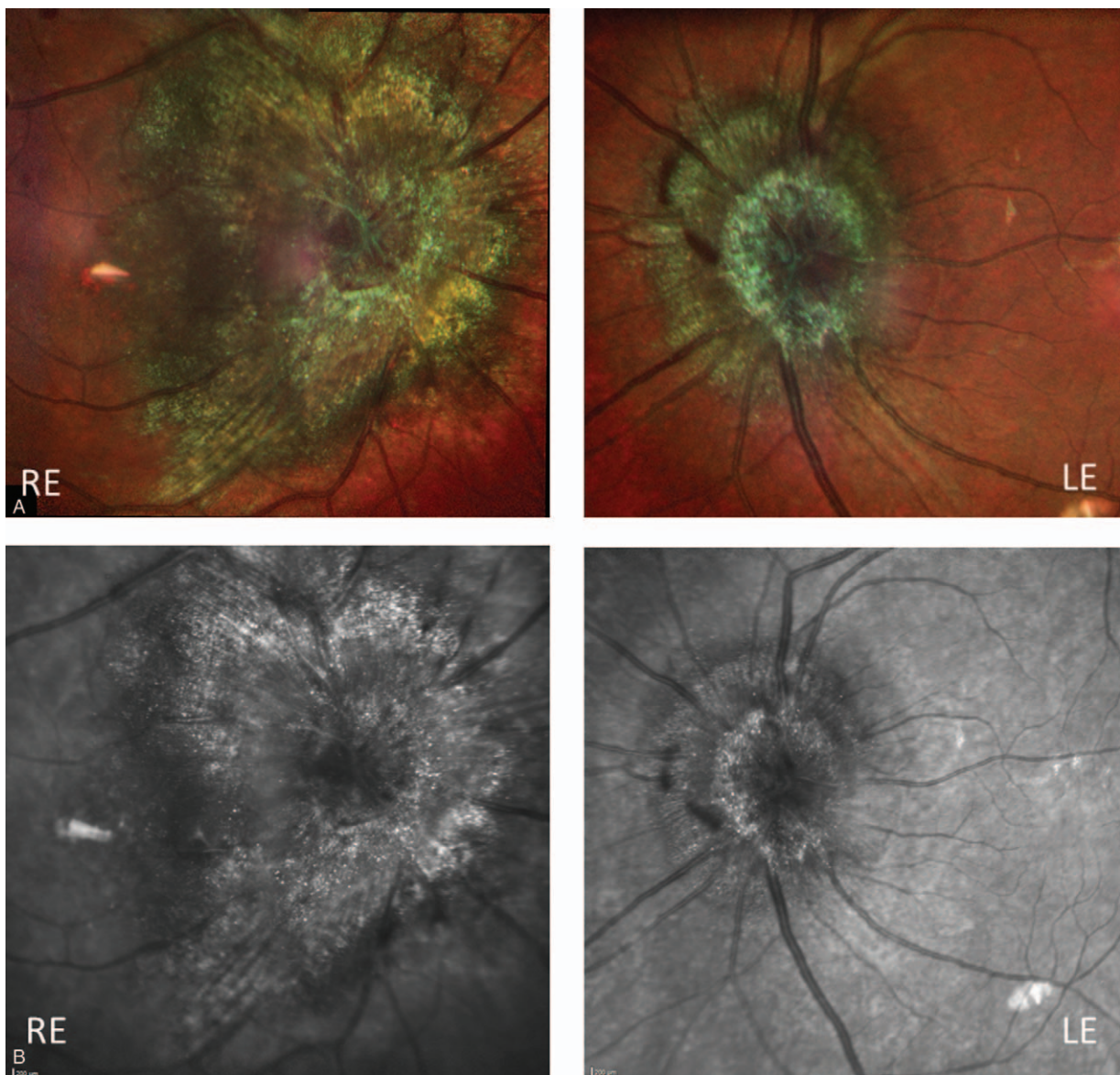


Figure 2. Multicolor (A) and infrared (B) imaging of fundus examination: visualization of the crystalline deposits as tiny bright spots on the papilla and macula of both eyes.

kappa was elevated at 77.4 mg/L and lambda at 24 mg/L with a FLC ratio of 3.23. Other laboratory reports revealed the following: hemoglobin 11.6 g/dL, platelets 183,000/mm³, lymphocytes 1080/mm³, neutrophils 3130/mm³, calcium 2.13 mmol/L, β 2-microglobulin 6.73 mg/L, C-reactive protein 3 mg/L, IgA 0.55 g/L, IgM 0.49 g/L. MRI of the spine was unremarkable.

Bone marrow aspiration showed 8% to 25% of dystrophic plasma cells. Cytogenetic analysis identified t^[11;12] (q13;q32) translocation. Bone marrow biopsy confirmed tumoral infiltration by CD138+ CD20- CD79a- cyclinD1+ plasma cells, and did not show amyloid deposit or crystalline inclusion. Immunophenotyping of peripheral blood lymphocytes also showed a subpopulation of B cells CD19+ CD5+ CD20+ (high) and CD10- with elevated lambda LC expression, counting for 1.3% of total lymphocytes.

A percutaneous ultrasound-guided renal biopsy was performed. Light examination revealed a cortico-medullary

specimen containing eleven glomeruli, of which 2 were globally sclerosed and 2 showed a focal segmental glomerular lesion. Numerous proximal tubular epithelial cells contained intracytoplasmic variably shaped fuchsinophilic crystals (Fig. 5A). The same crystals were also noted in tubular cells shed into tubular lumens and in some interstitial histiocytes, podocytes, and mesangial cells (Fig. 5B). Other proximal tubules described hyaline droplet changes. Near to 50% of cortical area exhibited interstitial fibrosis containing focal nonspecific mononuclear inflammatory cells. These lesions were not associated with cast nephropathy, light chain deposition disease (LCDD), or amyloid deposits. Immunofluorescent study performed on pronase-digested paraffin tissue revealed intense staining for kappa light chains of crystals located within tubular proximal cells, podocytes, mesangial cells, and interstitial histiocytes. Ultrastructural analysis revealed obstruction of proximal tubules by apoptotic epithelial cells, leading to dilatation and breakage of

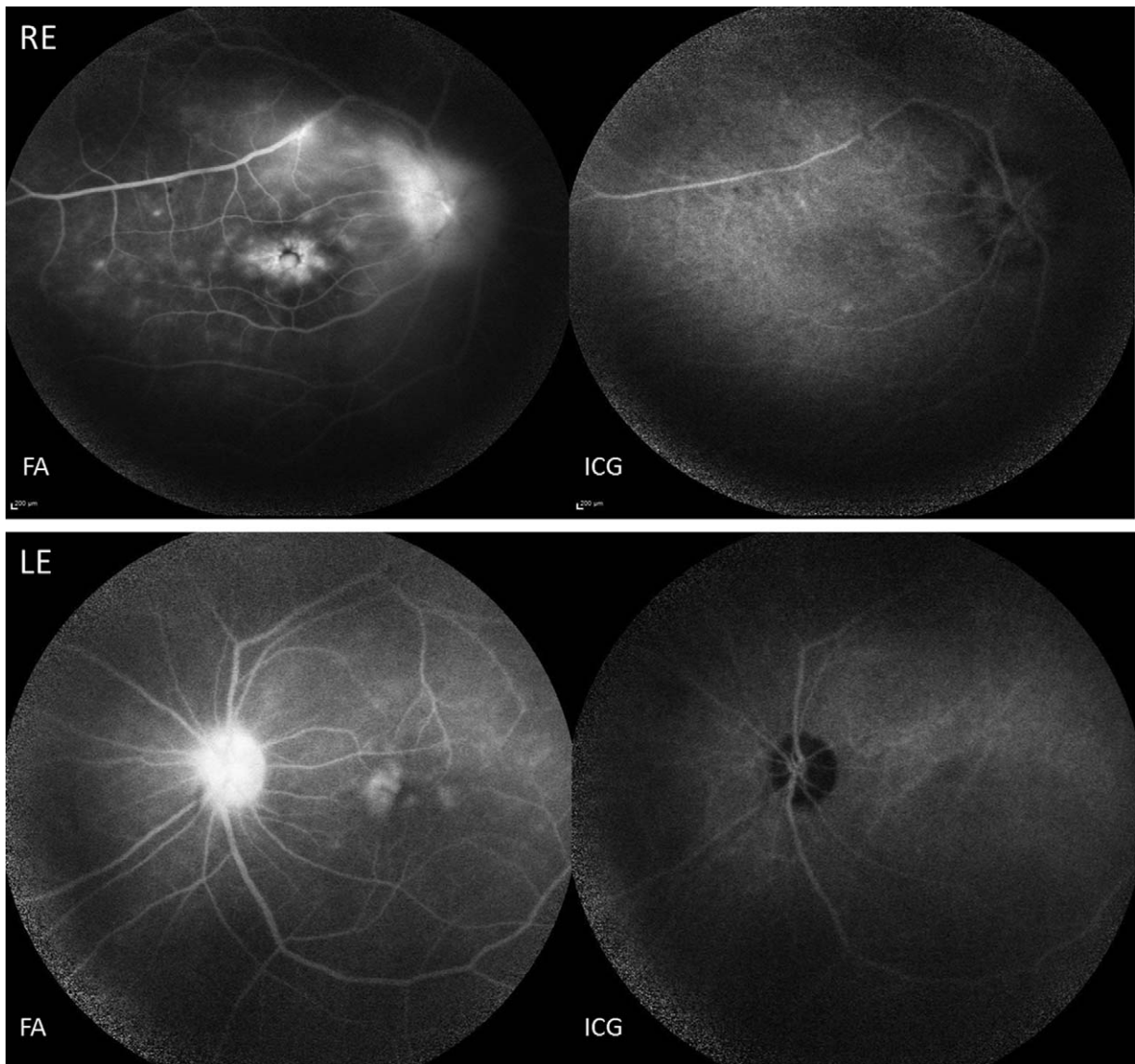


Figure 3. Fluorescein and ICG angiographies: macular and papillary leakage predominantly in the RE, with a discrete vasculitis, but no choroidal granuloma on ICG. RE=right eye.

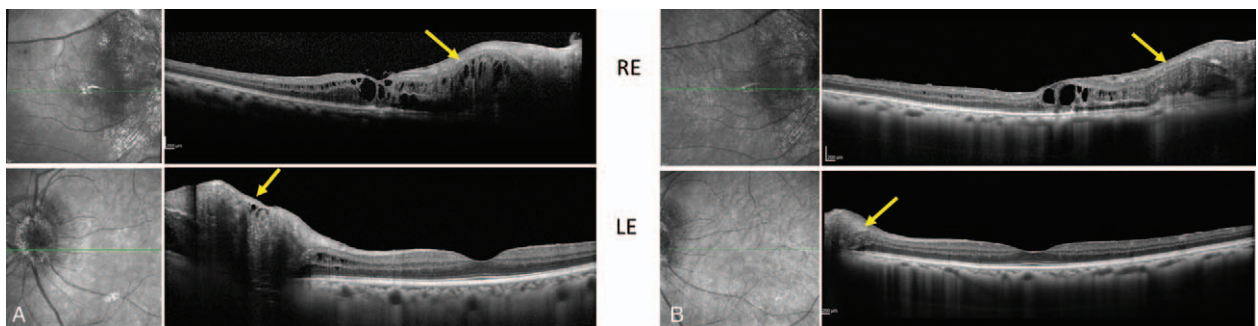


Figure 4. (A) OCT B scan, before treatment: macular and papillary edema in both eyes, hyper-reflective spots particularly dense at the level of the inner plexiform/ganglion cell layers (yellow arrows); (B) OCT B scan, after treatment: reduction of papilledema and macular edema. OCT=optical coherence tomography.

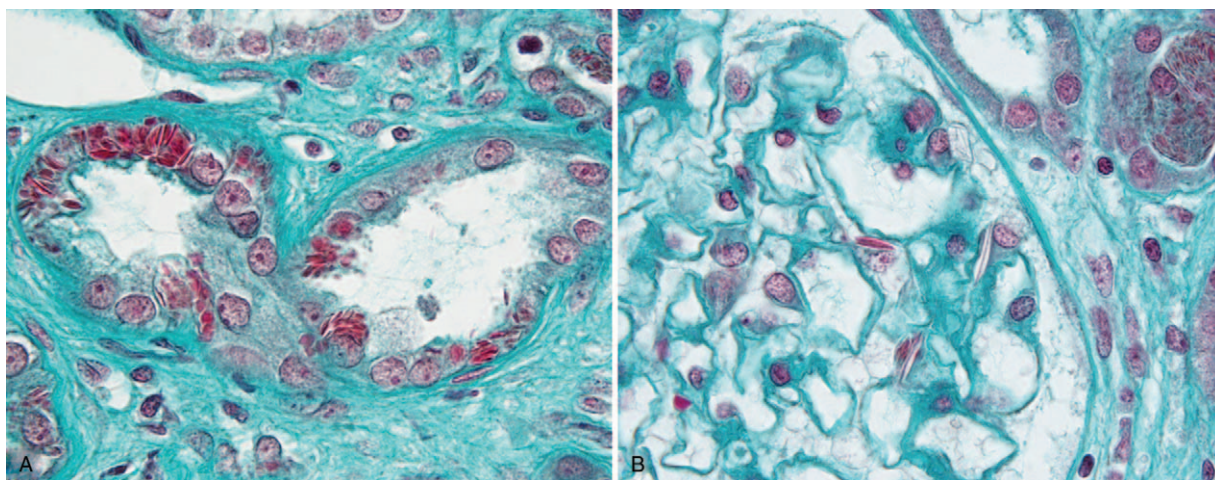


Figure 5. (A) Numerous proximal tubular epithelial cells contained variably shaped intracytoplasmic fuchsinophilic crystals (Masson trichrome, original magnification $\times 1000$). (B) Fuchsinophilic crystals were also noted in the cytoplasm of some podocytes and tubular epithelial cells shedded into tubular lumen (upper right corner) (Masson's trichrome, original magnification $\times 1000$).

the lumen. Interstitial histiocytes with crystalline inclusions were surrounding those sections (Fig. 6). Immunogold staining confirmed kappa LCPT (Fig. 7A and B).

The patient was diagnosed with IgG κ multiple myeloma with crystalline deposition (CSH; combined crystalline podocytopathy and tubulopathy) and was treated immediately with bortezomib, cyclophosphamide, and dexamethasone (VCD). After 3 cycles of VCD, hematologic and ophthalmic status remained stable, but the patient developed end-stage renal failure requiring dialysis. Therefore, a new regimen with bortezomib, lenalidomide, and dexamethasone (VRD) was given. After 5 cycles of VRD, a partial hematologic response was observed (M protein 7.7 g/L; sFLC ratio 2.5). Ophthalmic evaluation revealed a reduction of papilledema and macular edema (Fig. 4B), with stable visual acuity and persistence of corneal and retinal deposits.

3. Discussion

Crystal-storing histiocytosis is a rare disorder that is morphologically characterized by the accumulation of monoclonal

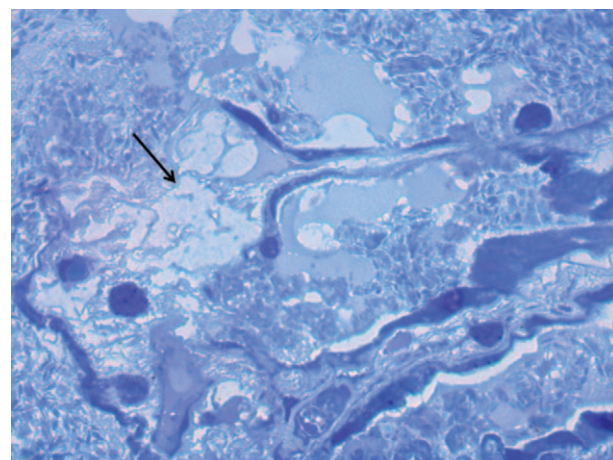


Figure 6. Proximal convoluted tubule with cystic dilatation of the lumen leading to breakage of the tubule. Interstitial histiocytes with crystalline inclusions (arrow). (Toluidine blue-stained 1- μ m thick sections, original magnification $\times 1000$).

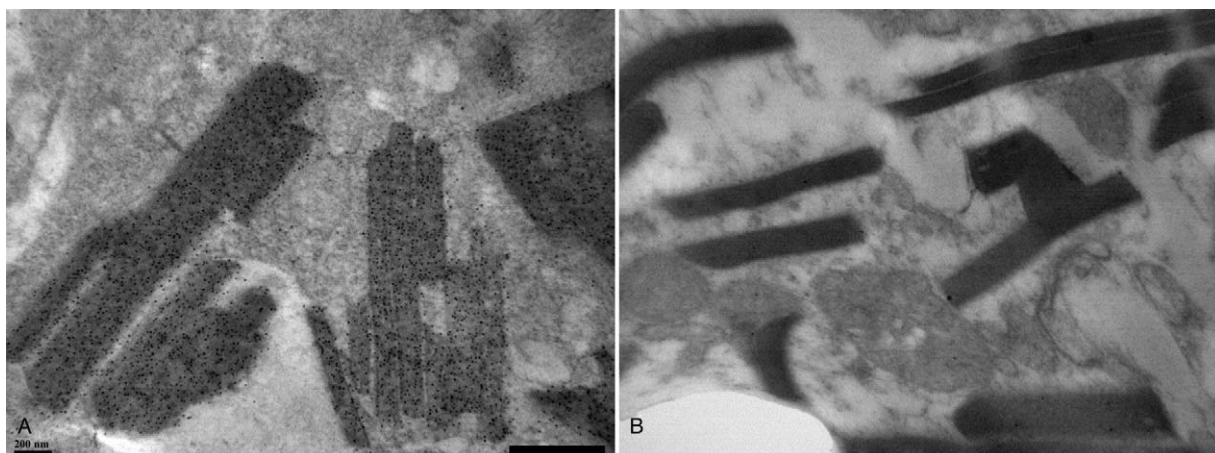


Figure 7. Proximal tubular intra cytoplasmic crystals positive for anti-kappa conjugate (A) and negative for anti-lambda (B) (original magnification $\times 60000$, immunogold staining).

immunoglobulin crystals, predominantly of a kappa light chain type, within lysosomes of macrophages. It is frequently associated with various types of B-cell lymphoproliferative disorders (MM, monoclonal gammopathy of undetermined significance, lymphoplasmatic lymphoma). The pathophysiology of monoclonal gammopathy-related CSH remains unclear, even if it has been hypothesized that mutations of the DNA sequence encoding the variable region of the involved light chain may lead to exposure of hydrophobic regions of the resultant protein, making it resistant to enzymatic degradation by macrophages.^[10] Apart from this, El Hamel et al^[11] compared CSH/Fanconi syndrome (FS) V κ domain 3D structures with the germline-encoded structures and those from patients with myeloma-associated FS revealing distinct hydrophobic residues exposed to the solvent. Thus, different mutations in the V domains of CSH/FS monoclonal κ LCs could explain resistance to degradation after phagocytosis.

Crystal-storing histiocytosis may result in a variety of clinical manifestations depending on the involved organs. Eye/orbit is 1 of the most common sites affected by CSH.^[12] Involvement of the cornea (“crystalline keratopathy”) is well described, and CSH has been also reported to involve the conjunctiva, the orbital fat, and extra-ocular muscles.^[13] Nevertheless, to our knowledge, retinal involvement has not been described yet.

Retinal microglia originates from hematopoietic cells and invades the retina from the retinal margin and the optic disc. Microglia is distributed in the outer plexiform layer, outer nuclear layer, inner plexiform layer, ganglion cell layer, and nerve fiber layer of the primate retina.^[14] In our case, the hyper-reflective crystals, seen on OCT B and C scans, were mostly located at the level of the inner plexiform/ganglion cell layers. The origin of papillary edema is still unclear. Posterior inflammation could cause papillary and macular leakage. Another hypothesis would be that crystals accumulation at the site of the lamina cribrosa may slow the axoplasmic flux.

Intrarenal crystalline deposits of M Ig and/or LC Ig are an important cause of renal dysfunction in patients with MM. The most common form of extracellular crystalline nephropathy is the light-chain cast nephropathy, where binding of freely filtered light chains to the Tamm-Horsfall protein leads to characteristic precipitates of monoclonal light chains within tubular lumen.^[15] Intracellular crystallization occurs less commonly within proximal tubular cells, leading to LCPT, which presents clinically as more and less complete FS.^[4,5,15] Crystallization may occur after endocytosis and proteolysis within the compartment of epithelial cells as there was no cytoplasmic LC inclusion inside plasma cells. Moreover, ultrastructural examination revealed breakage of urinary space surrounded by interstitial histiocytes which pleads for secondary phagocytosis of the crystal, and not primary CSH (Fig. 6). Crystalline inclusions in glomerular cells (podocytes, mesangial cells), which lead to significant glomerular proteinuria, are very rarely reported.^[8] The observed glomerular proteinuria in our patient may be due to the focal segmental glomerulosclerosis (FSGS) seen on renal biopsy and/or the pathogenicity of the kappa LC inclusions in the podocytes. Ultrastructural examination is in favor of crystals coming from the urinary space after backflowing from the tubules because of proximal tubule obstruction by apoptotic epithelial cells (Fig. 6). Other hypothesis is that LC-Ig could be endocytosed by podocytes and crystallise inside their own lysosomes. Podocyte dysfunction could then be caused by accumulation of light chains. All the more so our patient did not receive bisphosphonate or any other drugs causing collapsing glomerulopathy, minimal change disease or FSGS.

In this case, the patient complained of progressive decrease of visual acuity since 2 years, and it can be hypothesized that this reflected the progression of the ophthalmologic CSH. We believe that a prolonged course of a relatively indolent myeloma and a delay in the diagnosis can explain the massive crystalline deposition presented by the patient.

4. Conclusions

This is the first published case report of retinal involvement in CSH. The diagnosis of multiple myeloma, associated with CSH, crystalline LCPT, and Ig LC podocytopathy, was made—thanks to careful ophthalmologic examination before the extraordinary diversity of organ dysfunction due to monoclonal gammopathy was revealed and treated with anti plasma cells chemotherapy.

Acknowledgments

The authors would like to thank Palaniwamy Sunder Raj for the revision of the article for proper English language.

Author contributions

Study concept and design: IB, CT, SH, TS
 Acquisition of data: IB, CT, SH, JV, GT, SK, EG, VV, MMF, TS
 Analysis and interpretation of data: IB, CT, SH, JV, GT, SK, EG, VV, MMF, TS
 Drafting the manuscript: IB, CT, SH, VV, MMF, TS
 Critical revision of the manuscript for important intellectual content: IB, CT, SH, JV, GT, SK, EG, VV, MMF, TS
 Final approval of the version to be published: IB, CT, SH, JV, GT, SK, EG, VV, MMF, TS
 Agreement to be accountable for all aspects of the work in ensuring that questions related to accuracy or integrity of any part of the work are appropriately investigated and resolved: IB, CT, SH, JV, GT, SK, EG, VV, MMF, TS
Conceptualization: Idris Boudhabhay, Chérif Titah, Stéphanie Harel, Jérôme Verine, Thomas Sené.
Data curation: Idris Boudhabhay, Chérif Titah, Alexis Talbot, Stéphanie Harel, Jérôme Verine, Guy Touchard, Sihem Kaaki, Eric Gabison, Vivien Vasseur, Martine Mauguet-Faÿsse, Thomas Sené.
Formal analysis: Idris Boudhabhay, Chérif Titah, Stéphanie Harel, Jérôme Verine, Guy Touchard, Vivien Vasseur, Martine Mauguet-Faÿsse, Thomas Sené.
Investigation: Idris Boudhabhay, Chérif Titah, Alexis Talbot, Stéphanie Harel, Jérôme Verine, Guy Touchard, Sihem Kaaki, Eric Gabison, Vivien Vasseur, Martine Mauguet-Faÿsse, Thomas Sené.
Supervision: Thomas Sené.
Validation: Idris Boudhabhay, Chérif Titah, Alexis Talbot, Stéphanie Harel, Jérôme Verine, Guy Touchard, Sihem Kaaki, Eric Gabison, Vivien Vasseur, Martine Mauguet-Faÿsse, Thomas Sené.
Writing – original draft: Idris Boudhabhay, Chérif Titah, Stéphanie Harel, Vivien Vasseur, Martine Mauguet-Faÿsse, Thomas Sené.
Writing – review & editing: Idris Boudhabhay, Chérif Titah, Alexis Talbot, Stéphanie Harel, Jérôme Verine, Guy Touchard, Sihem Kaaki, Eric Gabison, Vivien Vasseur, Martine Mauguet-Faÿsse, Thomas Sené.
 Thomas Sené orcid: 0000-0002-3162-2537.

References

- [1] Merlini G, Stone MJ. Dangerous small B-cell clones. *Blood* 2006;108:2520–30.
- [2] Leung N, Bridoux F, Hutchison CA, et al. Monoclonal gammopathy of renal significance: when MGUS is no longer undetermined or insignificant. *Blood* 2012;120:4292–5.
- [3] van de Donk NWCJ, Palumbo A, Johnsen HE, et al. The clinical relevance and management of monoclonal gammopathy of undetermined significance and related disorders: recommendations from the European Myeloma Network. *Haematologica* 2014;99:984–96.
- [4] Stokes MB, Valeri AM, Herlitz L, et al. Light chain proximal tubulopathy: clinical and pathologic characteristics in the modern treatment era. *J Am Soc Nephrol* 2016;27:1555–65.
- [5] Vignon M, Javaugue V, Alexander MP, et al. Current anti-myeloma therapies in renal manifestations of monoclonal light chain-associated Fanconi syndrome: a retrospective series of 49 patients. *Leukemia* 2017;31:123–9.
- [6] Kowalewska J, Tomford RC, Alpers CE. Crystals in podocytes: an unusual manifestation of systemic disease. *Am J Kidney Dis* 2003;42:605–11.
- [7] Nasr SH, Preddie DC, Markowitz GS, et al. Multiple myeloma, nephrotic syndrome and crystalloid inclusions in podocytes. *Kidney Int* 2006;69:616–20.
- [8] Tomioka M, Ueki K, Nakahashi H, et al. Widespread crystalline inclusions affecting podocytes, tubular cells and interstitial histiocytes in the myeloma kidney. *Clin Nephrol* 2004;62:229–33.
- [9] Yamamoto T, Hishida A, Honda N, et al. Crystal-storing histiocytosis and crystalline tissue deposition in multiple myeloma. *Arch Pathol Lab Med* 1991;115:351–4.
- [10] Lebeau A, Zeindl-Eberhart E, Müller E-C, et al. Generalized crystal-storing histiocytosis associated with monoclonal gammopathy: molecular analysis of a disorder with rapid clinical course and review of the literature. *Blood* 2002;100:1817–27.
- [11] El Hamel C, Thierry A, Trouillas P, et al. Crystal-storing histiocytosis with renal Fanconi syndrome: pathological and molecular characteristics compared with classical myeloma-associated Fanconi syndrome. *Nephrol Dial Transplant* 2010;25:2982–90.
- [12] Dogan S, Barnes L, Cruz-Vettrano WP. Crystal-storing histiocytosis: report of a case, review of the literature (80 cases) and a proposed classification. *Head Neck Pathol* 2012;6:111–20.
- [13] Balderman SR, Lichtman MA. Unusual manifestations of monoclonal gammopathy: I. Ocular disease. *Rambam Maimonides Med J* 2015;6:
- [14] Chen L, Yang P, Kijlstra A. Distribution, markers, and functions of retinal microglia. *Ocul Immunol Inflamm* 2002;10:27–39.
- [15] Heher EC, Rennke HG, Laubach JP, et al. Kidney disease and multiple myeloma. *Clin J Am Soc Nephrol* 2013;8:2007–17.