



COVID-19 associated rhino-orbito-cerebral mucormycosis, risk factors and outcome predictors; a multicentric study

Mohammad Taher Rajabi · Amirhossein Aghajani · Seyed Mohsen Rafizadeh · Mansooreh Jamshidian Tehrani · Seyedeh Zahra Poursayed Lazarjani · Mohammad Mohsen Keshmirshekan · Abbas Mohammadi · Abbas Akrami · Mohammad Mehdi Parandin · Mohammad Bagher Rajabi · Seyede Simindokht Hosseini · Maryam Akbari

Received: 7 May 2022 / Accepted: 15 September 2022
© The Author(s), under exclusive licence to Springer Nature B.V. 2022

Abstract

Background Since the onset of the Covid-19 pandemic, an increase in mucormycosis cases has been observed in many countries, including Iran. However, the role of covid-19 and associated risk factors have not been thoroughly investigated.

Objective This study is designed to identify epidemiologic characteristics, risk factors, and outcome

predictors of Covid-19-Associated Rhino-Orbito-Cerebral Mucormycosis (C-ROCM).

Methods Data of pathology proven Covid Associated ROCM cases were retrospectively obtained from 7 tertiary care centers throughout Iran from February 20, 2021, to July 22, 2021. Univariate and multivariate analyses were performed using binary logistic regression to assess the effects of various factors on the outcome.

Results A total of 132 patients with C-ROCM were included in the study. The mean age of patients was 61.6 ± 13.9 (60.6% male). In 12 patients (9.1%), both eyes were involved. Diabetes was the most

Supplementary Information The online version contains supplementary material available at <https://doi.org/10.1007/s10792-022-02536-7>.

M. T. Rajabi · A. Aghajani (✉) · S. M. Rafizadeh · M. Jamshidian Tehrani
Farabi Comprehensive Center of Excellence in Ophthalmology, Department of Oculofacial Plastic and Orbital Surgery, Tehran University of Medical Sciences, Tehran, Iran
e-mail: a-aghajani@razi.tums.ac.ir

S. Z. Poursayed Lazarjani
Eye Research Center, Department of Eye, School of Medicine, Amiralmomenin Hospital, Guilan University of Medical Sciences, Rasht, Iran

M. M. Keshmirshekan
Geriatric Ophthalmology Research Center, Shahid Sadoughi University of Medical Science, Yazd, Iran

A. Mohammadi
Department of Ophthalmology, Farabi Comprehensive Center of Excellence in Ophthalmology, Tehran University of Medical Sciences, Tehran, Iran

A. Akrami · M. Akbari
Department of Ophthalmology, Medical Microbiology Research Center, Qazvin University of Medical Sciences, Qazvin, Iran

M. M. Parandin
Department of Ophthalmology, School of Medicine, Kermanshah University of Medical Sciences, Kermanshah, Iran

M. B. Rajabi
Department of Ophthalmology, Imam Khomeini Hospital Complex, Tehran, Iran

S. S. Hosseini
Tarjomani Research Center, Tehran University of Medical Sciences, Tehran, Iran

common comorbidity (94.7%). The mortality rate was 9.1%, higher in males (12.5%) than females (3.8%). Severe vision impairment was seen in 58 patients (43.9%). Main factors that had a negative impact on the outcome in the univariate analysis include older age ($P < 0.001$), higher steroid dosage ($P < 0.001$), higher HbA1c level ($P < 0.001$), Covid-19 severity ($P < 0.001$), and brain involvement ($P < 0.001$). However, in the multivariate analysis, the effects of age ($P = 0.062$), steroid dosage ($P = 0.226$), and Covid-19 intensity ($P = 0.084$) decreased, and the difference was no longer statistically significant. CRAO was a predictor of mortality in the univariate analysis ($P = 0.008$, OR = 4.50), but in the multivariate analysis, this effect decreased and was no longer significant ($P = 0.125$).

Conclusion The risk of C-ROCM and its complications may increase in patients with more severe Covid-19, steroid over-prescription, ICU admission due to Covid-19, and poor glycemic control during and after Covid-19 treatment.

Keywords Co-infection · Covid-19 · Mucormycosis · Sars-CoV-2 · Fungal infection · Rhino-orbito-cerebral · Diabetes · Corticosteroids

Introduction

The Severe acute respiratory syndrome coronavirus 2 (Sars-Cov-2) pandemic is an outbreak disease first identified in December 2019. The severity of the disease ranges from asymptomatic infection to death and may be associated with a wide range of common bacterial and fungal infections or coinfections which are serious challenges that increase morbidity and mortality. [1–3]

Recent case reports indicate an increased prevalence of mucormycosis in severe cases of Covid-19 after recovery. [2, 4, 5]

Mucormycosis is a rare opportunistic infection and is considered one of the catastrophic medical complications in immunocompromised patients. In recent years, a change in the epidemiology of mucormycosis has been observed, with an increase in incidence, new pathogens, and susceptible populations. The increase has been noted worldwide but is very high in the Asian continent. Most patients with mucormycosis have underlying diseases and risk factors [6, 7].

Diabetes mellitus overshadows all other risk factors in Asia. The Rhino-Orbito-Cerebral form of mucormycosis (ROCM) is most commonly seen in patients with diabetes mellitus, whereas pulmonary mucormycosis occurs in patients with hematologic malignancies and transplant recipients. [8]

Continuous reports of Covid-19-associated mucormycosis (CAM) from various countries, including 15 cases from Iran, increased our concerns about CAM. [9–11]

Steroid overtreatment, uncontrolled diabetes, poor oral hygiene, and unsanitary use of oxygen therapy have been suggested as stimulants for developing Covid-19 associated Mucormycosis [12–14]. However, the exact cause of the increased prevalence of Mucormycosis in Covid-19 patients is not thoroughly investigated.

Iran is one of the countries adversely affected by the Covid-19 pandemic. Most studies have comprehensively examined all forms of CAM [rhino-orbital, rhino-orbito-cerebral, pulmonary, renal, other] and even included cases of mucormycosis unrelated to Covid-19 (non-CAM) [1, 15]. Here, we conducted a nationwide multicenter study to evaluate the epidemiology and outcomes of Covid-19-Associated Rhino-Orbito-Cerebral Mucormycosis (C-ROCM) in Iran. This study aimed to investigate and identify risk factors, symptoms, clinical forms, and prognosis of C-ROCM.

Methods

We conducted a retrospective observational study in 7 tertiary care centers throughout Iran. Data of all confirmed mucormycosis cases among patients with Covid-19 were collected from February 2021 to December 2021. Approval for the study was obtained from the ethical committee of the Tehran University of Medical Sciences, complying with the Helsinki Declaration. All patients received a thorough explanation of the study design and aim, and written informed consent was obtained.

Study subjects and definitions

We defined a *case* of proven rhino-orbito-cerebral mucormycosis (ROCM) as compatible clinical manifestation, imaging findings, and demonstration

of fungi in the tissue obtained from an endoscopic nasal biopsy of a patient by either direct microscopic visualization of broad ribbon-like aseptate hyphae or isolation of Mucorales (Fig. 1) and positive mucormycosis PCR result.

The Covid-19 diagnosis was based on the positive result of reverse transcription polymerase chain reaction assay (RT-PCR) on upper respiratory mucosal specimens. C-ROCM was defined as the occurrence of proven rhino-orbto-cerebral mucormycosis in Covid-19 recovered patients.

We included all proven ROCM cases who had recently been treated for RT-PCR positive covid-19 disease. Patients with non-Mucorales zygomycosis, negative RT-PCR for Covid-19 or negative pathology or RT-PCR test for mucormycosis were excluded from the study.

In order to categorize the severity of the ROCM, the proposed staging system by Hoavar SG. was implemented retrospectively. [16]

Visual impairment was defined according to the ICD-11 classification [17]. The visual acuity outcomes of bilateral cases were analyzed based on the worse eye. The severity of the Covid-19 disease was categorized based on the worst chest CT score during the active phase of the Covid-19 disease [18]. Total steroid dosage received by the patients was converted to prednisone potency to facilitate comparisons. *Poor outcome* was defined as severe vision impairment, facial disfigurement due to exenteration or mortality, based on the last examination findings at least four weeks after discharge.

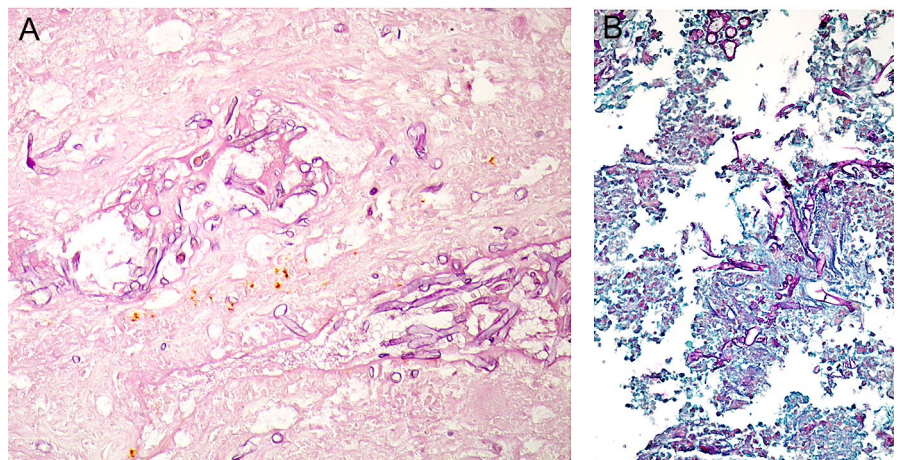
Study procedure

We developed a standard form that we circulated to the centers for data collection. The following information was extracted from the patients' records: demographic characteristics; Covid vaccination status; underlying diseases; Covid-19 severity; CNS involvement; Paranasal Sinus involvement (ethmoid, frontal, maxillary, sphenoid); duration of hospitalization due to Covid-19; the interval between Covid-19 diagnosis and mucormycosis hospitalization; treatment details including immunosuppressive treatments, surgical procedures [endoscopic debridement, retrobulbar injection of amphotericin B, exenteration]; hemoglobin A1c, blood sugar level and staging of ROCM at the time of admission; presenting symptoms; visual acuity; findings of the last follow up visit; and significant ocular findings including central retinal artery occlusion (CRAO), branch retinal artery occlusion (BRAO), and endophthalmitis.

Treatment details

All patients received treatment for Covid-19 according to protocol at the respective institutions. To treat mucormycosis, patients received liposomal amphotericin B (AmB) (5 mg/kg 1×/d for six weeks). In instances of liposomal AmB shortage, patients received Deoxycholate AmB or Oral Posaconazole (IV: 300 mg BD on the first day, then 300 mg OD). Antifungal medications were prescribed for variable durations depending on the site of mucormycosis, radiologic findings, and clinical response. Patients

Fig. 1 Fibrofatty tissue with ischemic necrosis containing broad, non-septate hyphae (the fungal forms of mucormycosis) **A**, H&E staining **B**, PAS staining



with intracranial extension received higher doses of AmB for extended periods. All patients underwent MRI evaluation at least every two weeks and whenever the patient's symptoms worsened. Nasal endoscopy and complete endoscopic sinus debridement of necrotic tissue were repeatedly performed based on clinical and imaging findings until hemorrhagic tissues were reached. In the presence of any orbital involvement in imaging along with corresponding signs and symptoms (decreased vision or blindness, limited eye movements, and loss of forehead and cheek sensation), patients received transcutaneous retrobulbar Amphotericin (TRAMB) injection (1 ml of 3.5 mg/ml). All patients were closely monitored for blood sugar control. Patients underwent sequential nasal endoscopy and debridement, retrobulbar injection of amphotericin, or exenteration as needed. For stage 1 and 2 diseases, functional sinus endoscopy surgery with paranasal sinus debridement was performed. In case of maxillary involvement, medial or total maxillectomy with or without ethmoidectomy, frontal exploration, Sphenoidotomy, septectomy, and turbinectomy were performed. For stage 3 disease (orbital involvement), endoscopic debridement was performed along with an injection of retrobulbar amphotericin. In case of complete orbital necrosis coupled with total visual loss, orbital exenteration was performed. A neurosurgeon participated in patient management for stage 4 disease with intracranial involvement. In summary, all patients underwent appropriate endoscopic debridement. The criteria for discharge were as follows: improved or stable clinical condition, no signs of disease activity on two consecutive MRIs, and good control of blood sugar (BS < 250) in diabetic patients.

Statistical analysis

Mean, standard deviation, range, frequency, and percentage were used to represent the data. Simple multinomial logistic regression was used to evaluate the effects of the different variables on the outcome (severe vision impairment, facial disfigurement, and mortality). Due to the limited sample size, multiple multinomial logistic regression could not be performed for the outcome. Instead, the outcome was deoptimized for poor outcome, and then the effects of various factors on the poor outcome were assessed using binary logistic regression. Potential risk factors

(variables with a *P*-value < 0.1) were included in the multiple logistic regression to assess the simultaneous effects of these factors. The stepwise variable selection method was used to identify the most parsimonious model in the final stage. All statistical analyses were performed using SPSS (IBM Corp. Released 2017. IBM SPSS Statistics for Windows, Version 25.0. Armonk, NY: IBM Corp.). A *P*-value of less than 0.05 was considered statistically significant.

Results

A total of 284 patients were assessed for eligibility, and 152 cases were excluded from the study. Ninety-six of them did not have a positive Covid-19 RT-PCR test within two months before the diagnosis of ROCM; the histopathological results of 43 cases were negative for Mucorales, and 13 patients refused consent. A total of 132 patients with C-ROCM were included in the study. The mean age of patients was 61.6 ± 13.9 (60.6% male).

Of 132 patients, 112 (84.8%) had a history of hospitalization for Covid-19 treatment, 20 (15.1%) were treated in outpatient settings, and all were referred after the onset of C-ROCM symptoms. Forty-two patients (31.8%) had been admitted to the ICU due to Covid-19, and 122 patients (92.4%) were treated with corticosteroids.

Decreased vision, facial pain, and paresthesia were the most common early symptoms reported by the patients. Seventy-three patients (55.3%) had reduced vision at the time of admission due to mucormycosis, of which 11 (8.3%) had mild vision impairment (20/20 to 20/70), 46 (34.8%) had moderate vision impairment (20/70 to 20/200) and 16 (12.1%) had severe vision impairment (worse than 20/200).

A total of 19 patients (14.3%) had received the Covid-19 vaccine, of which 7 patients (5.3%) had received two doses, and 12 patients (9.1%) had received only one dose.

During hospitalization, 37 patients (28%) developed CRAO, and 19 patients (14.4%) developed BRAO. Orbital involvement without CNS involvement was observed in 81 patients (61.3%), and simultaneous orbital and brain involvement was observed in 33 patients (25%). Eighteen patients (13.6%) did not have orbital or brain involvement.

Steroids that had been prescribed in the treatment of Covid-19 disease were as follows: Intravenous methylprednisolone in 58 patients (43.9%), intravenous dexamethasone in 47 patients (35.6%), oral prednisolone in 3 patients (2.3%), intravenous methylprednisolone together with intravenous dexamethasone in 8 patients (6.1%), intravenous methylprednisolone together with oral prednisolone in 4 patients (3%), and intravenous dexamethasone together with oral prednisolone in 2 patients (1.5%).

Diabetes was one of the most common comorbidities. History of diabetes was present in 68 patients (51.5%), and hyperglycemia was diagnosed in 57 patients (43.2%) with unknown diabetic status prior to admission (defined as new diabetes). A history of diabetes or new diabetes *per se* had no significant relationship with the outcome (P -value > 0.9). The mean HbA1c in patients with a history of diabetes was 10.156, higher than its incidence in new diabetes (9.575). The mean blood sugar level was 323.8 in patients with a history of diabetes and 449.5 in patients with new diabetes. The average dose of steroids used in new diabetes patients was 1560 mg (the equivalent of prednisone), significantly higher than patients with a history of diabetes or non-diabetics (1091 mg). The prevalence of mortality was the same in both groups (8.8%). Severe vision impairment (visual acuity worse than 6/60) was slightly more prevalent in the group with a history of diabetes (47.1%) than in new diabetes (43.9%), though it was not statistically significant. Preliminary information regarding patients' demographics and Covid-19 treatment details are presented in Table 1.

The majority of patients (91.6%) were treated with liposomal AmB. Three patients (2.2%) were treated with AmB-deoxycholate, and eight (6%) received only posaconazole. A total of 86 patients (65.1%) received retrobulbar amphotericin injection, of which five (3.7%) were eventually exenterated. Seventeen cases (12.8%) underwent exenteration without a history of retrobulbar amphotericin injection. In total, 22 eyes (16.6%) underwent exenteration with no cases of Bilateral exenteration. Information regarding procedures due to C-ROCM is summarized in Table 2.

During the follow-up period, there were 12 cases of mortality (9.1%), ten male patients and two female patients (all deaths occurred during hospitalization). The mortality rate was 12.5% in males and 3.8% in females.

Covid-19 severity was significantly associated with the outcome. Mortality and severe vision impairment also increased with the increasing severity of the Covid-19 (P -value < 0.0001).

Forty-two patients (31.8%) had a history of ICU admission due to Covid-19, which significantly worsened the C-ROCM outcome. As the time interval between the onset of mucormycosis symptoms and the initiation of treatment increased, complications and mortality due to mucormycosis increased, although it was not statistically significant. There was no significant correlation between Covid-19 vaccination and medications used in C-ROCM treatment and outcome.

The ethmoid or maxillary sinus involvement was not significantly related to the poor outcome ($P = 0.103$, $P = 0.764$, respectively). On the other hand, involvement of the sphenoid sinus was significantly associated with the poor outcome ($P < 0.001$). Sphenoid sinus was notably more involved in patients with severe vision impairment (49.4%). In all cases in which mortality occurred, the sphenoid sinus was involved. Frontal sinus involvement was found in 36 patients (27.3%) and was significantly associated with poor outcomes. MRI findings of paranasal sinuses involvement are summarized in Table 3.

C-ROCM staging at the time of admission had a significant effect on the outcome:

One patient (0.7%) was in stage 1, where vision was preserved (visual acuity better than 6/60).

Twenty-one patients (15.9%) were in stage 2, and none developed severe visual impairment (visual acuity worse than 6/60).

Eighty-four patients (63.6%) were in stage 3, in which there were 3 cases of mortality (3.5%) and 42 cases (50%) of severe vision impairment.

Twenty-six patients (19.6%) were in stage 4, in which 9 patients (34.6%) died, and 16 patients (61.5%) had severe vision impairment.

The outcome of C-ROCM was significantly associated with brain involvement ($P < 0.001$). Thirty-three patients (25%) had simultaneous orbital and brain involvement, of whom 11 (33.3%) died. None of the patients who did not have orbital involvement died (Figs. 2 and 3).

CRAO was the most common significant intraocular pathologic finding, detected in 37 patients (28%). The mortality rate was 18.9% in these patients compared to 5.3% in patients without

Table 1 Demographics and Characteristics of patients

Parameter		
Age (years)	Mean \pm SD	61.6 \pm 13.9
	Range	23 to 86
Steroid dosage (mg of prednisone)	Mean \pm SD	1290 \pm 735
	Range	0 to 3000
HbA1C level	Mean \pm SD	9.8 \pm 1
	Range	6.8 to 12.1
Blood sugar level	Mean \pm SD	372 \pm 114
	Range	156 to 680
Duration of Covid-19 hospitalization (days)	Mean \pm SD	8.8 \pm 5.1
	Range	0 to 28
Interval between covid diagnosis and C-ROCM admission (days)	Mean \pm SD	16.2 \pm 3.8
	Range	7 to 30
Worse eye VA at admission (logmar)	Mean \pm SD	1.92 \pm 1.11
	Range	0.01 to 3
Symptoms duration prior to treatment (days)	Mean \pm SD	3.9 \pm 2.1
	Range	1 to 12
Mucor hospitalization (days)	Mean \pm SD	36.3 \pm 13.7
	Range	12 to 120
Eye	OD	65 (49.2%)
	OS	55 (41.7%)
	OU	12 (9.1%)
Sex	M	80 (60.6%)
	F	52 (39.4%)
Diabetes Meletus	No Diabetes	7 (5.3%)
	Newly diagnosed DM	57 (43.2%)
	History of DM	68 (51.5%)
Renal failure	Yes	17 (12.9%)
	No	115 (87.1%)
HTN	Yes	40 (30.3%)
	No	92 (69.7%)
Covid severity	Mild	5 (3.8%)
	Moderate	42 (31.8%)
	Severe	85 (64.4%)
ICU admission due to Covid-19	No	90 (68.2%)
	Yes	42 (31.8%)
Covid vaccination status	No	113 (85.6%)
	1 dose	12 (9.1%)
	2 doses	7 (5.3%)

CRAO. Severe vision impairment (59.5%) and facial disfigurement (18.9%) were also significantly higher in these patients than in the group without CRAO. BRAO was found in 19 patients (14.4%), which was not significantly associated with outcome or mortality alone ($P = 0.101$).

There was no clear association between the presenting symptoms of mucormycosis at the time of admission and the outcome.

Table 2 summary of surgical procedures in C-ROCM cases by outcome

Procedure*	n (%)	Severe vision impairment	Facial disfigurement	Mortality
Endoscopic debridement (ED)	29 (22.0%)	0 (0.0%)	0 (0.0%)	3 (10.3%)
ED+ Retrobulbar AmB	81 (61.4%)	43 (53.1%)	0 (0.0%)	2 (2.5%)
ED+ Exenteration	17 (12.9%)	0 (0.0%)	12 (70.6%)	5 (29.4%)
ED+ Retrobulbar AmB + Exenteration	5 (3.8%)	0 (0.0%)	3 (60.0%)	2 (40.0%)

Table 3 Prevalence of involved paranasal sinuses by outcome

Paranasal sinus	n (%)	Severe vision impairment	Facial disfigurement	Mortality
Ethmoid	128 (97.0%)	43 (33.6%)	15 (11.7%)	12 (9.4%)
Maxilla	110 (83.3%)	30 (27.3%)	14 (12.7%)	11 (10.0%)
Sphenoid	85 (64.4%)	42 (49.4%)	15 (17.6%)	12 (14.1%)
Frontal	36 (27.3%)	14 (38.9%)	8 (22.2%)	5 (13.9%)

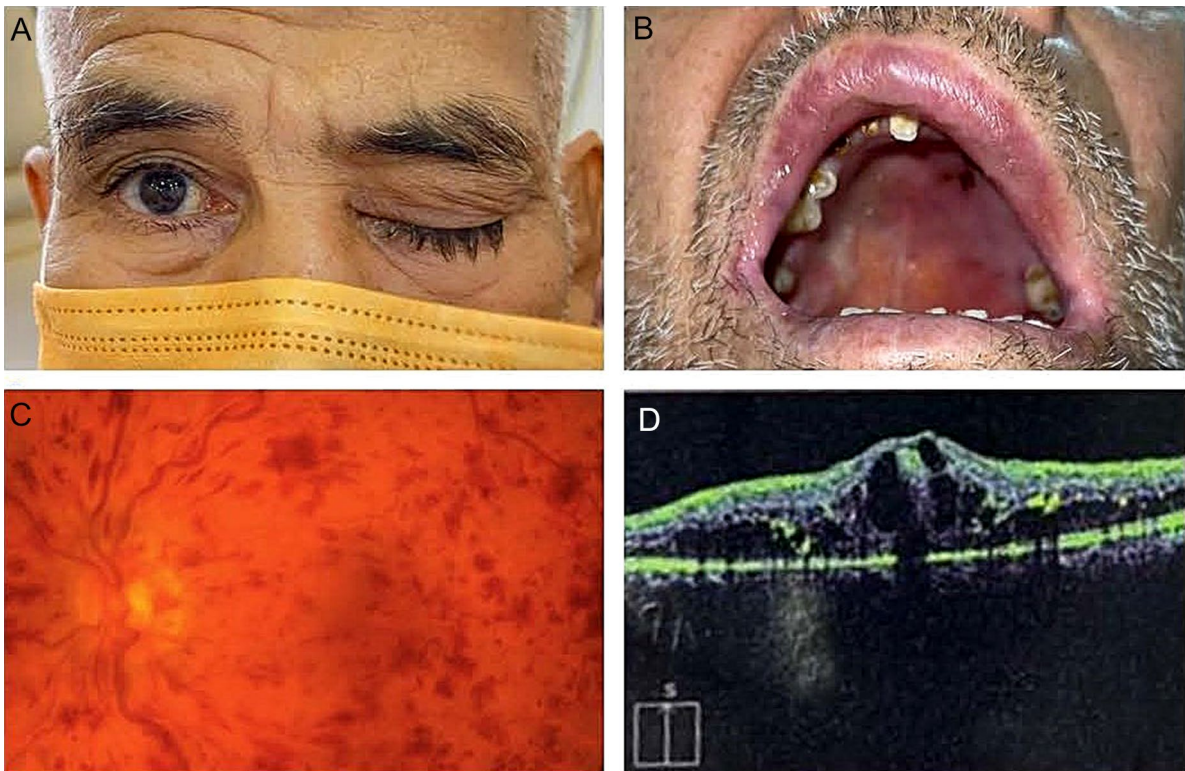


Fig. 2 A 63-year-old Covid-19 recovered patient presented with left complete ptosis, ophthalmoplegia and decreased vision. **A**, A Standard photograph showing left complete ptosis **B**, Black necrotic tissue is noted on hard palate **C**, Funduscopy

revealed central retinal vein occlusion (CRVO) **D**, Macular OCT of the same patient showing diffuse macular edema associated with CRVO

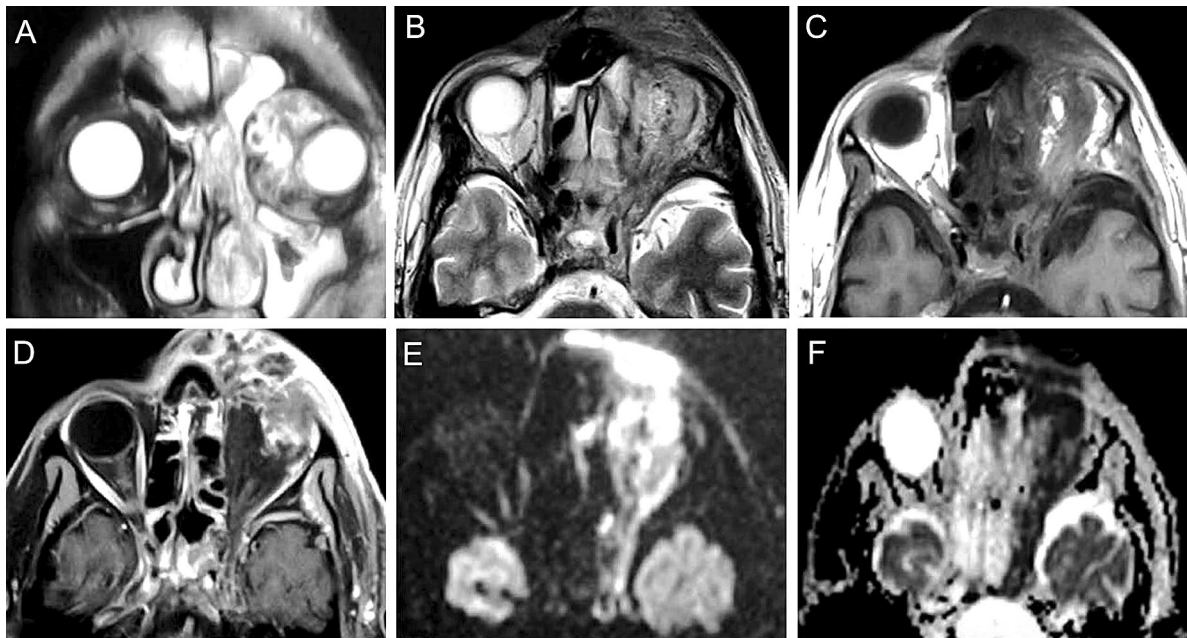


Fig. 3 Orbital MRI of a 58-year-old male patient with left Covid-associated rhino-orbito-cerebral mucormycosis. **A**, marked mucosal thickening of the left maxillary and frontal sinus is noted in Coronal T2-weighted image **B**, Axial T2-weighted image shows hypointense fungal elements along with intraconal fat obliteration in the left orbit **C**, Axial T1-weighted image, involvement of the left orbital apex with

extension to the left cavernous sinus **D**, Fat-suppressed axial T1-weighted post-contrast image shows heterogenous enhancement of left orbital components **E**, **F**, diffusion restriction in the left orbit on DWI/ADC images with extension through the orbital apex to the left cavernous sinus, compatible with left cavernous sinus obliteration

Table 4 Univariate and multivariable effect of possible risk factors on poor outcome using Binary logistic regression

		Univariate				Multivariable			
		OR	95% CI		P	AOR	95% CI		P
			Lower	Upper			Lower	Upper	
Age*	10 yrs	1.63	1.23	2.16	0.001	1.52	0.98	2.35	0.062
Steroid dosage	100 mg/dl	1.06	1.01	1.12	0.015	1.06	0.97	1.15	0.226
HbA1C*		7.74	3.64	16.47	<0.001	13.47	4.09	44.32	<0.001
Sex*	M	1.00				1.00			
	F	1.82	0.90	3.70	0.096	4.53	1.25	16.42	0.022
Covid severity*	Mild + Moderate	1.00				1.00			
	Severe	7.42	3.28	16.83	<0.001	3.60	0.84	15.34	0.084
CNS involvement*	No	1.00				1.00			
	Yes	50.05	6.57	381.29	<0.001	73.80	4.18	1303.38	0.003

OR: Odds Ratio; AOR: Adjusted Odds Ratio

*Chosen variable by Stepwise model selection method

Table 3 demonstrates the simple and adjusted effect of different factors on poor outcomes (severe vision impairment, disfigurement, and mortality).

This table contains the univariate (unadjusted) and multivariable (adjusted) effect of factors on poor outcomes. Also, the final model chosen based on stepwise model selection has been demonstrated in this table

Multivariate analysis of poor outcome predictors (Table 4)

Mortality, facial disfigurement, and severe vision impairment were defined as *poor outcomes*. The relationship between age, sex, steroid dosage, Covid-19 severity, HbA1c, orbital, and brain involvement was investigated using binary logistic regression as univariate and multivariate.

Main factors that had a negative impact on the outcome in the univariate analysis include older age ($P < 0.001$), higher steroid dosage ($P < 0.001$), higher HbA1c level ($P < 0.001$), Covid-19 severity ($P < 0.001$), and brain involvement ($P < 0.001$). However, in the multivariate analysis, the effects of age ($P = 0.062$), steroid dosage ($P = 0.226$), and Covid-19 intensity ($P = 0.084$) decreased, and the difference was no longer statistically significant, while brain involvement ($P = 0.003$) and female sex ($P = 0.022$) significantly worsened the outcome.

Multivariate analysis of mortality predictors (Table 5)

In the univariate analysis, CRAO was a predictor of mortality ($P = 0.008$, OR = 4.50), but in multivariate analysis, this effect decreased and was no longer significant ($P = 0.125$). In univariate analysis, severe vision impairment unexpectedly had a negative

correlation with mortality ($P = 0.043$, OR = 0.12), but in multivariate analysis, this effect was reversed and significantly predicted an increase in mortality ($P = 0.029$, OR = 13.76).

Brain involvement in both univariate and multivariate analysis was a strong predictor of mortality ($P < 0.001$ and $P = 0.004$, respectively). Retrobulbar injection of amphotericin was associated with reduced mortality in univariate ($P = 0.079$) and multivariate analysis ($P = 0.168$), but this correlation was not statistically significant. In cases of exenteration in univariate analysis, the prevalence of mortality was higher, although it was not statistically significant ($P = 0.073$), and this effect was further reduced in multivariate analysis ($P = 0.692$).

Discussion

Throughout the Covid-19 pandemic, an increased incidence of Covid-19-associated mucormycosis (CAM), especially among patients with uncontrolled hyperglycemia, has been observed in many countries [19, 20]. The soaring second wave of Covid-19 infection was found to be associated with an exponential increase in the incidence of CAM [21]. The prevalence of rhino-orbito-cerebral mucormycosis was relatively rare in the pre-pandemic world. However,

Table 5 Univariate and multivariable effects of possible risk factors on Mortality using Binary logistic regression

		Univariate			<i>P</i>	Multivariable			<i>P</i>
		OR	95% CI			OR	95% CI		
			Lower	Upper			Lower	Upper	
CRAO	–	1.00			1.00				
	+	4.50	1.48	13.69	0.008	0.32	0.07	1.38	0.125
Severe vision impairment [§]	–	1.00			1.00				
	+	0.12	0.02	0.94	0.043	13.76	1.30	145.79	0.029
Brain involvement [§]	No	1.00			1.00				
	Yes	28.95	6.09	137.63	<0.001	16.52	2.47	110.38	0.004
Surgery [§]	None [¥]	1.00			1.00				
	TRAMB [¥]	0.25	0.05	1.18	0.079	0.25	0.04	1.79	0.168
	Exenteration [¥]	3.47	0.89	13.48	0.073	1.48	0.21	10.19	0.692

OR: Odds Ratio; AOR: Adjusted Odds Ratio, TRAMB: Retrobulbar Amphotericin B injection

[§] Chosen variable by Stepwise model selection method

[¥] Endoscopic debridement were performed for all cases

This table contains the univariate (unadjusted) and multivariable (adjusted) effect of factors on mortality. Also, the final model chosen based on stepwise model selection has been demonstrated in this table

it is known to have high rates of morbidity and mortality [6, 7]. Only 2–6% of invasive fungal infections were attributed to Mucorales order in pre-pandemic times. The cumulative incidence of mucormycosis before the pandemic was only 0.07% among solid organ transplant recipients at the end of the first year [22]. Prakash and Chakrabarti identified diabetes as a predisposing factor in 17–88% of CAM patients. [7]

Covid-19 and mucormycosis share common risk factors, such as DM, which can play an independent role in the mortality rate. In addition, while steroids may be a necessary Covid-19 treatment and help reduce mortality, the subsequent deterioration in glycemic control and their immunosuppressive effects could provide an opportunity for Mucorales to invade. [23, 24]

In our study, the total steroid dosage was one of the risk factors investigated, and in the initial analysis, it was found that the outcome worsened significantly with increased dosage, but in the multivariate analysis, this relationship was not observed. In more severe cases, a higher dose of steroids had been used, directly related to uncontrolled diabetes. These associations of steroids appear to be more influential than their immunosuppressive function.

Older age led to worsening outcomes, but this difference was not significant in multivariate analysis. It seems that age alone was not the primary cause of worsening outcomes and may have influenced other risk factors. The results of our multinomial logistic regression analysis showed that for every ten years of aging, the rate of severe vision impairment was 1.44 times, facial disfigurement was 2.14 times, and mortality was 2.06 times.

Our study echoed the results of previous investigations showing a higher prevalence of mucormycosis and mortality rates in male patients. Contrary to expectations, severe vision impairment was more common in women. These results were not statistically significant in the univariate analysis, whereas in the multivariate analysis, a significant difference was observed with a *P*-value of 0.025. Further investigation is needed to elucidate these findings.

A systematic review of 101 mucormycosis cases associated with Covid-19 by Singh et al. showed that more than 80% of cases had hyperglycemia before or after the onset of mucormycosis as a risk factor [15]. In our study, uncontrolled blood sugar level was identified as a significant risk factor for C-ROCM.

Accurate determination of the effect of diabetes on mortality in patients with CAM requires further evaluation in a more comprehensive study. The most crucial factor that uniformly predicted worse outcomes in the univariate and multivariate analyses was the HbA1c level. Given the prominent role that uncontrolled diabetes plays in the development of mucormycosis, this association seems quite plausible.

Another issue is the possible role of Covid-19 in worsening blood sugar control in DM patients or the development of new diabetes. According to Müller et al., The human pancreas and beta cells could be a potential target for the SARS-CoV-2 virus [25, 26]. Covid-19 infection alone may also lead to insulin resistance, and these metabolic changes may predispose Covid-19 patients who did not have DM or had well-controlled DM to the development of mucormycosis. [27]

In our study, the outcome was significantly worsened with increased Covid-19 severity, and this association was also observed in the multivariate analysis. Covid-19 itself may increase the risk of mucormycosis, which requires further investigation.

A mortality rate of 9.1% was observed in our study after C-ROCM, lower than other similar studies. The lower mortality rate in our study may be due to the implementation of C-ROCM management protocol in terms of timely and effective surgical debridement with appropriate antifungal therapy, proper in-hospital glycemic control, and multidisciplinary medical care.

One of the most critical decisions in C-ROCM cases is whether or not to perform exenteration. Various indications for exenteration have been proposed in previous studies; in some studies, exenteration was associated with increased survival [23, 28–31]. Nevertheless, performing exenteration in C-ROCM cases with orbital involvement remains controversial, and a clear indication has not yet been established. In our study, although the prevalence of orbital involvement was high (86%), the rate of exenteration was relatively low (16.6%), yet the mortality rate did not increase compared to previous studies. The reason that fewer exenterations were performed is that in the majority of C-ROCM cases, it was observed that after initial control with endoscopic debridement and glycemic control, disease progression was halted, and serial endoscopies and MRIs showed no evidence of disease progression.

Therefore, a more conservative approach was taken to treat C-ROCM cases than the usual ROCM.

In this study, it was found that in most cases, when risk factors for the disease, including high blood sugar, were controlled, progression of C-ROCM was halted, and more aggressive treatment measures were not required. There is a possibility that the prognosis of C-ROCM is better than typical cases of ROCM, but clarification of this matter and the establishment of an appropriate treatment guideline requires further controlled studies.

Strength

Our study was unique in some aspects while also carrying limitations. All C-ROCM cases in this study were proven ROCM in RT-PCR positive Covid-19 patients. As we know, this is the most comprehensive study on ROCM in COVID-19 patients in Iran to date. In the current study, various independent factors that determine the clinical outcome in C-ROCM were analyzed using multivariate logistic regression analysis. Thus, we can propose each of these factors as a significant independent factor that is not influenced by the others, which is a major strength of this study.

Limitations

For comparison of the clinical outcome, it would be ideal to include a control group. However, due to the heterogeneity of the underlying conditions and limited cases of non-Covid-19 associated mucormycosis, it was not practical to include a control group in this study.

In our study, the mortality rate was lower than in most reports, which complicated the statistical analysis of mortality predictors. Moreover, since this data were retrospectively collected, and most cases were co-managed by different departments, several clinical parameters that may be associated with increased risk of developing mucormycosis or worse outcomes, including consecutive blood sugar levels during corticosteroid use, the exact timing of procedures, ferritin, and zinc levels were not available at the time of collection.

Conclusion

The results of this study illustrate that the risk of C-ROCM and its complications increases in patients with more severe Covid-19 disease, steroid overuse, ICU admission, and poor glycemic control during and after Covid-19 treatment. Moreover, two issues caught our attention. First, the majority of Covid-19 patients had been treated with high-dose steroids, even with mild or moderate disease. Second, most patients were hyperglycemic at admission, even those with no history of diabetes. Thus, we assume closer adherence to the treatment protocol of covid-19 disease and optimal administration of steroids should be promptly considered.

Author contributions All authors contributed to the data curation and investigation. Conceptualization and methodology were performed by M.T.R. and A.A.. The first draft of the manuscript was written by A.A., and all authors commented on previous versions of the manuscript. All authors read and approved the final manuscript.

Funding No dedicated funding was received to carry out this research.

Declarations

Competing interests The authors declare no competing interests.

Conflict of interest Authors declare no financial support or relationships that may pose conflict of interest.

References

1. Song G, Liang G, Liu W (2020) Fungal co-infections associated with global COVID-19 pandemic: a clinical and diagnostic perspective from China. *Mycopathologia* 185(4):599–606. <https://doi.org/10.1007/s11046-020-00462-9>
2. Rawson TM, Moore LSP, Zhu N et al (2020) Bacterial and fungal coinfection in individuals with coronavirus: a rapid review to support COVID-19 antimicrobial prescribing. *Clin Infect Dis* 71(9):2459–2468. <https://doi.org/10.1093/cid/ciaa530>
3. Skiada A, Lass-Floerl C, Klimko N, Ibrahim A, Roilides E, Petrikos G (2018) Challenges in the diagnosis and treatment of mucormycosis. *Med Mycol*. 56(suppl_1):93–101. <https://doi.org/10.1093/mmy/myx101>
4. Bassetti M, Kollef MH, Timsit JF (2020) Bacterial and fungal superinfections in critically ill patients with COVID-19. *Intensive Care Med* 46(11):2071–2074. <https://doi.org/10.1007/s00134-020-06219-8>

5. Hughes S, Troise O, Donaldson H, Mughal N, Moore LSP (2020) Bacterial and fungal coinfection among hospitalized patients with COVID-19: a retrospective cohort study in a UK secondary-care setting. *Clin Microbiol Infect* 26(10):1395–1399. <https://doi.org/10.1016/j.cmi.2020.06.025>
6. Bitar D, Lortholary O, Le Strat Y et al (2014) Population-based analysis of invasive fungal infections, France, 2001–2010. *Emerg Infect Dis* 20(7):1149–1155. <https://doi.org/10.3201/eid2007.140087>
7. Prakash H, Chakrabarti A (2019) Global epidemiology of mucormycosis. *J Fungi* 5(1):26
8. Jeong W, Keighley C, Wolfe R et al (2019) The epidemiology and clinical manifestations of mucormycosis: a systematic review and meta-analysis of case reports. *Clin Microbiol Infect* 25(1):26–34. <https://doi.org/10.1016/j.cmi.2018.07.011>
9. Pakdel F, Ahmadikia K, Salehi M et al (2021) Mucormycosis in patients with COVID-19: a cross-sectional descriptive multicentre study from Iran. *Mycoses* 64(10):1238–1252. <https://doi.org/10.1111/myc.13334>
10. Buil JB, van Zanten ARH, Bentvelsen RG et al (2021) Case series of four secondary mucormycosis infections in COVID-19 patients, the Netherlands, December 2020 to May 2021. *Euro Surveill*. <https://doi.org/10.2807/1560-7917.ES.2021.26.23.2100510>
11. Veisi A, Bagheri A, Eshaghi M, Rikhtehgar MH, Rezaei Kanavi M, Farjad R (2021) Rhino-orbital mucormycosis during steroid therapy in COVID-19 patients: a case report. *Eur J Ophthalmol*. <https://doi.org/10.1177/11206721211009450>
12. Lionakis MS, Kontoyiannis DP (2003) Glucocorticoids and invasive fungal infections. *Lancet* 362(9398):1828–1838. [https://doi.org/10.1016/s0140-6736\(03\)14904-5](https://doi.org/10.1016/s0140-6736(03)14904-5)
13. Antinori S, Bonazzetti C, Gubertini G et al (2020) Tocilizumab for cytokine storm syndrome in COVID-19 pneumonia: an increased risk for candidemia? *Autoimmun Rev*. 19(7):102564. <https://doi.org/10.1016/j.autrev.2020.102564>
14. Narayanan S, Chua JV, Baddley JW (2021) COVID-19 associated Mucormycosis (CAM): risk factors and mechanisms of disease. *Clin Infect Dis*. <https://doi.org/10.1093/cid/ciab726>
15. Singh AK, Singh R, Joshi SR, Misra A (2021) Mucormycosis in COVID-19: A systematic review of cases reported worldwide and in India. *Diabetes Metab Syndr* 15(4):102146. <https://doi.org/10.1016/j.dsx.2021.05.019>
16. Honavar SG (2021) Code mucor: guidelines for the diagnosis, staging and management of rhino-orbito-cerebral mucormycosis in the setting of COVID-19. *Indian J Ophthalmol* 69(6):1361–1365. https://doi.org/10.4103/ijfo.IJO_1165_21
17. World Health Organization (2019) International statistical classification of diseases and related health problems (11th ed.). <https://icd.who.int/>
18. Elmokadem AH, Mounir AM, Ramadan ZA, Elsedieq M, Saleh GA (2022) Comparison of chest CT severity scoring systems for COVID-19. *Eur Radiol* 32(5):3501–3512
19. Alloush TK, Mansour O, Alloush AT et al (2021) Rhino-orbito-cerebral mucormycosis during the COVID-19 third wave in 2021: an Egyptian preliminary report from a single tertiary hospital. *Neurol Sci*. <https://doi.org/10.1007/s10072-021-05740-y>
20. Guzman-Castro S, Chora-Hernandez LD, Trujillo-Alonso G et al (2021) COVID-19-associated mucormycosis, diabetes and steroid therapy: experience in a single centre in Western Mexico. *Mycoses*. <https://doi.org/10.1111/myc.13383>
21. Ravindra K, Ahlawat A (2021) Five probable factors responsible for the COVID-associated mucormycosis outbreak in India. *Int J Infect Dis* 112:278–280. <https://doi.org/10.1016/j.ijid.2021.09.057>
22. Park BJ, Pappas PG, Wannemuehler KA et al (2011) Invasive non-Aspergillus mold infections in transplant recipients, United States, 2001–2006. *Emerg Infect Dis* 17(10):1855–1864. <https://doi.org/10.3201/eid1710.110087>
23. Ibrahim AS, Spellberg B, Walsh TJ, Kontoyiannis DP (2012) Pathogenesis of mucormycosis. *Clin Infect Dis* 54(suppl_1):S16–S22
24. Patrikios G, Tsioutis C (2018) Recent advances in the pathogenesis of mucormycoses. *Clin Ther* 40(6):894–902. <https://doi.org/10.1016/j.clinthera.2018.03.009>
25. Müller JA, Groß R, Conzelmann C et al (2021) SARS-CoV-2 infects and replicates in cells of the human endocrine and exocrine pancreas. *Nat Metab* 3(2):149–165
26. van Paassen J, Vos JS, Hoekstra EM, Neumann KM, Boot PC, Arbous SM (2020) Corticosteroid use in COVID-19 patients: a systematic review and meta-analysis on clinical outcomes. *Crit Care* 24(1):1–22
27. Kothandaraman N, Rengaraj A, Xue B et al (2021) COVID-19 endocrinopathy with hindsight from SARS. *Am J Physiol-Endocrinol Metab* 320(1):E139–E150
28. Hargrove RN, Wesley RE, Klippenstein KA, Fleming JC, Haik BG (2006) Indications for orbital exenteration in mucormycosis. *Ophthalmic Plast Reconstr Surg* 22(4):286–291. <https://doi.org/10.1097/01.iop.0000225418.50441.ee>
29. Jeong W, Keighley C, Wolfe R et al (2019) Contemporary management and clinical outcomes of mucormycosis: a systematic review and meta-analysis of case reports. *Int J Antimicrob Agents* 53(5):589–597. <https://doi.org/10.1016/j.ijantimicag.2019.01.002>
30. Kontoyiannis DP, Lewis RE (2011) How I treat mucormycosis. *Blood* 118(5):1216–1224. <https://doi.org/10.1182/blood-2011-03-316430>
31. Shah K, Dave V, Bradoo R, Shinde C, Prathibha M (2019) Orbital exenteration in rhino-orbito-cerebral mucormycosis: a prospective analytical study with scoring system. *Indian J Otolaryngol Head Neck Surg* 71(2):259–265. <https://doi.org/10.1007/s12070-018-1293-8>

Publisher's Note Springer Nature remains neutral with regard to jurisdictional claims in published maps and institutional affiliations.

Springer Nature or its licensor holds exclusive rights to this article under a publishing agreement with the author(s) or other rightsholder(s); author self-archiving of the accepted manuscript version of this article is solely governed by the terms of such publishing agreement and applicable law.