



A Lucky Case of Successful Free Fibula Osteocutaneous Flap Harvest in Peronea Arteria Magna

Mohamad Aizat Rosli, MBChB^{1,2}  Wan Azman Wan Sulaiman, MD, MS^{1,2} 
Ahmad Sukari Halim, MD, FCCP^{1,2} 

¹ Hospital Universiti Sains Malaysia, Universiti Sains Malaysia, Kota Bharu, Kelantan, Malaysia

² Reconstructive Sciences Unit, School of Medical Sciences, Universiti Sains Malaysia, Kota Bharu, Kelantan, Malaysia

Address for correspondence Ahmad Sukari Halim, MD, FCCP, Hospital Universiti Sains Malaysia, Jalan Raja Perempuan Zainab II, Kubang Kerian, 16150 Kota Bharu, Kelantan, Malaysia
(e-mail: ashalim@usm.my).

Arch Plast Surg 2022;49:253–257.

Abstract

The free fibula flap (FFF) is based on the peroneal artery (PA) system, and it is well known that several anatomical variations of the lower limb vascular system exist, including peronea arteria magna (PAM). PAM is a rare congenital variation in which both anterior tibial artery and posterior tibial artery are either aplastic or hypoplastic, and as a result, PA will be the dominant blood supply to the foot. This variation was described as type III-C in Kim-Lippert's Classification of the Infra-Popliteal Arterial Branching Variations. The awareness of its existence is crucial as it often precludes FFF from being harvested due to the risk of significant limb ischemia and limb loss. Despite some literature reporting donor site complications and impending limb loss following FFF harvest in PAM, preoperative vascular mapping before FFF transfer remains controversial among the microsurgeons. We present a case with an incidental intraoperative finding of PAM that had a successful FFF harvest by luck, without preoperative vascular mapping.

Keywords

- ▶ fibula
- ▶ free tissue flaps
- ▶ tibial arteries
- ▶ lower extremity
- ▶ foot

The free fibula flap (FFF) has become one of the workhorse flaps since its introduction by Taylor et al in 1975.¹ It has been widely used to reconstruct posttraumatic and postoncological resection bony defect due to its versatility, ease of harvesting, and long vascular pedicle.² Hidalgo further developed this flap for mandibular reconstruction in 1989 as it has a thin and pliable bone, as well as the presence of cutaneous island allowing reconstruction of both mandible and the surrounding soft tissues.³

The FFF is based on the peroneal artery (PA), and it is well known that several anatomical variations of the lower limb vascular system exist. PA usually arise from the posterior tibialis artery (PTA) 2.5 to 3 cm below the lower border of the popliteus muscle, and subsequently branches off to give rise

to peroneal nutrient arteries, periosteal branches, and septocutaneous arteries to the skin over the lateral aspect of the leg.² The variations of the origin, course, and diameter of the anterior tibialis artery (ATA), PTA, and PA were initially described and classified by Lippert and Pabst in 1985⁴ and later modified by Kim et al in 1989.⁵ The Kim-Lippert's Classification has now become the widely used guide to describe the infrapopliteal arterial branching variations.⁵

The knowledge of the third group in Kim-Lippert's Classification is of the utmost importance in the harvest of FFF because it describes the presence of hypoplasia or aplasia of the tibial arteries with the PA being the dominant artery supplying the peripheral pedal arterial supply via dorsalis pedis artery (DPA) and PTA. In Class III C, both ATA and PTA

DOI <https://doi.org/10.1055/s-0042-1744411>.
ISSN 2234-6163.

© 2022. The Korean Society of Plastic and Reconstructive Surgeons. All rights reserved.

This is an open access article published by Thieme under the terms of the Creative Commons Attribution-NonDerivative-NonCommercial-License, permitting copying and reproduction so long as the original work is given appropriate credit. Contents may not be used for commercial purposes, or adapted, remixed, transformed or built upon. (<https://creativecommons.org/licenses/by-nc-nd/4.0/>)

Thieme Medical Publishers, Inc., 333 Seventh Avenue, 18th Floor, New York, NY 10001, USA

are either hypoplastic or aplastic; otherwise commonly known as peronea arteria magna (PAM).^{5,6} The prevalence of PAM is estimated at only 0.4%. Albeit scarce, the awareness of its existence is crucial as it often precludes FFF from being harvested due to the risk of significant limb ischemia and limb loss.⁶

We present a case with an incidental intraoperative finding of PAM that had a successful FFF harvest by luck, without preoperative vascular mapping.

Case Report

Ms. A is a 17-year-old female with no known comorbidity, presented in August 2020 with a 1-year history of swelling and tenderness over her left foot. A magnetic resonance imaging (MRI) was performed in a private center, which showed an enhancing well-circumscribed mass centered in the second webspace (between second and third metatarsal shafts) involving interosseous muscles, most likely soft tissue tumor or sarcoma. Resection was done; however, the histopathology examination (HPE) report came back as perineuroma with the surgical margins' involvement. Unfortunately, the swelling recurred 8 months postoperatively. She was then referred to our center for further management. Our clinical examination revealed a well-healed scar with an ill-defined swelling over the dorsum of her left foot. A repeat MRI showed a lesion surrounding the second metatarsal with local infiltration to the overlying muscles and bone of the second and third metatarsal, suggesting tumor recurrence.

She underwent wide resection of left foot tumor, left extensor digitorum tendon repair with peroneal brevis tendon graft, and left foot reconstruction with a free fibular osteocutaneous flap. The tumor encased the left second and third metatarsal bones; hence these bones and overlying second and third extensor digitorum longus tendons were removed together. The resulting soft tissue and bony defect measured approximately $8 \times 8 \times 4$ cm (►Fig. 1A). The harvested fibular bone was osteotomized, and 8 cm of bone and its skin paddle were used to bridge the bony defect; proximally to middle and lateral cuneiform and distally to second and third proximal phalanges. The arterial anastomosis was performed between the flap's PA and recipient site's DPA, while the venous anastomosis between the respective vena comitans of each artery. The flap was secured in place with a T plate and screws post-anastomosis. The wound was then covered with the skin paddle (►Fig. 1B). The configuration of the reconstruction is portrayed in the X-ray (►Fig. 1C).

During the flap's harvest on the contralateral leg, a large dominant PA emerged from the popliteal artery supplying the flap and providing a dominant blood supply to the foot. Further exploration also revealed aplastic PTA and hypoplastic ATA originating from the popliteal artery. The PA is shown by white arrowhead, while the black arrow demonstrates the aplastic PTA (►Fig. 2A). The aplastic PTA was seen tapering down and abruptly terminated at the level of the mid tibia. The hypoplastic ATA was small in caliber upon exploration and slightly expanded upon distal PA ligation (marked by the red arrow in ►Fig. 2B). These findings correspond to the type

III-C in Kim-Lippert's Classification. Preoperatively, clinical examination revealed normal DPA and PTA pulses, and flap planning was performed with a handheld Doppler in the usual manner. However, no preoperative angiography was performed to reconfirm the donor leg vascularity.

Additional precautionary steps were taken during harvest to avoid any ischemic event to the right lower limb. The tourniquet was first released, and the PA was clamped before it was divided. Distal circulation assessment and monitoring of the right foot were performed during clamping. After 15 minutes of clamping, the right DPA remained palpable clinically and was detectable by handheld Doppler. The oxygen saturation over the right lower limb distal extremity was also maintaining at 100%, demonstrating adequate residual blood flow to the foot. The artery was then divided, and the flap was raised without any acute or chronic ischemic complications. HPE came back as deep (desmoid type) fibromatosis, with all margins' involvement except the superficial and proximal margins. She was then subjected to adjuvant radiotherapy.

Six months postoperatively, no ischemic event or right leg claudication was reported. The right leg donor site healed well, and no noticeable skin changes suggestive of an ischemic limb were observed (►Fig. 3A). The flap also remained viable with no tumor recurrence (►Fig. 3B), and the patient could fully bear weight. There was a solid bony union with increased radiodensity suggesting bone remodeling and graft viability, as shown in the foot X-ray (►Fig. 3C). A more extended follow-up period is warranted for her. Although there was no necrosis of the distal foot area suggesting an acute ischemic event, chronic hypoperfusion may cause delayed manifestation of soft tissue, muscle, and bone atrophy.

Discussion

PAM is a rare congenital variation in which the ATA and PTA are either absent or hypoplastic, and as a result, PA will be the dominant blood supply to the foot.⁵ Limb ischemia and limb loss are often the feared adverse complications from the FFF harvest in these patients.⁶ Albeit some literature reporting donor site complications and impending limb loss following FFF harvest in PAM, preoperative vascular mapping before FFF transfer remains controversial among the microsurgeons.⁷⁻⁹ For instance, Rosson and Singh in 2005 reported an unsuccessful FFF harvest in a patient with PAM, requiring an emergency vascular bypass with a reversed saphenous vein graft to regain limb perfusion.¹⁰ It was also reported that the cost-to-benefit ratio and some imaging modalities' invasiveness contribute to this ongoing debate.¹⁰

Several authors advocate for preoperative vascular mapping of the FFF donor leg by using the computer tomography angiography (CTA), digital subtraction angiography (DSA),⁹ and magnetic resonance angiography (MRA).^{8,11} CTA may be the preferred initial screening tool for detecting vascular pathologies. For equivocal findings, DSA is deemed superior to CTA in terms of contrast and spatial resolution. The invasiveness of DSA carries undesirable risks such as internal bleeding, arterial puncture, thrombosis, infection, vessel

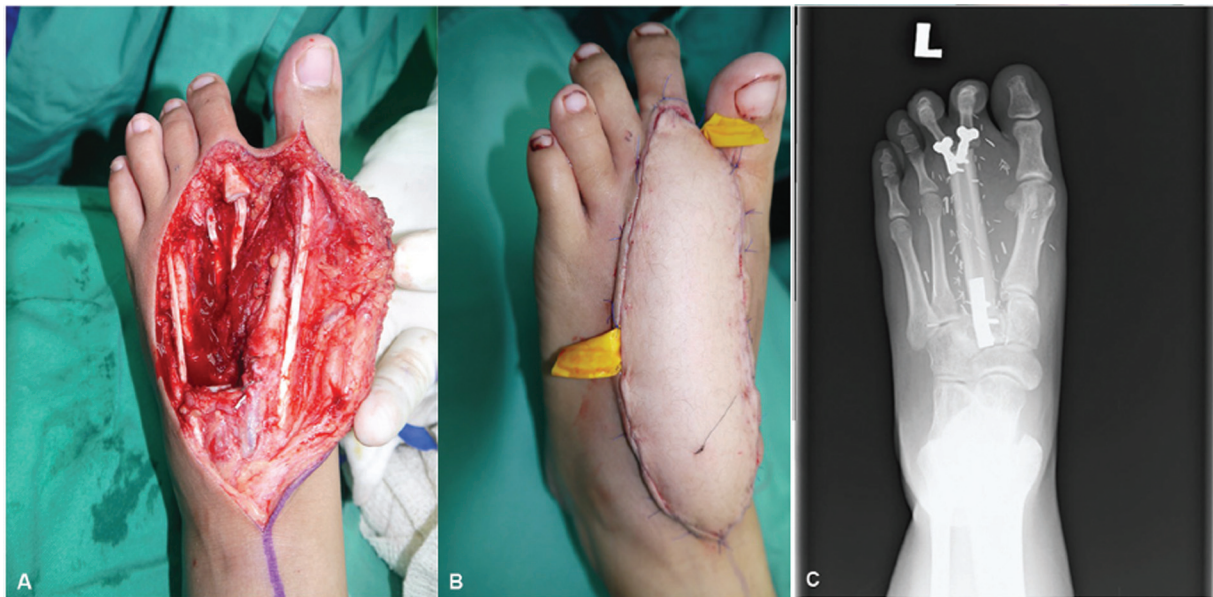


Fig. 1 The reconstruction with free fibula osteocutaneous flap. The patient's left foot was reconstructed with a free fibula flap following oncological resection of the tumor. (A) The defect after tumor resection, measuring $8 \times 8 \times 4$ cm. (B) The immediate postoperative flap appearance. (C) The flap's osseous configuration as shown in an X-ray.

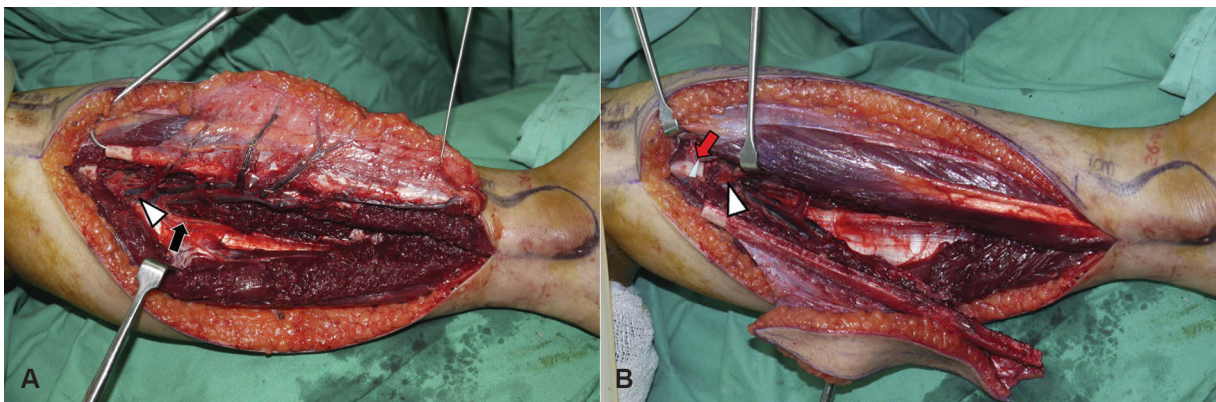


Fig. 2 The finding of peronea arteria magna (PAM) intraoperatively. Clinical findings of PAM upon flap harvest and elevation. (A) The prominent peroneal artery (PA) with extensive branching is shown by the white arrowhead, while the black arrow demonstrates the very small aplastic posterior tibial artery (PTA), which was seen tapering down and abruptly terminated at the level of mid to distal tibia. (B) The small caliber hypoplastic anterior tibialis artery (ATA) is marked by the red arrow and has become slightly expanded upon distal PA ligation.

dissection, pseudoaneurysm, hematoma, and renal injury to the contrast medium.⁸ MRA offers an alternative option as it is not invasive and can give excellent visualization of the leg vascular anatomy.^{10,12} Nevertheless, MRA is costly, and metal fixators or implants are contraindicated for its usage.⁸

On the other hand, some authors oppose the use of preoperative imaging of the donor limb^{7,13} as it is believed that preoperative clinical examination and intraoperative assessment are reliable enough without the need for additional preoperative imaging. They also believe that the FFF harvest can be abandoned if PAM is identified intraoperatively; however, the added cost from the additional surgery and morbidity must be considered. It is worth noting that PAM can even be present in patients with a normal clinical vascular examination. Both DPA and PTA may be palpable due to the collateral branches of the dominant PA supplying

these vessels.¹⁰ In a study by Young et al, two of their participants had PAM despite normal distal pulses during the clinical examination.¹⁴

In PAM (subtype III-C), the PA is the only dominant vessel supplying the foot; hence its removal during the FFF harvest may result in limb ischemia or total limb loss. In the other two subtypes, the larger diameter dominant PA shares the blood supply to the foot either with the ATA or PTA, while the other tibial vessel counterpart being hypoplastic. These variations are not easily detected by clinical examination alone without preoperative vascular imaging, unlike Allen's test used in the forearm to detect radial or ulnar arteries dominance.⁶

Despite being one of the main referral centers in Malaysia for major reconstruction, we do not perform routine preoperative imaging to assess FFF donor limb, except in patients with a significant previous history of trauma or other

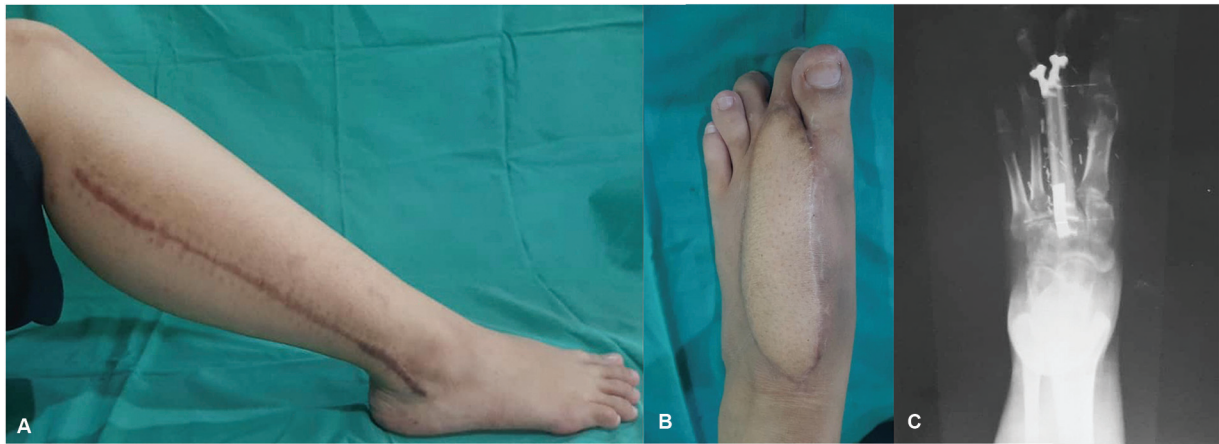

Fig. 3 Right leg (donor site) and left foot (recipient site) appearance after 6 months. The observations as shown by clinical and radiological examinations. (A) The donor site healed well with no obvious skin changes suggestive of ischemic limb. (B) The flap appearance after 6 months. (C) Left foot's X-ray showing minimal hypertrophy with no resorption suggesting graft viability.

comorbidities that may compromise vascularity the fibula flap's donor site. In such cases, we usually opt for the more conventional CTA. Our practice is due to the high cost-to-benefit ratio owing to PAM's rarity in our population. In the last 5 years (from 2016 to 2020), we have performed 51 free fibular transfers for various etiologies and only one of these patients presented with PAM. Unnecessary routine imaging will add a substantial strain to our busy and overburdened radiology unit. Only clinical assessment, perforator identification, and flap planning with handheld Doppler were made in most cases, including this case.

Due to limited options for simultaneous bone and cutaneous reconstruction and to avoid unnecessary morbidity and cost increase due to aborted procedure, the FFF was still harvested with strict precaution and rigorous postoperative monitoring despite the relative contraindication in PAM. It is worth noting that despite our practice, we do advocate the use of preoperative imaging to avoid any donor's ischemic complications posttransfer. However, we are unable to routinely use preoperative vascular mapping as a standard due to the limitations described above.

The increase in blood flow through the hypoplastic ATA and collateral vessels may have provided adequate residual blood flow to the right foot following the distal PA's ligation. Unfortunately, the evidence is limited as this was not explored postoperatively with further imaging due to logistic issues caused by the COVID-19 pandemic. This case provides some evidence that with meticulous techniques, care, and a bit of luck, FFF may be safely harvested from a patient with PAM. Nevertheless, this practice is risky, requiring rigorous postoperative care and a low threshold for an emergency vascular bypass for limb salvage. We still believe that in an ideal situation with unlimited resources, preoperative imaging is mandatory to prevent unnecessary donor limb morbidity or even limb loss.

Author Contributions

Conceptualization: M.A.R., W.A.W.S., A.S.H. Data curation: M.A.R., W.A.W.S. Formal analysis: M.A.R., W.A.W.S., A.S.H.

Funding acquisition: None. Methodology: M.A.R., W.A.W.S., A.S.H. Project administration: M.A.R., W.A.W.S., A.S.H. Writing - original draft: M.A.R. Writing - review and editing: all authors.

Ethical Approval

The study was performed in accordance with the principles of the Declaration of Helsinki. Written informed consents were obtained.

Patient Consent

The patients provided written informed consent for the publication and the use of their images.

Conflict of Interest

None declared.

References

- Taylor GI, Miller GD, Ham FJ. The free vascularized bone graft. A clinical extension of microvascular techniques. *Plast Reconstr Surg* 1975;55(05):533-544
- Longo B, Sorotos M, Nicolotti M, Santanelli di Pompeo F. Retrospective analysis of incidence of peroneal artery hypoplasia in 101 free fibula transfers and new classification of popliteal branch anomalies. *Injury* 2014;45(02):394-398
- Hidalgo DA. Fibula free flap, plastic and reconstructive surgery. *Plast Reconstr Surg* 1989;84(02):71-79
- Lippert H, Pabst R. *Arterial Variations in Man*. München: J.F. Bergmann Verlag; 1985
- Kim D, Orron DE, Skillman JJ. Surgical significance of popliteal arterial variants. A unified angiographic classification. *Ann Surg* 1989;210(06):776-781
- Abou-Foul AK, Borumandi F. Anatomical variants of lower limb vasculature and implications for free fibula flap: systematic review and critical analysis. *Microsurgery* 2016;36(02):165-172
- Lutz BS, Wei FC, Ng SH, Chen IH, Chen SHT. Routine donor leg angiography before vascularized free fibula transplantation is not necessary: a prospective study in 120 clinical cases. *Plast Reconstr Surg* 1999;103(01):121-127
- Hölzle F, Ristow O, Rau A, et al. Evaluation of the vessels of the lower leg before microsurgical fibular transfer. Part II:

- magnetic resonance angiography for standard preoperative assessment. *Br J Oral Maxillofac Surg* 2011;49(04):275–280
- 9 Kelly AM, Cronin P, Hussain HK, Londy FJ, Chepeha DB, Carlos RC. Preoperative MR angiography in free fibula flap transfer for head and neck cancer: clinical application and influence on surgical decision making. *Am J Roentgenol* 2007;188(01):268–274
- 10 Rosson GD, Singh NK. Devascularizing complications of free fibula harvest: peronea arteria magna. *J Reconstr Microsurg* 2005;21(08):533–538
- 11 Mast BA. Comparison of magnetic resonance angiography and digital subtraction angiography for visualization of lower extremity arteries. *Ann Plast Surg* 2001;46(03):261–264
- 12 Koelemay MJ, Lijmer JG, Stoker J, Legemate DA, Bossuyt PM. Magnetic resonance angiography for the evaluation of lower extremity arterial disease: a meta-analysis. *JAMA* 2001;285(10):1338–1345
- 13 Disa JJ, Cordeiro PG. The current role of preoperative arteriography in free fibula flaps. *Plast Reconstr Surg* 1998;102(04):1083–1088
- 14 Young DM, Trabelsy PP, Anthony JP. The need for preoperative leg angiography in fibula free flaps. *J Reconstr Microsurg* 1994;10(05):283–288