



# Acromion and glenoid shape: Why are they important predictive factors for the future of our shoulders?

Richard W. Nyffeler<sup>1</sup>  
Dominik C. Meyer<sup>2</sup>

- The shape of the acromion differs between patients with degenerative rotator cuff tears and individuals without rotator cuff pathology.
- It can be assessed in the sagittal plane (acromion type, acromion slope) and in the coronal plane (lateral acromion angle, acromion index, critical shoulder angle).
- The inter-observer reliability is better for the measurements in the coronal plane.
- A large lateral extension (high acromion index or high critical shoulder angle) and a lateral down-sloping of the acromion (low lateral acromion angle) are associated with full-thickness supraspinatus tears.
- The significance of glenoid inclination for rotator cuff disease is less clear.
- The postulated patho-mechanism is the compression of the supraspinatus tendon between the humeral head and the acromion. Bursal side tears might be caused by friction and abrasion of the tendon. Articular side tears could be due to impairment of the gliding mechanism between tendon fibrils leading to local stress concentration. Further research is needed to understand the exact pathomechanism of tendon degeneration and tear.

**Keywords:** shoulder; acromion; glenoid; subacromial impingement; supraspinatus tendon; rotator cuff tear; osteoarthritis; tendon fibrils; gliding mechanism.

Cite this article: *EFORT Open Rev* 2017;2.  
DOI: 10.1302/2058-5241.2.160076. Originally published online at [www.efortopenreviews.org](http://www.efortopenreviews.org)

## Introduction

The acromion partially covers the humeral head, articulates with the clavicle and gives attachment to the anterolateral portion of the deltoid muscle and the coraco-acromial ligament. It has been associated with chronic pain and dysfunction of the shoulder for a long time. In 1934, Codman<sup>1</sup> reported that hypertrophic changes at the acromial edge could frequently be observed on the radiographs of

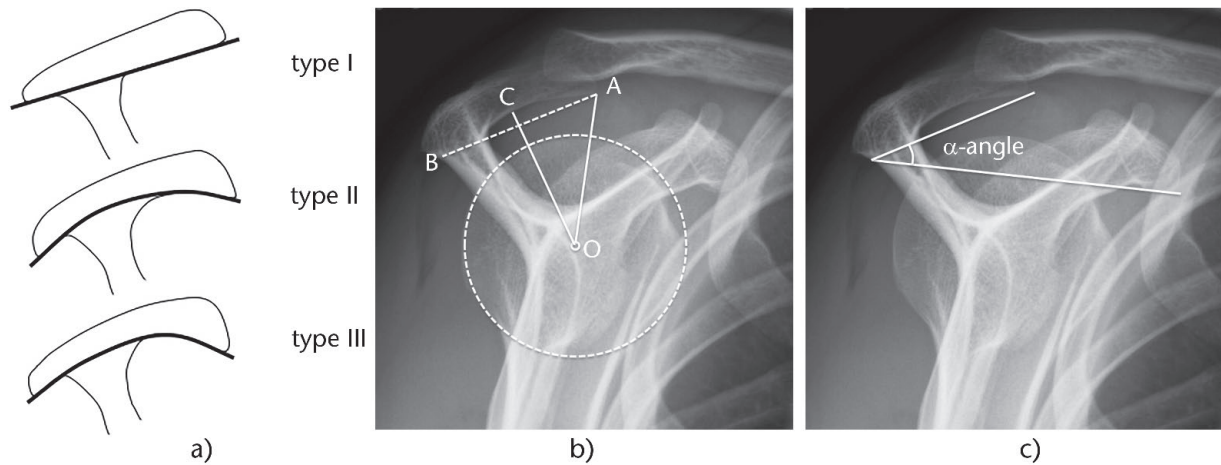
patients with long-standing subacromial bursitis associated with complete tear of the rotator cuff. In 1949, Armstrong<sup>2</sup> noted that in the middle range of abduction movement the supraspinatus tendon impinges on the overlying processes and that the tendon and the bursa are compressed between the humerus and the acromion. He stated that this pressure causes pain, when there is abnormality of the tendon or bursa. In 1972, Neer<sup>3</sup> emphasised that impingement of the cuff occurs against the anterior part of the acromion and the coraco-acromial ligament. Some years later, Watson<sup>4</sup> suggested that refractory cases of the painful arc syndrome could be due to impingement of the rotator cuff against a bulging coraco-acromial ligament, forced down by the swollen overlying degenerated acromioclavicular joint.

Although all these authors identified the acromion and its adjacent structures as the potential source of the most frequent shoulder disorders, more systematic investigations concerning the morphology of the acromion only started ten years after Neer's description of the antero-inferior acromion spur. Because these morphological findings are important for the understanding of the patho-mechanism and the treatment of rotator cuff diseases, they are summarised in the following review.

## Acromion shape in the sagittal plane

### *Acromial type*

Bigliani et al<sup>5</sup> classified the shape of the acromion on supraspinatus outlet (or lateral) radiographs into three distinct types: type I represents a flat, type II a curved and type III a hooked undersurface of the acromion (Fig. 1a). The authors found a higher prevalence of rotator cuff tears (RCTs) in patients with a hooked acromion than in individuals with a curved or flat acromion. Other studies confirmed these results, but also showed a fair inter-observer reliability. The disagreement between observers mainly concerned the allocation of an acromion type II or type III. Park et al<sup>6</sup> therefore proposed a more objective evaluation criterion. On standardised supraspinatus outlet views they



**Fig. 1** a) Bigliani et al<sup>5</sup> classified the acromion into three types: type I represents a flat, type II a curved and type III a hooked acromion. b) Supraspinatus outlet view demonstrating the assessment of the shape of the acromion according to Park et al.<sup>6</sup> Three points are drawn on the undersurface of the acromion: the most anterior point (A), the most posterior point (B) and the point (C) which is equidistant from the two other points. Point (O) represents the centre of the humeral head. If point C lies on the line connecting point A to B, then the acromion is a type I. If the distances OA and OC are equal, then the acromion is a type II. If the distance OA is shorter than the distance OC, then it is a type III acromion. c) Supraspinatus outlet view showing the measurement of the acromial slope according to Aoki et al. This is determined between a line drawn on the undersurface of the acromion and another line connecting the postero-inferior border of the acromion with the inferior border of the coracoid process and is called the  $\alpha$ -angle.

first determined three points on the undersurface of the acromion; the most anterior point (A), the most posterior point (B) and the point (C) which was equidistant from the two other points (Fig. 1b). They then determined the centre of the humeral head (point O) and measured the distances from this point to the points A and C. If both distances were equal, then the acromion was a type II. If the distance OA was shorter than the distance OC, then it was a type III acromion. The authors showed that the reliability of their evaluation method was better than that of Bigliani.

#### Anteroinferior osteophyte

The acromion may have a bony prominence or spur at the anteroinferior edge, in the area of the coracoacromial ligament insertion. In the literature this prominence has been called excrescence, beak, spur, osteophyte and enthesophyte.<sup>7</sup> It is more common in type III acromions (37%) than in type I acromions (2%),<sup>8</sup> but it should not be confounded with a hooked or a type III acromion. It is not yet known, if it is the cause or a consequence of subacromial impingement. Several researchers suggested that it could be due to increased tensile forces within the coracoacromial ligament during flexion and internal rotation of the shoulder.<sup>9</sup> Their theory however does not explain why there are no traction spurs on the coracoid side. The fact that the undersurface of the coracoacromial ligament and the bursal side of the supraspinatus tendon often appear rough in patients with impingement syndrome could mean that a spur is the result of friction and attrition at the anteroinferior edge of the acromion rather than the consequence of traction in the ligament.

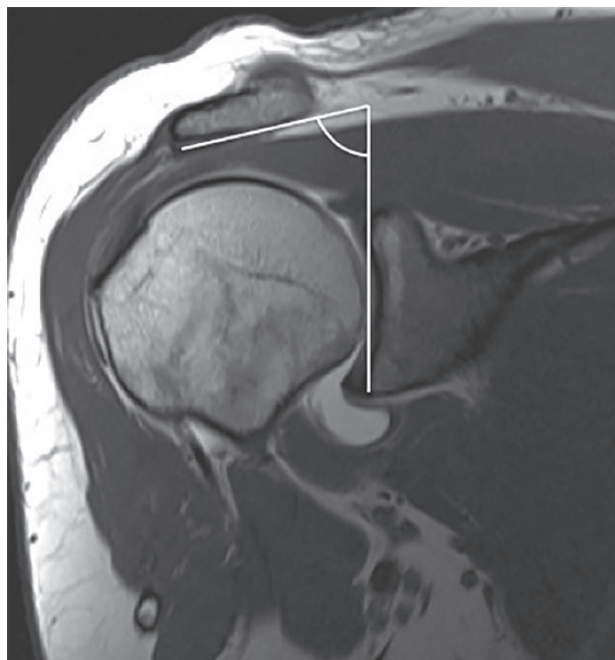#### Acromial slope

Aoki et al<sup>10</sup> measured the slope of the acromion on supraspinatus outlet views. It was the angle between a line drawn on the undersurface of the acromion and another line connecting the postero-inferior border of the acromion with the inferior border of the coracoid process and was called  $\alpha$ -angle (Fig. 1c). It was in the range of 23° to 45° in healthy adults and 23° to 39° in patients who had a stage II subacromial impingement lesion without a spur on the undersurface of the acromion. The mean values were significantly different between healthy adults and patients, and the authors therefore concluded that a low slope of the acromion might be an important factor in the pathogenesis of subacromial impingement. Other authors confirmed these findings.<sup>11,12</sup> Instead of acromial slope, some authors used the term acromial tilt.<sup>13</sup>

### Acromion shape in the coronal plane

#### Acromion inclination

Banas et al<sup>14</sup> described the lateral acromion angle (LAA), which was measured from an oblique coronal MRI slice just posterior to the acromioclavicular joint. The angle was determined by the intersection of a line parallel to the acromion undersurface and a second line parallel to the glenoid fossa (Fig. 2). The authors found that the angle was not affected by small variations in the orientation of the image plane. In their study with 100 patients having symptoms suggesting rotator cuff disease, the lateral acromion angle was in the range of 64° to 99°. The higher angles were



**Fig. 2** The lateral acromion angle is determined on coronal MR arthrograms and represents the angle enclosed between the glenoid plane and the undersurface of the acromion.

found in patients with an intact tendon and the lower angles in patients with tendon discontinuity. All shoulders with an acromion angle less than  $70^\circ$  had full-thickness rotator cuff tears. Other authors confirmed these findings.<sup>12,15</sup>

#### *Lateral extension of the acromion*

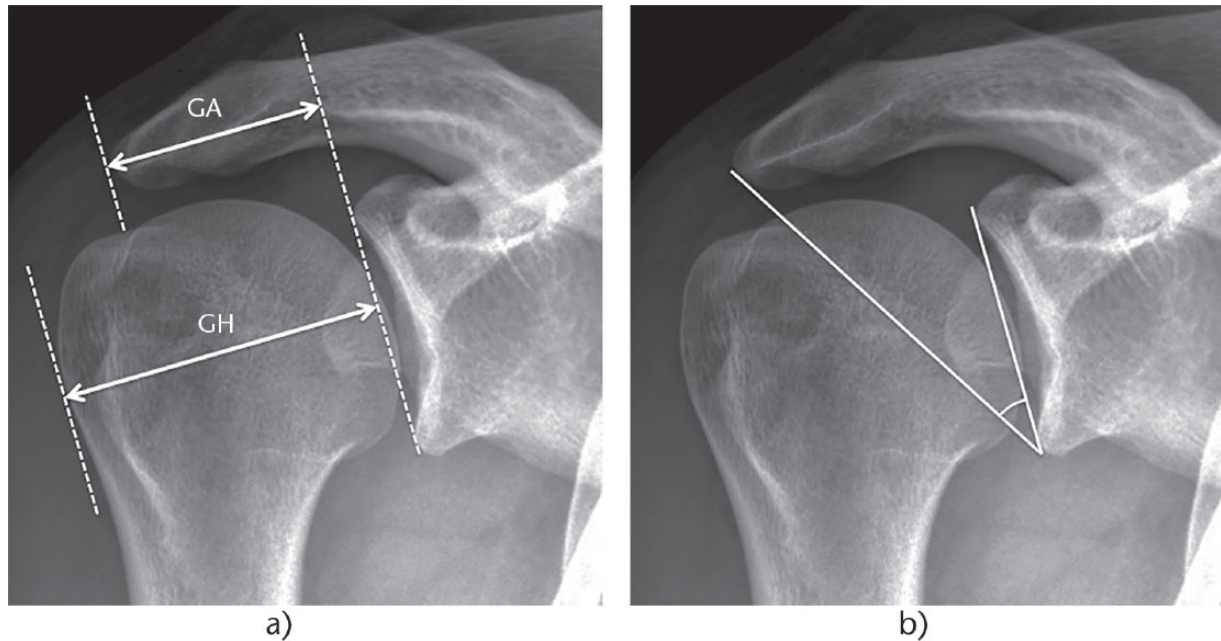
Since the acromion of patients with a rotator cuff tear very often appears large, Nyffeler et al<sup>16</sup> proposed a method to quantify the lateral extension of the acromion on standardised true anteroposterior (AP) radiographs with the arm in neutral rotation. They divided the distance from the glenoid to the acromion by the distance from the glenoid to the lateral aspect of the humeral head and called the resulting value the acromion index (AI) (Fig. 3a). A high AI corresponded to a large lateral extension of the acromion. In their study the average AI was 0.73 in patients with a full-thickness rotator cuff tear, 0.60 in patients with osteoarthritis and 0.64 in a control group. The differences between the patients with a full-thickness rotator cuff tear and the two groups of individuals with an intact rotator cuff were significant. The difference between the control group and the patients with osteoarthritis was not significant. This was mainly attributed to the disappearance of the joint space and the related reduction of the distance from the glenoid to the lateral aspect of the humeral head in osteoarthritic shoulders. Pre-morbid radiographs of shoulders with primary osteoarthritis were not available for this study.

Many other authors then investigated the association between a wide lateral extension of the acromion and rotator cuff tears. Torrens et al<sup>17</sup> confirmed the findings with a slightly different measurement method (acromial coverage index). Miyazaki et al<sup>18</sup> determined the AI in Brazilian and Japanese adults and concluded that the AI can be used as a predictive factor for rotator cuff tears in the Brazilian population but not in the Japanese population. Kim et al<sup>19</sup> detected a higher AI more frequently in patients with large-to-massive cuff tears than in patients with partial-thickness articular side tears. Zumstein et al<sup>20</sup> identified a wide lateral extension of the acromion as a risk factor for re-tearing after open repair of massive tears. Balke et al<sup>21</sup> showed that shoulders with degenerative tears had a significantly larger lateral extension of the acromion than shoulders with traumatic supraspinatus tendon tears. Hamid et al<sup>22</sup> found excellent inter-observer reliability of the AI but no difference between patients with rotator cuff tears and individuals with no history of rotator cuff pathology.

Later, Moor et al<sup>15</sup> proposed another radiological parameter to describe the lateral extension of the acromion, which is independent of the orientation of the arm, the width of the glenohumeral joint space and the flattening of the humeral head. They determined, on standardised AP radiographs, the angle formed between a line connecting the superior and inferior borders of the glenoid fossa and another line drawn from the inferior border of the glenoid to the most lateral point of the acromion (Fig. 3b). This angle was called critical shoulder angle (CSA) and averaged  $33.1^\circ$  in a control group of asymptomatic patients with an intact cuff,  $38.0^\circ$  in patients with a rotator cuff tear and  $28.1^\circ$  in patients with osteoarthritis. The inter-observer reliability was excellent. The authors concluded that degenerative rotator cuff tears were associated with significantly larger CSAs and primary glenohumeral osteoarthritis with significantly smaller CSAs than asymptomatic shoulders without these pathologies. Other studies confirmed these findings.<sup>23,24</sup>

#### **Glenoid inclination**

In the literature, glenoid inclination has been defined and measured in many different ways. Churchill et al<sup>25</sup> determined glenoid inclination on 172 pairs of dry scapulae. They used as reference for the orientation of the glenoid fossa a line connecting the mid-point of the glenoid surface to the junction of the scapular spine with the vertebral border of the scapula. This line was called the transverse axis of the scapula. An angle of  $0^\circ$  corresponded to a glenoid which was perpendicular to the transverse axis of the scapula. They found that glenoid inclination varied considerably, in the range of  $-7.0^\circ$  (facing downwards) to  $+15.8^\circ$  (facing upwards). No significant



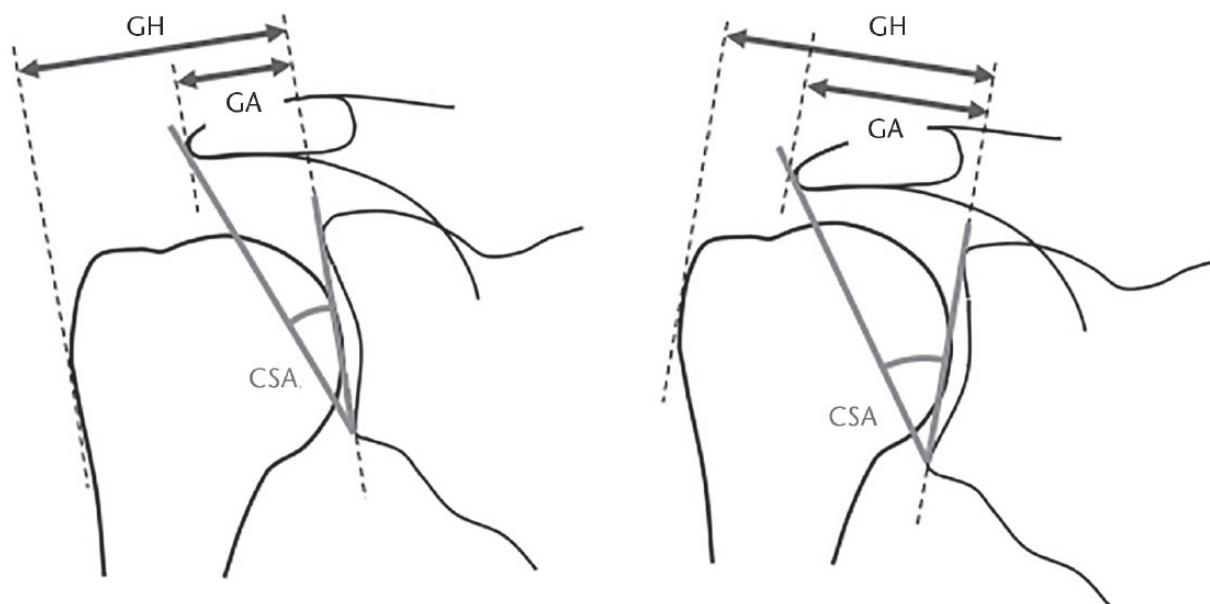
**Fig. 3** a) True AP radiographs with the humerus in neutral rotation are used to determine the lateral extension of the acromion. The distance from the glenoid plane to the lateral border of the acromion (GA) is divided by the distance from the glenoid plane to the lateral aspect of the humeral head (GH) and called the acromion index. A high acromion index represents an acromion that projects far laterally and covers the biggest portion of the humeral head. b) The critical shoulder angle is measured on true AP radiographs and corresponds to the angle formed between the glenoid plane and a line connecting the inferior glenoid rim with the lateral aspect of the acromion.

difference could be detected between races and sex. Hughes et al<sup>26</sup> measured glenoid inclination on AP radiographs of eight pairs of cadaver shoulders, in which one shoulder had an intact rotator cuff and the other shoulder had a full-thickness rotator cuff tear. Their reference was a line drawn from the spinoglenoid notch to the intersection of the spine and the medial border of the scapula. Glenoid inclination was defined as the angle measured in the superolateral quadrant of the intersection formed by the reference line and a line joining the inferior and superior glenoid rim. They found that glenoid inclination was greater in cadaver shoulders having full-thickness rotator cuff tears (98.6°) than in shoulders without tears (91.0°). Kandemir et al<sup>27</sup> used a three-dimensional (3D) digitising system to measure six different angles of inclination in 24 cadaveric shoulders, 12 with an intact rotator cuff and 12 with a full-thickness tear. They did not find a difference in glenoid inclination in scapulae between shoulders with an intact cuff and those with a full-thickness tear. Bishop et al<sup>28</sup> determined glenoid inclination on patient-specific CT-based bone models of 21 patients, in whom a full-thickness supraspinatus tear had been repaired on one side. In their cohort, glenoid inclination was significantly lower for the rotator cuff repaired shoulders than for the contralateral, asymptomatic shoulders. Maurer et al<sup>29</sup> studied three different methods to measure glenoid inclination on standard AP radiographs and CT images. They

found that the angle  $\beta$  between the glenoid fossa and the floor of the supraspinatus fossa, visible as the sclerotic line, was the most reproducible measurement method on conventional AP radiographs, providing a good resistance to positional variability of the scapula and a good inter-rater reliability. Daggett et al<sup>30</sup> measured the  $\beta$ -angle of 51 shoulders on AP radiographs, unformatted two-dimensional (2D) CT scans and reformatted 2D CT scans in the scapular plane. They compared the results with the glenoid inclination angle calculated with 3D software. In their study, the most accurate method for measuring the  $\beta$ -angle was the measurement on reformatted 2D CT scans. With this method, the mean difference compared with the 3D measurements was 1°. Determination of the  $\beta$ -angle on AP radiographs was not as accurate, with a mean difference of 3°. The measurements on unformatted 2D CT scans showed a mean difference of 10° and the method was considered inadequate to determine glenoid inclination.

All the above-cited authors determined glenoid inclination relative to a reference line on the scapula. The vertical or the image border is an unsuitable reference because the position of the scapula at rest depends on the posture of the patient in front of the radiograph cassette. In elderly patients with a curved back and hanging shoulders, the glenoid may be tilted downwards despite a normal inclination relative to the transverse axis of the scapula.





**Fig. 4** Drawing demonstrating the correlation between AI and critical shoulder angle. Both parameters depend on the inclination of the glenoid and the lateral extension of the acromion. The AI and the critical shoulder angle decrease when the glenoid is oriented downwards and they increase when the glenoid is faced upwards.

### Relationship between lateral acromion angle, acromion index, critical shoulder angle and glenoid inclination

Moor et al<sup>15</sup> noted that, in contrast to the AI, the critical shoulder angle combines the measurements of glenoid inclination and lateral extension of the acromion, thus integrating both potential risk factors for degenerative rotator cuff tears into one radiological parameter. Because other authors have repeated this statement, it needs some clarification. It is true that the CSA depends on the lateral extension of the acromion as well as the inclination of the glenoid. But it does not allow quantifying one of them. For a given CSA, neither the lateral extension of the acromion nor the inclination of the glenoid is known. It is wrong to assume that the AI does not depend on the inclination of the glenoid. The glenoid plane serves as reference for the measurements. The distance from the glenoid to the lateral border of the acromion increases when the glenoid is faced upwards and it decreases when the glenoid is oriented downwards (Fig. 4). When measured correctly, the AI and the critical shoulder angle both accurately predict the presence of degenerative rotator cuff tears.<sup>31,32</sup> The CSA, however, is in addition also significantly different between primary osteoarthritis and normal shoulders. This is not the case for the AI,<sup>33</sup> probably due to the joint space narrowing and the flattening of the humeral head in osteoarthritic shoulders.

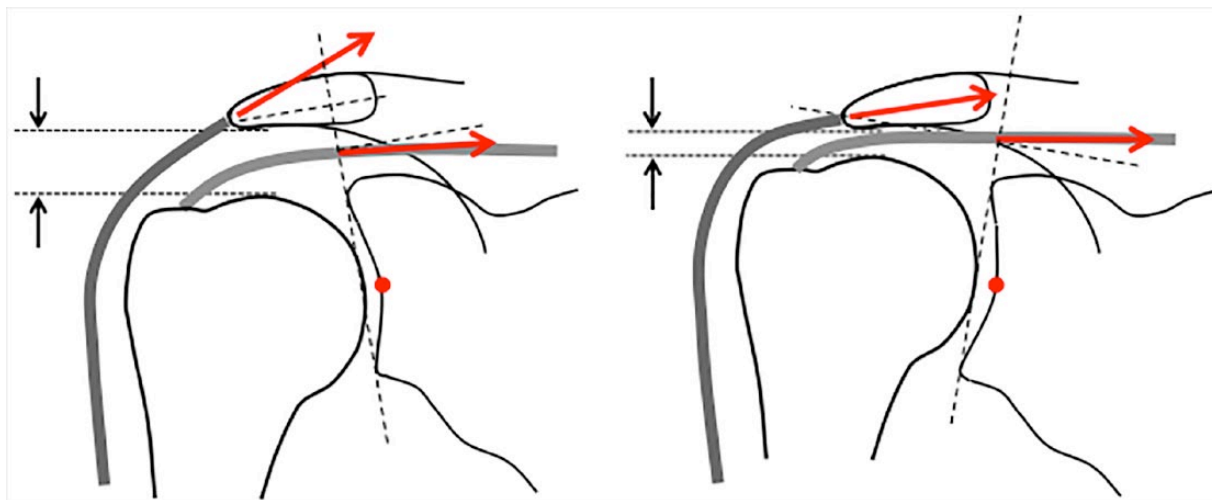
The lateral acromial angle is influenced by the inclination of the glenoid too. But as with the AI and the CSA, it

does not allow knowing the effective orientation of the glenoid relative to the transverse axis of the scapula or relative to the force vectors of the rotator cuff muscles. The lateral acromion angle is independent of the lateral extension of the acromion. Nevertheless, it seems to correlate with rotator cuff disease as well.

### Postulated patho-mechanism

It is thought that an unfavourable shape of the acromion initiates or at least contributes to the development of degenerative rotator cuff lesions. Neer noted that the coraco-acromial ligament and the anterior third of the acromion rub against the supraspinatus when the arm is abducted, thereby causing the rotator cuff to tear over time. This patho-mechanism may be responsible for bur-sal side tears but it does not explain the more frequently observed articular side partial tears.

Nyffeler et al postulated that the middle deltoid might play a major role.<sup>16</sup> Its fibres originate from the acromion and wind around the humeral head before inserting on the humeral shaft. Contraction of this muscle during active abduction pulls the humeral shaft upwards and presses the humeral head against the glenoid cavity. The relationship between the ascending and compressive force components depends on the deflection of the muscle. If the acromion projects far laterally, then the middle deltoid is almost straight, the ascending force component is high and the compressive force component is low. If the acromion is short, the deltoid is deflected and the



**Fig. 5** The acromio-humeral distance and the orientation of the force vectors of the deltoid and supraspinatus depend on the inclination of the glenoid. Upward inclination decreases the subacromial space, decreases the ascending force component of the deltoid and increases the ascending force component of the supraspinatus.

ascending force component decreases at the cost of the compressive force component (Fig. 5). These two components are equal for an AI of about 0.64. It was speculated that a high ascending force component favours subacromial impingement and degenerative changes of the supraspinatus tendon, whereas a high compressive force component favours degenerative changes of the glenohumeral joint. Terrier et al<sup>34</sup> conducted a 3D finite element study and confirmed that a large lateral extension of the acromion increases superior translation of the humerus during active elevation of the arm. In another finite element study, Engelhard et al<sup>35</sup> showed that medialisation of the acromion increases glenoid articular cartilage strain.

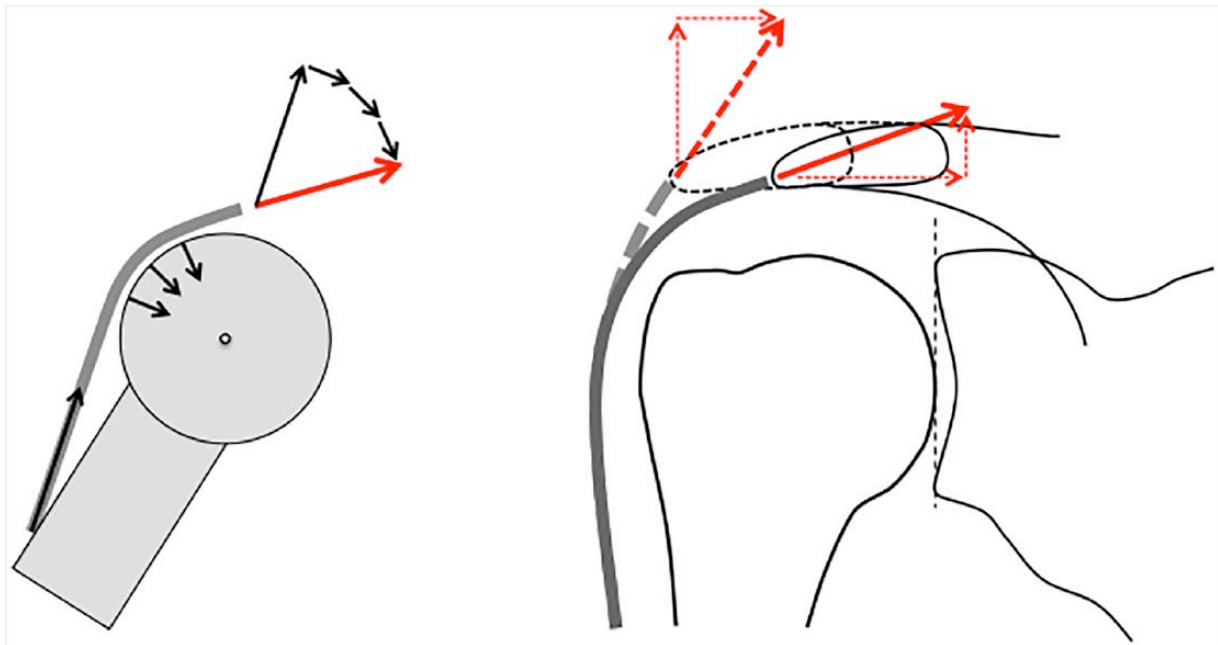
With use of a shoulder simulator, Gerber et al<sup>36</sup> determined how the lateral extension of the acromion influences the stability of the shoulder joint. They simulated a normal shoulder with a CSA of 33° and a shoulder ‘at risk’ for rotator cuff tear with a lateralised acromion and a CSA of 38°. In their experiments, the instability ratio was higher in the shoulder with the lateralised acromion. In order to stabilise the arm in space, the authors had to increase the supraspinatus force by 13% to 33%. They therefore concluded that a high CSA could induce supraspinatus overload. In another experiment, Moor et al<sup>37</sup> changed the CSA by changing the inclination of the glenoid. Tilting the glenoid upwards increased the shear joint force and therefore the instability ratio. They concluded that the increased compensatory activity of the rotator cuff to keep the humeral head centred may lead to mechanical overload and could explain the clinically observed association between large angles and rotator cuff tears.

Theoretically, turning the glenoid around its AP axis results in a superior or inferior displacement of the humeral

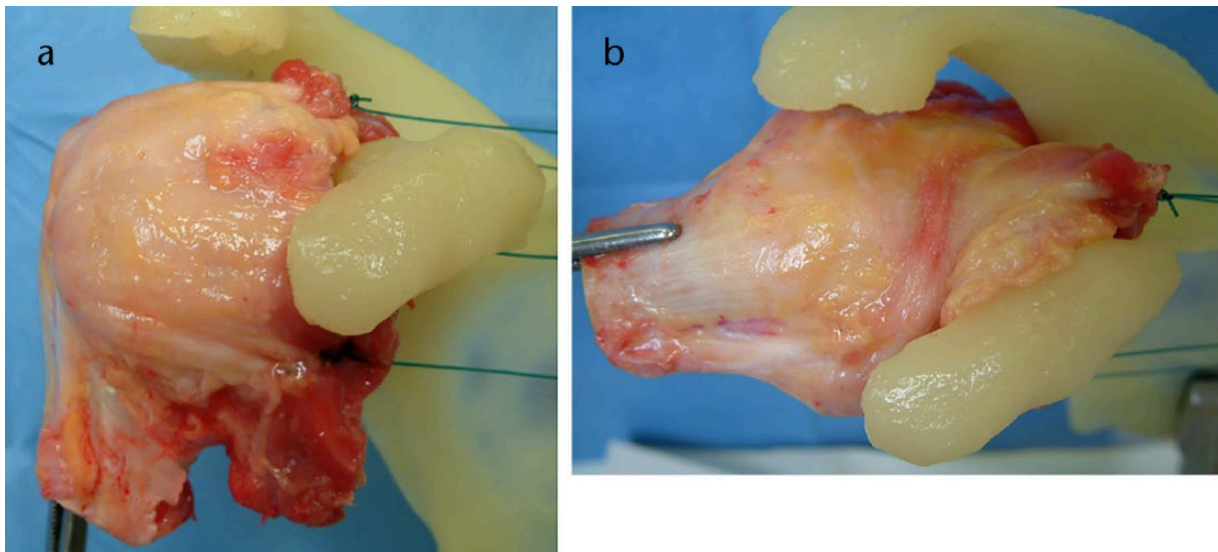
head of about 0.5 mm per degree of variation of glenoid inclination. Without concurrent elevation of the acromion, a superior inclination of the glenoid reduces the acromio-humeral distance and puts the supraspinatus tendon under pressure. Changing the inclination of the glenoid and therefore the position of the humeral head relative to the acromion also changes the orientation of the deltoid and supraspinatus force vectors (Fig. 6). The shear component of the supraspinatus is oriented downwards if the glenoid is tilted downwards and upwards if the glenoid is tilted upwards. In order to reduce the subacromial pressure and improve the joint stability in upwards tilted glenoids it would therefore be better, from a biomechanical point of view, to decrease the supraspinatus load and increase the force in the other, more downwards-oriented rotator cuff muscles. Several authors have shown that voluntary activation of specific muscle groups can influence the position of the humeral head on the glenoid and therefore the width of the subacromial space.<sup>38</sup> Further research is necessary to find out, if patients with upwards-oriented glenoids show different muscle activation patterns than patients with downwards-tilted glenoids.

#### Hypotheses

It is understandable that a sharp subacromial spur may cause an abrasion and tear of the supraspinatus tendon. However, it is not yet clear how a large acromion with a smooth undersurface may cause an articular side or a full-thickness rotator cuff tear. The authors of the present article hypothesise that these lesions are not the result of an increased load in the whole tendon but that they are caused by an alteration of the gliding capacities of the tendon fibrils within the tendon substance, leading to local



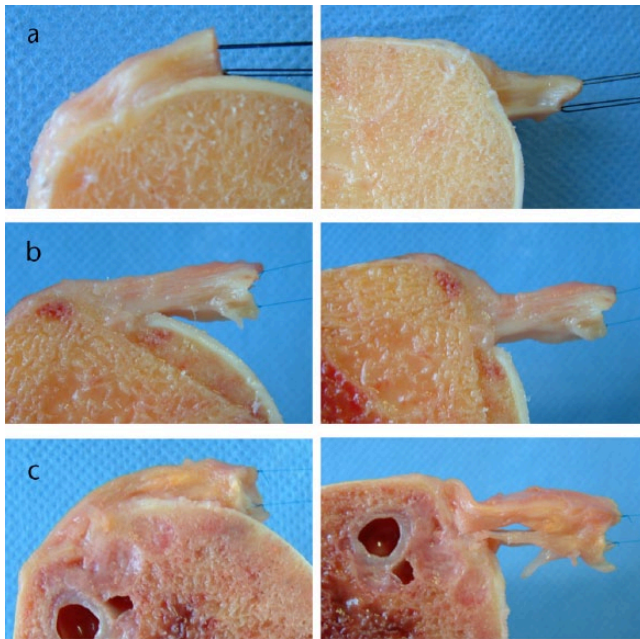
**Fig. 6** The lateral deltoid winds around the humeral head and therefore exerts not only an ascending force on the humeral shaft but also a compressive force on the humeral head. The resultant deltoid force (red vector) corresponds to the sum of these forces and is in line with the deltoid muscle fibres at their origin on the acromion. A large acromion is therefore associated with a high ascending force component and a short acromion with a high compressive force component.



**Fig. 7** Photographs of a cadaver shoulder specimen. The cuff was preloaded with use of thin sutures. Changing the position of the arm from adduction (a) to abduction and internal rotation (b) deformed the tendons.

stress concentration at the articular side of the cuff. Intact tendons of the rotator cuff are flexed, warped and twisted during rotation and elevation of the arm (Fig. 7). The supraspinatus and infraspinatus tendons are particularly affected by these deformations. To avoid any folds and wrinkles during such movements, the tendon fibrils must be able to glide against each other. Impairment of the

gliding mechanism may alter the strain distribution within the tendon. For example, during glenohumeral abduction the bursal side fibrils of the supraspinatus tendon must glide over the articular side fibrils (Fig. 8a). In an intact tendon this relative movement ensures adequate loading of the entire tendon. If gliding between the fibrils is hampered, the bursal-side portion of the tendon is folded and



**Fig. 8** Photographs showing the supraspinatus tendon stumps of three cadaver shoulders, in adduction (images on the left side) and in abduction (images on the right side). One specimen had a normal tendon (a), one specimen showed degenerative changes (b) and one specimen had a cleavage lesion (c). The tendons were cut in adduction, about 1.5 cm from their insertion on the greater tuberosity and perpendicular to the tendon surface, and they were preloaded with thin sutures on the bursal and articular side. In abduction, the cutting surface of the normal tendon was no longer perpendicular to the tendon surface, indicating that the superior fibrils glided over the inferior fibrils. In the other two specimens with degenerative changes the cutting surface did not change its orientation during abduction, indicating that the tendon fibrils could not glide against each other.

unloaded and the articular side portion is stretched and potentially overloaded during active abduction (Fig. 8b and 8c). Local stress concentration could result in local tendon failure and reduction of the tendon's cross-section. Decreasing the cross-section would increase the strength in the remaining tendon substance and therefore increase the risk for tear progression.

Why should a wide lateral extension of the acromion or a low lateral acromion angle alter the gliding capacity of the tendon fibrils? Repetitive compression and irritation of the postero-superior rotator cuff between the humeral head and the coracoacromial arch could initiate inflammatory reactions with structural changes and alterations of the mechanical properties of the tendon. Such reactions could also be triggered by other factors associated with degenerative rotator cuff tears, such as ageing, decreased vascularity, smoking and high cholesterol values. Further research is needed to confirm or reject these hypotheses.

## Procedures to correct an unfavourable shape of the acromion or glenoid

Different surgical procedures have been performed. Watson-Jones<sup>39</sup> introduced acromionectomy for the treatment of subdeltoid bursitis, supraspinatus calcifications and supraspinatus tendon tears. He routinely removed the lateral part or the whole acromion when he repaired a ruptured tendon. He stated that the excision of the bone ridge prevented later friction and recurrent rupture. Several other authors<sup>2,40</sup> performed an acromionectomy and reported good results concerning pain relief and function. The major complication was a secondary detachment of the deltoid muscle from the clavicle or the acromion, resulting in a weakness and deformity of the shoulder. Neer and Marberry<sup>41</sup> studied 30 consecutive patients who previously had a radical acromionectomy performed elsewhere. In total, 27 had pain, all had marked weakness of the shoulder and none could raise the arm above the horizontal. All objected to the appearance of the shoulder. The authors concluded that a radical acromionectomy weakened the deltoid both by removing its lever arm and by encouraging retraction of the origin of the muscles. Neer<sup>3</sup> therefore suggested that removing only the anterior edge and undersurface of the anterior part of the acromion with the attached coraco-acromial ligament is enough to decompress the cuff. This procedure became very popular and it is still performed by many shoulder surgeons. Other methods to decompress the subacromial space were proposed. Some surgeons performed a glenoid osteotomy and Grammont et al<sup>42</sup> made a translation-rotation-elevation osteotomy of the spine of the scapula. Although very effective, neither the glenoid osteotomy nor the osteotomy of the scapular spine found wide acceptance. As there is new knowledge of the relationship between a wide lateral extension of the acromion and rotator cuff tear, removing the lateral part of the acromion as previously reported by Watson-Jones has regained a certain interest. Some surgeons have started to shorten the acromion during rotator cuff repair. In open surgery, the risk for a secondary detachment of the deltoid can be minimised if the muscle is taken down with a bone chip and is re-attached transosseously with non-absorbable sutures. Placing the arm on an abduction splint after the operation decreases tension not only in the repaired rotator cuff but also in the re-attached deltoid muscle. Altintas et al<sup>43</sup> and Katthagen et al<sup>44</sup> showed in cadaver studies that the lateral part of the acromion can also be resected arthroscopically (ALAR arthroscopic lateral acromion resection) without damaging the deltoid insertion.



## Discussion

Pathologies of the rotator cuff concern a large part of the population. They often cause pain, alter the function of the shoulder, reduce the quality of life, and can significantly rise the cost of treatment. Torn tendons are often repaired. A lot of efforts have been made to improve the surgical technique and tendon healing. Nevertheless the re-tear rate remains high. This could be due to the fact, that the causes for the initial tear are not well known and therefore not eliminated during surgery. That's why it is crucial to understand the pathomechanism of rotator cuff degeneration and rotator cuff tear. The term degeneration is not well defined, but it certainly includes modifications of the microstructure and the mechanical properties. A deterioration of the deformability of the tendon could explain local stress concentration and local failure.

One factor inducing tendon degeneration could be an imbalance of the forces around the shoulder, due to an unfavourable shape of the acromion and the glenoid. Further studies are needed to determine the exact nature of tendon degeneration, and to find out whether shortening of the acromion could be used as a preventive measure to stop progression from early stage rotator cuff disease to rotator cuff tear.

### AUTHOR INFORMATION

<sup>1</sup>Orthopädie Sonnenhof, Buchserstrasse 30, 3006 Bern, Switzerland.

<sup>2</sup>Balgrist University Hospital, Forchstrasse 340, 8008 Zürich, Switzerland.

Correspondence should be sent to: Dr Richard W. Nyffeler, Orthopädie Sonnenhof, Buchserstrasse 30, 3006 Bern, Switzerland.  
Email: richard.nyffeler@bluwin.ch

### ICMJE CONFLICT OF INTEREST STATEMENT

None

### FUNDING

No benefits in any form have been received or will be received from a commercial party related directly or indirectly to the subject of this article.

### LICENCE

© 2017 The author(s)

This article is distributed under the terms of the Creative Commons Attribution-Non-Commercial 4.0 International (CC BY-NC 4.0) licence (<https://creativecommons.org/licenses/by-nc/4.0/>) which permits non-commercial use, reproduction and distribution of the work without further permission provided the original work is attributed.

### REFERENCES

- Codman EA.** *The shoulder: Rupture of the supraspinatus tendon and other lesions in or about the subacromial bursa.* Boston: Thomas Todd Co, 1934.
- Armstrong JR.** Excision of the acromion in treatment of the supraspinatus syndrome; report of 95 excisions. *J Bone Joint Surg [Br]* 1949;31-B:436-442.
- Neer CS II.** Anterior acromioplasty for the chronic impingement syndrome in the shoulder: a preliminary report. *J Bone Joint Surg [Am]* 1972;54-A:41-50.
- Watson M.** The refractory painful arc syndrome. *J Bone Joint Surg [Br]* 1978;60-B:544-546.
- Bigliani LU, Morrison DS, April EW.** The morphology of the acromion and its relationship to rotator cuff tears. *Orthop Trans* 1986;10:216.
- Park TS, Park DW, Kim SI, Kweon TH.** Roentgenographic assessment of acromial morphology using supraspinatus outlet radiographs. *Arthroscopy* 2001;17:496-501.
- Chambler AFW, Emery RJH.** Acromial morphology: the enigma of terminology. *Knee Surg Sports Traumatol Arthrosc* 1997;5:268-272.
- Natsis K, Tsikarakas P, Totlis T, et al.** Correlation between the four types of acromion and the existence of enthesophytes: A study on 423 dried scapulas and review of the literature. *Clin Anatomy* 2007;20:267-272.
- Chambler AFW, Bull AMJ, Reilly P, Amis AA, Emery RJH.** Coracoacromial ligament tension in vivo. *J Shoulder Elbow Surg* 2003;12:365-367.
- Aoki M, Ishii S, Usui M.** The slope of the acromion and rotator cuff impingement. *Orthop Trans* 1986;10:228.
- Zuckerman JD, Kummer FJ, Cuomo F, et al.** The influence of coracoacromial arch anatomy on rotator cuff tears. *J Shoulder Elbow Surg* 1992;1:4-14.
- Balke M, Schmidt C, Dedy N, et al.** Correlation of acromial morphology with impingement syndrome and rotator cuff tears. *Acta Orthop* 2013;84:178-183.
- Kitay GS, Iannotti JP, Williams GR, et al.** Roentgenographic assessment of acromial morphologic condition in rotator cuff impingement syndrome. *J Shoulder Elbow Surg* 1995;4:441-448.
- Banas MP, Miller RJ, Totterman S.** Relationship between the lateral acromion angle and rotator cuff disease. *J Shoulder Elbow Surg* 1995;4:454-461.
- Moor BK, Bouaicha S, Rothenfluh DA, Sukthankar A, Gerber C.** Is there an association between the individual anatomy of the scapula and the development of rotator cuff tears or osteoarthritis of the glenohumeral joint? A radiological study of the critical shoulder angle. *Bone Joint J* 2013;95-B:935-941.
- Nyffeler RW, Werner CM, Sukthankar A, Schmid MR, Gerber C.** Association of a large lateral extension of the acromion with rotator cuff tears. *J Bone Joint Surg [Am]* 2006;88-A:800-805.
- Torrens C, López JM, Puente I, Cáceres E.** The influence of the acromial coverage index in rotator cuff tears. *J Shoulder Elbow Surg* 2007;16:347-351.
- Miyazaki AN, Itoi E, Sano H, et al.** Comparison between the acromion index and rotator cuff tears in the Brazilian and Japanese populations. *J Shoulder Elbow Surg* 2011;20:1082-1086.
- Kim JR, Ryu KJ, Hong IT, Kim BK, Kim JH.** Can a high acromion index predict rotator cuff tears? *Int Orthop* 2012;36:1019-1024.
- Zumstein MA, Jost B, Hempel J, Hodler J, Gerber C.** The clinical and structural long-term results of open repair of massive tears of the rotator cuff. *J Bone Joint Surg [Am]* 2008;90-A:2423-2431.
- Balke M, Liem D, Greshake O, et al.** Differences in acromial morphology of shoulders in patients with degenerative and traumatic supraspinatus tendon tears. *Knee Surg Sports Traumatol Arthrosc* 2016;24:2200-2205.
- Hamid N, Omid R, Yamaguchi K, et al.** Relationship of radiographic acromial characteristics and rotator cuff disease: a prospective investigation of clinical, radiographic, and sonographic findings. *J Shoulder Elbow Surg* 2012;21:1289-1298.
- Blonna D, Giani A, Bellato E, et al.** Predominance of the critical shoulder angle in the pathogenesis of degenerative diseases of the shoulder. *J Shoulder Elbow Surg* 2016;25:1328-1336.

- 24. Cherchi L, Ciomohac JF, Godet J, Clavert P, Kempf JF.** Critical shoulder angle: measurement reproducibility and correlation with rotator cuff tendon tears. *Orthop Traumatol Surg Res* 2016;102:559-562.
- 25. Churchill RS, Brems JJ, Kotschi H.** Glenoid size, inclination, and version: an anatomic study. *J Shoulder Elbow Surg* 2001;10:327-332.
- 26. Hughes RE, Bryant CR, Hall JM, et al.** Glenoid inclination is associated with full-thickness rotator cuff tears. *Clin Orthop Relat Res* 2003;407:86-91.
- 27. Kandemir U, Allaire RB, Jolly JT, Debski RE, McMahon PJ.** The relationship between the orientation of the glenoid and tears of the rotator cuff. *J Bone Joint Surg [Br]* 2006;88-B:1105-1109.
- 28. Bishop JL, Kline SK, Aalderink KJ, Zuel R, Bey MJ.** Glenoid inclination: in vivo measures in rotator cuff tear patients and associations with superior glenohumeral joint translation. *J Shoulder Elbow Surg* 2009;18:231-236.
- 29. Maurer A, Fucentese SF, Pfirrmann CW, et al.** Assessment of glenoid inclination on routine clinical radiographs and computed tomography examinations of the shoulder. *J Shoulder Elbow Surg* 2012;21:1096-1103.
- 30. Daggett M, Werner B, Gauci MO, Chaoui J, Walch G.** Comparison of glenoid inclination angle using different clinical imaging modalities. *J Shoulder Elbow Surg* 2016;25:180-185.
- 31. Moor BK, Wieser K, Slankamenac K, Gerber C, Bouaicha S.** Relationship of individual scapular anatomy and degenerative rotator cuff tears. *J Shoulder Elbow Surg* 2014;23:536-541.
- 32. Pandey V, Vijayan D, Tapashetti S, et al.** Does scapular morphology affect the integrity of the rotator cuff? *J Shoulder Elbow Surg* 2016;25:413-421.
- 33. Kircher J, Morhard M, Gavriilidis I, et al.** Is there an association between a low acromion index and osteoarthritis of the shoulder? *Int Orthop* 2010;34:1005-1010.
- 34. Terrier A, Reist A, Nyffeler RW.** Influence of the shape of the acromion on joint reaction force and humeral head translation during abduction in the scapular plane. *J Biomech* 2006;39:582.
- 35. Engelhard C, Farron A, Becce F, et al.** Effects of glenoid inclination and acromion index on humeral head translation and glenoid articular cartilage strain. *J Shoulder Elbow Surg* 2017;26:157-164.
- 36. Gerber C, Snedeker JG, Baumgartner D, Viehöfer AF.** Supraspinatus tendon load during abduction is dependent on the size of the critical shoulder angle: A biomechanical analysis. *J Orthop Res* 2014;32:952-957.
- 37. Moor BK, Kuster R, Osterhoff G, et al.** Inclination-dependent changes of the critical shoulder angle significantly influence superior glenohumeral joint stability. *Clin Biomech (Bristol, Avon)* 2016;32:268-273.
- 38. Hinterwimmer S, Von Eisenhart-Rothe R, Siebert M, et al.** Influence of adducting and abducting muscle forces on the subacromial space width. *Med Sci Sports Exerc* 2003;35:2055-2059.
- 39. Watson-Jones R.** *Fractures and joint injuries*. Baltimore: The Williams and Wilkins Company, 1943.
- 40. Hammond G.** Complete acromionectomy in the treatment of chronic tendinitis of the shoulder. *J Bone Joint Surg [Am]* 1962;44-A:494-504.
- 41. Neer CS II, Marberry TA.** On the disadvantages of radical acromionectomy. *J Bone Joint Surg [Am]* 1981;63-A:416-419.
- 42. Grammont PM, Trouilloud P, Sakka M.** [Translation-rotation osteotomy. 1975-1985 experiences with anterior impingement and incomplete lesions of the rotatory cuff]. *Rev Chir Orthop Appar Mot* 1988;74:337-340. (In French)
- 43. Altintas B, Kääh M, Greiner S.** Arthroscopic lateral acromion resection (ALAR) optimizes rotator cuff tear relevant scapula parameters. *Arch Orthop Trauma Surg* 2016;136:799-804.
- 44. Katthagen JC, Marchetti DC, Tahal DS, Turnbull TL, Millett PJ.** The effects of arthroscopic lateral acromioplasty on the critical shoulder angle and the anterolateral deltoid origin: an anatomic cadaveric study. *Arthroscopy* 2016; 32:569-575.