

Saprochaete Capitata Infection in an 80-Year Old Chronic Obstructive Pulmonary Disease (COPD) Patient: A Case Report

Pham Ngoc Duan^{1,2}, Nguyen Nhu Hung³, Phong Tran Nhu⁴, Chu Dinh Thien⁵, Quang Canh Tran^{6*}

¹Department of Parasitology, Hanoi Medical University, Hanoi, Vietnam; ²Department of Microbiology and Parasitology, Hanoi Medical University Hospital, Hanoi, Vietnam; ³Department of Microbiology, 74 Hospital, Phuc Yen, Vinh Phuc, Vietnam; ⁴Faculty of Nursing, Dainam University, Hanoi, Vietnam; ⁵Institute for Research and Development, Duy Tan University, 03 Quang Trung, Danang, Vietnam; ⁶Center for Hygiene and Food Safety, Haiduong Medical Technical University, Hai Duong, Vietnam

Abstract

Citation: Duan PN, Hung NN, Nhu PT, Thien CD, Tran QC. Saprochaete Capitata Infection in an 80-Year Old Chronic Obstructive Pulmonary Disease (COPD) Patient: A Case Report. Open Access Maced J Med Sci. 2019 Dec 30; 7(24):4329-4332. https://doi.org/10.3889/oamjms.2019.385

Keywords: Saprochaete capitata; COPD; Fluconazole

***Correspondence:** Quang Canh Tran. Center for Hygiene and Food Safety, Haiduong Medical Technical University, Hai Duong, Vietnam. E-mail: tranquangcanh68@gmail.com

Received: 04-Sep-2019; **Revised:** 20-Nov-2019; **Accepted:** 21-Nov-2019; **Online first:** 20-Dec-2019

Copyright: © 2019 Pham Ngoc Duan, Nguyen Nhu Hung, Phong Tran Nhu, Chu Dinh Thien, Quang Canh Tran. This is an open-access article distributed under the terms of the Creative Commons Attribution-NonCommercial 4.0 International License (CC BY-NC 4.0)

Funding: This research did not receive any financial support

Competing Interests: The authors have declared that no competing interests exist

BACKGROUND: The fungal disease caused by invasive fungus *Saprochaete capitata* is becoming an increasingly popular infection. Fungal pathogens mainly occur in patients with immunocompromised disorders such as hematologic malignancies, acute myeloid leukemia, transplant patients.

CASE REPORT: In this study, we presented a COPD patient infected with *S. capitata*. At the first check, the patient showed cough, dyspnea, chest pain on both sides. The clinical laboratory test result was characterized with high White blood cell (12.8 G/L), HIV negative. The X ray showed bronchitis and emphysema. Bronchoscopy illustrated bronchial mucositis. CT scanner demonstrated pneumonia with fuzzy nodular lesions and thick interstitial organization in both lungs. The patient was treated with ciprofloxacin 800 mg/day; cefuroxime 2250 mg/day. However, the fever appeared 2 weeks thereafter. The *S. capitata* was discovered in the bronchial fluid. The patient was then treated with fluconazole 400 mg/day for 14 days. At the end of treatment, all signs and symptoms of *S. capitata* infection disappeared and the patient recovered.

CONCLUSION: This case study showed that *S. capitata* infection can occur in the COPD patients and fluconazole is a pertinent drug for treatment of the infection.

Introduction

Candida and *Aspergillus* spp. are mainly the causes of invasive fungal infections in hospitals. However, infection with rare fungal pathogens has become more popular in recent years. Infections caused by *Saprochaete capitata* are one of the emerging diseases. *S. capitata*, previously known as *Geotrichum capitatum*, *Trichosporon capitatum*, *Blastoschizomyces capitatus*, *Dipodascus capitatus*, is a non-fermentative, urease-negative ascomycetous yeast classified in Saccharomycetaceae family [1], [2], [3], [4], [5], [6], [7]. *S. capitata* fungus grows well in the Sabouraud agar, their colonies are similar to yeast, but their morphology characterizes with long and short segments with different sizes. This fungus is mainly found in natural environments such as soil, sand and wood pulp [8]. In addition, it has also been found in poultry feces, gastrointestinal tract, respiratory tract,

and is a part of the normal microflora of human skin [9]. They are known as the fungi that live in the respiratory tract and digestive tracts of humans, they are invasive pathogens like other yeast species [10].

S. capitata infection is mainly seen in patients with neutrophil leukemia (87%), more rarely in patients with other non-hematological diseases such as diabetes, neuralgia, organ transplantation and inflammations [11] (Table 1). In this report, we described a case of fungal infection caused by *S. capitata* in COPD patients.

Table 1: Some report cases cause by *Saprochaete capitata*

No.	Case	Age	Symptoms/ problems	Treatment	References
1	Acute myeloid leukemia	41	Erythema, high fever	caspofungin and liposomal amphotericin B	[12]
2	Kidney transplant	82	hypertensive nephrosclerosis	liposomal amphotericin B	[13]
3	Burkitt lymphoma	74	fever and central nervous system	fluconazole and caspofungin	[12]
4	Acute myeloid leukemia	57	Fever, diarrhoea and skin rash	levofloxacin and fluconazole	[14]
5	Pneumonia, asthma	86	shortness of breath, productive cough and fatigue	itraconazole	[15]

Clinical Case

An 80-year-old man was diagnosed with COPD and Gout 10 years ago. The patient came to the hospital with productive cough, dyspnea, chest pain on both sides a week before. Examination revealed symptoms including vesicular breathing, coarse crackle and wheeze in both lungs, no hypertension, non-diabetic, no fever. The laboratory blood test results were: Red blood cell 4.36 T/L, hematocrit 138 g/l, White blood cell 12.8 G/L (Lymphocyte 17.4% and Granulocyte 74.1%), HIV negative, Genxpert DPG (-), AFB (-). The X-ray showed bronchitis and emphysema. Bronchoscopy illustrated bronchial mucositis (Figure 1).

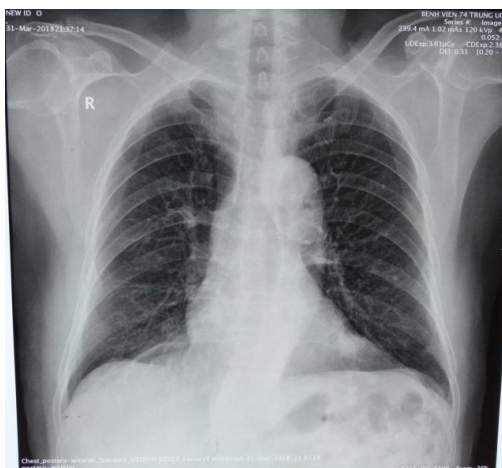


Figure 1: X – ray of patient before treatment

CT scanner demonstrated the pneumonia with fuzzy nodular lesions and thick interstitial organization in both lungs (Figure 2). The patient was treated with ciprofloxacin 800mg/day; cefuroxime 2250 mg/day; ventolin 40mg/ day; pulmicort 500mg; salbutamol 16mg/ day.

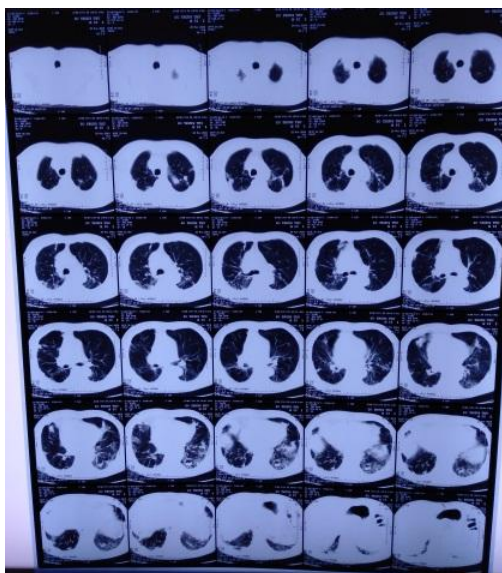


Figure 2: CT scan of the patient before treatment

After 2 weeks, cough and shortness of breath decreased, fever, however, developed. The patient was then treated with methylprednisolon 40 mg per day for 7 days. After the cease of drug, fever again developed. Therefore, the patient was treated with raxadin 2000 mmg + moxifloxacin 400 mmg + doxycyclin 1000 mmg per day for another 7 days. The patient was still feverish, tired, screeching and snoring was in both sides of the lung. The phlegm of patient was sampled and cultured to find fungi. *S. capitata* was detected by semi-automatic Vitek system (Figure 3 and 4), the blood cultured showed negative.

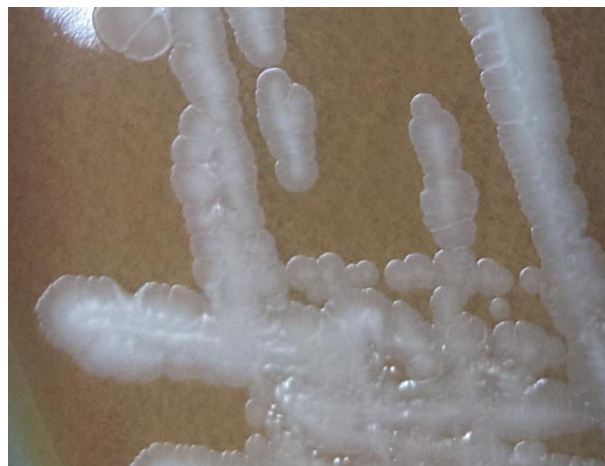

Figure 3: *Saprochaete capitata* on SAB media at 72 hour at 37°C

After 14 days of treatment with fluconazol 400 mg per day, the patient recovered and all the symptoms disappeared. The phlegm cultured showed negative.



Figure 4: *Saprochaete capitata* staining with lactophenol cotton blue under microscope (X 400)

Discussion

Saprochaete capitata has determined considerable taxonomic evaluation [16]. Evaluation of this fungus under microscopy showed the septal pores and cell wall structure with lots of arthroconidia and few blastoconidia [1]. In our case, *S. capitata* grow well on the Saboraud agar at 37°C, the colonies are similar to those of yeast. However, it is, with different dimensions of segments under microscope (Figure 4), similar to the filamentous fungi. Conventionally, detection of these fungi in the culture medium basing on their morphology is an important diagnosis. Using automatic or semi-automatic system may be a great choice. The Vitek 2 system version 07.01 was used to confirm *S. capitata*. This system has been shown to possess an accuracy rate of 98%. Besides, D 32C (bioMérieux), and RapID Yeast Plus (Innovative Diagnostic Systems) systems also were applied to diagnosis of this fungus [17], [18]. Unfortunately, their morphology is very similar to that of *S. clavata* [17].

S. capitata infection is becoming an emerging disease, particularly in immunocompromised such as haematological malignancies, associated cancer and onychomycosis [19]. Factors such as extended neutropenia, active chemotherapy, broad-spectrum antibiotics use and reduced local defense system by breaking down the skin and mucosa were mainly beneficial factors for this infection [20]. The haematological malignancy including acute leukemia is the disease in the most popular patients and estimated incidence is around 0.5% [1], [21]. Extremely, all of breaking through infections with acute leukemia developed in patients who were in intensive chemotherapy [1]. Moreover, broad spectrum antibiotic was used for treatment of all patients who developed neutropenic fever. The 30-day mortality is 30 days it related with invasive disease ranges from 60 – 80% [1]. In this case, the patient was treated with two antibiotics for 14 days. The symptoms decrease at the end of antibiotic treatment. However, the patient appeared fever in the afternoon. This case indicates the antibiotics ciprofloxacin and cefuroxime are not really effective with *S. capitata*. Positive blood culture was found in almost of case infection with 77.3%. While our case showed negative in blood culture. The pneumonia in *S. capitata* usually associated in haematological malignancies or multiple diseases. It could make the infection becomes more severe [15].

The in vitro study of susceptibility *S. capitata* is quite weak. Published literature showed that *S. capitata* is susceptible to flucytosine (MIC values 0.25-0.5 mg/mL), itraconazole (MIC values 0.12-0.50 mg/mL), voriconazole (MIC values 0.25-0.5 mg/mL) and posaconazole (MIC values 0.03-0.25 mg/mL). However, these organisms are less susceptible to fluconazole with a MIC between 16 and 32 mg/mL in most studies [3], [22], [23]. Amphotericin B was

effective in inhibition of these fungus only with high concentration (MIC values 0.5-2.0 mg/mL) [24]. *S. capitata* was demonstrated to intrinsically resist to echinocandins [25]. Girmenia et al. reported that amphotericin B, flucytosine, fluconazole, itraconazole, and voriconazole had high efficacy against *S. capitata* isolates. Other authors indicated that amphotericin B and voriconazole were more potent than other drugs in inhibition of *S. capitata* [23]. In these cases, demonstrated *S. capitata* reduce susceptible to anidulafungin at 8 mg/mL MIC value as expected. Fluconazole is less effective than itraconazole, voriconazole and azoles against *S. capitata*. The data of optimal treatment to *S. capitata* infection is not enough. In this infection indicated use of amphotericin B alone or in combination with flucytosine is a quality treatment. *S. capitata* infection treat with fluconazole and echinocandins were also quite good choice. Breakthrough infections of *S. capitata* reported in neutropenic patients collected echinocandins [7], [26], [27]. In our case, *S. capitata* was effectively treated with fluconazole 400 mg/day per 14 days, but it is need more evidence of MIC value. This case also demonstrates that antibiotic treatment of this infection only reduces some symptoms, but it is unable to thoroughly treat the infection. Identification of fungi is the most important for diagnosis and treatment.

In conclusion, *S. capitata* infected mostly to haematological malignancies patients, also with immunosuppressive and immunocompetent patients. In this case, the COPD patient was infected with *S. capitata*, treated with fluconazole 400 mg/day. The signs and symptoms disappeared after 2 weeks. The MIC of *S. capitata* should be do in the further study.

References

- Girmenia C, et al. Invasive infections caused by *Trichosporon* species and *Geotrichum capitatum* in patients with hematological malignancies: a retrospective multicenter study from Italy and review of the literature. *J Clin Microbiol.* 2005; 43(4):1818-28. <https://doi.org/10.1128/JCM.43.4.1818-1828.2005> PMID:15815003 PMCID:PMC1081342
- Kremery V, Krupova I, Denning DW. Invasive yeast infections other than *Candida* spp. in acute leukaemia. *J Hosp Infect;* 1999; 41(181). [https://doi.org/10.1016/S0195-6701\(99\)90015-4](https://doi.org/10.1016/S0195-6701(99)90015-4)
- Martino R, et al. *Blastoschizomyces capitatus* infection in patients with leukemia: report of 26 cases. *Clin Infect Dis.* 2004; 38(3):335-41. <https://doi.org/10.1086/380643> PMID:14727202
- Pemmaraju N, et al. Disseminated *Saprochaete capitata* (formerly known as *Geotrichum capitatum* and *Blastoschizomyces capitatus*) in a patient with acute myeloid leukemia. *Eur J Haematol.* 2014; 93(6):543-4. <https://doi.org/10.1111/ejh.12303> PMID:24592915
- Miceli MH, Diaz JA, Lee SA. Emerging opportunistic yeast infections. *Lancet Infect Dis.* 2011; 11(2):142-51. [https://doi.org/10.1016/S1473-3099\(10\)70218-8](https://doi.org/10.1016/S1473-3099(10)70218-8)
- Lafayette TC, et al. *Dipodascus capitatus* (*Geotrichum capitatum*): fatal systemic infection on patient with acute myeloid leukemia. *Rev Soc Bras Med Trop.* 2011; 44(5):648-50.

<https://doi.org/10.1590/S0037-86822011000500028>

PMid:22031088

7. Ozkaya-Parlakay A, et al. Geotrichum capitatum septicemia in a hematological malignancy patient with positive galactomannan antigen: case report and review of the literature. *Turk J Pediatr*. 2012; 54(6):674-8.

8. Arendrup MC, et al. ESCMID and ECMM joint clinical guidelines for the diagnosis and management of rare invasive yeast infections. *Clin Microbiol Infect*. 2014; 20(3):76-98.

<https://doi.org/10.1111/1469-0691.12360> PMid:24102785

9. Bouza E, Munoz P. Invasive infections caused by *Blastoschizomyces capitatus* and *Scedosporium* spp. *Clin Microbiol Infect*. 2004; 10(1):76-85. <https://doi.org/10.1111/j.1470-9465.2004.00842.x> PMid:14748804

10. Birrenbach T, et al. Emergence of *Blastoschizomyces capitatus* yeast infections, Central Europe. *Emerg Infect Dis*. 2012; 18(1):98-101. <https://doi.org/10.3201/eid1801.111192> PMid:22261201
PMid:PMC3310123

11. Cavanna C, et al. Fungemia due to *Saprochaete capitata* in a non-neutropenic patient hospitalized in an intensive care unit after cardiac surgery. *J Mycol Med*. 2017; 27(2):281-284.

<https://doi.org/10.1016/j.mycmed.2017.01.014> PMid:28302347

12. Garcia-Ruiz JC, et al. Invasive infections caused by *Saprochaete capitata* in patients with hematological malignancies: report of five cases and review of the antifungal therapy. *Rev Iberoam Micol*. 2013; 30(4):248-55.

<https://doi.org/10.1016/j.riam.2013.02.004> PMid:23583265

13. Hajar Z, Medawar W, Rizk N. *Saprochaete capitata* (*Geotrichum capitatum*), an emerging fungal infection in kidney transplant recipients. *J Mycol Med*. 2018; 28(2):387-389.

<https://doi.org/10.1016/j.mycmed.2018.04.005> PMid:29709266

14. Schuermans C, et al. Breakthrough *Saprochaete capitata* infections in patients receiving echinocandins: case report and review of the literature. *Med Mycol*. 2011; 49(4):414-8.

<https://doi.org/10.3109/13693786.2010.535179> PMid:21105848

15. Tanabe MB, Patel SA. *Blastoschizomyces capitatus* pulmonary infections in immunocompetent patients: case report, case series and literature review. *Epidemiol Infect*. 2018; 146(1):58-64.

<https://doi.org/10.1017/S0950268817002643> PMid:29198203

16. De Hoog GS, Smith MT. Ribosomal gene phylogeny and species delimitation in *Geotrichum* and its teleomorphs. *Stud Mycol*. 2004; 50:489-515.

17. Desnos-Ollivier M, et al. Misidentification of *Saprochaete clavata* as *Magnusiomyces capitatus* in clinical isolates: utility of internal transcribed spacer sequencing and matrix-assisted laser desorption ionization-time of flight mass spectrometry and importance of reliable databases. *J Clin Microbiol*. 2014; 52(6):2196-8.

<https://doi.org/10.1128/JCM.00039-14>

PMid:24696028 PMid:PMC4042774

18. Kolecka A, et al. Identification of medically relevant species of arthroconidial yeasts by use of matrix-assisted laser desorption ionization-time of flight mass spectrometry. *J Clin Microbiol*. 2013; 51(8):2491-500. <https://doi.org/10.1128/JCM.00470-13>
PMid:23678074 PMid:PMC3719645

19. Savini V, et al. Multidrug-resistant *Geotrichum capitatum* from a haematology ward. *Mycoses*. 2011; 54(6):542-3.

<https://doi.org/10.1111/j.1439-0507.2010.01894.x> PMid:20492528

20. Ersoz G, et al. An outbreak of *Dipodascus capitatus* infection in the ICU: three case reports and review of the literature. *Jpn J Infect Dis*. 2004; 57(6):248-52.

21. Christakis G, et al. Fatal *Blastoschizomyces capitatus* sepsis in a neutropenic patient with acute myeloid leukemia: first documented case from Greece. *Mycoses*. 2005; 48(3):216-20.

<https://doi.org/10.1111/j.1439-0507.2005.01098.x> PMid:15842341

22. D'Antonio D, et al. Emergence of fluconazole-resistant strains of *Blastoschizomyces capitatus* causing nosocomial infections in cancer patients. *J Clin Microbiol*. 1996; 34(3):753-5.

<https://doi.org/10.1128/JCM.34.3.753-755.1996> PMid:8904454

PMid:PMC228886

23. Girmenia C, et al. In vitro susceptibility testing of *Geotrichum capitatum*: comparison of the E-test, disk diffusion, and Sensititre colorimetric methods with the NCCLS M27-A2 broth microdilution reference method. *Antimicrob Agents Chemother*. 2003; 47(12):3985-8. <https://doi.org/10.1128/AAC.47.12.3985-3988.2003>
PMid:14638517 PMid:PMC296229

24. Subramanya Supram H, et al. Emergence of *Magnusiomyces capitatus* infections in Western Nepal. *Med Mycol*. 2016; 54(2):103-10. <https://doi.org/10.1093/mmy/myv075> PMid:26483432

25. Domenico D'Antonio FR, Lacone A, Violante B, Fazii P, Pontieri E, Staniscia T, Caracciolo C, Bianchini S, Sferra R, Vetuschi A, Eugenio Gaudio, Giuseppe Carruba, Onychomycosis Caused by *Blastoschizomyces capitatus*. *J Clin Microbiol*. 1999; 37(2927). <https://doi.org/10.1128/JCM.37.9.2927-2930.1999>
PMid:10449477 PMid:PMC85415

26. Chittick P, et al. Case of fatal *Blastoschizomyces capitatus* infection occurring in a patient receiving empiric micafungin therapy. *Antimicrob Agents Chemother*. 2009; 53(12):5306-7.

<https://doi.org/10.1128/AAC.00710-09> PMid:19738005

PMid:PMC2786321

27. Espinel-Ingroff A. In vitro activity of the new triazole voriconazole (UK-109,496) against opportunistic filamentous and dimorphic fungi and common and emerging yeast pathogens. *J Clin Microbiol*. 1998; 36(1):198-202.

<https://doi.org/10.1128/JCM.36.1.198-202.1998> PMid:9431946

PMid:PMC124833