



Preliminary Report

Micro-Autologous Fat Transplantation for Treating a Gummy Smile

Shu-Hung Huang, MD, PhD; Yu-Hao Huang, MD; Yun-Nan Lin, MD; Su-Shin Lee, MD; Chih-Kang Chou, MD, MS; Tsung-Ying Lin, MD; Hidenobu Takahashi, BS; Yur-Ren Kuo, MD, PhD; Chung-Sheng Lai, MD, PhD; Sin-Daw Lin, MD; and Tsai-Ming Lin MD, PhD

Aesthetic Surgery Journal 2018, Vol 38(9) 925-937 © 2018 The American Society for Aesthetic Plastic Surgery, Inc. This is an Open Access article distributed under the terms of the Creative Commons Attribution Non-Commercial License (http://creativecommons.org/licenses/by-nc/4.0/), which permits non-commercial re-use, distribution, and reproduction in any medium, provided the original work is properly cited. For commercial re-use, please contact journals.permissions@oup.com DOI: 10.1093/asj/sjy069 www.aestheticsurgeryjournal.com OXFORD UNIVERSITY PRESS

Abstract

Background: A gummy smile is treated using many techniques, including botulinum toxin injection and various surgical interventions. Micro-autologous fat transplantation (MAFT) is a potentially advantageous alternative approach that has not been previously evaluated.

Objectives: This study sought to determine the long-term results of MAFT in patients with a gummy smile.

Methods: Seven patients with gummy smiles were evaluated for MAFT treatment between October 2015 and April 2017. Centrifuged purified fat was micro-transplanted into the nasolabial groove, ergotrid, and upper lip areas using the MAFT-GUN while the patients were under total intravenous anesthesia.

Results: The mean age of the 7 patients was 31 years (range, 23-40 years). The mean operating time for MAFT was 52 minutes (range, 40-72 minutes), and the mean volume of fat delivered to the nasolabial groove, ergotrid, and upper lip was 16.1 mL. The mean decreases of gingival display in the right canine incisor, left canine incisor, right canine, and left canine teeth were 4.9, 4.6, 3.8, and 4.4 mm, respectively. The smiles of the 7 patients showed significant improvement at an average follow-up time of 12.9 months.

Conclusions: Gummy smile treatment using MAFT is an effective, reliable, and relatively simple method, with high patient satisfaction and minimal risk of complications.

Level of Evidence: 4

Editorial Decision date: March 9, 2018; online publish-ahead-of-print March 16, 2018.



The various features of the mouth play important roles in the appearance of a smile. The normal incisor shows 2-3 mm according to the description of Kerawala and Newlands.¹ In some individuals, extreme retraction of the

Plastic Surgeon, Division of Plastic Surgery, Department of Surgery, Kaohsiung Medical University, Kaohsiung, Taiwan. Dr T-Y Lin is a Traumatology Specialized Surgeon, Division of Traumatology, Department of Emergency, Kaohsiung Medical University. Drs Y-H Huang and C-K Chou are plastic surgeons in private practice in Kaohsiung, Taiwan. Mr Takahashi is a Medical Student, Department of Post Baccalaureate Medicine, Kaohsiung Medical University.

Corresponding Author:

Dr Tsai-Ming Lin, Charming Institute of Aesthetic and Regenerative Surgery, 2F.-1, No.172, Ziqiang 2nd Rd., Qianjin Dist., Kaohsiung City 801, Taiwan. E-mail: k79157@gmail.com

Dr S-H Huang is an Associate Professor, Division of Plastic Surgery, Department of Surgery, Kaohsiung Medical University Hospital and Department of Surgery, School of Medicine, College of Medicine, Kaohsiung Medical University, Kaohsiung, Taiwan. Drs Y-R Kuo, C-S Lai and S-D Lin are Professors, Dr S-S Lee is an Associate Professor, Dr T-M Lin is a Clinical Professor, and Dr Y-N Lin is a

lip, along with exposure of the incisors and a large portion of the gums, produces the so-called “gummy smile” or “horse smile.” There is variability in what is esthetically acceptable for gingival display in a smile. However, a gummy smile is defined as the exposure of more than 2 mm of the gums while a person is smiling.²⁻⁴ Etiologic factors can be skeletal, gingival, muscular, or iatrogenic, and may be present alone or in combination with each other.⁵ The literature contains several reports addressing the treatment of skeletal problems such as vertical maxillary excess,⁶⁻⁹ as well as gingival problems related to delayed passive eruption.¹⁰ The upper lip elevator muscles include the levator labii superioris, levator labii superioris alaeque nasi, levator anguli oris, zygomaticus major, zygomaticus minor, and depressor septi nasi. If these muscles are hyperfunctional, they can raise the upper lip and cause excessive gingival display. Several surgical procedures have been reported (with varying results and effects) to correct a gummy smile caused by hyperfunctional upper lip elevator muscles (most frequently, the levator labii superioris muscle).^{4,11-14}

Botulinum toxin has been under clinical investigation since the late 1970s for the treatment of severe conditions associated with excessive muscle contraction or pain.¹⁵ A nonsurgical option such as botulinum therapy for reducing excessive gingival display caused by muscle hyperfunction could be advantageous for the improvement of gummy smile.^{3,16-19} However, the lack of long-term efficacy with botulinum toxin makes repeated treatment necessary.

Neuber reported the first application of fat grafting in 1893.²⁰ This procedure has become common in many clinical applications because of the ease of fat harvesting, an abundant fat volume available, and lack of immune system rejection. However, the retention rates are unpredictable and morbidities such as abscess formation, cyst formation, nodulation, and neurovascular injury have been reported.^{21,22} Structural fat grafting has received extensive attention and the results have demonstrated acceptable clinical outcomes.²³ A group proposed the concept of micro-autologous fat transplantation (MAFT) in 2006 and illustrated the reliability of this technique in facial rejuvenation procedures.²⁴⁻³¹ In this study, we demonstrated favorable long-term results using the MAFT technique for correcting the gummy smile.

METHODS

Patient Demographics

Between October 2015 and April 2017, 7 patients (6 women, 1 man) underwent MAFT treatment for gummy smiles. The exclusion criteria included a history of facial trauma, comorbidities or surgery of the lip or maxilla, or botulinum toxin injection of the lip, gingival, or maxillary areas. Regular follow-up evaluations were conducted

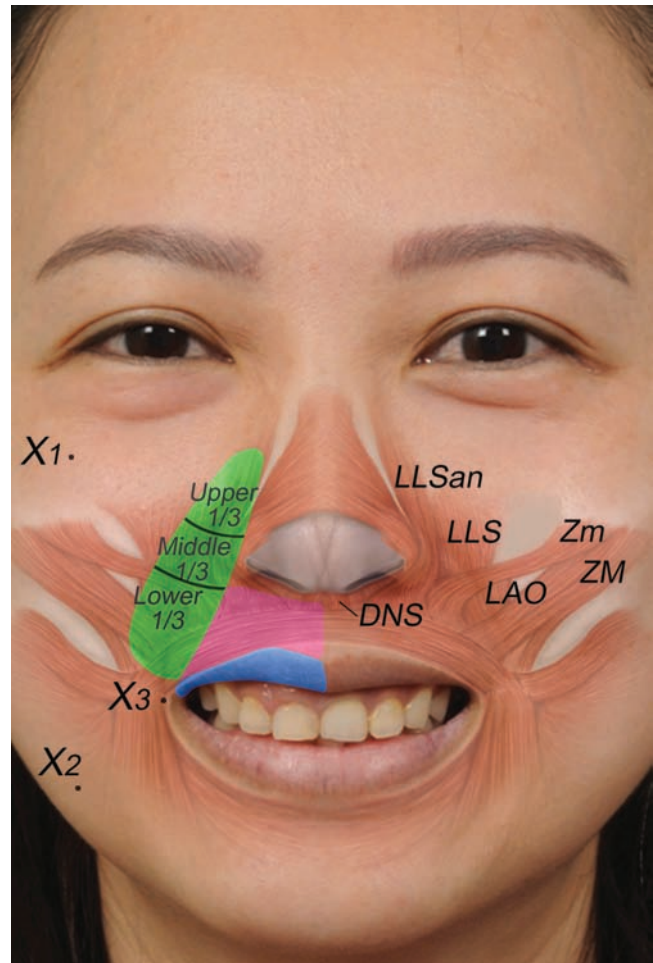
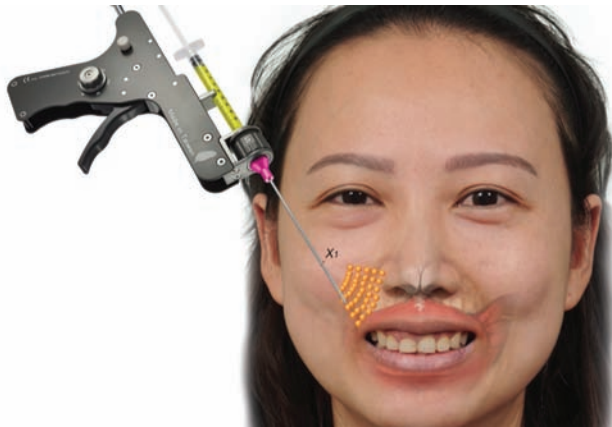


Figure 1. The surgical planning of micro-autologous fat transplantation for the treatment of gummy smile of this 36-year-old female. The recipient areas included the nasolabial groove (green), ergotrid (pink), and upper lip (blue). X1-3 were the insertion sites made by a #11 blade. LLS, levator labii superioris; LLSan, levator labii superioris alaeque nasi; LAO, levator anguli oris; ZM, zygomaticus major; Zm, zygomaticus minor; DNS, depressor septi nasi.

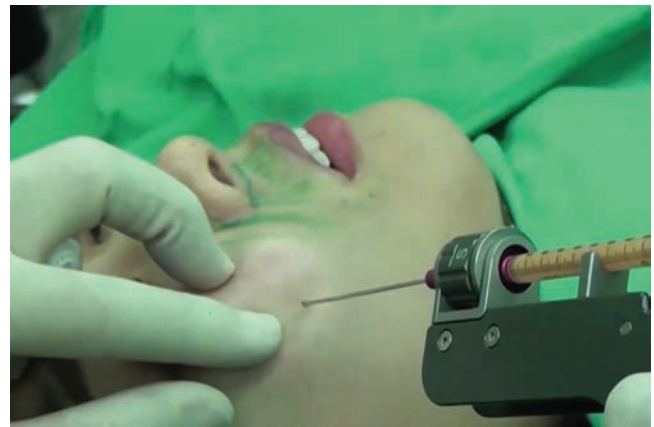at an outpatient clinic at 1, 3, and 6 months (or longer where possible) after MAFT. These studies were approved by the Institutional Review Board-I, Kaohsiung Medical University, Taiwan (KMUHIRB-E(1)-20180024) and are in accordance with the Helsinki Declaration.

Preoperative Planning and Photography

The patients underwent standard preoperative procedures and photography after providing signed consent. Other basic data, including the length of pre-MAFT gingival display, were recorded for both sides of the canine and canine incisor teeth for each patient. While standing, the surgical planning was conducted with the recipient areas outlined as shown in Figure 1.



Video 1. Micro-autologous fat transplantation (MAFT), nasolabial groove, ergotrid, upper lip, gummy smile. Watch now at <https://academic.oup.com/asj/article-lookup/doi/10.1093/asj/sjy069>



Video 2. Micro-autologous fat transplantation (MAFT), nasolabial groove, ergotrid, upper lip, gummy smile. Watch now at <https://academic.oup.com/asj/article-lookup/doi/10.1093/asj/sjy069>

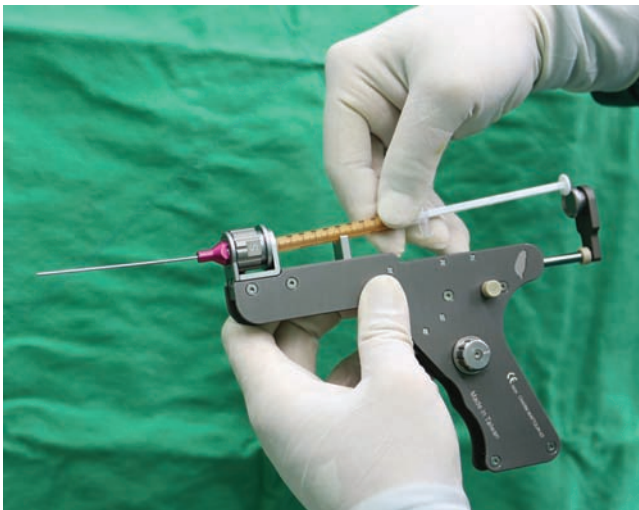


Figure 2. The purified fat was transferred to a 1 mL syringe and then loaded into the MAFT-GUN (Dermato Plastica Beauty Co., Ltd. Kaohsiung, Taiwan).

Anesthesiology and MAFT Procedure

The patients were placed under total intravenous anesthesia during the MAFT procedure.²⁴⁻³¹ The lipoaspirate was harvested mostly from the lower abdomen (or thigh) area after pre-infiltration with a tumescent solution. Appropriate local anesthesia was applied at the insertion sites for each patient (point X1-3 in Figure 1). In accordance with the “structural fat grafting” technique proposed by Coleman in 1998, the extracted lipoaspirate was processed and purified by standard centrifugation at 3000 rpm (approximately 1200 G) for 3 min.²³ After centrifugation, the purified fat was transferred to a 1 mL syringe and then loaded into a MAFT-GUN (Dermato Plastica Beauty Co., Ltd. Kaohsiung, Taiwan; Figure 2). The volume of the fat parcel (each aliquot) injected

by the trigger was set by adjusting the 6-grade dial to a setting of “120,” which corresponds to 1/120 mL (0.0083 mL). The fat parcels were meticulously transplanted in three portions into the nasolabial groove, ergotrid area, and upper lip (Figure 1, marked in green, pink, and blue, respectively). The maneuver for transplanting the fat graft is visually demonstrated in Figure 1 and in Videos 1-2). The following sections outline how the procedure was performed.

MAFT Maneuver Technique: Fat Parcels in the Nasolabial Groove

Using a #11 blade, a 2-3 mm incision was made in the mid-cheek region (Figure 1, X1 point). An 18-G blunt-tip side-hole injection cannula was vertically inserted through the incision until the bone was reached. Thereafter, we slid the cannula on top of the maxilla up to the lateral nostril area. The 6-grade volume knob of the MAFT-GUN was turned to “120” to inject a volume of 1/120 mL per parcel, per pull of the trigger. For the upper one-third of the nasolabial groove, we started from the deep layer where fat parcels were placed on top of the maxilla, and proceeded to inject fat parcels into the middle and superficial layers. More fat parcels were injected into the medial aspect of the nasolabial groove than into the lateral aspect to achieve a relatively uniform appearance. In the middle one-third of the nasolabial groove, we started from the deep layer where fat parcels were placed in the deep subcutaneous tissue and avoided penetrating into the oral cavity. We, thereafter, injected fat parcels into the middle and superficial layers. A bleached appearance was visible on the skin with the horizontal tilting of the injection cannula tip. This maneuver allows fat parcels to be placed more superficially (ie, just under the dermis of skin). In the lower one-third of the nasolabial groove, we applied the maneuver described for the middle one-third of the groove. We sequentially injected fat parcels into the deep, middle, and superficial layers.

Table 1. Patient Demographics

	Age, sex	Pre-MAFT gingival show#, mm				Post-MAFT gingival show#, mm				Decrease in gingival show#, mm				Fat graft volume, mL			Follow-up, months
		Rt	Lt	Rt	Lt	Rt	Lt	Rt	Lt	Rt	Lt	Rt	Lt	Nasolabial groove	Ergotrid Rt/Lt	Lip Rt/Lt	
		canine	canine	canine	canine	canine	canine	canine	canine	canine	canine	canine	canine	canine	Rt/Lt		
		incisor	incisor			incisor	incisor			incisor	incisor						
Case 1	29, F	3.5	3.5	2.8	2.0	-0.5	0.0	-0.5	0.0	4.0	3.5	3.3	2.0	3.0/4.0	2.0/2.0	1.0/1.0	24
Case 2	23, F	8.0	9.0	5.8	12.0	-1.0	1.5	0.0	2.5	9.0	7.5	5.8	9.5	3.0/3.0	4.0/4.0	1.5/1.5	15
Case 3	36, F	2.3	2.1	1.0	1.0	-1.5	-1.5	-2.0	-2.0	3.8	3.6	3.0	3.0	3.5/3.5	2.5/2.5	1.0/1.0	13
Case 4	24, M	7.0	6.5	7.5	6.5	2.3	2.5	1.2	1.0	4.7	4.0	5.3	5.5	4.0/4.0	5.0/5.0	-/-	13
Case 5	36, F	3.0	2.5	3.0	2.0	0.5	0.0	0.0	-0.5	3.5	2.5	3.0	2.5	6.0/6.0	3.0/3.0	1.0/1.0	11
Case 6	40, F	2.0	2.0	2.0	2.0	-1.5	-1.5	-1.0	-1.0	3.5	3.5	3.0	3.0	6.0/6.0	1.0/1.0	0.5/0.5	8
Case 7	29, F	3.5	6.5	2.0	4.5	-2.0	-1.0	-1.5	-1.5	5.5	7.5	3.5	6.0	5.0/5.0	3.0/3.0	0.75/0.75	6

#The measurements of gingival show were taken from the gum line at the midline of the canine incisors (right and left) and canines (right and left) to the lowest portion of the upper lip.

We injected from another insertion point (Figure 1, X2 point) at the mandibular border approximately 10 mm behind the prejowl sulcus to make a crisscross transplantation pattern. More fat parcels were injected into the medial aspect of the nasolabial groove than into the lateral aspect to achieve a relatively uniform appearance.

MAFT Maneuver Technique: Fat Parcels in the Ergotrid Area

Using a #11 blade, a 2-3 mm longitudinal incision was made approximately 2 mm lateral to the oral commissure (Figure 1, X3 point). The 6-grade volume knob of the MAFT-GUN was turned to "120" to inject a volume of 1/120 mL per parcel, per pull of the trigger. In the ergotrid area, we started injecting from the deep layer where fat parcels were placed in the deep subcutaneous tissue and avoided penetrating into the oral cavity. We then injected fat parcels into the middle and superficial layers.

MAFT Maneuver Technique: Fat Parcels in the Upper Lip

We centrally inserted an 18-G blunt-tip side-hole injection cannula through the incision (Figure 1, X3 point) in the vermillion border of the mouth angle, and advanced it to the tubercle and the contralateral side of the lip. The 6-grade volume knob of the MAFT-GUN was turned to "120" to inject a volume of 1/120 mL per parcel, per pull of the trigger. We commenced from the deep layer where fat parcels were placed in the central zone of the vermillion, and proceeded to inject more fat parcels into the middle layer; we tilted the injection cannula horizontally during the injection. Fat parcels were placed exterior to the central zone. Finally, we injected fat parcels into the superficial

layer. The side-hole director was turned to "N" (indicating the upward injection direction) to create a tenting effect during the injection. A bleached appearance was visible on the skin with the horizontal tilting of the injection cannula tip. This maneuver allows fat parcels to be placed more superficially (ie, just under the dry part of the vermillion). At the end of the procedure, all the incisions were sutured with one stitch of 6-0 nylon.

Post-MAFT Management and Evaluation

Regular posttreatment care, including the administration of oral antibiotics and non-steroidal anti-inflammatory drugs, was performed routinely for 3 days after the procedure. No massaging was performed immediately following the MAFT procedure. A gentle manual lymphatic drainage massage was performed 7 days after surgery to relieve swelling. In the last follow up visit, data including photography, the length of post-MAFT gingival display of both sides of the canine and canine incisor teeth, and the average of gingival display for each patient, were recorded.

RESULTS

The mean age of the 7 patients was 31 years (range, 23-40 years; Table 1). The entire MAFT procedure (from harvesting to transplantation) lasted an average of 52 minutes (range, 40-72 minutes), and the mean fat volume delivered was 16.1 mL (range, 13-20 mL). Patients were monitored for an average of 12.9 months (range, 6-24 months) and no major complications (eg, infection, skin necrosis, nodulation, fibrosis, calcification, asymmetry, or vascular insults)

were recorded. Mild to moderate swelling was noted over the operative areas but subsided after 7 to 10 days. The average of gingival display (average of both sides of the canine and canine incisor teeth) of seven patients all showed less than 2 mm (−0.25, 0.75, 1.75, 1.75, −0.25, −1.25, −1.50 mm, separately). They were all subjectively satisfied with the procedure and none requested follow-up work to refine the results. Four of these cases demonstrating MAFT for the treatment of a gummy smile are illustrated in [Figures 3-6](#) and [Video 3](#) is a record of the pre- and post-MAFT dynamic improvement of the gummy smiles.

DISCUSSION

Treatment of gummy smile includes surgical intervention of bony, gingival, or muscular abnormalities and non-invasive botulinum toxin injection.^{3,5,7-19} However, the abovementioned strategies have not been established as definitive treatments ([Table 2](#)).

Many unresolved issues exist for fat-grafting procedures. In particular, patient dissatisfaction may occur because of unpredictable absorption rates and potential morbidities, and there remains a lack of evidence regarding long-term outcomes.^{21,22} In 1993, Carpenada observed that only 40% of tissue at the area 1.5 ± 0.5 mm to the margin survived in fat grafting.³⁴ He emphasized that the central portion of a fat parcel with a radius larger than 2 mm will undergo necrosis due to insufficient direct diffusion and impaired plasmatic imbibition in the initial 24-48 hours after fat grafting.³⁴ The study also concluded that the percentage of graft viability depends on graft thickness and geometrical shape, and is inversely proportional to the graft diameter for grafts with a diameter greater than 3 mm.³⁵ Therefore, small aliquots are generally favorable in fat grafting, and the ideal radius of a fat parcel is between 1 and 2 mm. After describing “structural fat grafting,”²³ Coleman further stated that in specific areas such as the periorbital region (which has thinner skin), each delivered fat parcel should have a volume of 1/50 mL to 1/30 mL (0.020 to 0.033 mL, respectively) to avoid potential central necrosis and subsequent complications.³⁶

The previous study by Carpaneda determined that the ideal radius of a fat parcel is between 1 and 2 mm ([Supplemental Table 1](#)).³⁴ This work, along with a mathematical calculation, suggests that a favorable injection procedure for 1 mL of fat graft should involve 30 to 240 aliquots. This was presented as the central dogma of micro-autologous fat transplantation (MAFT) and was advocated by Lin et al ([Supplemental Table 1](#)).²⁴ The concept of MAFT, as proposed by Lin et al in 2007,²⁴ emphasizes that the volume of each delivered parcel should be less than 1/100 mL (<0.01 mL) to avoid potential fat-grafting morbidities. A spherically shaped fat parcel

with a radius of approximately 1.3 mm has a volume of 0.01 mL.²⁴⁻³¹ The MAFT-GUN³⁷ possesses a precise control mechanism that accurately and consistently delivers fat parcels at volumes of 1/60, 1/90, 1/120, 1/150, 1/180, and 1/240 mL. The MAFT-GUN, therefore, provides surgeons with a tool to control the parcel volume to avoid central necrosis and subsequent complications. The clinical results obtained using MAFT have demonstrated the feasibility of this approach and the importance of controlling the fat parcel size to achieve favorable outcomes.²⁵⁻³¹ Specifically, the accurate and consistent control of the fat parcel volume is critical in avoiding occasional dislodgement of larger parcels, which may result in nodulation and skin irregularity after fat grafting.

Ellenbogen and Swara applied a different approach to treat a gummy smile.³³ They utilized an implant made from silicon, Supramid, turbinate bone, and septal cartilage as a spacer.³³ They partially transected the levator labii superioris as far laterally as the ala extended. A packet was then made between the ends of the muscle for insertion of the spacer implant, which was intended to decrease excursion in the upward direction of the levator labii superioris. It is known that merely severing the levator labii superioris, as in a tethered lip operation, lowers the level of the lip in repose. Furthermore, with the weight and blocking effect of the spacer implant, the excursion of the lip during smiling remains restricted and the gummy smile improves. By a similar mechanism, the fat parcels delivered by MAFT in the nasolabial groove areas and ergotrid act as an “autologous tissue spacer,” not only to decrease the elevation function of the levator labii superioris, but also that of the neighboring lip elevator muscles including the levator labii superioris alaeque nasi, levator anguli oris, zygomaticus major, zygomaticus minor, and depressor septi nasi. The heavy weight of the fat parcels (the average delivered fat volume of 16.1 mL weighs approximately 14.8 g because the density of fat has been determined to be 0.9196 g/mL³⁸) forms a strong blockage while the upper lip elevator muscles contract during smiling. The fat parcels in the upper lip itself also behave like a spacer to decrease the impact of the elevator muscles while smiling. Finally, the increased vertical width of the upper lip and longitudinal elongation of the ergotrid due to fat grafting also have a camouflage effect to reduce the excessive gingival display during smiling.

While all patients in our series underwent only one MAFT procedure, a secondary touchup may be considered 4-6 months after the first procedure for those who desire additional improvement. Although the estimated fat retention rate in this study was not accurately measured, the overall results were good and fat survival appeared acceptable at the average follow-up time point (12.9 months). The long-term outcome

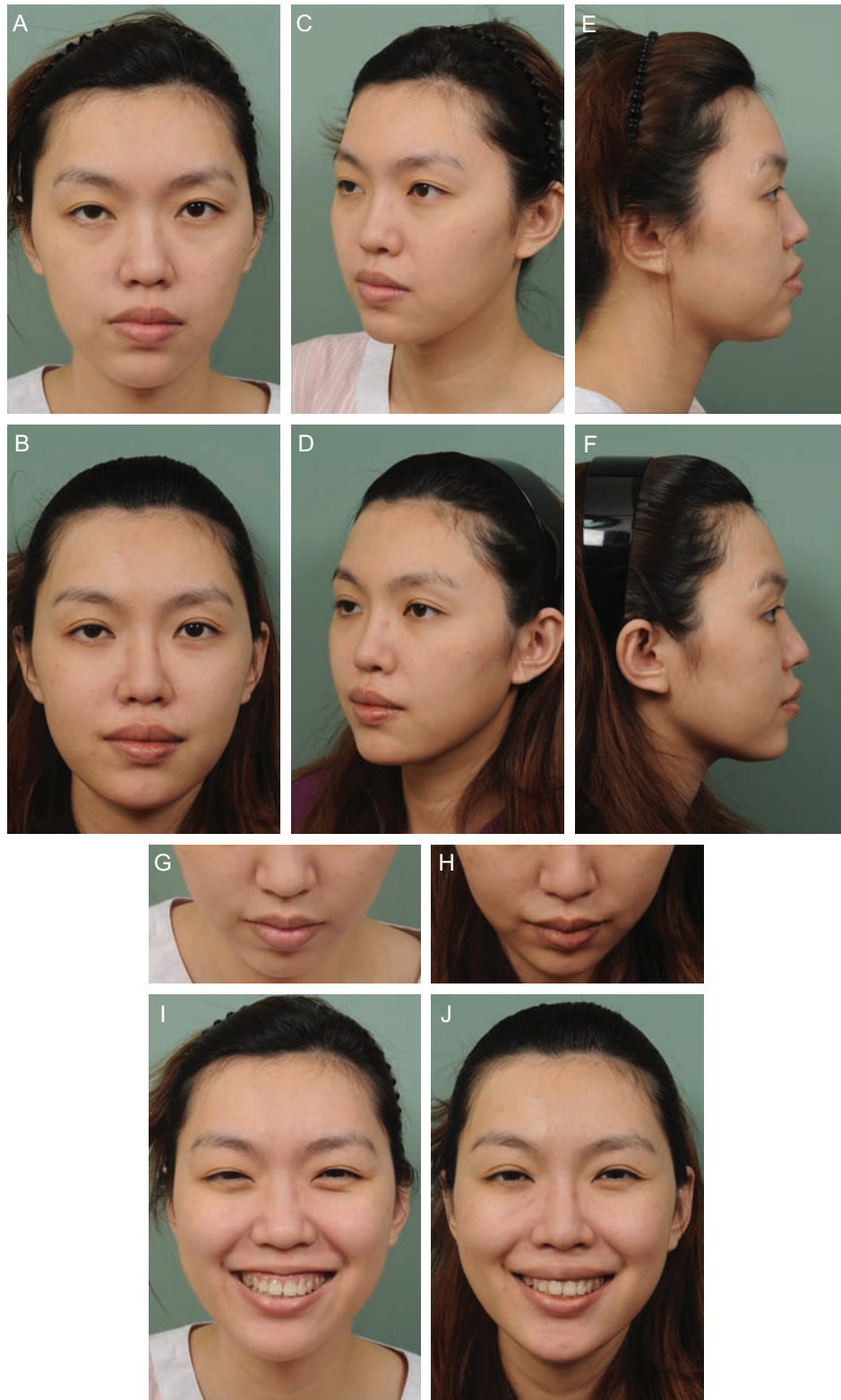

Figure 3. (A, C, E, G, I) This 29-year-old woman presented for fat grafting to improve her gummy smile. MAFT was performed for the placement of a 13-mL fat graft (right side/left side of the nasolabial groove, ergotrid, and upper lip: 3.0/4.0, 2.0/2.0, and 1.0/1.0 mL, respectively). (B, D, F, H, J) Twenty-four months after a single MAFT session, in repose, there was no obvious thickening or widening of her upper lip. However, during full smiling, the excessive gingival display (preoperative in 3I) was significantly improved (posttreatment in 3J) due to the increased thickness and width of the upper lip and the mild decreased strength of upper lip elevator muscles.



Figure 4. (A, C, E, G, I) This 23-year-old woman presented for the improvement of her severe gummy smile with fat grafting. MAFT was performed on her nasolabial groove, ergotrid, and upper lip areas with the placement of a 17-mL fat graft (right side/left side of the nasolabial groove, ergotrid, and upper lip: 3.0/3.0, 4.0/4.0, and 1.5/1.5 mL, respectively). (B, D, F, H, J) Fifteen months after a single MAFT session, the volume was maintained in repose demonstrated by the mild thickness of lip and the increased height of ergotrid. Her gummy smile was improved in successive degrees of smiling. The overexposed gingiva (preoperative in 4G) was significantly improved by increasing the vertical length of her ergotrid and the thickness/width of the upper lip (posttreatment in 4H). This is demonstrated by the level changing of a small nevus (indicated by black arrow) in the nasolabial groove (preoperative in 4I and posttreatment in 4J).

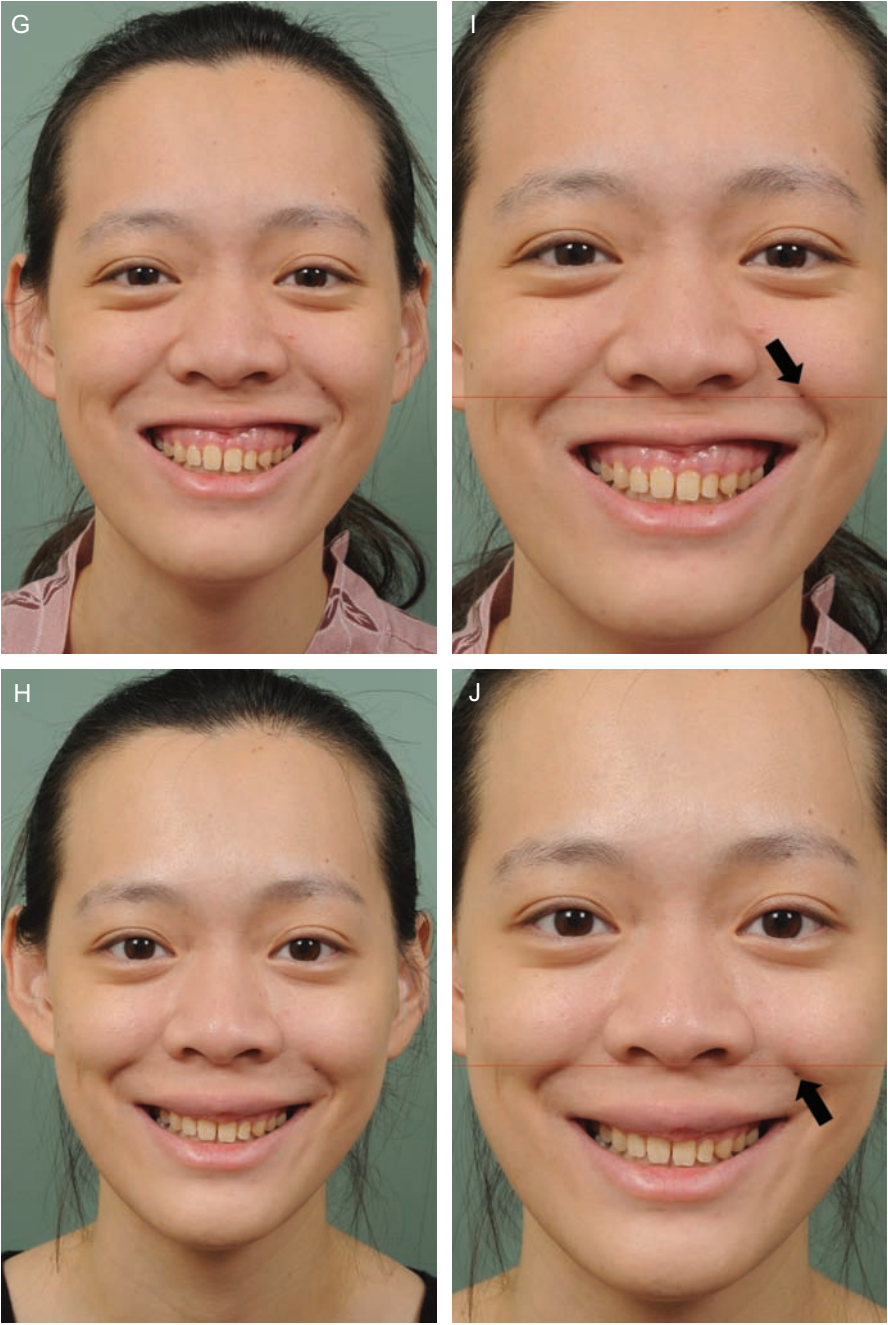

Figure 4. Continued



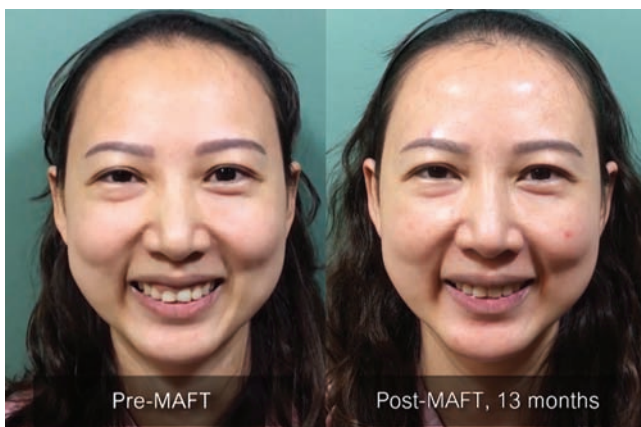
Figure 5. (A, C, E, G, I) This 36-year-old woman presented for fat grafting to improve her gummy smile. MAFT was performed with the placement of a 14-mL fat graft (right side/left side of the nasolabial groove, ergotrid, and upper lip: 3.5/3.5, 2.5/2.5, and 1.0/1.0 mL, respectively). (B, D, F, H, J) Thirteen months after a single MAFT session. Her improvement of gummy smile was maintained in successive degrees of smiling.




Figure 5. Continued



Figure 6. (A, C, E, G) This 24-year-old man presented for fat grafting to improve his gummy smile. MAFT was performed and an 18-mL fat graft was placed (right side/left side of the nasolabial groove and ergotrid: 4.0/4.0 and 5.0/5.0 mL, respectively). (B, D, F, H) Thirteen months after a single MAFT session, the improved appearance of his smile was maintained.



Video 3. Micro-autologous fat transplantation (MAFT), gummy smile. Watch now at <https://academic.oup.com/asj/article-lookup/doi/10.1093/asj/sjy069>

(up to 24 months) was reliable, as anticipated (Figure 3). From pre- and postoperative frontal, oblique and profile views, the natural contouring without any deformation further indicates that the retained fat volume does not interfere with facial appearance either in repose or in animation. Compared with the invasiveness of traditional surgical interventions⁷⁻¹⁴ and the prerequisite repeatability of botulinum toxin injection,¹⁵⁻¹⁹ the MAFT provided a simple, mini-invasive, effective, reliable and long-term strategy for a gummy smile (Table 2). The limitations of this study were that the patient satisfaction was subjective, total case numbers were not large and the exact retention volume of fat grafting was not provided. Therefore, further studies include a large number cases with longer follow-up time and the application of 3-dimensional volume measurement for fat retention rate should be mandatory.

Table 2. A Brief Review of Various Strategies to Treat a Gummy Smile

Authors	Year	Target site	Surgery/nonsurgical	Brief description of procedure	Necessity of repeat treatment	Comments of author
Dudeley and Colantino	1970 ³²	Bone	Surgery	Complete alveolar osteotomy to correct maxillary prognathism	No	Time-consuming, relatively disabling, and complicated.
Kostianovsky and Rubinstein	1973 ¹¹	Gingiva/mucosa	Surgery	An elliptical mucosal excision between the medial sides of two first bicuspid teeth about 3-4 mm above the upper anterior teeth	No	7/18 cases showed recurrence of disability. Resulting deformation due to elimination of the upper maxillary vestibule.
Fournier and Litton	1979 ¹²	Gingiva/mucosa	Surgery	As in Kostianovsky and Rubinstein	No	In some cases, the procedure could not achieve the needed amount of correction.
Miskinyar	1983 ¹³	Muscle	Surgery	Levator labii superioris (one or two) amputated at the junction with the orbicularis oris	No	None of the 27 cases showed recurrence of disability.
Ellenbogen and Swara	1984 ³³	Muscle	Surgery	Transection of the levator labii superioris with a spacer (custom-carved implant from silicone, Supramid, cartilage, or bone) placed in position	No	Implant rejection (Supramid) or ineffectiveness (bone)
Polo	2005 ⁵	Muscle	Nonsurgical	Botulinum toxin type A to treat the excessive upper lip elevator muscles contraction	Yes	Temporary impediment of gummy smiles caused by hyperfunctional upper lip elevator muscles.
Present study	2017	Soft tissue	Surgery (minimally invasive)	MAFT technique to delicately place fat grafting in the nasolabial groove, ergotrid, and upper lip to form a bio-barrier as a spacer to the lip levator muscles	No	Minimal change in repose and significant improvement in gummy smiling

CONCLUSIONS

Various strategies can be employed to treat a gummy smile. Botulinum toxin, while effective, does not seem suitable for all patients because of its short duration of action. Invasive surgeries involving management of bony, gingival, or lip elevator muscle abnormalities have complication risks that may not be acceptable for all patients. MAFT is a simple and reliable alternative strategy for improving the appearance of patients with a gummy smile.

In summary, this study presents the development of a simple and consistent procedure based on the MAFT technique for treating gummy smile. To our knowledge, this is the first report of autologous fat grafting for this application. Favorable outcomes were obtained in 7 cases with sustainable long-term effectiveness, further confirming that this strategy is an innovative alternative for the treatment of a gummy smile.^{5,11-13,32,33}

Supplementary Material

This article contains supplementary material located online at www.aestheticsurgeryjournal.com.

Disclosures

Dr Tsai-Ming Lin owns the patent rights of the MAFT-GUN and is a scientific adviser for Dermato Plastica Beauty Co., the manufacturer of the MAFT-GUN device. The other authors declared no potential conflicts of interest with respect to the research, authorship, and publication of this article.

Funding

The authors received no financial support for the research, authorship, and publication of this article.

REFERENCES

1. Kerawala C, Newlands C. Chapter 5: orthognathic surgery. In: Kerawala C, Newlands C, eds. *Oral and Maxillofacial Surgery*. United Kingdom: Oxford University Press; 2014:223.
2. Peck S, Peck L, Kataja M. Some vertical lineaments of lip position. *Am J Orthod Dentofacial Orthop*. 1992;101(6):519-524.
3. Mazzuco R, Hexsel D. Gummy smile and botulinum toxin: a new approach based on the gingival exposure area. *J Am Acad Dermatol*. 2010;63(6):1042-1051.

4. Ishida LH, Ishida LC, Ishida J, Grynglas J, Alonso N, Ferreira MC. Myotomy of the levator labii superioris muscle and lip repositioning: a combined approach for the correction of gummy smile. *Plast Reconstr Surg.* 2010;126(3):1014-1019.
5. Polo M. Botulinum toxin type A in the treatment of excessive gingival display. *Am J Orthod Dentofacial Orthop.* 2005;127(2):214-218; quiz 261.
6. Schendel SA, Eisenfeld J, Bell WH, Epker BN, Mishevich DJ. The long face syndrome: vertical maxillary excess. *Am J Orthod.* 1976;70(4):398-408.
7. Poulton DR. Surgical orthodontics: maxillary procedures. *Angle Orthod.* 1976;46(4):312-331.
8. Bell WH. Correction of maxillary excess by anterior maxillary osteotomy. A review of three basic procedures. *Oral Surg Oral Med Oral Pathol.* 1977;43(3):323-332.
9. Conley RS, Legan HL. Correction of severe vertical maxillary excess with anterior open bite and transverse maxillary deficiency. *Angle Orthod.* 2002;72(3):265-274.
10. Coslet JG, Vanarsdall R, Weisgold A. Diagnosis and classification of delayed passive eruption of the dentogingival junction in the adult. *Alpha Omegan.* 1977;70(3):24-28.
11. Rubinstein A, Kostianovsky A. Cosmetic surgery for the malformation of the laugh: original technique. *Prensa Med Argent.* 1973;60:952.
12. Litton C, Fournier P. Simple surgical correction of the gummy smile. *Plast Reconstr Surg.* 1979;63(3):372-373.
13. Miskinyar SA. A new method for correcting a gummy smile. *Plast Reconstr Surg.* 1983;72(3):397-400.
14. Ezquerria F, Berrazueta MJ, Ruiz-Capillas A, Arregui JS. New approach to the gummy smile. *Plast Reconstr Surg.* 1999;104(4):1143-1150; discussion 1151.
15. Brin MF, Hallett M, Jankovic J. Preface. In: Brin MF, Hallett M, Jankovic J, eds. *Scientific and Therapeutic Aspects of Botulinum Toxin.* Philadelphia: Lippincott Williams and Wilkins; 2002:v-vi.
16. Hwang WS, Hur MS, Hu KS, et al. Surface anatomy of the lip elevator muscles for the treatment of gummy smile using botulinum toxin. *Angle Orthod.* 2009;79(1):70-77.
17. Suber JS, Dinh TP, Prince MD, Smith PD. OnabotulinumtoxinA for the treatment of a "gummy smile". *Aesthet Surg J.* 2014;34(3):432-437.
18. Sucupira E, Abramovitz A. A simplified method for smile enhancement: botulinum toxin injection for gummy smile. *Plast Reconstr Surg.* 2012;130(3):726-728.
19. Nasr MW, Jabbour SF, Sidaoui JA, Haber RN, Kechichian EG. Botulinum toxin for the treatment of excessive gingival display: a systematic review. *Aesthet Surg J.* 2016;36(1):82-88.
20. Neuber F. Fettransplantation. *Bericht über die Verhandlungen der Deutschen Gesellschaft für Chirurgie Zbl Chir.* 1893;22:66.
21. Khawaja HA, Hernández-Pérez E. Fat transfer review: controversies, complications, their prevention, and treatment. *Int J Cosmet Surg Aesthetic Dermatol.* 2002;4(2):131-138.
22. Strong AL, Cederna PS, Rubin JP, Coleman SR, Levi B. The current state of fat grafting: a review of harvesting, processing, and injection techniques. *Plast Reconstr Surg.* 2015;136(4):897-912.
23. Coleman SR. Structural fat grafting. *Aesthet Surg J.* 1998;18(5):386, 388.
24. Lin TM, Lin SD, Lai CS. The treatment of nasolabial fold with free fat graft: preliminary concept of Micro-Autologous Fat Transplantation (MAFT). In: 2nd Academic Congress of Taiwan Cosmetic Association Taipei;2007; Taiwan.
25. Chou CK, Lin TM, Chou C. Influential factors in autologous fat transplantation - focusing on the lumen size of injection needle and the injecting volume. *J IPRAS.* 2013;9:25-27.
26. Lin TM, Lin TY, Chou CK, Lai CS, Lin SD. Application of microautologous fat transplantation in the correction of sunken upper eyelid. *Plast Reconstr Surg Glob Open.* 2014;2(11):e259.
27. Lin TM. Total facial rejuvenation with micro-autologous fat transplantation (MAFT). In: Pu LLQ, Chen YR, Li QF, Wei FC, eds. *Aesthetic Plastic Surgery in Asians: Principles and Techniques*, 1st ed. St. Louis, US: CRC Press; 2015:127-146.
28. Lin TM, Lin TY, Huang YH, et al. Fat grafting for recontouring sunken upper eyelids with multiple folds in Asians-novel mechanism for neoformation of double eyelid crease. *Ann Plast Surg.* 2016;76(4):371-375.
29. Kao WP, Lin YN, Lin TY, et al. Microautologous fat transplantation for primary augmentation rhinoplasty: long-term monitoring of 198 Asian patients. *Aesthet Surg J.* 2016;36(6):648-656.
30. Lee SS, Huang YH, Lin TY, et al. Long-term outcome of microautologous fat transplantation to correct temporal depression. *J Craniofac Surg.* 2017;28(3):629-634.
31. Chou CK, Lee SS, Lin TY, et al. Micro-autologous fat transplantation (MAFT) for forehead volumizing and contouring. *Aesthetic Plast Surg.* 2017;41(4):845-855.
32. Colantino RA, Dudley T. Correction of maxillary prognathism by complete alveolar osteotomy. *J Oral Surg.* 1970;28(7):543-548.
33. Ellenbogen R, Swara N. The improvement of the gummy smile using the implant spacer technique. *Ann Plast Surg.* 1984;12(1):16-24.
34. Carpaneda CA, Ribeiro MT. Study of the histologic alterations and viability of the adipose graft in humans. *Aesthetic Plast Surg.* 1993;17(1):43-47.
35. Carpaneda CA, Ribeiro MT. Percentage of graft viability versus injected volume in adipose autotransplants. *Aesthetic Plast Surg.* 1994;18(1):17-19.
36. Coleman SR. Structural fat grafting: more than a permanent filler. *Plast Reconstr Surg.* 2006;118(3 Suppl):108S-120S.
37. United States Patent, Patent No.: US 7,632,251 B2. 2009.
38. Farvid MS, Ng TW, Chan DC, Barrett PH, Watts GF. Association of adiponectin and resistin with adipose tissue compartments, insulin resistance and dyslipidaemia. *Diabetes Obes Metab.* 2005;7(4):406-413.