

# A new tool for bile duct tissue sampling: ex vivo clinical evaluation of intraductal cryobiopsy for cholangioscopy




## Authors

Lukas Wirsing<sup>1</sup>, Walter Linzenbold<sup>2</sup>, Simon U. Jaeger<sup>3,4</sup>, Phillip Stahl<sup>5</sup>, German Ott<sup>5</sup>, Tobias Leibold<sup>6</sup>, Markus Enderle<sup>2</sup>, Jörg Albert<sup>1</sup>, Jan Peveling-Oberhag<sup>1</sup>

## Institutions

- 1 Department of Gastroenterology, Hepatology and Endocrinology, Robert-Bosch-Hospital, Stuttgart, Germany
- 2 ERBE Elektromedizin GmbH, Tuebingen, Germany
- 3 Department of Clinical Pharmacology, University Hospital, University of Tuebingen, Tuebingen, Germany
- 4 Dr. Margarete Fischer-Bosch-Institute of Clinical Pharmacology (IKP), Stuttgart, Germany
- 5 Department of Clinical Pathology, Robert-Bosch-Hospital, Stuttgart, Germany
- 6 Department of Surgery, Robert-Bosch-Hospital, Stuttgart, Germany

submitted 29.9.2021

accepted after revision 3.3.2022

## Bibliography

Endosc Int Open 2022; 10: E809–E814

DOI 10.1055/a-1797-8966

ISSN 2364-3722

© 2022. The Author(s).

This is an open access article published by Thieme under the terms of the Creative Commons Attribution-NonDerivative-NonCommercial License, permitting copying and reproduction so long as the original work is given appropriate credit. Contents may not be used for commercial purposes, or adapted, remixed, transformed or built upon. (<https://creativecommons.org/licenses/by-nc-nd/4.0/>)


Georg Thieme Verlag KG, Rüdigerstraße 14,  
70469 Stuttgart, Germany

## Corresponding author

Jan Peveling-Oberhag, MD, Medizinische Klinik 1, Robert-Bosch-Krankenhaus, Auerbachstraße 110, 70376 Stuttgart, Germany

Fax: +49-711-8101-3793

[Jan.peveling-oberhag@rbk.de](mailto:Jan.peveling-oberhag@rbk.de)

 Supplementary material is available under  
<https://doi.org/10.1055/a-1797-8966>

## ABSTRACT

**Background and study aims** Indeterminate biliary strictures represent a major challenge in clinical diagnostics. Diagnostic yield of radiological, endoscopic imaging and histopathological diagnosis is insufficient. The cryobiopsy technique is a new method for tissue extraction already used in different clinical settings. The aim of this ex vivo clinical study was to investigate feasibility and tissue quality of cryobiopsy in the bile duct.

**Patients and methods** We included 14 patients who underwent pancreaticoduodenectomy. Bile duct samples were taken with either a new prototype cryoprobe or one of two forceps types. Results were analyzed for general feasibility, specimen size, histological assessability as well as representativity of retrieved tissue.

**Results** Feasibility of cholangioscopic forceps was poor compared to gastric biopsy forceps or cryobiopsy. Significantly larger tissue samples were obtained with cryobiopsy ( $5.6 \pm 4.5 \text{ mm}^2$ ) compared to gastric biopsy forceps ( $3.3 \pm 5.1 \text{ mm}^2$ ,  $P=0.006$ ). Furthermore, cryobiopsy was superior in histological assessment quality ( $P=0.02$ ) and concerning representativity ( $P=0.03$ ).

**Conclusions** Cryobiopsy in the bile duct is feasible and the quality of the obtained tissue is high. Further investigation of bile duct cryobiopsy in vivo is warranted.

## Introduction

Indeterminate biliary strictures (IBS) still pose a major challenge in endoscopic diagnostics today [1, 2]. Endoscopic retrograde cholangiopancreatography (ERCP) represents the standard procedure to obtain cytological/histopathological material within the bile duct [3]. Brush cytology and fluoroscopic guided

forceps biopsy are routinely used for this purpose [4]. However, inadequate sensitivity, as low as 45% is frequently reported for both methods [2].

Hence, different approaches to obtain tissue are being developed. Per oral cholangioscopy allows direct visualization of the biliary tract and targeted biopsies of the suspected area. However, recent studies still show moderate sensitivity [5].

Endoscopic ultrasound-guided fine-needle aspiration is also discussed as an uprising diagnostic modality with a varying spread of sensitivity [6]. Due to these insufficient outcomes, alternative methods are necessary to increase the sensitivity and diagnostic rate.

The cryobiopsy technique is a new method for tissue extraction which is already used in pneumology in clinical routine [7]. Its principle is based on the Joule-Thomson Effect, which causes a sudden cooling effect in the cryoprobes tip with an immediate attachment to the surrounding tissue by freezing to it [8, 9]. The cryoprobe can subsequently be extracted with the attached tissue.

The purpose of this ex vivo clinical study was to investigate the feasibility and tissue quality of cryobiopsy in comparison to standard biopsy forceps for retrieval of native and pathologically altered bile duct tissue.

## Patients and methods

This prospective study was approved by the Ethics Committee of the University Tuebingen (No. 495/2017BO2). Patients with suspected tumor or confirmed malignant obstruction of the common bile duct (CBD) or in the pancreatic region who underwent a pancreaticoduodenectomy were included. For each patient, written informed consent for participation in the study and for data protection was obtained before intervention.

A cryoprobe prototype (ERBE Elektromedizin GmbH, Tuebingen, Germany) with 160 cm in length and 1.1 mm in diameter was used for cryobiopsy. The cryoprobe was connected to a cryo device (ERBECRYO2, ERBE Elektromedizin GmbH, Germany) serving as gas supplier using carbon dioxide as cooling agent (► Fig. 1).


Two different forceps were used as control to perform biopsies; a standard cholangioscopic forceps (Medwork Endobite, Medwork GmbH, Hoechststadt an der Aisch, Germany) with a closed diameter of 1.8 mm and a standard gastric biopsy forceps (Boston Scientific Radial Jaw 4, Marlborough, Massachusetts, United States) with a closed diameter of 2.2 mm.

The explanted tissue contained parts of the pancreas, CBD, and duodenum. The CBD was incised lengthwise and fixated

with tweezers onto an underlayer to visualize the designated biopsy area. Either cryobiopsy or forceps biopsy was conducted. When cryobiopsy was performed, the probe was placed tangentially onto the incised bile duct and tissue could be retrieved with a quick pull on the probe. Activation time for cryobiopsy was varied between 1 and 6 seconds in initial experiments to optimize tissue retrieval. An activation time of three seconds was used for the majority of biopsies ensuring best specimen quality while causing least tissue damage. Obtained tissue samples were fixed in formalin, embedded in paraffin and subsequently stained in hematoxylin and eosin. The samples were analyzed and assessed by two experienced pathologists who were blinded to the biopsy method. The primary aim was to evaluate the specimen quality described by a histological assessment score using a 7-point Likert scale (see **Supplementary Table 1**) as has been also described previously [10]. Data were also collected and analyzed for feasibility (a biopsy attempt was feasible, if any specimen was obtained), specimen area (mm<sup>2</sup>) and representativity. Representativity was assessed qualitatively as the presence of evaluable bile duct epithelium to rule out malignancy or, in case of carcinoma, the presence of ample tumor cells and possible invasive growth allowing a definite diagnosis of malignancy. Discrepancies in the judgment of representativity were solved by case discussion between both pathologists. The sample area was determined by rendering the fixed tissue and automatically calculating the surface using the ZEN blue Edition software tool (Carl Zeiss Microimaging Goettingen, Germany).

## Statistical analysis

All data were analyzed with Graph Pad Prism Version 8 (Graph Pad Software, LCC) or R (R Core Team [2020]), using the tidyverse package, version 1.3.0. To calculate statistical significance, Mann-Whitney test, Wilcoxon test or Chi-square test were applied, depending on data type. Interobserver reliability for representativity was expressed by Cohen's kappa coefficient. All p-values are two-sided and  $P < 0.05$  was considered as statistically significant. To correct for multiple comparisons, the Bonferroni–Holm method was applied. A post hoc power analysis was performed deriving from the current study data. Effect size was calculated where comparable biopsy pairs were available (ten pairings of cryobiopsy vs. gastric biopsy forceps). As effect measure, the difference in mean size of the histologic specimens retrieved by each method in each patient was used. Power calculation was performed with the `power.t.test` function in R. The mean paired difference between size of cryobiopsy and gastric biopsy forceps was 3.2 mm<sup>2</sup>, with a standard deviation of 4.8. With  $n = 10$  pairs, a delta of 0.667 and a significance level of 0.05, the power was approximately 47%. Because this was not a randomized study a post hoc analysis was performed to detect bias in the chronological order of biopsy attempts. Every biopsy attempt per patient was ranked according to its chronological order and mean ranks per patient and instrument were calculated. Median rank for attempts compared in the analysis with the gastric biopsy forceps was 5.0, while cryobiopsy attempts had median rank of 4.0 ( $P = 0.089$ ). Therefore, although the distribution of biopsy attempts was not com-



► Fig. 1 Representative picture of cryo device and cryoprobe (tip of the probe shown in magnified view)

► **Table 1** Clinical data from patients.

Patient	Gender	Age at resection	Histology/tumor	Biopsy attempts successful and overall taken biopsies
1	Female	69	Pancreatic carcinoma	3/3
2	Female	79	Pancreatic carcinoma	0/6
3	Male	61	Pancreatic carcinoma	4/9
4	Female	77	Pancreatic carcinoma	3/6
5	Male	76	Pancreatic carcinoma	5/8
6	Female	56	Cholangiocellular carcinoma	4/7
7	Male	76	Pancreatic carcinoma	4/7
8	Male	83	Pancreatic carcinoma	5/10
9	Male	64	Ampullary adenocarcinoma	4/10
10	Female	50	Chronic pancreatitis	6/9
11	Male	60	Neuroendocrine tumor	5/9
12	Male	82	Pancreatic carcinoma	2/9
13	Male	84	Cholangiocellular carcinoma	9/9
14	Male	74	Cystadenoma	3/10

pletely equal between patients and biopsy technique, there was likely no statistical bias introduced.

## Results

### Population

A total of 14 patients (9 male/5 female) with a mean age of 70.8 years (range: 50 to 84) were included in this study. Final histologic assessment confirmed pancreatic cancer for eight patients, two had cholangiocellular carcinoma, one was diagnosed with ampullary adenocarcinoma, one with chronic pancreatitis, one with neuroendocrine tumor, and one with cystadenoma without any proof of dysplasia. Clinical patient data are summarized in ► **Table 1**.

### Feasibility of ex vivo biopsies

A total of 112 biopsy attempts with either cryobiopsy, cholangioscopic forceps or gastric biopsy forceps were evaluated (► **Fig. 2a**). Fifty-seven (50.9%) of these were successful, meaning tissue particles could be retrieved from the bile duct (► **Table 2**). Another ten tissue samples were excluded from the analysis of size and assessability due to a lack of histopathological evaluable material (either technical error or missing evaluable bile ducts within the specimen, ► **Fig. 2a**). Attempts with cholangioscopic forceps showed an especially low success rate (20.7% [6/29]). Therefore, gastric biopsy forceps (success rate of 69.7% [23/33]) was additionally performed as an alternative biopsy modality to allow a meaningful comparison. There was no statistically significant difference between the success rate of cryobiopsy (56% [28/50]) and gastric biopsy forceps ( $P=0.31$ ). Because only three cholangioscopic forceps biopsies from a single patient could be fully evaluated, this modality was excluded from further comparisons.

In the subgroup with pathologically altered areas (bile duct with overt tumor infiltration), biopsies could be obtained successfully in 50% of patient (3/6) with cholangioscopic forceps, 55.5% (5/9) with gastric biopsy forceps, and 81.8% with cryobiopsy (9/11) with no significant difference between the groups.

### Histopathological specimen size

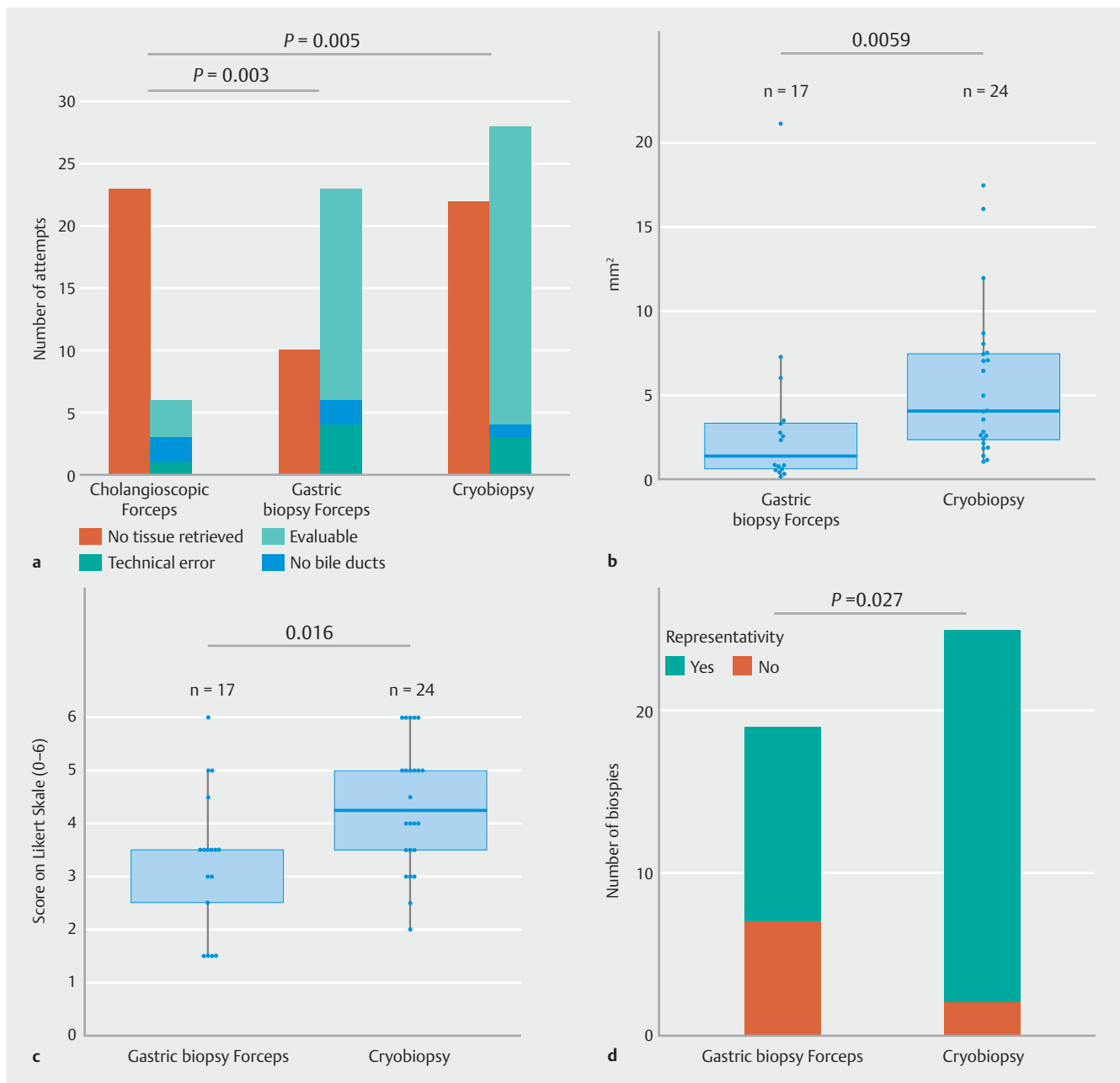
Mean specimen area obtained by gastric biopsy forceps was  $3.3 \pm 5.1 \text{ mm}^2$  and  $5.6 \pm 4.5 \text{ mm}^2$  for cryobiopsy. The specimen area of cryobiopsy was significantly larger compared to gastric biopsy forceps ( $P=0.0059$ ) (► **Fig. 2b**). A representative image of the automated size measurement from cryobiopsy is shown in **Supplementary Fig. 2a**.

### Histological assessment

Mean histological assessment quality score was  $3.29 \pm 1.34$  and  $4.35 \pm 1.20$  for gastric biopsy forceps and cryobiopsy, respectively ( $P=0.016$ , ► **Fig. 2c**).

### Representativity

There was a good agreement between the two pathologists' evaluations (Agreement 87.5%, Cohen's Kappa of 0.69). Three tissue samples were excluded from the above-mentioned analysis of specimen size and histological assessability due to a lack of evaluable bile duct tissue. These samples were counted as not representative in this comparison in analogy to an intention to treat analysis. Of 19 obtained samples for gastric biopsy forceps 12 (63%) were evaluated as representative by both pathologists. Twenty-three of 25 samples of cryobiopsy (92%) were representative ( $P=0.027$ ; ► **Fig. 2d**). **Supplementary Fig. 2b** and **Supplementary Fig. 2c** show examples of histological sections for gastric biopsy forceps and cryobiopsy.



► **Fig. 2** **a** Number of biopsy attempts for each instrument (no tissue retrieved, red; evaluable for all subsequent analyses, green; technical error during processing, blue; no evaluable bile ducts within the histopathological specimen, purple). **b** Measured areas of tissue samples (cryobiopsy vs. gastric biopsy forceps). Scatter blots including individual datapoints and boxes displaying medians, 25th and 75th percentiles, and whiskers extending to 1.5 of interquartile range. **c** Histological assessment by two independent histopathologists according to the histopathological assessability score (evaluation see **Supplementary Table 1**, cryobiopsy vs. gastric biopsy forceps). Scatter blots including individual datapoints and boxes displaying medians, 25th and 75th percentiles, and whiskers extending to 1.5 of interquartile range. **d** Number of representative results (cryobiopsy vs. gastric biopsy forceps, representative yes in red and no in blue). Representativity was assessed qualitatively by two expert pathologists. Representativity was defined as the presence of ample evaluable bile duct epithelium to rule out malignancy or, in case of carcinoma, the presence of ample tumor cells and possible invasive growth allowing a definite diagnosis of malignancy.

## Discussion

IBS are challenging, therefore, different biopsy techniques are required to improve sensitivity [1, 2, 11]. One of those could be cryobiopsy. Several studies have demonstrated that cryobiopsy is diagnostically superior to conventional biopsy techniques such as forceps e.g. for lung biopsy [12, 13].

In our study, the average sample area was significantly larger for cryobiopsy although this difference was less pronounced than in other reports with similar cryoprobe dimensions [9, 10, 14]. One explanation could be that the gastric biopsy forceps used in the current study has a far wider opening diameter compared to bronchoscopic or cholangioscopic forceps. Fur-

► **Table 2** Clinical data from patients II (distribution biopsy attempts).

Method	Cryobiopsy attempts successful/overall	Cholangioforceps biopsy attempts successful/overall	Gastric biopsy forceps biopsy attempts successful/overall	Total biopsy attempts per patient successful/overall
<b>Patient</b>				
1	3/3	0/0	0/0	3/3
2	0/3	0/3	0/0	0/6
3	3/4	1/5	0/0	4/9
4	0/3	0/0	3/3	3/6
5	3/5	0/0	2/3	5/8
6	3/4	0/0	1/3	4/7
7	3/4	0/0	1/3	4/7
8	3/4	0/3	2/3	5/10
9	3/4	0/3	1/3	4/10
10	2/3	1/3	3/3	6/9
11	1/3	1/3	3/3	5/9
12	1/3	0/3	1/3	2/9
13	3/3	3/3	3/3	9/9
14	0/4	0/3	3/3	3/10
Total	28/50	6/29	23/33	57/112

thermore, in our current study only comparatively low activation times of the cryobiopsy were used as damage to the tissue had to be prevented for further processing. Higher activation times would yield larger specimens, but on the other hand, if activation time is too high, specimens could potentially be too large to be retrieved through the working channel of the cholangioscope and hence would have to be extracted together with the cholangioscope, as is routinely done during bronchoscopic procedures [15]. In addition, longer activation times could risk bile duct perforation and bleeding complications during the procedure, although histological evaluation showed no signs of severe damage to the subepithelial tissue while performing cryobiopsy. Based on the design of this ex vivo feasibility study we are unable to draw conclusions about complications during the diagnostic procedure. This has to be addressed in further studies.

During the current study, the low success rate of cholangioscopic forceps biopsies (20.7%) was surprising; however, this limitation is in line with our own clinical observations. The tiny cholangioscopic forceps grasps only a very limited amount of tissue and often is unable to penetrate the firm surface of the bile duct and its tight connective tissue. By trend, gastric biopsy forceps surpassed cryobiopsy in tissue acquisition from healthy biliary epithelium. Likely, the serrated surface of the gastric biopsy forceps assists in grabbing tissue from the firm surface of the bile ducts in comparison to the plane surface of the cholangioscopic forceps or cryobiopsy.

Nevertheless, both, representativity and histological assessment were significantly larger for cryobiopsy compared to gas-

tric biopsy forceps, especially from malign lesions, possibly due to the scattered surface area compared to unaltered tissue. However, due to the low numbers of included patients with tumor infiltration (only three patients were included in the subgroup of patients with pathologically altered areas) our conclusion concerning tumor patients is only of observatory nature.

Low case numbers overall can be discussed as further limitation of this study. The main target was to investigate general feasibility of cryobiopsy in the human bile duct. Therefore, an intended number of 15 cases was defined as sufficient to draw conclusions about feasibility. Also, as this was a single-center study, cases of patients who underwent pancreaticoduodenectomy were limited.

All experiments were performed on an imposed bile duct after lengthwise incision and fixation to allow for a more standardized comparison of histopathological representativity. Therefore, the overall clinical challenge of improving the diagnostic yield in IBS was not specifically addressed by our current study. The different biopsy techniques ideally have to be compared during cholangioscopy or fluoroscopic guided biopsy of intrahepatic lesions in a real-life setting. The cryoprobe prototype fits with 1.1-mm diameter in every working channel of current cholangioscopes and has already been field-tested in subsequent tests after this study.

Here we postulate a possible advantage of cryobiopsy because prior studies have indicated it can be applied frontally and tangentially with equal efficacy [12]. This could be beneficial especially in small bile ducts with lacking flexibility during cholangioscopy/ERCP.

## Conclusions

This first systematic study of cryobiopsy in the biliary tract shows that cryobiopsy is feasible, obtains larger tissue samples, and has superior quality compared to forceps biopsies. Cryobiopsy represents a novel and effective method for tissue extraction in the bile ducts and can help to improve the common clinical dilemma of IBS. With these promising results, an in vivo study is justified.

## Acknowledgments

The authors thank all the medical staff who cared for the involved patients, especially the nurses from the surgical department as well as the involved technicians.

## Competing interests

The co-authors Walter Linzenbold and Markus Enderle are employees of ERBE Elektromedizin GmbH, Tuebingen, Germany. Cryoprobes were provided by ERBE Elektromedizin GmbH, Tuebingen, Germany. All other authors have no conflict of interest.

## References

- [1] de Moura DTH, Moura EGHD, Bernardo WM et al. Endoscopic retrograde cholangiopancreatography versus endoscopic ultrasound for tissue diagnosis of malignant biliary stricture: Systematic review and meta-analysis. *Endosc Ultrasound* 2018; 7: 10–19
- [2] Navaneethan U, Njei B, Lourdasamy V et al. Comparative effectiveness of biliary brush cytology and intraductal biopsy for detection of malignant biliary strictures: a systematic review and meta-analysis. *Gastrointest Endosc* 2015; 81: 168–176
- [3] Walter D, Peveling-Oberhag J, Schulze F et al. Intraductal biopsies in indeterminate biliary stricture: Evaluation of histopathological criteria in fluoroscopy- vs. cholangioscopy guided technique. *Dig Liver Dis* 2016; 48: 765–770
- [4] de Bellis M, Sherman S, Fogel EL et al. Tissue sampling at ERCP in suspected malignant biliary strictures (Part 2). *Gastrointest Endosc* 2002; 56: 720–730
- [5] Navaneethan U, Hasan MK, Lourdasamy V et al. Single-operator cholangioscopy and targeted biopsies in the diagnosis of indeterminate biliary strictures: a systematic review. *Gastrointest Endosc* 2015; 82: 608–14.e2
- [6] Sadeghi A, Mohamadnejad M, Islami F et al. Diagnostic yield of EUS-guided FNA for malignant biliary stricture: a systematic review and meta-analysis. *Gastrointest Endosc* 2016; 83: 290–8.e1
- [7] Troy LK, Grainge C, Corte TJ et al. Diagnostic accuracy of transbronchial lung cryobiopsy for interstitial lung disease diagnosis (COLDICE): a prospective, comparative study. *Lancet Respir Med* 2020; 8: 171–181
- [8] Hetzel J, Hetzel M, Hasel C et al. Old meets modern: the use of traditional cryoprobes in the age of molecular biology. *Respiration* 2008; 76: 193–197
- [9] Klein J-T, Berger F, Linzenbold W et al. Cryobiopsy in the upper urinary tract: preclinical evaluation of a novel device. *Urology* 2019; 123: 273–279
- [10] Yarmus LB, Semaan RW, Arias SA et al. A randomized controlled trial of a novel sheath cryoprobe for bronchoscopic lung biopsy in a porcine model. *Chest* 2016; 150: 329–336
- [11] Tanaka H, Matsusaki S, Baba Y et al. Usefulness of endoscopic transpapillary tissue sampling for malignant biliary strictures and predictive factors of diagnostic accuracy. *Clin Endosc* 2018; 51: 174–180
- [12] Hetzel J, Eberhardt R, Herth FJF et al. Cryobiopsy increases the diagnostic yield of endobronchial biopsy: a multicentre trial. *Eur Respir J* 2012; 39: 685–690
- [13] Schumann C, Hetzel J, Babiak AJ et al. Cryoprobe biopsy increases the diagnostic yield in endobronchial tumor lesions. *J Thorac Cardiovasc Surg* 2010; 140: 417–421
- [14] Franke K-J, Linzenbold W, Nuessle D et al. A new tool for transbronchial cryobiopsies in the lung: an experimental feasibility ex vivo study. *Respiration* 2016; 91: 228–234
- [15] Hetzel J, Linzenbold W, Boesmueller H et al. Evaluation of efficacy of a new cryoprobe for transbronchial cryobiopsy: a randomized, controlled in vivo animal study. *Respiration* 2020; 99: 248–256