

REVIEW ARTICLE

Worsening of diabetic retinopathy with rapid improvement in systemic glucose control: A review

Stephen C. Bain FRCP¹  | Michael A. Klufas MD² | Allen Ho MD² | David R. Matthews DPhil³

¹School of Medicine, Swansea University, Swansea, UK

²Wills Eye Hospital/Mid Atlantic Retina, Philadelphia, Pennsylvania

³Oxford Centre for Diabetes, Endocrinology and Metabolism, and Harris Manchester College, University of Oxford, Oxford, UK

Correspondence

Stephen C. Bain FRCP, Diabetes research unit Cymru, Swansea University Medical School, Swansea, SA2 8PP, UK.

Email: s.c.bain@swansea.ac.uk

Funding information

Medical writing assistance was funded by Novo Nordisk. Novo Nordisk was also provided with the opportunity to perform a medical accuracy review.

Worsening of diabetic retinopathy (DR) is associated with the initiation of effective treatment of glycaemia in some patients with diabetes. It has been associated with risk factors such as poor blood-glucose control and hypertension, and it manifests prior to the long-term benefits of optimizing glycaemic control. The majority of evidence supports an association of large and rapid reductions in blood-glucose levels with early worsening of DR. Despite a general awareness of early worsening within the diabetes community, mechanisms to explain the phenomenon remain speculative. We provide an overview of early worsening of DR and its pathophysiology based on current data. We describe the phenomenon in various settings, including in patients receiving insulin- or non-insulin-based treatments, in those undergoing bariatric surgery, and in pregnant women. We discuss various mechanisms and theories that have been suggested to explain this paradoxical phenomenon, and we summarize the implications of these in clinical practice.

KEYWORDS

diabetic retinopathy, GLP-1 analogue, glycaemic control, insulin therapy, type 1 diabetes, type 2 diabetes

1 | THE EARLY WORSENING PHENOMENON IN DIABETIC RETINOPATHY

Diabetic retinopathy (DR) is a common complication of diabetes that affects the vasculature in the eye and occurs in approximately one-third of patients with diabetes.^{1,2} It is the leading cause of vision loss in the working-age and elderly population.³ The progression and development of DR is associated with a number of risk factors, including long duration of diabetes, poor glycaemic control and poorly controlled hypertension.^{2,3} Deterioration of DR, upon initiation of stringent diabetes treatment, is referred to as “early worsening”. In this context, the term “early” refers to the establishment of good glycaemic control, and not to a short duration of diabetes. This seemingly paradoxical outcome was first described in the 1980s in patients with type 1 diabetes who were treated intensively with continuous subcutaneous insulin infusion (CSII) rather than conventional treatment, that is, short- or intermediate-acting insulin.^{4–6} One early report involving 18 patients with long-term (mean, 14.6 years) poorly controlled diabetes showed that changing from a period of poor control to tight control of diabetes was detrimental for patients with existing DR. In this

study, seven patients experienced worsening DR, while four patients with existing moderate-to-severe DR experienced rapid progression of retinopathy within three to 6 months of CSII.⁴

The timescale over which early worsening has been reported ranges from 3 months up to 3 years after treatment initiation.^{7–11} In the Oslo study, early worsening developed after 3 months of treatment in half of the patients treated with CSII ($n = 7/15$) or multiple insulin injections ($n = 8/15$) compared with none in the conventional treatment group.⁷ Similarly, in the Kroc collaborative study, almost half of the patients receiving CSII (47%) developed early worsening by Month 8 of treatment, compared to 27% in the conventional treatment group.⁸ In these trials, early worsening was defined in various ways, including by progression on the Early Treatment of Diabetic Retinopathy Study (ETDRS) severity scale, a standardized scale of disease severity derived from grading of retinal fundus photographs, which characterizes DR stages (also known as the diabetic retinopathy severity scale [DRSS])¹² and by fluorescein angiograms.^{7–9}

While the existence of early worsening is not in doubt, the pathophysiology of this phenomenon is not well understood. Furthermore, the circumstances under which it appears remain to be fully

This is an open access article under the terms of the Creative Commons Attribution-NonCommercial License, which permits use, distribution and reproduction in any medium, provided the original work is properly cited and is not used for commercial purposes.

© 2018 The Authors. *Diabetes, Obesity and Metabolism* published by John Wiley & Sons Ltd.

elucidated. Since its discovery, early worsening has been described in patients with type 1 and type 2 diabetes, including those undergoing various diabetic therapies, those who have undergone bariatric surgery, and pregnant women.¹³ Here we review the current understanding of the pathophysiology of early worsening and possible underlying mechanisms. We explore the literature related to early worsening of DR in various settings, the microvascular changes that occur, and existing theories that explain early worsening.

2 | METHODOLOGY ON LITERATURE SEARCH STRATEGY AND SELECTION CRITERIA

A literature search was conducted using BIOSIS Previews, Current Contents Search, EMBASE and MEDLINE databases to identify DR-related publications. The search terms used are shown in Table 1. Searches covered publication dates from 1 January 2012 to 31 December 2017. A total of 167 primary and secondary articles and 41 reviews were retrieved and assessed for suitability of inclusion. Clinically relevant publications, as decided by the authors, were also included.

TABLE 1 Search terms used for literature searches in BIOSIS Previews, Current Contents search, EMBASE and MEDLINE databases

Set#	Search terms	Results
Primary and secondary articles (NOT reviews)		
S5	S4 NOT (rtype.Exact[“review”])	167 ^a
S4	(s1 and s2 and s3) AND pd(20120101-20171231)	184 ^a
S3	ti,ab((glycemic or glycaemic or “blood glucose” or BG) near/3 (control or maintenance or management or improve ^b))	120 361 ^b
S2	MESH.EXACT(“disease progression”) OR EMB.EXACT(“disease exacerbation”) or ti,ab(progression or worsening or exacerbation or aggravat ^b)	2 055 459 ^b
S1	MJEMB.EXACT(“retinopathy”) OR MJMESH.EXACT(“diabetic retinopathy”) or ti,ab(diabet* near/3 [retinopathy or retinopathia])	85 482 ^b
Review articles only		
S5	S4 AND (rtype.exact(“review”) AND pd(20120101-20171231))	41 ^a
S4	s1 and s2 and s3	586 ^a
S3	ti,ab((glycemic or glycaemic or “blood glucose” or BG) near/3 (control or maintenance or management or improve ^b))	120 361 ^b
S2	MESH.EXACT(“disease progression”) OR EMB.EXACT(“disease exacerbation”) or ti,ab(progression or worsening or exacerbation or aggravat ^b)	2 055 459 ^b
S1	MJEMB.EXACT(“retinopathy”) OR MJMESH.EXACT(“diabetic retinopathy”) or ti,ab(diabet* near/3 [retinopathy or retinopathia])	85 482 ^b

^a Duplicates were removed from the search and from the result count.

^b Duplicates were removed from the search but included in the result count.

Articles were considered suitable for inclusion if they covered specific topics such as the factors impacting DR progression, the relationship between glycaemic control and long-term diabetes outcomes and the relationship between glycaemic improvement and early or transient worsening of DR. Landmark trials for both type 1 and type 2 diabetes were also included.

3 | STAGING OF DIABETIC RETINOPATHY

DR is a progressive disease comprising several stages including: (a) no DR, in which there are no abnormalities, (b) mild non-proliferative DR, in which there are microaneurysms only, (c) moderate non-proliferative DR, in which there may be microaneurysms, retinal dot-and-blot haemorrhages, hard exudates or cotton-wool spots, but no signs of severe non-proliferative DR, (d) severe non-proliferative DR, in which there may be intraretinal haemorrhages, definite venous beading, or intraretinal microvascular abnormalities, but no signs of proliferative DR, and (e) proliferative DR with neovascularization and/or vitreous or pre-retinal haemorrhages.³ This five-stage DR severity score is the standard for measuring DR disease and reflects changes in the eye following eye examinations or fundus photography.¹² In severe non-proliferative DR, abnormal new blood vessels grow in response to the hypoxic environment caused by capillary occlusion, which worsens ischaemia. In proliferative DR the main pathogenic factor is retinal hypoxia, which stimulates vascular endothelial growth factor (VEGF) production, resulting in retinal neovascularization.³

Evidence suggests that retinal neurodegeneration is an early process that precedes microvascular complications of the eye.¹⁴ This has been reflected in guidelines from the American Diabetes Association, in which DR is referred to as a highly specific neurovascular complication of diabetes.¹⁵

4 | THE PATHOPHYSIOLOGY OF EARLY WORSENING: MECHANISM OF ACTION

The definition of early worsening of DR varies across trials, ranging from changes in severity to specific morphological changes or clinically significant progression. The definition of “worsening” has been recorded as the appearance of cotton-wool spots/soft exudates, haemorrhages, including dot-and-blot haemorrhages, “red spots” or microaneurysms, intraretinal microvascular abnormalities (IRMAs) and capillary-free areas.^{6,9,16–18} Cotton-wool spots are lesions caused by microvascular perfusion abnormalities and secondary axoplasmic stasis.¹⁹ The relationship between cotton-wool spots and glycaemic change is unclear. One theory suggests that a decrease in retinal blood flow may cause cotton-wool exudates to appear. This leads to an insufficient blood supply on the downstream side of arteriosclerotic arterioles. Impaired autoregulation may also be involved.⁹

In the Kroc Collaboration study, patients in the intensively treated group were characterized by increased numbers of soft exudates (cotton-wool spots) and IRMAs, compared with those in the conventionally treated group, after 8 months. However, at 2 years, the number

of soft exudates and IRMAs were similar in both treatment groups.²⁰ In the STENO study, early worsening events were characterized by soft exudates, microaneurysms and haemorrhages at 1 year. In this study, retinal morphology had improved at 2 years.^{5,9} In the Oslo study, at 3 months only subjects in the intensively treated group had significantly more microaneurysms and haemorrhages versus baseline.⁶ However, at 2 years those in the conventionally treated group had significantly more microaneurysms and haemorrhages versus baseline and versus the intensively treated group.⁶ In the landmark Diabetic Control and Complications Trial (DCCT), at 4 years compared with baseline, there was more significant progression of DR in those with soft exudates and IRMAs versus those without. Furthermore, the rate of early worsening of DR was higher in the intensively treated group versus the conventionally treated group and in patients who previously had early worsening than in those who did not. In the DCCT, the most important factors for early worsening were a higher HbA1c level at screening and reduction of this level during the first 6 months of treatment.¹⁷ This effect was also seen in a study of patients who underwent successful pancreas transplantations. The group of patients who experienced early worsening had, among other characteristics, poor pre-transplant glycaemic control and a large difference in HbA1c between the pre- and post-transplant periods.²¹

Early worsening of DR, resulting from treatment with insulin and other agents including GLP-1RAs, suggests a glycaemia-related mechanism of action. However, other possible mechanisms should be considered in explaining early worsening in patients with diabetes.

4.1 | Other potential mechanisms of early worsening

The role of blood pressure (BP) control in early worsening remains to be clarified. The UK Prospective Diabetes Study (UKPDS) reported the effect of BP control on DR progression, suggesting that tight BP control may reduce the risk of DR complications. After 1.5 years the relative risk of two-step or worse deterioration on the ETDRS scale in those randomized to tight BP control was lower compared to that in

those with less tight BP control (RR, 0.88; 95% CI, 0.60-1.29).²² At 4.5 years after randomization, there was a significant difference in microaneurysms between the tight BP control group and the less-tight BP control group (23.3% vs 33.5%; RR, 0.7; $P = 0.003$). This effect continued to 7.5 years. In addition, although cotton-wool spots increased in both groups, there were fewer in the tight BP control group. Fewer patients in the tight BP control group, compared to the less-tight BP control group, had two-step or more deterioration on the ETDRS scale at 4.5 years (RR, 0.75; $P = 0.02$).²³ Conversely, in the ADVANCE study, lowering of BP, or intensive glucose control, did not significantly reduce the incidence and progression of clinically significant DR.²⁴ In the ACCORD BP study, in which 1263 patients with type 2 diabetes were randomized to intensive vs standard antihypertensive therapy, BP control had no effect on the rate of progression of DR (adjusted odds ratio, 1.23; 95% CI, 0.84-1.79; $P = 0.29$).²⁵ There was also no reported effect of BP on DR complications in the SUSTAIN 6 trial.²⁶

It has also been suggested that a rapid drop in HbA1c with intensive vs conventional treatment lowers intravascular osmotic pressure, creating an osmotic gradient between extracellular and intracellular compartments. This causes water to move from high to low osmotic pressure levels, with vessels, such as small vessels in the eye, being low-pressure areas that are particularly sensitive. However, this hypothesis is tentative and requires further investigation.²⁷

5 | EARLY WORSENING IN TYPE 1 DIABETES

A well-known report of early worsening of DR in type 1 diabetes is from the DCCT (Figure 1).¹⁷ This landmark trial documented the frequency, the importance of and the risk factors for early worsening of DR using intensive insulin treatment vs conventional treatment in patients with type 1 diabetes who had none-to-moderate non-proliferative DR. At the 6-month and/or 12-month visit, early

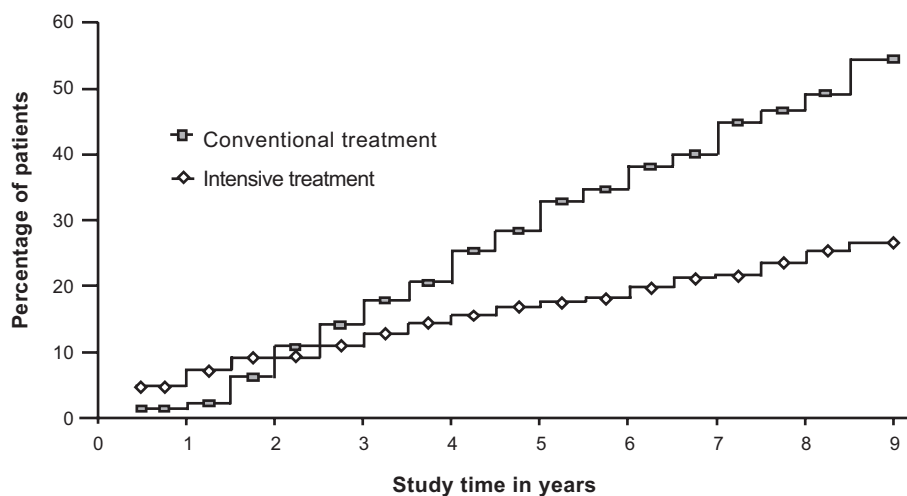


FIGURE 1 Cumulative incidence of DR progression (three-step or greater by ETDRS criteria) in the Diabetic Control and Complications Trial (DCCT) primary prevention cohort. There was little difference in percentage of patients with retinopathy progression between the Intensive and Conventional groups over the first 3 years; however, there was a 76% reduction in risk of DR progression evident at the conclusion of the DCCT after mean follow-up of 6.5 years.²⁸ ©2014 by the American Diabetes Association Diabetes Care 2014;37:17-23. Reprinted with permission from the American Diabetes Association

worsening was observed in significantly more patients assigned to receive intensive (13.1%) vs conventional (7.6%) treatment ($P < 0.001$). DR regression, that is, improvement of DR, subsequently occurred at the 18-month visit in 51% and 55% of patients, respectively. The risk of three-step (\geq three steps on the ETDRS final scale) or greater progression of DR vs baseline was higher in patients with early worsening compared to those without (Table 2).¹⁷ Characteristically, patients with early worsening had higher HbA1c at baseline and experienced greater reductions in HbA1c during the first 6 months of treatment compared to those without. However, despite this initial deterioration in DR, intensively treated patients had similar or more favourable outcomes compared with conventionally treated patients without early worsening. Furthermore, after 10 years, once HbA1c levels had become comparable between the two treatment groups, the risk of DR progression was still significantly lower in patients who had been treated intensively compared with conventionally treated patients, and a beneficial effect persisted for up to 18 years (Table 2).^{28,29}

The effects on DR of rapid reductions in HbA1c were further shown in a retrospective 24-month case-control study, in which individuals with diabetes and progression of retinopathy (case) were compared with individuals with diabetes and no progression of retinopathy (control). In the case group, HbA1c values decreased rapidly approximately 10 to 9 months before the progression of retinopathy, whereas, in the control group, HbA1c values did not change during the entire follow-up period. The relative risk of DR progression with a 1%, 2% or 3% decrease in HbA1c for approximately 6 months was 1.7, 2.8 and 4.7, respectively (Table 2).³⁰

The effect of intensive vs conventional glycaemic targets on long-term complications in patients with type 1 diabetes was assessed in a Cochrane-based review.³¹ This review comprised 12 trials, a total of 2230 patients and a mean follow-up across trials ranging between one and 6.5 years. Findings showed that intensive vs conventional treatment was highly effective in reducing the risk of developing microvascular diabetes complications such as DR (6.2% vs 23.2%; relative risk, 0.27; 95% CI, 0.18-0.42; $P < 0.00001$). Furthermore, early worsening of DR was evident after only 1 year of intensive vs conventional glucose control (34.7% vs 14.9%; relative risk, 2.32; 95% CI, 1.16-4.63; $P < 0.02$).³¹

6 | EARLY WORSENING IN TYPE 2 DIABETES

The evidence for early worsening in patients with type 2 diabetes is limited because many large randomized controlled trials, for example the ADVANCE and ACCORD trials, evaluated only the effect of intensive vs conventional therapy on DR progression, assessed as retinal change at trial end rather than as an early outcome.^{10,24,25,32}

In the UKPDS trial, which was conducted in patients with new-onset type 2 diabetes, and which used regular in-trial graded photography for retinal assessment, the risk of two-step progression of DR during the first 3 years was 15.8% with intensive therapy vs 15.3% with conventional therapy in newly diagnosed patients with type 2 diabetes who were undergoing treatment with either insulin or a

sulphonylurea, and by 9 years there was a sustained significant protective effect of improved control.¹⁰ The long-term risk reduction of DR progression was significantly better in intensively (23.0%) vs conventionally (27.8%) treated patients after 6 years of follow-up ($P = 0.017$).¹⁰

Early worsening was also demonstrated in a retrospective case-control study in 68 public hospital patients with type 2 diabetes, predominantly from ethnic minorities (Latino/other). These patients underwent annual retinal imaging either as part of a case management programme or as standard diabetes care.³³ An "intensive" group of patients ($n = 34$) with an HbA1c decrease of more than 1.5% was compared with randomly chosen (control) patients ($n = 34$) with minimal HbA1c changes over 2 years. In this study, the intensive group had a larger reduction in HbA1c over 2 years compared with the control group ($4.0\% \pm 0.41\%$ vs $0.2\% \pm 0.11\%$). Patients in the intensive group showed a 22.6% worsening in retinopathy grade progression ($P = 0.015$), while there was minimal change from baseline in the control group ($P = \text{NS}$). Change in retinopathy grade was significantly different between groups ($P = 0.02$). Furthermore, in the intensive group, more eyes worsened by ≥ 1 retinal grade ($P = 0.0025$) and developed sight-threatening retinopathy ($P = 0.003$) vs eyes in the control group.³³ This study supports DCCT findings that DR is significantly worsened in poorly controlled type 2 diabetes after early intensification of glycaemic control and a dramatic change in HbA1c.^{17,33}

As is the case for patients with type 1 diabetes, there is a large body of evidence supporting a beneficial effect of tight glycaemic control in the long term for patients with type 2 diabetes. The ACCORD eye study, for example, demonstrated reduced incidence or progression of DR. This study investigated whether intensive glycaemic control, combination therapy for dyslipidaemia and intensive BP control could limit DR in patients with type 2 diabetes.²⁵ Participants ($N = 10\,251$) were randomly assigned to receive either intensive (target HbA1c $< 6.0\%$ / < 42 mmol/mol) or conventional (target HbA1c 7.0%-7.9%/53-63 mmol/mol) treatment for glycaemia, dyslipidaemia and BP. At 4 years, rates of progression of DR were 7.3% with intensive glycaemic control vs 10.4% with standard control.²⁵ A follow-on study (ACCORDION), at 4 years after trial end, showed that DR progressed in 5.8% with intensive glycaemic control vs 12.7% with standard control (adjusted odds ratio, 0.42; 95% CI, 0.28-0.63; $P < 0.0001$). Thus, prior intensive glycaemic control continued to reduce DR progression, even after study end when HbA1c levels had become similar in both groups, 8 years after randomization and approximately 4 years after trial end.³⁴

Results from a meta-analysis of the ACCORD, UKPDS, Action in Diabetes and Vascular Disease: Preterax and Diamicon MR Controlled Evaluation (ADVANCE) and Veterans Administration Diabetes Trial (VADT) studies, in patients with type 2 diabetes, suggest that intensive vs conventional glucose control was associated with a 13% risk reduction (HR, 0.87; 95% CI, 0.76-1.00; $P = 0.04$) in eye events, a composite of requirement for pan-retinal photocoagulation therapy or pars plana vitrectomy, development of proliferative retinopathy or progression of DR, after 5 years of follow-up.³⁵

TABLE 2 Summaries of clinical studies reporting early worsening DR, or associated outcomes

Trial name	Trial type; treatment regimen; duration	Patient population and N	Key findings relating to diabetic retinopathy and/or early worsening	Reference
Type 1 diabetes				
Diabetes Control and Complications Trial (DCCT)	Multicentre, randomized clinical trial; INT versus CON therapy; Mean follow-up = 6.5 y	<ul style="list-style-type: none"> Type 1 diabetes N = 1441 INT: n = 728 CON: n = 711 	<ul style="list-style-type: none"> INT vs CON therapy reduced the risk of developing DR by 76% Early worsening was observed at the 6- or 12-month visit in 13.1% vs 7.6% patients assigned CON vs INT therapy, respectively ($P < 0.001$). 	The DCCT Research Group 1998 ¹⁷
Epidemiology of Diabetes Intervention and Complications (EDIC)	Observational follow-up of DCCT	<ul style="list-style-type: none"> Type 1 diabetes N = 1441 INT: n = 728 CON: n = 711 	<ul style="list-style-type: none"> Following DCCT, when HbA1c levels in INT and CON groups converged (year 8, INT, 7.98%; CON, 8.07%), the benefit of early INT persisted with a 53% ($P < 0.0001$) reduction in the risk of further retinopathy progression A 56% ($P < 0.001$) risk reduction in development of proliferative DR in INT group Severe retinal outcomes and procedures to treat them were reduced by 50% in the INT group 	Aiello et al., 2014 ²⁸
18 y follow-up of DCCT/EDIC study	Follow-up of DCCT/EDIC	<ul style="list-style-type: none"> Type 1 diabetes N = 1441 INT: n = 728 CON: n = 711 	<ul style="list-style-type: none"> 39% vs 56% of INT vs CON therapy patients at risk had further progression from DCCT closeout (incidence); 46% adjusted risk reduction (CI 36, 54; $P < 0.0001$) Overall, fewer former INT group patients continued to be affected by retinal complications 18 y after DCCT close-out 	Lachin et al., 2015 ²⁹
N/A	Retrospective case-control study	Diabetes with progression of DR (case) and without progression of DR (control) N = 76 Case: n = 24 Control group 1 (baseline DR): n = 23 Control group 2 (no baseline DR): n = 29	<ul style="list-style-type: none"> HbA1c values decreased rapidly 10 to 9 months before progression of DR in case group. HbA1c remained stable during follow-up in control group The relative risks of a 1%, 2% and 3% decrease in HbA1c, for about 6 months prior to progression of DR were estimated as, respectively, 1.6, 2.4 and 3.8 	Funatsu et al., 1992 ³⁰
Type 2 diabetes				
Veterans Affairs Diabetes Trial (VADT)	Post hoc analysis of VADT prospective study	<ul style="list-style-type: none"> Poorly controlled type 2 diabetes completing 7-field stereo fundus photos at baseline and 5 y N = 858 	<ul style="list-style-type: none"> Odds of DR progression lower by ~40% in those with baseline TC ≥ 200 mg/dL ($P = 0.007$), LDL-C ≥ 120 mg/dL ($P < 0.02$) or HDL-C ≥ 40 mg/dL ($P < 0.007$) in INT versus standard glycaemic treatment Odds of DR progression lower by ~40-50% with reductions of TC by ≥ 40 mg/dL ($p < 0.0001$), of LDL-C of ≥ 40 mg/dL ($P < 0.004$), and of TG by ≥ 60 mg/dL ($P = 0.004$) at year 5 INT associated with decreased odds of progression but not with onset of retinopathy in those with worse lipid levels at baseline and more improved lipid levels during the study 	Azad et al., 2016 ³²
The Action in Diabetes and Vascular Disease: Preterax and Diamicon MR Controlled Evaluation (ADVANCE) Retinal Measurements Study (AdRem)	Substudy of ADVANCE, multicentre, randomised clinical trial	<ul style="list-style-type: none"> Type 2 diabetes (aged ≥ 55 y) N = 1602 	<ul style="list-style-type: none"> Compared with standard glucose control (n = 611), intensive glucose control (n = 630) did not reduce ($P = 0.27$) the incidence and progression of retinopathy (OR 0.84; 95% CI 0.61 to 1.15) Lower, borderline significant risks of microaneurysms, hard exudates and macular oedema observed with intensive glucose control, adjusted for baseline retinal haemorrhages BP lowering or intensive glucose control did not significantly reduce the incidence and progression of retinopathy 	Beulens et al., 2009 ²⁴
Public hospital study (US)	Retrospective case-control study, retinal imaging	<ul style="list-style-type: none"> Type 2 diabetes, minorities "Intensive" HbA1c decrease $>1.5\%$ (n = 34) Minimal HbA1c changes (n = 34) 	<ul style="list-style-type: none"> Retinopathy grade progressed $+0.7 \pm 0.25$ units from baseline in the intensive group ($P = 0.015$), a 22.6% worsening The control group changed minimally from baseline (0.03 ± 0.14 units, $P = \text{NS}$) More eyes worsened by ≥ 1 retinal grade ($P = 0.0025$) and developed sight-threatening retinopathy ($P = 0.003$) in the intensive group DR significantly worsened in poorly controlled type 2 diabetes after early intensification of glycaemic control and dramatic HbA1c change 	Shurter et al., 2013 ³³

TABLE 2 (Continued)

Trial name	Trial type; treatment regimen; duration	Patient population and N	Key findings relating to diabetic retinopathy and/or early worsening	Reference
UK Prospective Diabetes Study (UKPDS)	Prospective study; Intensive policy: Sulphonylurea (chlorpropamide, glibenclamide, glipizide) or insulin Conventional policy: Diet	<ul style="list-style-type: none"> Type 2 diabetes (newly diagnosed) N = 3867 	<ul style="list-style-type: none"> After 6 y' follow-up, fewer patients in the intensive vs conventional group, had a two-step deterioration in retinopathy 	UK Prospective Diabetes Study (UKPDS) Group. 1998 ¹⁰
Kroc Collaborative Study Group	Randomized study (8 months), 2-y follow-up of DR progression (CSII vs unchanged conventional injection)	<ul style="list-style-type: none"> Type 2 diabetes and mild-to-moderate DR N = 64 	<ul style="list-style-type: none"> In type 2 diabetes patients with mild-to-moderate DR, the acceleration in activity associated with tightened control is not sustained and does not initiate vasoproliferative deterioration in DR No lasting damage results from the initial DR flare in some type 2 diabetes patients with mild-to-moderate DR after starting CSII 	Kroc Collaborative Study Group, 1988 ²⁰
UKPDS 69	Prospective study	<ul style="list-style-type: none"> Type 2 diabetes 19 clinics in UK N = 1148 	<ul style="list-style-type: none"> At 1.5 y, in patients with any type of DR at baseline, the RR of two-step or worse deterioration on the ETDRS scale in those randomized to tight BP control was numerically greater vs those with less tight BP control (RR, 1.07; 95% CI, 0.60 to 1.90) In the long term, reduction in BP was associated with an improvement in DR 	Matthews et al., 2004 ²³
Collaborators on Trials of Lowering Glucose (CONTROL) Group	Meta-analysis of microvascular outcomes in ACCORD, ADVANCE, UKPDS and VADT	<ul style="list-style-type: none"> Type 2 diabetes N = 27 049 	<ul style="list-style-type: none"> Compared with less intensive glucose control, more intensive glucose control resulted in an absolute difference of -0.90% (95% CI -1.22 to -0.58) in mean HbA1c at completion of follow-up RR reduced by 13% for eye events (HR: 0.87, 0.76 to 1.00; P = 0.04) More intensive glucose control over 5 y reduced eye events 	Zoungas et al., 2017 ³⁵
N/A	Phase 1 and subsequent follow-up study GLP-1RA therapy; Follow-up data available from mean 439 days from phase 1 screening	<ul style="list-style-type: none"> Type 2 diabetes Phase 1: Exenatide treatment n = 165 Follow-up: n = 47 	<ul style="list-style-type: none"> Phase 1 study: 29.7% (n = 49) of patients had progression of DR of whom 96% (n = 47) had improvement in HbA1c <ul style="list-style-type: none"> The proportion of patients with progression of DR was higher with greater HbA1c reduction The degree of worsening of DR was proportionate to HbA1c reduction Follow-up: 62% (n = 24) had an improvement in DR; 18% (n = 7) had no documented change to DR status 	Varadhan et al., 2011 ⁴³ Varadhan et al., 2014 ⁴⁰
Liraglutide Effect and Action in Diabetes: Evaluation of Cardiovascular Outcome Results (LEADER)	Multicentre, double-blind, placebo-controlled study; Median follow-up 3.8 y	<ul style="list-style-type: none"> Type 2 diabetes N = 9340 Liraglutide: n = 4668 Placebo: n = 4672 	<ul style="list-style-type: none"> Incidence of DR events was non-significantly higher in the liraglutide vs placebo group (0.6 vs 0.5 events per 100 patient-years; HR, 1.15, 95% CI, 0.87 to 1.52; P = 0.33) 	Marso et al., 2016 ⁴¹
SUSTAIN 6	Multicentre, double-blind, placebo-controlled study; Median follow-up 2.1 y	<ul style="list-style-type: none"> Type 2 diabetes N = 3297 Semaglutide: n = 1648 Placebo: n = 1649 	<ul style="list-style-type: none"> Incidence of DR events was significantly higher in the semaglutide vs placebo group (1.5 vs 0.9 events per 100 patient-years; HR, 1.76, 95% CI, 1.11 to 2.78; P = 0.02) 	Marso et al., 2016 ⁴¹
N/A	Meta-analysis of GLP-1RA RCT microvascular effects	<ul style="list-style-type: none"> Type 2 diabetes 37 trials GLP-1RA (n = 21 782) Comparator (n = 17 296) 	<ul style="list-style-type: none"> GLP1-RAs not associated with a significant increase in the incidence of retinopathy (MH-OR [95% CI] 0.92 [0.74 to 1.16]; P = 0.49) In subgroup analyses, GLP1-RAs associated with lower risk of retinopathy vs sulphonylureas SUSTAIN 6 suggested that treatment with semaglutide could be associated with a progression of DR 	Dicembrini et al., 2017 ⁴⁶
Type 2 diabetes and bariatric surgery				
Specialist bariatric unit (UK)	Retrospective observational study, following bariatric surgery	<ul style="list-style-type: none"> Type 2 diabetes Post-bariatric surgery N = 102 4 y' follow-up 	<ul style="list-style-type: none"> Preoperatively, 68% of patients had no DR vs 30% with background retinopathy, 1% pre-proliferative retinopathy and 1% proliferative retinopathy In the first postoperative visit, 19% of patients developed new DR versus 70% stable and 11% improved. Proportions did not differ significantly over time 	Chen et al., 2017 ⁵³

TABLE 2 (Continued)

Trial name	Trial type; treatment regimen; duration	Patient population and N	Key findings relating to diabetic retinopathy and/or early worsening	Reference
N/A	Meta-analysis on impact of bariatric surgery on DR	<ul style="list-style-type: none"> Type 2 diabetes DR outcome before and after bariatric surgery 4 non-randomized case series N = 148 	<ul style="list-style-type: none"> Bariatric surgery does not prevent progression of DR Young male patients with pre-existing DR and poor preoperative glycaemic control are most at risk of progression 	Cheung et al., 2015 ⁵⁵
Scandinavian Obesity Surgery Registry (SOREg)	Registry survey on DR outcomes before and after GBP	<ul style="list-style-type: none"> Type 2 diabetes and bariatric surgery N = 117 	<ul style="list-style-type: none"> Occurrence of DR before GBP: No DR 62%, mild 26%, moderate 10%, severe 0% and proliferative DR 2% No significant changes in occurrence of DR after surgery No association between preoperative BMI, HbA1c, or reduction in HbA1c and worsening of DR 	Moren et al., 2017 ⁵⁷
N/A	Retrospective pilot analysis of electronic hospital records	<ul style="list-style-type: none"> Morbid obesity and type 2 diabetes N = 40 pre- and post-surgery DR screening 	<ul style="list-style-type: none"> Of those without DR pre-surgery, 1.5% (n = 26) progressed to minimum BDR, post-surgery Those with minimum BDR (n = 9) pre-surgery revealed no progression, with 55.6% (n = 5) showing evidence of regression Risk of progression of DR in those with moderate BDR or worse 	Thomas et al., 2014 ⁵⁶
N/A	Retrospective observational study	<ul style="list-style-type: none"> Type 2 diabetes and bariatric surgery N = 318 	<ul style="list-style-type: none"> 68.6% had no DR pre-operatively vs 18.9%, 8.5% and 4% with a DR grade of minimal, mild or moderate and higher, respectively First post-operative retinal screening results showed that after surgery 73% had no change in their DR grade, 11% regressed and 16% progressed 	Murphy et al., 2015 ⁵⁴
N/A	Meta-analysis of bariatric surgery and DR	<ul style="list-style-type: none"> Obese type 2 diabetes 7 studies 	<ul style="list-style-type: none"> Incident cases of DR were fewer with bariatric surgery than with medical treatment Change of DR score (three studies) was not different, while only two studies were available on numbers of patients showing progression or regression of retinopathy Bariatric surgery seems to prevent new cases of DR, but available studies provide insufficient evidence to support progression or regression of DR 	Merlotti et al., 2017 ⁵⁸
N/A	Retrospective observational cohort study (US) of microvascular disease (DR, neuropathy and/or nephropathy)	<ul style="list-style-type: none"> Type 2 diabetes and bariatric surgery N = 4683 	<ul style="list-style-type: none"> The rate of incident microvascular disease was primarily due to incidence of DR, which occurred at a rate of 8.0%, 18.2%, 28.4%, and 36.5% at 1, 3, 5, and 7 y, post-surgery For every additional year of time spent in remission prior to relapse, the risk of microvascular disease was reduced by 19% (HR 0.81 [95% CI 0.67 to 0.99]) vs patients who never remitted Remission of type 2 diabetes after bariatric surgery confers benefits for risk of incident microvascular disease even if patients eventually experience a relapse of their type 2 diabetes 	Coleman et al., 2016 ⁵⁹

Abbreviations: BDR, background diabetic retinopathy; BMI, body mass index; BP, blood pressure; CI, confidence interval; CSII, continuous subcutaneous insulin infusion; DR, diabetic retinopathy; CON, conventional; ETDR, Early Treatment of Diabetic Retinopathy Study; GBP, gastric bypass surgery; GLP-1RA, glucagon-like peptide-1 receptor agonist; HR, hazard ratio; INT, intensive; LDL-C, low-density lipoprotein cholesterol; MH-OR, Mantel-Haenszel Odds Ratio; N/A, not available; NS, not specified; OR, odds ratio; RCT, randomized controlled trial; RR, relative risk; s.c., subcutaneous; TC, total cholesterol; TG, triglycerides.

7 | EARLY WORSENING WITH INSULIN

Early worsening of DR has been associated historically with insulin therapy. This was based on the observed increase in risk of DR

progression, defined as an increase of at least three steps on the ETDRS severity scale, in a six-month Phase 3 trial with insulin glargine vs human neutral protamine Hagedorn (NPH) insulin. In this study, 7.0% and 2.7% of patients in the insulin glargine group and the NPH

insulin group, respectively, experienced DR progression.^{36,37} Subsequently, an *in vitro* study showed insulin glargine to have greater binding affinity for the insulin-like growth factor 1 (IGF-1) receptor compared with NPH insulin.³⁸ It was hypothesized that this might lead to the increased risk of DR progression with insulin glargine. However, this was disputed by the results of a 5-year trial investigating DR with insulin glargine vs NPH, which showed no difference in the rate of DR progression.³⁷ Subsequently, the ORIGIN study found that there was no significant difference between the insulin glargine group and the standard-of-care group in the occurrence of microvascular events.³⁹

8 | EARLY WORSENING WITH NON-INSULIN THERAPIES

The evidence for early worsening of DR with non-insulin therapies continues to grow. Glucagon-like peptide-one receptor agonists (GLP-1RAs), such as exenatide, liraglutide and semaglutide, exemplify a non-insulin-therapy drug class that is associated with increased rates of DR complication events, including early worsening of DR.^{11,26,40–42} However, not all increases were significant when compared with placebo.⁴¹

In a retrospective cohort study in patients with type 2 diabetes, more than 6 months of treatment with exenatide resulted in 29.7% ($n = 49/165$) of patients experiencing progression of DR, of whom 16 patients experienced new-onset DR and 33 patients experienced worsening of pre-existing DR, while in 19.4% of patients DR improved ($P < 0.005$). The proportion of patients with progression of DR was higher with greater reductions in HbA1c.⁴³ Follow-up data from this study showed that sustained treatment with exenatide resulted in 80% of patients having an improved (62%) or stable (18%) DR status after a mean 439 days (1.2 years) from the phase 1 screening; initial DR screening took place 234 days (8 months) from baseline.⁴⁰ In the LEADER trial, DR complications, defined as the need for retinal photocoagulation or treatment with intravitreal agents, vitreous haemorrhage or the onset of diabetes-related blindness, was evaluated in patients with type 2 diabetes and high cardiovascular risk. In this study the incidence of DR complications was non-significantly higher in patients receiving liraglutide compared to those receiving placebo (0.6 vs 0.5 events per 100 patient-years; HR, 1.15; 95% CI, 0.87–1.52; $P = 0.33$).⁴¹ Similarly, semaglutide was associated with an increased rate of DR complications in the SUSTAIN 6 study, a pre-approval trial to evaluate cardiovascular and other long-term outcomes in patients with type 2 diabetes.¹¹ DR complications were significantly higher in the SUSTAIN 6 trial with semaglutide vs placebo (HR, 1.76; 95% CI, 1.11–2.78; $P = 0.02$).¹¹

It is important to emphasize that both the LEADER and the SUSTAIN 6 trials had similar methodological limitations with regards to the design of the DR complications endpoint. Neither was designed to assess DR and, based on the DR collection methods used as part of the general evaluation of investigator-reported AEs, it is not possible to draw definitive conclusions concerning the increased risk of DR from these trials. For example, standardized retinal fundus photography was not included in the LEADER and SUSTAIN 6 study protocols. A subsequent SUSTAIN 6 post hoc analysis suggests that the

increased risk of DR with semaglutide may not be an agent-specific effect, but rather, attributable to the rapidity and magnitude of HbA1c reduction during the first 16 weeks of treatment in patients with pre-existing DR and poor glycaemic control at baseline who were undergoing treatment with insulin (Table 2).²⁶ Furthermore, it has been hypothesized that the worsening of DR in the SUSTAIN 6 trial may be accounted for, in part, by the inclusion of patients with advanced non-proliferative or proliferative DR, in whom semaglutide may have triggered neovascularization. However, there is no information available from either *in vitro* or *in vivo* studies on the angiogenic effect of GLP-1RA in the retina, and further investigation is required.⁴²

Across the rest of the SUSTAIN Phase 3a clinical development programme (SUSTAIN 1 to 5 and Japan-based trials) and in SUSTAIN 7, in which patients with sight-threatening DR were excluded, there was no increase in DR adverse events in patients treated with semaglutide vs comparators.^{26,44} Furthermore, an assessment using the Food and Drug Administration Adverse Event Reporting System has shown no evidence that GLP-1RAs are associated with adverse events suggestive of DR progression.⁴⁵ A meta-analysis assessing the effects of GLP-1RAs on DR showed that treatment with GLP-1RAs was not associated with a significant increase in the incidence of retinopathy (Mantel-Haenszel odds ratio, 0.92; 95% CI, 0.74–1.16; $P = 0.49$). However, this analysis did not evaluate early worsening of DR.⁴⁶

In experimental animal models of early-stage DR, systemically and locally administered GLP-1RAs prevented neurodegeneration of the retina and protected from diabetes-related changes to the retina.^{47–49} Similarly, DPP4 inhibitors had a protective effect on retinal microvasculature and prevented neurodegeneration and vascular leakage in the diabetic retina.^{50,51} This evidence for a direct beneficial effect of GLP-1RAs on the retina supports the hypothesis that early worsening of DR in the SUSTAIN 6 trial may be attributed to rapid improvement in glucose control in insulin-treated patients with pre-existing retinopathy, rather than to direct retinal toxicity of GLP-1RAs.^{45,47–49}

9 | EARLY WORSENING FOLLOWING BARIATRIC SURGERY

The effect of bariatric surgery on DR and early worsening remains debatable. Existing data support positive, neutral and negative effects of bariatric surgery on DR.⁵² The potential risk factors for DR progression following bariatric surgery may include pre-operation DR severity, magnitude of post-surgery HbA1c reduction and, in some cases, gender and ethnicity.^{53,54}

Uncontrolled studies suggest that bariatric surgery may contribute to the worsening of pre-existing DR following surgery.^{53,55} A meta-analysis of four non-randomized case studies ($N = 148$) showed that, in patients with DR prior to surgery ($n = 68$), 57.4% \pm 18.5% of patients experienced no change, 23.5% \pm 18.7% experienced progression and 19.2% \pm 2.9% experienced an improvement in DR. In patients without pre-operative DR ($n = 80$) an average of 92.5% \pm 7.4% remained DR free, while 7.5% \pm 7.4% progressed to DR. The odds ratio for DR progression in patients with pre-operative DR compared to those without was 2.77 (95% CI, 1.10 to 6.9; $P = 0.03$).⁵⁵ However, data concerning the time

points after bariatric surgery when no change occurred or when progression or improvements in DR occurred, or how the improved DR rate was assessed, are important considerations when interpreting findings. In a retrospective observational study of patients with type 2 diabetes (N = 102) to assess whether bariatric surgery prevented DR progression, the overall incidence of new retinopathy was 24%. In this study, young male patients with pre-existing DR and poor pre-operative glycaemic control, who did not have significantly improved post-operative HbA1c levels, were at most risk of DR progression.⁵³ A pilot study in patients with type 2 diabetes and morbid obesity showed that moderate background DR, or worse, increased the risk of DR progression, while minimal DR or the absence of DR resulted in a low incidence of new-onset DR and DR progression.⁵⁶ Findings from a retrospective, observational study in patients with type 2 diabetes showed that the probability of DR progression, to moderate or higher severity, after bariatric surgery was associated with the magnitude of HbA1c reduction from pre-surgery levels, with a short duration of post-operative retinal screening, with severe pre-operative DR, with male gender and with ethnicity.⁵⁴

In other studies, bariatric surgery has been shown to have no effect on DR deterioration. For example, a survey of the Scandinavian Obesity Surgery Registry showed that, in 117 patients with type 2 diabetes, the majority of patients experienced no post-surgery DR deterioration (mean, 16 months after surgery; unspecified method of evaluating DR). Furthermore, no association between pre-operative body mass index (BMI), HbA1c or reduction in HbA1c and worsening of DR progression was reported.⁵⁷

Conversely, some studies have shown an improvement in DR progression following bariatric surgery. For example, a meta-analysis of seven controlled studies indicated that bariatric surgery prevented new incident cases of retinopathy. However, there were insufficient data to support reduced progression or regression of DR.⁵⁸ Similarly, in a retrospective observational cohort study (N = 4683; 40% racial/ethnic minority, Hispanic, non-Hispanic black or other), patients who experienced remission of type 2 diabetes after bariatric surgery had a 29% lower risk of microvascular complications, including first occurrence of retinopathy. Furthermore, in patients who eventually relapsed, for every year they remained in remission, they experienced a 19% risk reduction in microvascular disease compared to patients who did not go into remission.⁵⁹

10 | EARLY WORSENING DURING PREGNANCY

Pregnancy is a risk factor for DR progression and is associated with increased DR prevalence and severity compared to that in non-pregnant women with diabetes. The highest risk of DR worsening occurs in the second trimester and can persist for up to 12 months post-partum. Factors associated with DR progression during pregnancy include diabetes duration, DR severity at conception, hyperglycaemic control, anaemia and coexisting hypertension.⁶⁰ These risk factors have been confirmed in a Japan-based study (N = 93; type 1 diabetes, n = 68 and type 2 diabetes, n = 25) in which progression

of DR occurred in 17% of patients. In this study, patients who experienced DR progression had a significantly longer duration of diabetes ($P < 0.00001$), had pre-pregnancy DR ($P < 0.00001$) and had higher BP in the second trimester ($P < 0.05$) compared to patients who did not experience DR progression.⁶¹

Rapid implementation of tight glycaemic control has also been associated with worsening of retinopathy in pregnant women with type 1 diabetes.⁶² Guidelines recommend that pregnant women with pre-existing diabetes be offered retinal assessment by examination and fundus retinal imaging. In addition, guidelines suggest that DR should not be considered a contraindication to rapid glycaemic control in women with high HbA1c in early pregnancy, but rather, that retinal assessment is essential in such individuals.⁶³

11 | THEORIES CONCERNING THE PARADOXICAL EARLY WORSENING OF DR

Several theories exist to explain the paradoxical worsening of DR that is evident in patients with diabetes following rapid and large reductions in blood glucose. However, as there are currently no suitable animal models of DR, there are significant limitations associated with such theories.

11.1 | Osmotic force theory

Glucose is an osmotically active molecule and can influence water movements. Thus, changes in blood glucose concentrations can alter osmotic pressure, which in turn affects water retention. Earlier, we described how rapid reductions in blood glucose affect osmotic pressure and the extracellular and intravascular areas.²⁷ Although evidence for this theory is limited, transient refractive error is associated with tight glycaemic control, relating to the rate of reduction in plasma blood glucose. In a study of 14 patients with diabetes (plasma glucose ≥ 400 mg/dL [22.2 mmol/L]; HbA1c $\geq 12.0\%$ [108 mmol/mol]), transient hyperopic change occurred in patients who improved control after hyperglycaemia. There was a positive correlation between the magnitude of maximum hyperopic change and the daily rate of plasma glucose reduction over the first 7 days of treatment ($P < 0.001$), the number of days required for hyperopia to reach its peak ($P < 0.001$) and the number of days required for the development and resolution of hyperopic changes ($P < 0.0001$).⁶⁴ This correlation alone, however, is insufficient evidence for causation.

11.2 | Synergistic hypothesis

The synergistic hypothesis postulates that early worsening is caused by the synergistic action of insulin and VEGF on blood vessels in the retina, triggering vascular proliferation and, therefore, worsening DR.²⁷ In an in vitro study, insulin was found to increase reactive oxygen species (ROS) in bovine retinal endothelial cells. This increased insulin-induced ROS production and VEGF expression, in the presence of high glucose, may explain early worsening DR (Table 3).⁶⁵

TABLE 3 Summaries of preclinical studies reporting early worsening, or associated outcomes

Title	Study population	Key findings relating to DR and/or early worsening	Reference
Topical administration of GLP-1RAs prevents retinal neurodegeneration in experimental diabetes	Human and <i>db/db</i> mice retinas	<ul style="list-style-type: none"> Abundant expression of GLP-1R in the human retina and retinas from <i>db/db</i> mice Systemic administration of liraglutide prevented retinal neurodegeneration (glial activation, neural apoptosis, and electroretinographical abnormalities) A similar neuroprotective effect was found using topical administration of native GLP-1 and liraglutide, lixisenatide, and exenatide. <ul style="list-style-type: none"> No reduction in blood glucose levels was observed, suggesting that GLP-1R activation prevents retinal neurodegeneration 	Hernández et al., 2016 ⁴⁷
Different effects of low- and high-dose insulin on ROS production and VEGF expression in bovine retinal microvascular endothelial cells in the presence of high glucose	BRECs	<ul style="list-style-type: none"> High-dose insulin-induced ROS production and VEGF expression in BRECs in the presence of high glucose might be one of the reasons for the transient worsening of DR during intensive insulin treatment 	Wu et al., 2011 ⁶⁵
Acute intensive insulin therapy exacerbates diabetic blood-retinal barrier breakdown via hypoxia-inducible factor-1 α and VEGF	Diabetic rats	<ul style="list-style-type: none"> VEGF mRNA and protein levels are increased in retina of diabetic rats intensively treated with insulin through hypoxia-inducible factor-1α-mediated increases in retinal VEGF expression, leading to BRB breakdown This mechanism explains the transient worsening of DR, specifically BRB breakdown, that follows the institution of intensive insulin therapy 	Poulaki et al., 2002 ⁶⁶
The influence of glucose concentration and hypoxia on VEGF secretion by cultured retinal cells	Human and bovine retinal cells	<ul style="list-style-type: none"> Lack of both oxygen and glucose led to significant upregulation of VEGF production, whereas lack of oxygen but excess glucose led to downregulation of VEGF Sufficient oxygen with excess glucose had no effect on VEGF production "Early worsening" of DR may result when diabetic patients with minimal to moderate retinopathy, whose retinal circulation and, hence, retinal oxygen supply is compromised, are placed on a "tight" glucose control regimen and their major remaining retinal energy source is reduced, with VEGF upregulation as a compensatory mechanism 	Kennedy and Frank, 2011 ⁶⁷
Effects of ischemic preconditioning and bevacizumab on apoptosis and vascular permeability following retinal ischemia-reperfusion injury	Rats	<ul style="list-style-type: none"> Transient ischaemia followed by retinal reperfusion led to a significant increase in VEGF VEGF expression was linked to vascular permeability IR provides an acute model of ischaemic retinopathy including neurodegeneration and VEGF-dependent vascular permeability 	Abcouwer et al., 2010 ⁶⁸
Effect of intensive insulin therapy on macular biometrics, plasma VEGF and its soluble receptor, in newly diagnosed diabetic patients	Human	<ul style="list-style-type: none"> Newly diagnosed patients with blurred vision starting insulin therapy presented with a transient increase in macular volume and thickness and decrease in circulating soluble VEGF receptor 	Hernández et al., 2010 ⁶⁹
Hypoglycaemia-induced retinal neurodegeneration is associated with mitochondrial ROS production caused by fatty acid oxidation	Bovine aortic endothelial cells	<ul style="list-style-type: none"> mtROS production is increased in hypoglycaemic conditions as a result of increased fatty acid oxidation Recurrent hypoglycaemia increased ROS production and enhanced pathological retinal neovascularization Hypoglycaemia-induced mtROS production may contribute to early worsening of DR 	Kajihara et al., 2016 ⁷⁰
The role of DNA methylation in the metabolic memory phenomenon associated with the continued progression of DR	Human retinal epithelial cells, diabetic rat retinas	<ul style="list-style-type: none"> Retinal DNA methylation-hydroxymethylation machinery does not benefit immediately from reversal of hyperglycaemia Maintenance of good glycaemic control for longer duration, and/or direct targeting DNA methylation ameliorates continuous mitochondrial damage, and could retard/halt DR progression 	Mishra and Kowluru, 2016 ⁷¹
Hypoglycaemia exacerbates ischaemic retinal injury in rats	Rats and rat retinas	<ul style="list-style-type: none"> Reduced blood glucose levels or hypoglycaemia caused a significant reduction in vitreous glucose concentration, exacerbating ischaemic retinal injury 	Casson et al., 2004 ⁷²

Abbreviations: BRB, blood-retinal barrier; BREC, bovine retinal microvascular endothelial cells; DR, diabetic retinopathy; GLP-1RA, glucagon-like peptide-one receptor agonist; mtROS, mitochondrial reactive oxygen species; ROS, reactive oxygen species; VEGF, vascular endothelial growth factor.

11.3 | Blood-retinal barrier

Another mechanism that has been suggested to explain transient worsening of DR is that involving a breakdown of the blood-brain

barrier following intensive insulin therapy. An in vitro study demonstrated an increase in VEGF mRNA and protein levels in the retinas of diabetic rats following acute intensive insulin therapy. Retinal nuclear

extracts from insulin-treated rats had high levels of hypoxia-inducible factor-1 α (HIF-1 α). Thus, acute intensive insulin therapy led to blood-retinal barrier breakdown via an HIF-1 α -mediated increase in retinal VEGF expression, resulting in transient DR (Table 3).⁶⁶

11.4 | VEGF hypothesis

Tight glycaemic control in an hypoxic environment may lead to VEGF upregulation. In a series of *in vitro* experiments in human and bovine retinal cells, the lack of both oxygen and glucose led to significant upregulation of VEGF production, whereas lack of oxygen in combination with excess glucose led to downregulation of VEGF and sufficient oxygen with excess glucose had no effect on VEGF production.⁶⁷ In rat cells, transient ischaemia, followed by retinal reperfusion, led to a significant increase in VEGF. VEGF expression was linked to vascular permeability.⁶⁸ In addition, a study of 26 patients newly diagnosed with type 1 or type 2 diabetes showed that, in those who experienced blurred vision after initiating insulin therapy, a transient increase in macular volume and thickness followed, which is associated with a decrease in the circulating soluble VEGF receptor, sFlt-1 (Table 3).⁶⁹

11.5 | Other potential effects of tight glycaemic control

Although changes in retinal blood flow and haemodynamics are associated with early worsening of DR,^{70,71} the exact nature of these changes is controversial. For example, in bovine aortic endothelial cells, mitochondrial ROS (mtROS) production was increased in hypoglycaemic conditions as a result of increased fatty acid oxidation. Furthermore, there was an increase in pathological retinal neovascularization in recurrent hypoglycaemic conditions in streptozotocin (STZ)-induced diabetic control mice vs eMnSOD-Tg (STZ-Tg) mice. Blocking fatty acid oxidation led to reduced ROS production, inhibiting disease progression and suggesting that hypoglycaemia-induced mtROS production may contribute to early worsening of DR (Table 3).⁷⁰ In another study using human retinal epithelial cells, the rapid achievement of good glycaemic control did not trigger an immediate effect on the retinal DNA methylation-hydroxymethylation machinery associated with DR progression. In this study, good glycaemic control for a longer duration, and/or direct targeting of DNA methylation, improved mitochondrial damage and could therefore potentially slow DR progression (Table 3).⁷¹ The relationship between hypoglycaemia and ischaemic retinopathy was investigated in an *in vivo* study using Wistar rats. In this study, reduced blood glucose levels or hypoglycaemia caused a significant ($P < 0.001$) reduction in vitreous glucose concentration, thereby exacerbating ischaemic retinal injury (Table 3).⁷² The role of epigenetic modifications in early worsening of DR following tight glycaemic control remains to be fully investigated.

12 | CONCLUSIONS

Early worsening of DR is a well-described phenomenon evident in patients with type 1 and type 2 diabetes, in those who have

undergone bariatric surgery and in pregnant women.¹³ It does not appear to be agent-specific as it has been described in patients receiving diverse treatments, including intensive insulin therapy, sulphonylureas, thiazolidinediones and GLP-1RAs.^{4–6,10,11,26,40,41}

Morphological retinal changes that occur in early worsening include cotton-wool spots/soft exudates, IRMAs, retinal haemorrhages and progression to severe non-proliferative or proliferative forms of DR.^{3,6,9,16,17} While the mechanism leading to early worsening remains unclear, most evidence suggests an association with glycaemic control. The most important factors that are linked with early worsening of DR following rapid improvement of hyperglycaemia are a large reduction in HbA1c (<2%) and the severity of pre-existing DR at baseline.^{17,30,33} Consequently, insulin labels carry a warning of the risk of early worsening of DR with large and rapid reductions in HbA1c in patients with diabetes.⁷³ Although a gradual improvement in HbA1c is possible with insulin, this may not be possible with treatments such as GLP-1RAs, where the improvement in glycaemic control can be rapid and profound. Poorly controlled hypertension is another potential risk factor associated with early worsening.³

Various hypotheses have been proposed to explain early worsening of DR, but all are tentative or inconclusive. There are knowledge gaps consequent to the lack of adequate baseline and follow-up retinal imaging data in several large-scale studies. Non-clinical studies might help address the gaps and generate more robust theories, but suitable animal models are limited.

Early worsening of DR has implications in clinical practice. Guidelines from the American Diabetes Association suggest at least annual eye examinations for patients with DR, while guidelines from the Royal College of Ophthalmologists recommend annual eye examinations for mild-to-moderate DR and examinations every four to 6 months for moderately severe-to-very severe DR. Guideline revisions may be required for patients with DR and poor glycaemic control prior to initiation of highly efficacious antidiabetic medications.^{15,63} Rigorous methodology for DR assessment in future studies evaluating diabetes agents are required.

Eye status should be assessed in patients at increased ocular risk prior to initiating intensive treatments to achieve glycaemic control, and patients should be informed of the risk and reassured that both the transient loss of visual acuity and the possible change in retinal architecture are small risks compared with the proven long-term benefits of glycaemic control.

ACKNOWLEDGMENTS

The authors would like to thank AXON Communications for writing and editorial assistance in the development of this manuscript, which was funded by Novo Nordisk.

Conflicts of interest

S. C. B. has received research grants (including principal investigator, collaborator or consultant and pending grants/grants already received) from Healthcare and Research Wales (Welsh Government) and Novo Nordisk; he has received other research support from Healthcare and Research Wales (Welsh Government) and infrastructure support and

honoraria from Novo Nordisk, Sanofi, Lilly, Boehringer Ingelheim and Merck; and he has ownership interests in GycoMedia, a diabetes online news service. M. K. and A. C. H. consult for Novo Nordisk. D. R. M. has received advisory board and consulting fees or honoraria from Novo Nordisk, Novartis, Eli Lilly, Sanofi, Janssen and Servier; he has current research support from Janssen and has lectured for Novo Nordisk, Servier, Sanofi Aventis and Janssen.

Author contributions

All authors contributed to the conception of the review, interpretation of data and critical revision of manuscript.

ORCID

Stephen C. Bain  <https://orcid.org/0000-0001-8519-4964>

REFERENCES

- American Diabetes Association. 10. Microvascular complications and foot care: standards of medical care in diabetes-2018. *Diabetes Care*. 2018;41:S105-S118.
- Yau JW, Rogers SL, Kawasaki R, et al. Global prevalence and major risk factors of diabetic retinopathy. *Diabetes Care*. 2012;35:556-564.
- Wong TY, Cheung CM, Larsen M, Sharma S, Simo R. Diabetic retinopathy. *Nat Rev Dis Primers*. 2016;2:16012.
- Hooymans JM, Ballegooye EV, Schweitzer NM, Doorebos H, Reitsma WD, Slutter WJ. Worsening of diabetic retinopathy with strict control of blood sugar. *Lancet*. 1982;2:438.
- Lauritzen T, Frost-Larsen K, Larsen HW, Deckert T. Two-year experience with continuous subcutaneous insulin infusion in relation to retinopathy and neuropathy. *Diabetes*. 1985;34:74-79.
- Dahl-Jorgensen K. Near-normoglycemia and late diabetic complications. The Oslo Study. *Acta Endocrinol Suppl (Copenh)*. 1987;284:1-38.
- Brinchmann-Hansen O, Dahl-Jorgensen K, Hanssen KF, Sandvik L. Effects of intensified insulin treatment on various lesions of diabetic retinopathy. *Am J Ophthalmol*. 1985;100:644-653.
- The Kroc Collaborative Study Group. Blood glucose control and the evolution of diabetic retinopathy and albuminuria. A preliminary multicenter trial. *N Engl J Med*. 1984;311:365-372.
- Lauritzen T, Frost-Larsen K, Larsen HW, Deckert T. Effect of 1 year of near-normal blood glucose levels on retinopathy in insulin-dependent diabetics. *Lancet*. 1983;1:200-204.
- UK Prospective Diabetes Study (UKPDS) Group. Intensive blood-glucose control with sulphonylureas or insulin compared with conventional treatment and risk of complications in patients with type 2 diabetes (UKPDS 33). *Lancet*. 1998;352:837-853.
- Marso SP, Bain SC, Consoli A, et al. SUSTAIN-6 Investigators. Semaglutide and cardiovascular outcomes in patients with type 2 diabetes. *N Engl J Med*. 2016;375:1834-1844.
- Wilkinson CP, Ferris FL III, Klein RE, et al. Proposed international clinical diabetic retinopathy and diabetic macular edema disease severity scales. *Ophthalmology*. 2003;110:1677-1682.
- Feldman-Billard S, Langer É, Massin P. Early worsening of diabetic retinopathy after rapid improvement of blood glucose control in patients with diabetes. *Diabetes Metab*. 2018;44:4-14.
- Simo R, Hernandez C. Neurodegeneration in the diabetic eye: new insights and therapeutic perspectives. *Trends Endocrinol Metab*. 2014;25:23-33.
- Solomon SD, Chew E, Duh EJ, et al. Diabetic retinopathy: a position statement by the American Diabetes Association. *Diabetes Care*. 2017;40:412-418.
- The Kroc Collaborative Study Group. Collaborative studies of the effects of continuous subcutaneous insulin infusion in insulin-dependent diabetes mellitus. Conclusions. *Diabetes*. 1985;34:87-89.
- Early worsening of diabetic retinopathy in the Diabetes Control and Complications Trial. *Arch Ophthalmol*. 1998;116:874-886.
- Viswanath K, McGavin DD. Diabetic retinopathy: clinical findings and management. *Community Eye Health*. 2003;16:21-24.
- Chui TY, Thibos LN, Bradley A, Burns SA. The mechanisms of vision loss associated with a cotton wool spot. *Vision Res*. 2009;49:2826-2834.
- The Kroc Collaborative Study Group. Diabetic retinopathy after two years of intensified insulin treatment. Follow-up of the Kroc collaborative study. *JAMA*. 1988;260:37-41.
- Kim YJ, Shin S, Han DJ, et al. Long-term effects of pancreas transplantation on diabetic retinopathy and incidence and predictive risk factors for early worsening. *Transplantation*. 2018;102:e30-e38.
- UK Prospective Diabetes Study Group. Tight blood pressure control and risk of macrovascular and microvascular complications in type 2 diabetes: UKPDS 38. *BMJ*. 1998;317:703-713.
- Matthews DR, Stratton IM, Aldington SJ, Holman RR, Kohner EM. Risks of progression of retinopathy and vision loss related to tight blood pressure control in type 2 diabetes mellitus: UKPDS 69. *Arch Ophthalmol*. 2004;122:1631-1640.
- Beulens JW, Patel A, Vingerling JR, et al. Effects of blood pressure lowering and intensive glucose control on the incidence and progression of retinopathy in patients with type 2 diabetes mellitus: a randomised controlled trial. *Diabetologia*. 2009;52:2027-2036.
- Chew EY, Ambrosius WT, Davis MD, et al. Effects of medical therapies on retinopathy progression in type 2 diabetes. *N Engl J Med*. 2010;363:233-244.
- Vilsbøll T, Bain SC, Leiter LA, et al. Semaglutide, reduction in HbA1c and the risk of diabetic retinopathy. *Diabetes Obes Metab*. 2018;20:889-897.
- Jingi AM, Tankeu AT, Ateba NA, Noubiap JJ. Mechanism of worsening diabetic retinopathy with rapid lowering of blood glucose: the synergistic hypothesis. *BMC Endocr Disord*. 2017;17:63.
- Aiello LP. Diabetic retinopathy and other ocular findings in the diabetes control and complications trial/epidemiology of diabetes interventions and complications study. *Diabetes Care*. 2014;37:17-23.
- Lachin JM, White NH, Hainsworth DP, Sun W, Cleary PA, Nathan DM. Effect of intensive diabetes therapy on the progression of diabetic retinopathy in patients with type 1 diabetes: 18 years of follow-up in the DCCT/EDIC. *Diabetes*. 2015;64:631-642.
- Funatsu H, Yamashita H, Ohashi Y, Ishigaki T. Effect of rapid glycemic control on progression of diabetic retinopathy. *Jpn J Ophthalmol*. 1992;36:356-367.
- Fullerton B, Jeitler K, Seitz M, Horvath K, Berghold A, Siebenhofer A. Intensive glucose control versus conventional glucose control for type 1 diabetes mellitus. *Cochrane Database Syst Rev*. 2014;2:Cd009122.
- Azad N, Bahn GD, Emanuele NV, et al. the VADT Study Group. Association of blood glucose control and lipids with diabetic retinopathy in the Veterans Affairs Diabetes Trial (VADT). *Diabetes Care*. 2016;39:816-822.
- Shurter A, Genter P, Ouyang D, Ipp E. Euglycemic progression: worsening of diabetic retinopathy in poorly controlled type 2 diabetes in minorities. *Diabetes Res Clin Pract*. 2013;100:362-367.
- Action to Control Cardiovascular Risk in Diabetes Follow-On (ACCORDION) Eye Study Group and the Action to Control Cardiovascular Risk in Diabetes Follow-On (ACCORDION) Study Group. Persistent effects of intensive glycemic control on retinopathy in type 2 diabetes in the Action to Control Cardiovascular Risk in Diabetes (ACCORD) follow-on study. *Diabetes Care*. 2016;39:1089-1100.
- Zoungas S, Arima H, Gerstein HC, et al. Collaborators on Trials of Lowering Glucose (CONTROL) group. Effects of intensive glucose control on microvascular outcomes in patients with type 2 diabetes: a meta-analysis of individual participant data from randomised controlled trials. *Lancet Diabetes Endocrinol*. 2017;5:431-437.
- Rosenstock J, Schwartz SL, Clark CM Jr, Park GD, Donley DW, Edwards MB. Basal insulin therapy in type 2 diabetes: 28-week comparison of insulin glargine (HOE 901) and NPH insulin. *Diabetes Care*. 2001;24:631-636.
- Rosenstock J, Fonseca V, McGill JB, et al. Similar progression of diabetic retinopathy with insulin glargine and neutral protamine

- Hagedorn (NPH) insulin in patients with type 2 diabetes: a long-term, randomised, open-label study. *Diabetologia*. 2009;52:1778-1788.
38. Mayer D, Shukla A, Enzmann H. Proliferative effects of insulin analogues on mammary epithelial cells. *Arch Physiol Biochem*. 2008;114:38-44.
39. Gerstein HC, Bosch J, Dagenais GR, et al. Basal insulin and cardiovascular and other outcomes in dysglycemia. *N Engl J Med*. 2012;367:319-328.
40. Varadhan L, Humphreys T, Walker AB, Varughese GI. The impact of improved glycaemic control with GLP-1 receptor agonist therapy on diabetic retinopathy. *Diabetes Res Clin Pract*. 2014;103:e37-e39.
41. Marso SP, Daniels GH, Brown-Frandsen K, et al. LEADER Steering Committee, LEADER Trial Investigators. Liraglutide and cardiovascular outcomes in type 2 diabetes. *N Engl J Med*. 2016;375:311-322.
42. Simo R, Hernandez C. GLP-1R as a target for the treatment of diabetic retinopathy: friend or foe? *Diabetes*. 2017;66:1453-1460.
43. Varadhan L, Humphreys T, Hariman C, Walker AB, Varughese GI. GLP-1 agonist treatment: implications for diabetic retinopathy screening. *Diabetes Res Clin Pract*. 2011;94:e68-e71.
44. Pratley RE, Aroda VR, Lingvay I, et al. SUSTAIN 7 investigators. Semaglutide versus dulaglutide once weekly in patients with type 2 diabetes (SUSTAIN 7): a randomised, open-label, phase 3b trial. *Lancet Diabetes Endocrinol*. 2018;6:275-286.
45. Fadini GP, Sarangdhar M, Avogaro A. Glucagon-like peptide-1 receptor agonists are not associated with retinal adverse events in the FDA Adverse Event Reporting System. *BMJ Open Diabetes Res Care*. 2018;6:e000475.
46. Dicembrini I, Nreu B, Scatena A, et al. Microvascular effects of glucagon-like peptide-1 receptor agonists in type 2 diabetes: a meta-analysis of randomized controlled trials. *Acta Diabetol*. 2017;54:933-941.
47. Hernandez C, Bogdanov P, Corraliza L, et al. Topical administration of GLP-1 receptor agonists prevents retinal neurodegeneration in experimental diabetes. *Diabetes*. 2016;65:172-187.
48. Zhang Y, Zhang J, Wang Q, et al. Intravitreal injection of exendin-4 analogue protects retinal cells in early diabetic rats. *Invest Ophthalmol Vis Sci*. 2011;52:278-285.
49. Fan Y, Liu K, Wang Q, Ruan Y, Ye W, Zhang Y. Exendin-4 alleviates retinal vascular leakage by protecting the blood-retinal barrier and reducing retinal vascular permeability in diabetic Goto-Kakizaki rats. *Exp Eye Res*. 2014;127:104-116.
50. Hernandez C, Bogdanov P, Sola-Adell C, et al. Topical administration of DPP-IV inhibitors prevents retinal neurodegeneration in experimental diabetes. *Diabetologia*. 2017;60:2285-2298.
51. Dietrich N, Kollibabka M, Busch S, et al. The DPP4 inhibitor linagliptin protects from experimental diabetic retinopathy. *PLoS One*. 2016;11:e0167853.
52. Gorman DM, le Roux CW, Docherty NG. The effect of bariatric surgery on diabetic retinopathy: good, bad, or both? *Diabetes Metab J*. 2016;40:354-364.
53. Chen Y, Laybourne JP, Sandinha MT, de Alwis NMW, Avery P, Steel DH. Does bariatric surgery prevent progression of diabetic retinopathy? *Eye (Lond)*. 2017;31:1131-1139.
54. Murphy R, Jiang Y, Booth M, et al. Progression of diabetic retinopathy after bariatric surgery. *Diabet Med*. 2015;32:1212-1220.
55. Cheung D, Switzer NJ, Ehmann D, Rudnisky C, Shi X, Karmali S. The impact of bariatric surgery on diabetic retinopathy: a systematic review and meta-analysis. *Obes Surg*. 2015;25:1604-1609.
56. Thomas RL, Prior SL, Barry JD, et al. Does bariatric surgery adversely impact on diabetic retinopathy in persons with morbid obesity and type 2 diabetes? A pilot study. *J Diabetes Complications*. 2014;28:191-195.
57. Moren A, Sundbom M, Ottosson J, Granstam E. Gastric bypass surgery does not increase the risk for sight-threatening diabetic retinopathy. *Acta Ophthalmol*. 2018;96:279-282.
58. Merlotti C, Ceriani V, Morabito A, Pontiroli AE. Bariatric surgery and diabetic retinopathy: a systematic review and meta-analysis of controlled clinical studies. *Obes Rev*. 2017;18:309-316.
59. Coleman KJ, Haneuse S, Johnson E, et al. Long-term microvascular disease outcomes in patients with type 2 diabetes after bariatric surgery: evidence for the legacy effect of surgery. *Diabetes Care*. 2016;39:1400-1407.
60. Mallika P, Tan A, S A, T A, Alwi SS, Intan G. Diabetic retinopathy and the effect of pregnancy. *Malays Fam Physician*. 2010;5:2-5.
61. Toda J, Kato S, Sanaka M, Kitano S. The effect of pregnancy on the progression of diabetic retinopathy. *Jpn J Ophthalmol*. 2016;60:454-458.
62. Chew EY, Mills JL, Metzger BE, et al. National Institute of Child Health and Human Development Diabetes in Early Pregnancy Study. Metabolic control and progression of retinopathy. The diabetes in early pregnancy study, National Institute of Child Health and Human Development Diabetes in Early Pregnancy Study. *Diabetes Care*. 1995;18:631-637.
63. The Royal College of Ophthalmologists. Diabetic Retinopathy Guidelines. 2012. <https://www.rcophth.ac.uk/wp-content/uploads/2014/12/2013-SCI-301-FINAL-DR-GUIDELINES-DEC-2012-updated-July-2013.pdf>. Accessed September 2018.
64. Okamoto F, Sone H, Nonoyama T, Hommura S. Refractive changes in diabetic patients during intensive glycaemic control. *Br J Ophthalmol*. 2000;84:1097-1102.
65. Wu H, Jiang C, Gan D, et al. Different effects of low - and high-dose insulin on ROS production and VEGF expression in bovine retinal microvascular endothelial cells in the presence of high glucose. *Graefes Arch Clin Exp Ophthalmol*. 2011;249:1303-1310.
66. Poulaki V, Qin W, Jousseaume AM, et al. Acute intensive insulin therapy exacerbates diabetic blood-retinal barrier breakdown via hypoxia-inducible factor-1 α and VEGF. *J Clin Invest*. 2002;109:805-815.
67. Kennedy A, Frank RN. The influence of glucose concentration and hypoxia on VEGF secretion by cultured retinal cells. *Curr Eye Res*. 2011;36:168-177.
68. Abcouwer SF, Lin CM, Wolpert EB, et al. Effects of ischemic preconditioning and bevacizumab on apoptosis and vascular permeability following retinal ischemia-reperfusion injury. *Invest Ophthalmol Vis Sci*. 2010;51:5920-5933.
69. Hernandez C, Zapata MA, Losada E, et al. Effect of intensive insulin therapy on macular biometrics, plasma VEGF and its soluble receptor in newly diagnosed diabetic patients. *Diabetes Metab Res Rev*. 2010;26:386-392.
70. Kajihara N, Kukidome D, Sada K, et al. Hypoglycaemia-induced retinal neurodegeneration is associated with mitochondrial ROS production caused by fatty acid oxidation. European Association for the Study of Diabetes, 52nd Annual Meeting; 2016. <https://www.easd.org/virtualmeeting/home.html#resources/hypoglycaemia-induced-retinal-neurodegeneration-is-associated-with-mitochondrial-ros-production-caused-by-fatty-acid-oxidation>. Accessed October 8, 2018.
71. Mishra M, Kowluru RA. The role of DNA methylation in the metabolic memory phenomenon associated with the continued progression of diabetic retinopathy. *Invest Ophthalmol Vis Sci*. 2016;57:5748-5757.
72. Casson RJ, Wood JP, Osborne NN. Hypoglycaemia exacerbates ischaemic retinal injury in rats. *Br J Ophthalmol*. 2004;88:816-820.
73. Sanofi-Aventis. Lantus[®] (Insulin Glargine), EU Summary of Product Characteristics. http://ec.europa.eu/health/documents/community-register/2017/20171003139003/anx_139003_en.pdf. Accessed October 8, 2018.

How to cite this article: Bain SC, Klufas MA, Ho A, Matthews DR. Worsening of diabetic retinopathy with rapid improvement in systemic glucose control: A review. *Diabetes Obes Metab*. 2019;21:454-466. <https://doi.org/10.1111/dom.13538>