


## ARTICLE

# Analgesic effects of indomethacin spray on drug-induced oral mucositis pain in patients with cancer: A single-arm cross-sectional study

Hironobu Hata<sup>1</sup>  | Shinya Takada<sup>2</sup> | Jun Sato<sup>3</sup> | Kazuhito Yoshikawa<sup>3</sup> | Kenji Imamachi<sup>1</sup> | Minako Edo<sup>1</sup> | Tamotsu Sagawa<sup>4</sup> | Koshi Fujikawa<sup>4</sup> | Michihiro Ueda<sup>5</sup> | Masashi Matsuzaka<sup>6,7</sup> | Yoshimasa Kitagawa<sup>3</sup>

<sup>1</sup> Department of Dentistry and Oral Surgery, National Hospital Organization Hokkaido Cancer Center, Sapporo, Japan

<sup>2</sup> Department of Pharmacy, National Hospital Organization Hokkaido Cancer Center, Sapporo, Japan

<sup>3</sup> Oral Diagnosis and Medicine, Faculty of Dental Medicine, Hokkaido University, Sapporo, Japan

<sup>4</sup> Department of Gastroenterology, National Hospital Organization Hokkaido Cancer Center, Sapporo, Japan

<sup>5</sup> Department of Clinical Oral Oncology, National Hospital Organization Hokkaido Cancer Center, Sapporo, Japan

<sup>6</sup> Clinical Research Support Centre, Hirosaki University Hospital, Hirosaki, Japan

<sup>7</sup> Department of Medical Informatics, Hirosaki University Hospital, Hirosaki, Japan

## Correspondence

Hironobu Hata, 3-54, Kikusui 4-jo 2-chome, Shiroishi-ku, Sapporo 003-0804, Japan.  
Email: [hata.hironobu.wq@mail.hosp.go.jp](mailto:hata.hironobu.wq@mail.hosp.go.jp)

The abstract of this paper was presented at annual meeting of MASCC (Multinational Association of Supportive Care in Cancer) held in Washington DC on June 22–24, 2017.

## Abstract

**Aims:** Symptomatic treatment is insufficient for chemotherapy- or targeted therapy-induced oral mucositis (OM) pain, and benzydamine mouthwash is not commercially available in Japan. We evaluated the analgesic effects of an in-hospital preparation of 0.25% indomethacin spray (IMS) on anticancer drug-induced OM pain.

**Methods:** This single-arm prospective trial enrolled 20 patients (median age 62.0 years) with OM and numerical rating scale scores of  $\geq 5$  who were undergoing chemotherapy or targeted therapy in our hospital. Pain scores were recorded using a visual analog scale (VAS) before and 30 min after IMS administration. Pain relief (PR) scores were recorded at 15, 30, and 60 min after IMS administration; total PR after 60 min (TOTPAR<sub>60</sub>) was calculated, and the mean PR score after 3 days (PR<sub>3days</sub>) was determined.

**Results:** The median (interquartile range) OM grade of the participants was 2.0 (2.0–2.3). The VAS score decreased significantly at 30 min after IMS administration ( $p = .001$ ). The median (interquartile range) TOTPAR<sub>60</sub> and PR<sub>3days</sub> were 6.0 (3.8–7.3) and 2.0 (2.0–3.0), respectively.

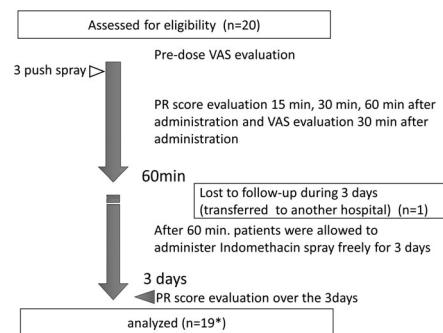
**Conclusions:** IMS helped improve patients' quality of life. The risk of systemic adverse effects was low because of the low dose administered. IMS effectively relieved anticancer drug-induced OM pain and may be useful for immediate self-medication.

## KEYWORDS

analgesic effect, cancer therapy, indomethacin spray, oral mucositis pain, quality of life

## 1 | INTRODUCTION

Mucositis was once thought to result only from damage to basal epithelial cells due to chemotherapy or radiation therapy. It is now understood that the pathogenesis is much more complex and involves the generation of damaging reactive oxygen species, activation of transcription factors such as nuclear factor- $\kappa$ B, and inflammatory pathways such as the cyclo-oxygenase pathway, and the upregulation of proinflammatory cytokines such as tumor necrosis factor (TNF)- $\alpha$  and interleukin (IL)-1 $\beta$ .<sup>1</sup> The various factors involved have been integrated into a five-step pathogenesis model.<sup>2,3</sup> Severe oral mucositis (OM) can cause severe pain and adversely affect oral function.<sup>4</sup> Controlling the pain caused by mucosal inflammation is important to maintain the quality of life in these patients. In Japan, doctors usually prescribe 0.8 mg/ml lidocaine mouthwash as an in-hospital remedy for OM pain; however, it has limited analgesic effects. Additionally, the use of lidocaine mouthwash alters one's sense of taste,<sup>5</sup> and the overuse of lidocaine mouthwash may suppress the gag reflex in some patients.<sup>6</sup> For severe OM pain, opioids are occasionally used. However, opioids cause complications such as constipation, pruritus, nausea, and vomiting.<sup>7</sup> In several countries, patients can purchase a mouthwash that contains benzydamine (Diffram oral rinse or spray), a nonsteroidal anti-inflammatory drug (NSAID) used to treat OM pain. Topical NSAIDs penetrate mucosa and are absorbed into tissue, producing analgesic and anti-inflammatory actions. It then acts by inhibition of prostaglandin (PGs) synthesis, by blocking the activity of the precursor enzyme cyclo-oxygenase.<sup>8</sup> According to the results of a randomized, double-blinded, placebo-controlled clinical trial, benzydamine oral rinse was effective, safe, and well tolerated for the prophylactic treatment of radiation-induced OM.<sup>9</sup> Furthermore, in 2014, the Multinational Association of Supportive Care in Cancer/International Society of Oral Oncology Clinical Practice Guidelines recommended the use of benzydamine mouthwash for the prevention of OM in patients with head and neck cancer who were undergoing moderate-dose radiation therapy (up to 50 Gy) without concomitant chemotherapy.<sup>10</sup> However, benzydamine is not approved for use by United States (US) Food and Drug Administration (FDA),<sup>11</sup> and it has never been marketed as an available drug in Japan. Owing to the inadequacy of measures taken against OM pain, in-hospital preparations of indomethacin spray (IMS) have been used in our hospital since 2009, and cancer patients have benefited from its mucosal analgesic action. Similar to benzydamine, indomethacin is an NSAID that can inhibit the production of proinflammatory cytokines such as tumor necrosis factor- $\alpha$  and interleukin-1 $\beta$ . However, the analgesic effects of IMS have not been identified, and



**FIGURE 1** Study design. One patient was transferred to another hospital. Therefore, the PR score over 3 days, which is a comprehensive evaluation of PR 3 days after freely using the indomethacin spray, could only be evaluated for 19 patients. PR, pain relief; VAS, visual analog scale

the in-hospital preparation method of IMS is complex; therefore, it is rarely used in other facilities in Japan. There are few reports on the effects of oral IMS for treating OM pain,<sup>12–14</sup> and no prospective studies have described the efficacy of IMS in large number of cases. Therefore, this study aimed to evaluate the pain-relieving effect of IMS, a nonmarketed in-hospital preparation, on OM in patients receiving anticancer drug treatment.

## 2 | PATIENTS AND METHODS

### 2.1 | Design

This was a single-arm, prospective trial (Figure 1). The study protocol was registered in the national clinical trials registry platform website of the University Hospital Medical Information Network (Tokyo, Japan; protocol ID, UMIN000015816) on December 5, 2014. We used the STROBE cross-sectional reporting guidelines.<sup>15</sup>

### 2.2 | Patient population

Inclusion criteria were patients who had chemotherapy- and/or targeted therapy-induced OM and those who had a numerical rating pain scale score of  $\geq 5$  in our hospital from February 2014 to February 2016. Exclusion criterion was patients who had radiation-induced OM. Six men and 14 women participated in this study. This is an exploratory study; therefore, sample size was not calculated.

### 2.3 | Indomethacin spray

IMS (0.25% indomethacin) was prepared in our hospital as described in a previous report.<sup>13</sup> As indomethacin

is almost insoluble in water, a stock solution was first prepared by dissolving 1.25 g of indomethacin (Fujifilm Wako Pure Chemical Corporation, Osaka, Japan) in 35 ml of 0.2-M  $\text{KH}_2\text{PO}_4$  and 0.2-M NaOH (pH = 8.8). Indomethacin sodium salt was then prepared by adding another 18 ml of 0.2-M NaOH. Next, the pH was adjusted to 7.4 using 6–7 ml of 0.2-M  $\text{KH}_2\text{PO}_4$ . Distilled water was then added to this pH-adjusted solution to obtain a final volume of 100 ml (1.25% stock solution). The stock solution was filter sterilized (0.22- $\mu\text{m}$  pore size). The stock solution was diluted five-fold with Sorensen's isotonic phosphate buffer (pH = 7.4) to obtain a ready-to-use 0.25% indomethacin working solution. The working solution was filter sterilized, transferred to 20-ml containers, and preserved in a dark, cold place (the solution expires after 2 months when stored at 4°C).

## 2.4 | Procedure and measures

The severity of OM was measured using the clinical examination guidelines of the Common Terminology Criteria for Adverse Events, version 3.0.<sup>16</sup> Oral pain severity and the degree of pain relief (PR) were recorded subjectively. The recording sheets were used to record patients' self-assessment result, and alarms were used to remind the patients to perform the evaluation at a fixed time. Oral pain severity was validated using the visual analog scale (VAS), a subjective measure of acute and chronic pain. Our VAS was a 100-mm straight horizontal line with both ends defined as the extreme pain limits measured, and directed from left (no pain) to right (worst pain). Scores were recorded by making a handwritten mark on the line. Patients' oral pain was recorded immediately before and at 30 min after the administration of IMS on separate pieces of paper; measurements were made by a fine ruler that was accurate up to 1 mm, and the data were transferred to the original data forms.<sup>17</sup> This process ensured that the measurements were as independent as possible, and that patients would not rate their pain according to what they had recorded before the administration of IMS. A 5-point categorical (CAT) scale was used to rate PR, where 0 = none, 1 = a little, 2 = moderate, 3 = a lot, and 4 = complete.<sup>18</sup> PR was recorded at 15 min ( $\text{PR}_{15}$ ), 30 min ( $\text{PR}_{30}$ ), and 60 min ( $\text{PR}_{60}$ ) after IMS administration, and PR for each time was digitized using the CAT scale and presented as a boxplot. The total PR effect was assessed at 60 min after IMS administration ( $\text{TOTPAR}_{60}$ ) using the following equation:  $\text{TOTPAR}_{60} = \sum_{t=15,30,60}^n \text{PR}_t$ .<sup>18</sup> After recording the PR score at predetermined time points, the mean PR score after 3 days ( $\text{PR}_{3\text{days}}$ ) of IMS use was determined. In this study, a  $\text{TOTPAR}_{60} \geq 4$  and  $\text{PR}_{3\text{days}} \geq 2$  indicated effective PR.

## 2.5 | Outcomes

Patients were allowed to use three-push single oral doses of IMS (total amount, approximately 0.6 mg of indomethacin); no additional use was allowed until 60 min after the initial IMS administration. However, after 60 min, patients were allowed to freely use IMS for 3 days. Our primary endpoint was the change in VAS scores for OM pain immediately before and at 30 min after the administration of IMS.

## 2.6 | Statistical analyses

Because this was an exploratory study, the sample size was not calculated. Data were analyzed using JMP 13 (SAS Institute Inc., Cary, NC). VAS scores before and at 30 min after the administration of IMS were compared using the Wilcoxon signed-rank test. The mean PR scores at each time point were compared using the Kruskal–Wallis test. For all analyses,  $p < .05$  (two-tailed) was considered statistically significant.

## 3 | RESULTS

Participants' median age was 62.0 years (interquartile range 54.8–66.0). Among them, 11 were inpatients and nine were outpatients. The cancer types were as follows: breast cancer, nine patients; rectal cancer, three patients; renal cancer, two patients; sigmoid colon, two patients; lung cancer, one patient; nasopharynx cancer, one patient; ovarian cancer, one patient; and testicular cancer, one patient. The types of treatment were as follows: cytotoxic chemotherapy, eight patients; molecular-targeted drug therapy, three; and both treatments, nine patients. The region of OM was the tongue in 11 patients, tongue and buccal mucosa in eight patients, and buccal mucosa in one patient. The median OM grade was 2.0 (interquartile range 2.0–2.3) (Table 1).

The VAS scores at 30 min were lower in 90% (18 of 20) of the patients after IMS administration than before IMS administration. The median VAS scores at 30 min after IMS administration were 27.5 mm (interquartile range 17.0–47.3), were 47% lower than those before IMS administration 52.0 mm (interquartile range 46.5–75.0) (Wilcoxon signed-rank test,  $n = 20$ ,  $p = .001$ , Figure 2). Moderate PR was reported by 55% of the patients (11 of 20) at 15 min after IMS administration. At 30 min after IMS administration, eight out of 20 patients reported a PR scale score of 3 (“a lot” of PR). Additionally, 75% (15 of 20) of the patients showed a PR scale score of 2 or 3 (“moderate” PR or “a lot” of PR, respectively) at 15 and 30 min after IMS administration, but only 55% (11 of 20) of patients showed a PR

TABLE 1 Patient characteristics

Case number	Sex	Age (years)	Primary site of cancer	Status	OM grade	Region of oral mucositis	Regimen of chemotherapy and/or targeted therapy
1	M	74	Rectal	Inpatient	3	Tongue Buccal mucosa	FOLFOX + bevacizumab
2	M	69	Renal	Outpatient	2	Tongue	Temsirolimus
3	M	34	Testicular	Inpatient	2	Tongue	BEP
4	F	58	Breast	Inpatient	3	Tongue	Everolimus
5	F	73	Breast	Outpatient	2	Tongue Buccal mucosa	Lapatinib + capecitabine
6	F	51	Breast	Inpatient	2	Tongue	ddEC
7	F	61	Rectal	Inpatient	1	Tongue	FOLFIRI + cetuximab
8	F	64	Breast	Inpatient	3	Tongue	Docetaxel + carboplatin + trastuzumab
9	M	63	Nasopharynx	Inpatient	2	Tongue	Cisplatin + 5-fluorouracil
10	F	66	Breast	Outpatient	2	Tongue Buccal mucosa	Docetaxel
11	F	63	Breast	Inpatient	3	Tongue Buccal mucosa	Lapatinib + capecitabine
12	F	46	Sigmoid colon	Outpatient	2	Tongue Buccal mucosa	FOLFIRI + cetuximab
13	F	55	Rectal	Outpatient	1	Buccal mucosa	FOLFIRI + bevacizumab
14	F	57	Breast	Inpatient	2	Tongue Buccal mucosa	Docetaxel + trastuzumab + pertuzumab
15	F	66	Sigmoid colon	Outpatient	2	Tongue Buccal mucosa	FOLFIRI + bevacizumab
16	F	65	Ovarian	Inpatient	2	Tongue	Docetaxel + carboplatin
17	F	55	Breast	Outpatient	1	Tongue	FEC
18	M	71	Renal	Outpatient	3	Tongue	Sunitinib
19	F	49	Breast	Outpatient	2	Tongue	FEC
20	M	54	Lung	Inpatient	1	Tongue Buccal mucosa	Amrubicin

Abbreviations: BEP, bleomycin + etoposide + cisplatin; ddEC, dose-dense epirubicin + cyclophosphamide; F, female; FEC, 5-fluorouracil + epirubicin + cyclophosphamide; FOLFIRI, folinic acid + 5-fluorouracil + irinotecan; FOLFOX, folinic acid + 5-fluorouracil + oxaliplatin; M, male.

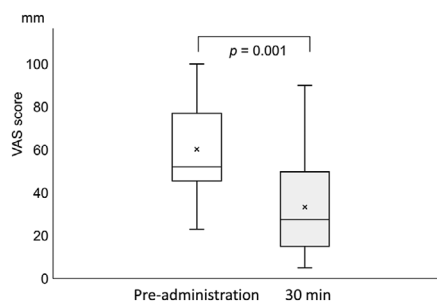
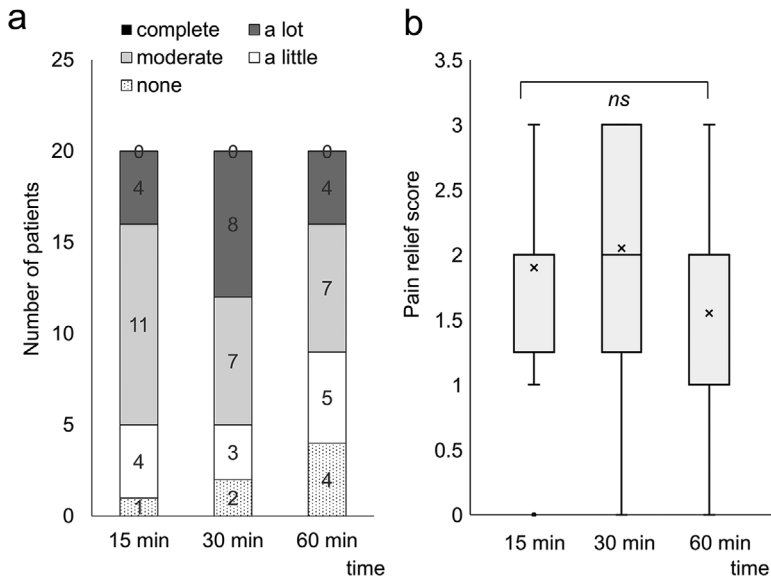


FIGURE 2 Box-and-whisker plots showing VAS scores before and after IMS administration. The ends of boxes represent the upper and lower quartiles; therefore, the box spans the interquartile range. The median is marked with a horizontal line in the box. The whiskers outside the box extend to the highest and lowest observed values. The mean is marked with an asterisk. IMS, indomethacin spray; VAS, visual analog scale

scale score of 2 or 3 (“moderate” PR or “a lot” of PR, respectively) at 60 min after IMS administration (Figure 3A). The mean PR score ( $X = 2.1$ ) was the highest at 30 min after IMS administration; however, there were no significant differences in PR scores across the time points (Kruskal–Wallis test,  $p = .24$ ) (Figure 3B).

Approximately 75% of the patients reported effective pain reduction ( $TOTPAR_{60} \geq 4$ ). The median  $TOTPAR_{60}$  was 6.0 (interquartile range 3.8–7.3), and the median  $PR_{3days}$  was 2.0 (interquartile range 2.0–3.0) (Table 2). After using IMS freely for 3 days, at least moderate PR was achieved in 16 (84.2%) of 19 patients (we could not collect the data from one patient because of her condition) (Table 2). The median number of sprays used over 3 days was 1.0 (interquartile range 1.0–2.0) per day. Among five patients (#1, #9, #13, #15, and #19) with a  $TOTPAR_{60} < 4$ , two patients (#1 and #15) showed moderate or high  $PR_{3days}$ . We did not observe any difference in sex, the primary site of cancer, region of OM, and regimen of chemotherapy and/or targeted therapy among the three patients (#9, #13, and #19) who experienced almost no PR, as indicated by  $TOTPAR_{60}$  and  $PR_{3days}$ , and we could not determine the cause for treatment unresponsiveness. The only common variable among these patients was that all of them were outpatients; however, there were no significant differences in  $TOTPAR_{60}$  or  $PR_{3days}$  between inpatients and outpatients (data not shown). The median mucositis grade and IQR of 12 patients (#4, #5, #6, #7, #8, #10, #11, #12, #16, #17, #18, and #20) with  $TOTPAR_{60}$  of 6 or more was 2 (1.75,



**FIGURE 3** Time series counts of the PR level (A) and PR rated using a categorical (CAT) scale. Each score is presented as a box-and-whisker plot (B). (A) The distribution of the number of PR levels at each time point and (B) the transition of PR scores. PR, pain relief

**TABLE 2** TOTPAR<sub>60</sub> and PR<sub>3days</sub> of each case

Case number	TOTPAR <sub>60</sub>	PR <sub>3days</sub>
1	3	3
2	5	2
3	4	2
4	6	3
5	8	3
6	7	3
7	6	2
8	6	3
9	3	1
10	8	3
11	6	N/A
12	6	2
13	1	1
14	5	2
15	3	2
16	8	2
17	8	4
18	7	2
19	2	1
20	8	3
Median	6	2
IQR	(3.8, 7.3)	(2.0, 3.0)

Abbreviations: IQR, interquartile range; N/A, not applicable; PR<sub>3days</sub>, mean pain relief score after 3 days; TOTPAR<sub>60</sub>, total pain relief after 60 min.

3.00), and the median mucositis grade of eight patients (#1, #2, #3, #9, #13, #14, #15, and #19) with TOTPAR<sub>60</sub> of 5 or less was 2 (2.00, 2.00). No significant difference was found between pain relief level and mucositis grading ( $p = .7644$ ).

#### 4 | DISCUSSION

In this study, we demonstrated the effectiveness of IMS in treating pain due to OM in patients undergoing cancer treatment. The mean VAS scores significantly decreased by 45% at 30 min after the administration of IMS. Comparisons of PR or PR scores at each time point revealed that IMS was most effective at 30 min after it was administered, and 55% of the patients maintained moderate or high PR for up to 60 min after administration. The effects of the spray appeared within 15 min after its use. Hence, for IMS to be effective, it should be administered at 15–20 min before a meal and upon the onset of oral pain. To the best of our knowledge, this study is the first prospective study to describe the efficacy of IMS, and it involved the highest number of cases relative to previously reported studies.<sup>12–14</sup>

A previous study of five patients demonstrated that 0.25% IMS reduced OM pain after hematopoietic stem cell transplantation. The analgesic effects in these patients were recorded using a 5-grade face scale (0–4); the mean grade of pain, which was 3.4 before the use of IMS, declined to 1.8 ( $n = 5$ ) after IMS administration.<sup>12</sup> However, because of the limited number of patients, there is insufficient evidence to confirm the efficacy of IMS. Furthermore, it is unclear when or how often pain scores were recorded after IMS administration, and there was no record of the actual duration of PR. To simplify the current study, patients with radiation-induced OM were excluded; however, IMS may be effective for radiation-induced OM pain. Previously, Momo et al. showed that IMS significantly reduced the radiation-induced OM pain score (face scale) in 13 patients from  $3.2 \pm 0.7$  to  $1.3 \pm 0.8$  ( $p < .01$ ).<sup>14</sup> Similarly, Ebina et al. reported that IMS significantly reduced radiation-induced OM pain scores (face scale) in five patients from  $2.4 \pm 0.4$  to

$1.0 \pm 0.1$  ( $p < .01$ ).<sup>13</sup> These results from a limited number of case studies indicate that IMS may be effective against both drug- and radiation-induced OM.

The US FDA has recommended the use of indomethacin capsules (25 mg) twice or thrice a day to manage pain, and the maximum recommended daily dose of indomethacin for humans is 200 mg.<sup>19</sup> The amount of indomethacin in IMS (20-ml container) prepared in this study was 25 mg. Therefore, even if the patients used all the IMS available in one container in a single day, there are no safety concerns. Nonetheless, the contraindications including hypersensitivity (e.g., anaphylactic reactions and serious skin reactions) to indomethacin, history of asthma, urticaria, other allergy-type reactions after taking aspirin or other NSAIDs, and the setting of coronary artery bypass graft surgery should be considered<sup>20</sup> when prescribing IMS. Furthermore, as with other NSAIDs, elderly patients and patients with a history of peptic ulcer disease and/or gastrointestinal bleeding who take indomethacin are at an increased risk of experiencing serious gastrointestinal events. In this study, there were no oral adverse events, such as apparent pain enhancement or exacerbation of mucositis or systemic adverse events such as peptic ulcer/or gastrointestinal bleeding, including digestive symptoms. In fact, none of the patients had abnormal laboratory data that could be attributed to IMS administration.

There are several limitations to this study. First, it had a single-arm study design, and it was performed in a single facility with a small number of cases. A placebo control group will be needed to prepare for a case-control study to unequivocally prove the efficacy of IMS. Second, this study did not include patients with radio-induced OM. Radio- and chemo-induced oral mucositis have different peaks of severity and improvement. Radio-induced oral mucositis may appear after 3–4 weeks of treatment, and the evolution is progressive if radiation therapy is not ceased. On the other hand, oral mucositis related to chemotherapy tends to increase 1–2 weeks after the start of treatment, followed by improvement.<sup>21</sup> We wanted to evaluate the efficacy of IMS by separating the two types of mucositis with different postonset courses as separate studies. Therefore, further research is needed to evaluate the efficacy of IMS against radiation-induced OM.

## 5 | CONCLUSIONS

Our findings demonstrated that IMS can effectively relieve anticancer drug-induced OM pain and that it may be useful for immediate self-medication. As it can be prepared readily in any hospital, it may be a good alternative to existing analgesics to relieve anticancer drug-induced OM pain in countries where benzydamine hydrochloride products

are not distributed, such as Japan. Our next step will be to study the effects of our in-house formulated IMS on pain caused by radiation-induced mucositis.

## ACKNOWLEDGMENTS

We sincerely thank all the patients who participated in this trial. We thank Editage (<https://www.editage.jp/>) for editing and reviewing this manuscript for English language.

## CONFLICT OF INTEREST

The authors declare that there is no conflict of interest.

## ETHICS STATEMENT

The study was conducted in accordance with the Declaration of Helsinki (as revised in 2013). The study was approved by the Hokkaido Cancer Center Ethics Review Board (clinical study number 26-4). All patients voluntarily agreed to participate in our study, and informed consent was obtained from each participant.

## AUTHOR CONTRIBUTIONS

Shinya Takada, Yoshimasa Kitagawa, and Jun Sato contributed to the study conception and design. Material preparation and data collection were performed by Shinya Takada, Kenji Imamachi, and Minako Edo. Data analysis was performed by Tamotsu Sagawa, Koshi Fujikawa, and Michihiro Ueda. Statistical analysis was performed by Masashi Matsuzaka. The first draft of the manuscript was written by Hironobu Hata. Jun Sato, Yoshimasa Kitagawa, and Kazuhito Yoshikawa commented on previous versions of the manuscript. All authors read and approved the final manuscript.

## DATA AVAILABILITY STATEMENT

The authors have full control of all primary data and have agreed to allow the journal to review the data if requested.

## ORCID

Hironobu Hata  <https://orcid.org/0000-0002-0077-7026>

## REFERENCES

1. Al-Dasooqi N, Sonis ST, Bowen JM, et al. Emerging evidence on the pathobiology of mucositis. *Support Care Cancer*. 2013;21:2075-2083.
2. Sonis ST. The pathobiology of mucositis. *Nat Rev Cancer*. 2004;4:277-284.
3. Lalla RV, Saunders DP, Peterson DE. Chemotherapy or radiation-induced oral mucositis. *Dent Clin North Am*. 2014;58:341-349.
4. Cheng KK, Leung SF, Liang RH, Tai JW, Yeung RM, Thompson DR. Severe oral mucositis associated with cancer therapy: impact on oral functional status and quality of life. *Support Care Cancer*. 2010;18:1477-1485.

5. Asante MA, Northfield TC. Variation in taste of topical lignocaine anaesthesia for gastroscopy. *Aliment Pharmacol Ther.* 1998;12:685-686.
6. Mason L, Moore RA, Edwards JE, Derry S, McQuay HJ. Topical NSAIDs for acute pain: a meta-analysis. *BMC Fam Pract.* 2004;5:10.
7. McNicol E, Horowicz-Mehler N, Fisk RA, et al. Management of opioid side effects in cancer-related and chronic noncancer pain: a systematic review. *J Pain.* 2003;4:231-256.
8. Srinivasan A, Shenai P, Chatra L, Veena KM, Rao PK. Topical drugs for pain relief. *Arch Med Rev J.* 2015;24:92-104.
9. Epstein JB, Silverman S Jr, Paggiarino DA, et al. Benzylamine HCl for prophylaxis of radiation-induced oral mucositis: results from a multicenter, randomized, double-blind, placebo-controlled clinical trial. *Cancer.* 2001;92:875-885.
10. Lalla RV, Bowen J, Barasch A, et al. MASCC/ISOO clinical practice guidelines for the management of mucositis secondary to cancer therapy. *Cancer.* 2014;120:1453-1461.
11. Lalla RV, Sonis ST, Peterson DE. Management of oral mucositis in patients who have cancer. *Dent Clin North Am.* 2008;52:61-77.
12. Nakamura T, Aoyama T, Yanagihara Y, et al. [The effects of Indomethacin spray on the pain of stomatitis in the patients for hematopoietic stem cell transplantation]. *Yakugaku Zasshi.* 2003;123:1023-1029. Article in Japanese.
13. Ebina K, Kizawa Y, Homma M, et al. Indomethacin spray for radiation oral mucositis - a report of five cases. *Palliat Care Res.* 2007;2:301-306. Article in Japanese.
14. Momo K, Homma M, Kambayashi Y, Kohda Y. Indomethacin spray for cancer treatment-induced oral mucositis. *Yakuzaigaku.* 2012;72:15-19. Article in Japanese.
15. von Elm E, Altman DG, Egger M, et al. The Strengthening the Reporting of Observational Studies in Epidemiology (STROBE) statement: guidelines for reporting observational studies. *Int J Surg.* 2014;12:1495-1499.
16. Cancer Therapy Evaluation Program. *Common Terminology Criteria for Adverse Events, Version 3.0.* DCTD, NCI, NIH, DHHS. 2006. [https://ctep.cancer.gov/protocolDevelopment/electronic\\_applications/docs/ctcae3.pdf](https://ctep.cancer.gov/protocolDevelopment/electronic_applications/docs/ctcae3.pdf). Accessed January 31, 2021.
17. Baharvand M, Sarrafi M, Alavi K, Jalali Moghaddam E. Efficacy of topical phenytoin on chemotherapy-induced oral mucositis; a pilot study. *Daru.* 2010;18:46-50.
18. Curtis GB, Johnson GH, Clark P, et al. Relative potency of controlled-release oxycodone and controlled-release morphine in a postoperative pain model. *Eur J Clin Pharmacol.* 1999;55:425-429.
19. US Food and Drug Administration. *Indomethacin Capsules, USP 25 mg.* 2006. FDA PI. [https://www.accessdata.fda.gov/drugsatfda\\_docs/label/2016/018829s0221bl.pdf](https://www.accessdata.fda.gov/drugsatfda_docs/label/2016/018829s0221bl.pdf). Accessed January 31, 2021.
20. Flach AJ. Topical nonsteroidal antiinflammatory drugs in ophthalmology. *Int Ophthalmol Clin.* 2002;42:1-11.
21. Ohrn KE, Wahlin YB, Sjoden PO. Oral status during radiotherapy and chemotherapy: a descriptive study of patient experiences and the occurrence of oral complications. *Support Care Cancer.* 2001;9:247-257.

**How to cite this article:** Hata H, Takada S, Sato J, et al. Analgesic effects of indomethacin spray on drug-induced oral mucositis pain in patients with cancer: A single-arm cross-sectional study. *Spec Care Dentist.* 2021;41:498-504.