



Contents lists available at ScienceDirect

## International Journal of Surgery Case Reports

journal homepage: [www.casereports.com](http://www.casereports.com)

## Xeroderma pigmentosum and renal leiomyosarcoma: A very rare case report association

Rami Boulma<sup>a,d</sup>, Yosra Ben Ahmed<sup>b,d</sup>, Meriem Oumaya<sup>b,d,\*</sup>, Amen Dhaoui<sup>c,d</sup>, Bilel Saidani<sup>a,d</sup>, Hassen Khouni<sup>a,d</sup>, Adnen Chouchen<sup>a,d</sup><sup>a</sup> Department of Surgery, FSI Hospital, La Marsa, Tunisia<sup>b</sup> Department of Pediatric Surgery B, Children Hospital Bechir Hamza, 1007 Tunis, Tunisia<sup>c</sup> Department of Pathology, FSI Hospital, La Marsa, Tunisia<sup>d</sup> University of Tunis El Manar, Tunis, Tunisia

## ARTICLE INFO

## Article history:

Received 12 November 2020

Received in revised form

13 December 2020

Accepted 15 December 2020

Available online 20 December 2020

## Keywords:

Case report

Xeroderma pigmentosum

Renal tumor

Leiomyosarcoma

## ABSTRACT

**INTRODUCTION:** Xeroderma pigmentosum (XP) is a rare genetic disorder causing extreme sensitivity to ultraviolet (UV) rays. It is transmitted by an autosomal recessive mode. This disease is classically characterized by a high risk of skin cancer. The occurrence of extra-dermatological cancers in patients followed for XP has been rarely reported in the literature. We present the case of a 14-year-old adolescent with an exceptional association of XP and renal leiomyosarcoma.

**PRESENTATION OF CASE:** A 14-year-old adolescent was presented with an abdominal mass revealed by hematuria and abdominal pain. Computed tomography (CT) of the abdomen showed an enhancing, heterogeneous right renal mass, consistent with the features of renal tumor. After non conclusive biopsy, a total nephrectomy of the right kidney was performed. Based on gross specimen observation and immunochemical analysis, the patient was diagnosed with high-grade renal leiomyosarcoma. An adjuvant chemotherapy was indicated and the patient was referred to medical oncology.

At 12 months follow-up, the patient is in total remission; The CT scan did not show any locoregional or distant recurrence

**CONCLUSION:** The risk of renal tumor is increased in patients followed for XP. Attending physicians should ask for renal imaging at the slightest sign of clinical call.

© 2020 The Authors. Published by Elsevier Ltd on behalf of IJS Publishing Group Ltd. This is an open access article under the CC BY-NC-ND license (<http://creativecommons.org/licenses/by-nc-nd/4.0/>).

## 1. Introduction

Xeroderma pigmentosum (XP) is a rare genetic disorder causing extreme sensitivity to ultraviolet (UV) rays. It is transmitted by an autosomal recessive mode and caused by a DNA repair defect in cells exposed to UV rays; This leads to genetic alterations with a risk of cancerization [1]. This disease is classically characterized by a high risk of skin cancer [1]. The occurrence of extra-dermatological cancers has been rarely reported in the literature. We present the case of a 14-year-old adolescent in whom the exceptional association: XP and renal leiomyosarcoma was discovered.

We would specify, through our case as well as a review of the literature, the epidemiological features, the clinical presentation, therapeutic characteristics and outcomes of the association of XP and renal tumor. The report has been arranged in line with SCARE guidelines [2].

\* Corresponding author at: Department of Pediatric Surgery B, Children Hospital Bechir Hamza, 1007, Tunis, Tunisia.

E-mail address: [meriem.oumaya@gmail.com](mailto:meriem.oumaya@gmail.com) (M. Oumaya).

<https://doi.org/10.1016/j.ijscr.2020.12.044>

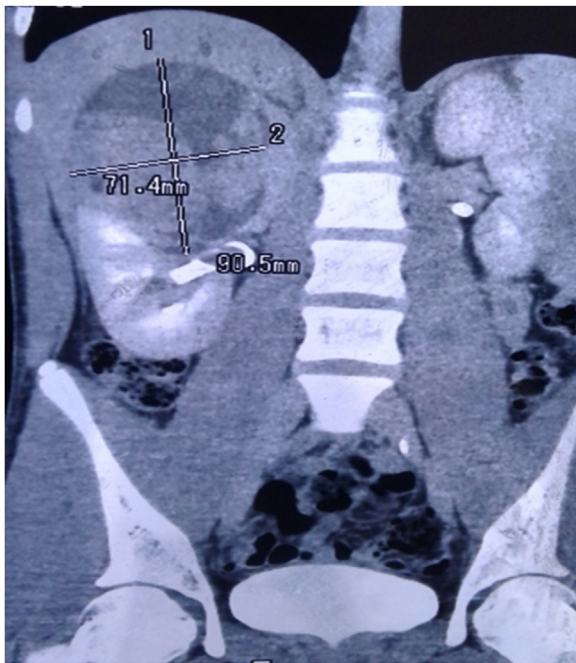2210-2612/© 2020 The Authors. Published by Elsevier Ltd on behalf of IJS Publishing Group Ltd. This is an open access article under the CC BY-NC-ND license (<http://creativecommons.org/licenses/by-nc-nd/4.0/>).

## 2. Presentation of case

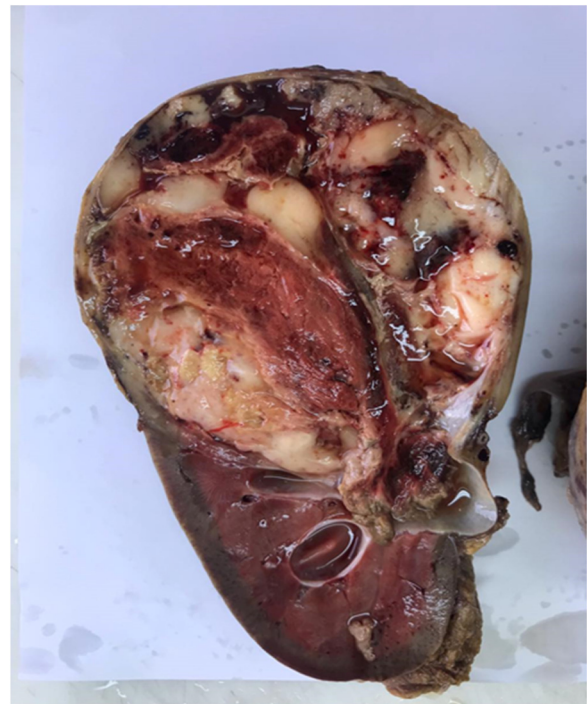A 14-year-old adolescent from a consanguineous marriage was followed in dermatology department for XP since the first month of his life. No prenatal diagnosis has been made, despite a first affected brother and another similar case in the family of the two parents. The patient presented with a chief complaint of abdominal pain and total hematuria for 4 weeks. No fever or voiding disorders were associated. The physical examination revealed: A good general condition with body mass index of 20 kg/m<sup>2</sup>, a normal blood pressure of 100/60 mmHg and thoracoabdominal diffuse hyperpigmentation skin lesions. Abdominal examination revealed a firm non-tender palpable mass situated in the right lumbar and hypochondrium extending to the midline.

The blood investigations showed no renal failure, with normal hemostasis factors. Cytobacteriological urinalysis demonstrated the presence of 500,000 red blood cells per ml with a negative culture.

Abdominal ultrasound revealed a right superior solido-cystic renal mass measuring 9 cm. The contralateral kidney was without abnormalities. In order to better characterize this renal mass and



**Fig. 1.** Computed tomography of abdomen and pelvis (coronal view) showing an enhancing, heterogeneous, 9 × 7 cm mass-situated in the upper polar of the right kidney.



**Fig. 2.** Macroscopic examination revealed a lobulated, grayish white, firm mass in the upper pole, reaching up to the capsule with focal areas of necrosis.

to rule out metastases, a thoraco-abdomino-pelvic CT was performed. It confirmed the presence of an upper right polar renal mass, with a cystic and solid component, measuring 10 × 9 × 7 cm (Fig. 1) significantly enhanced after injection of contrast agent, invading the pelvis, in contact with the inferior side of the liver but was separated from the right adrenal gland. The right renal vein and the contralateral kidney were unharmed. There were no radiological signs suggesting a locoregional or distant metastases.

Given the young age of the patient, the diagnosis of nephroblastoma was possible. A biopsy of the renal mass was decided in view of neoadjuvant chemotherapy. A scan-guided biopsy of the tumor mass was tried. This was complicated by a peri-renal hematoma with a drop in hemoglobin level from 12 g/dl to 10 g/dl. Histological analysis of the biopsy sample was not conclusive; The tissue removed showed normal renal parenchyma.

We decided to operate the patient. A transperitoneal total ureteronephrectomy was performed. The kidney tumor was adherent to the liver in the upper pole. Thus, the release of this pole resulted in a tear of the renal capsule. The kidney biopsy had probably weakened the kidney capsule there. The adrenal gland was spared, and margin status was macroscopically negative.

The postoperative course was uneventful. The patient was discharged home on day 4.

On the section cut of the kidney by pathology, a mass measuring 10 × 10 × 7 cm was found to occupy the entire upper pole of the kidney with capsular rupture. Adjacent ureter, renal vessels and lymph nodes were disease-free with no definitive evidence of lymphovascular invasion. Surgical margins were negative (Fig. 2). Upon microscopic evaluation, numerous spindle tumor cells were present adjacent to uninvolved kidney parenchyma (Fig. 3A,B)

Immunohistochemically, the tumor cells showed diffuse and strong positivity with smooth muscle actin (SMA), desmin and caldesmon while cytokeratin, Wilms Tumor 1 Protein (WT1) and melanoma markers HMB 45 and Melan A were negative.

The final diagnosis of high-grade (Grade 3) leiomyosarcoma was made according to French Federation of Cancer Centers System [3].

An adjuvant chemotherapy was indicated and the patient was referred to medical oncology.

At 12 months follow-up, the patient is in total remission; The CT scan did not show any locoregional or distant recurrence.

### 3. Discussion

XP is a rare disease with an estimated prevalence of 1/300,000 inhabitants, in the United States and Europe. Due to high consanguinity, the prevalence is higher in the Maghreb. In Tunisia the prevalence is estimated at 1/10,000 [1].

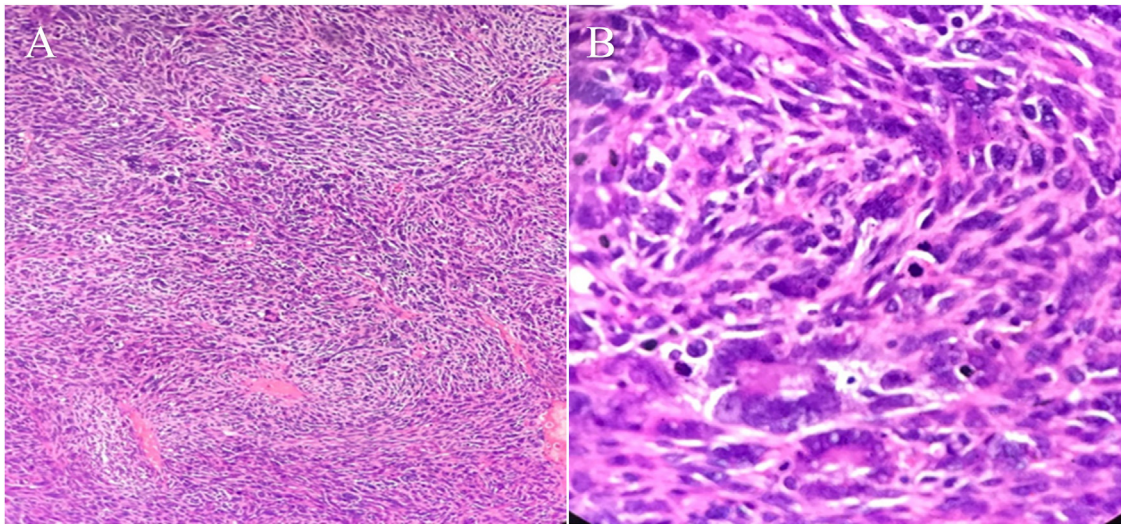
XP is an autosomal recessive genetic disease characterized by hypersensitivity of the skin to UV light. This hypersensitivity is due to genetic abnormalities responsible of a decrease in DNA repair capacity [4]. In fact, in these patients there is a defect in the genes encoding the DNA repair by excision and resynthesis of nucleotides (nucleotid excision repair NER) [5]. Genetic studies have identified seven subgroups of the disease. Each subgroup is characterized by specific genetic abnormalities [5]. This genetic heterogeneity is responsible of the great diversity in the clinical presentation of XP.

However, the common feature for all patients with XP is the high risk of skin cancer. This risk is evaluated to 100 times more compared to a control population. Because of skin cancer, the life expectancy of these patients is greatly affected.

In addition to skin tumors, there is a risk of extra dermatological cancers in case of XP. This risk has been evaluated between 10 and 20 times the general population. Several types of tumors have been reported: acute leukemia, thyroid carcinomas, uterine sarcomas, lung and brain tumors [1]. Less frequently, malignant renal tumors have also been reported in this field. The histologic types of these tumors were: nephroblastoma or Wilms tumor [6,7], mixed epithelial and malignant stromal renal tumor [8]. Only a single case of leiomyosarcoma associated with XP was described [9].

The pathophysiological mechanisms of the occurrence of tumors in internal organs, not exposed to UV rays have not been elucidated in patients suffering from XP. This could be explained





**Fig. 3.** Fascicular arrangement of spindle tumor cells (Low: A and High: B magnification).

by the genetic anomalies of some subtypes. In XP subtype C, for example, there is alterations in the DNA of cells of the central nervous system, despite the fact that these cells are not exposed to UV. These alterations are normally repaired by the same NER DNA repair systems that are deficient in XP and probably explain the neurological signs observed in these XP subtypes [10,11].

Thus, there is an increased susceptibility in XP to DNA damage affecting several types of cells, due to the DNA repair defects. This susceptibility could explain the occurrence of neuropathy and extra-dermatological cancers [5]. There is a weaker DNA repair capacity, which can be damaged by UV rays as well as by other aggressive factors: oxidative stress, tobacco, etc. These hypotheses were supported by the work of kun doo et al. [11] which showed, on a meta-analysis, a higher frequency of bladder cancer in XP subtype C, due to a repair defect in bladder cell DNA exposed to tobacco smoke. Thus, the occurrence of renal tumor during XP could be due to the accumulation of mutations by ineffective DNA repair.

The occurrence of renal leiomyosarcoma in case of XP is exceedingly rare and our case represents the 2nd case reported in the literature.

Renal leiomyosarcoma is a very rare tumor, accounting for 0.12% of malignant kidney tumors. These tumors are mostly seen in people over 45 years old. There is a female predominance of this type of tumor in the literature, probably related to certain genes on the X chromosome [12].

The clinical presentation of leiomyosarcoma is quite comparable to other renal tumors. These are often hematuria, abdominal pain [13]. Imaging is also nonspecific and cannot distinguish leiomyosarcoma from renal cell carcinoma. The most common CT signs are: a tissue mass, with significant enhancement, hypodense foci due to tumor necrosis and sometimes signs of locoregional invasion [14].

Macroscopic examination shows a large tumor [12]. Microscopically, this tumor is characterized by: cell necrosis, nuclear polymorphism and high mitotic rate. All these elements underline the high tumor aggressiveness of leiomyosarcoma, capable of rapid invasion of surrounding tissues. In fact, renal capsular involvement is found in 55% of cases and lymphovascular invasion in 26% [12]. For our patient, capsular breakage is probably due to both tumor aggressiveness and weakening from the previous biopsy.

The immunohistochemical profile of leiomyosarcoma is in favor of smooth muscle differentiation, with positivity of: Caldesmon, Desmine, actin and calponin. Immunohistochemical examination is essential in making the differential diagnosis with certain types

of tumors when histological examination does not allow a decision [15].

The overall prognosis of renal leiomyosarcoma is very poor. Miller et al. [12] who reported one of the largest series of renal leiomyosarcoma, note after a mean follow-up of 2.8 years, distant metastases in 90% and specific mortality affecting 75% of patients.

Given the high potential for local and distant malignancy, the treatment of choice for renal leiomyosarcoma is enlarged nephrectomy [12]. Conservative surgical treatment has been attempted in exceptional cases of low-grade, low-volume tumor with a unique kidney [16].

Neoadjuvant chemotherapy has been prescribed by some authors [11], if a preoperative diagnosis was possible. Positive results have been published by some authors reporting a remission of 6.5 years for low-grade leiomyosarcoma, with the combination of: enlarged nephrectomy, chemotherapy and radiotherapy [17].

However, all these cases are small series, without the possibility of drawing a clear consensus of management.

#### 4. Conclusion

Xeroderma pigmentosum (XP) is a rare autosomal genetic disease mainly reported in the Maghreb. This pathology is classically characterized by a high risk of skin cancer. Renal cancers are also more frequent in XP patients comparing to control population. However, renal leiomyosarcoma remains exceedingly rare. While the prognosis is poor, radical nephrectomy remains the treatment of choice. The potential benefits of adjuvant therapy should be discussed with selected patients.

The attending physicians must be aware of this risk and renal imaging should be performed at the slightest clinical sign.

#### Conflicts of interest

There are no conflicts of interest.

#### Funding

No sources of funding.

#### Ethical approval

The study is exempt from ethical approval.

## Consent

Written informed consent was obtained from the patient for publication of this case report and accompanying images. A copy of the written consent is available for review by the Editor-in-Chief of this journal on request.

## Author contribution

1. Study concept and design: Rami Boulma
2. Data collection and interpretation: Meriem Oumaya and Yosra Ben Ahmed
3. Interpretation and organisation of figures: Meriem Oumaya and Amen Dhaoui
4. Writing the paper: Rami Boulma and Bilel Saidani
5. Critical revision of the manuscript for important intellectual content: Yosra ben Ahmed and Meriem Oumaya
6. Study supervision: Hassen Khouni and Adnen Chouchen

## Registration of research studies

Not applicable.

## Guarantor

Meriem Oumaya.

## Provenance and peer review

Not commissioned, externally peer reviewed.

## References

- [1] M. Zghal, B. Fazaa, S. Abdelhak, M. Mokni, Xeroderma pigmentosum, *Ann. Dermatol. Venereol.* 145 (11) (2018) 706–722.
- [2] R.A. Agha, M.R. Borrelli, R. Farwana, K. Koshy, A.J. Fowler, D.P. Orgill, et al., The SCARE 2018 statement: Updating consensus Surgical CAse REport (SCARE) guidelines, *Int. J. Surg.* 60 (December) (2018) 132–136.
- [3] J.M. Coindre, Grading of soft tissue sarcomas - review and update, *Arch. Pathol. Lab. Med.* 130 (2006) 1448–1453.
- [4] O. Black, Xeroderma pigmentosum, *Head Neck Pathol.* 10 (2) (2016) 139–144.
- [5] P.J. Brooks, The case for 8,5'-Cyclopurine-2'-deoxynucleosides as endogenous DNA lesions that cause neurodegeneration in xeroderma pigmentosum, *Neuroscience* 145 (4) (2007) 1407–1417.
- [6] F. Lahlimi, M. Harif, J. Elhoudzi, Xeroderma pigmentosum et néphroblastome: une association rare, *Arch. Pédiatrie* 23 (1) (2016) 75–77.
- [7] R. Visweswara, A. Osman, S. Majeed, A. Sherghin, M. Muttardi, Xeroderma pigmentosum with adult Wilms' tumor. A rare association, *Scand. J. Urol. Nephrol.* 31 (1997) 569–571.
- [8] I. Smichi, A. Zehani, I. Chelly, et al., À propos d'une tumeur rarissime du rein: la tumeur mixte épithéliale et stromale maligne, *Progrès En Urol.* 25 (6) (2015) 293–297.
- [9] M. Tomás, A.S. Salinas, J. Moreno, G. Server, Renal leiomyosarcoma associated with xeroderma pigmentosum, *Arch. Esp. Urol.* 42 (5) (1989) 484–486.
- [10] H.R. Rezvani, F. Mazurier, F. Morice-Picard, et al., Xeroderma pigmentosum: clues to understanding cancer initiation, *Dermatologia Sin.* 28 (3) (2010) 93–101.
- [11] K. Dou, X. Qingzhu, H. Xiaolu, The association between XPC Lys939Gln gene polymorphism and urinary bladder cancer susceptibility: a systematic review and meta-analysis, *Diagn. Pathol.* 8 (1) (2013) 112–119.
- [12] J.S. Miller, M. Zhou, F. Brimo, C. Guo, J. Epstein, Primary leiomyosarcoma of the kidney: a clinicopathologic study of 27 cases, *Am. J. Surg. Pathol.* 34 (2) (2010) 238–242.
- [13] Y.S. Kwon, A. Salmasi, C.S. Han, D.C. Hon, E.A. Singer, Renal leiomyosarcoma: case report and review of the literature, *World J. Nephrol. Urol.* 4 (2) (2015) 213–217.
- [14] V.S. Katabathina, R. Vikram, A.M. Nagar, M. Tamboli, C. Menias, S.R. Prasad, Mesenchymal neoplasms of the kidney in adults: imaging spectrum with radiologic-pathologic correlation, *Radiographics* 30 (6) (2010) 1525–1540.
- [15] H. Ozturk, High-grade primary renal leiomyosarcoma, *Int. Braz. J. Urol.* 41 (2) (2015) 304–311.
- [16] A. Demir, C.M. Yazıcı, F. Eren, L. Turkeri, Case report: good prognosis in leiomyosarcoma of the kidney, *Int. Urol. Nephrol.* 39 (1) (2007) 7–10.
- [17] D. Sharma, S. Pradhan, N.C. Aryya, V.K. Shukla, Leiomyosarcoma of kidney- a case report with long term result after radiotherapy and chemotherapy, *Int. Urol. Nephrol.* 39 (2) (2007) 397–400.

## Open Access

This article is published Open Access at [sciencedirect.com](https://www.sciencedirect.com). It is distributed under the [IJSCR Supplemental terms and conditions](#), which permits unrestricted non commercial use, distribution, and reproduction in any medium, provided the original authors and source are credited.