

Review article

The underpinnings of cerebellar ataxias

Mario Manto

Service des Neurosciences, Université de Mons, Belgium
Unité des Ataxies Cérébelleuses, Service de Neurologie, CHU-Charleroi, Belgium



ARTICLE INFO

Article history:

Received 25 March 2022
Received in revised form 7 October 2022
Accepted 6 November 2022
Available online 17 November 2022

Keywords:

Cerebellum
Cerebellar cortex
Purkinje neurons
Interneurons
Cerebellar nuclei
Motor
Cognition
Internal models
Dysmetria
Ataxia
Therapies

ABSTRACT

The human cerebellum contains more than 60% of all neurons of the brain. Anatomically, the cerebellum is divided into 10 lobules (I–X). The cerebellar cortex is arranged into three layers: the molecular layer (external), the Purkinje cell layer and the granular layer (internal). Purkinje neurons and interneurons are inhibitory, except for granule cells. The layer of Purkinje neurons inhibit cerebellar nuclei, the sole output of the cerebellar circuitry, as well as vestibular nuclei. The cerebellum is arranged into a series of olivo-cortico-nuclear modules arranged longitudinally in the rostro-caudal plane. The cerebro-cerebellar connectivity is organized into multiple loops running in parallel. From the clinical standpoint, it is now considered that cerebellar symptoms can be gathered into 3 cerebellar syndromes: a cerebellar motor syndrome (CMS), a vestibulocerebellar syndrome (VCS) and a cerebellar cognitive affective syndrome/Schmahmann syndrome (CCAS/SS). CMS remains a cornerstone of modern clinical ataxiology, and relevant lesions involve lobules I–V, VI and VIII. The core feature of cerebellar symptoms is dysmetria, covering motor dysmetria (errors in the metrics of motion) and dysmetria of thought. The cerebellar circuitry plays a key-role in the generation and maintenance of internal models which correspond to neural representations reproducing the dynamic properties of the body. These models allow predictive computations for motor, cognitive, social, and affective operations. Cerebellar circuitry is endowed with noticeable plasticity properties.

© 2022 International Federation of Clinical Neurophysiology. Published by Elsevier B.V. This is an open access article under the CC BY-NC-ND license (<http://creativecommons.org/licenses/by-nc-nd/4.0/>).

Contents

1. History of cerebellar research	373
2. Structural anatomy	373
3. Cellular physiology.....	375
3.1. Firing of Purkinje neurons: Simple spikes and complex spikes	375
3.2. Sculpting motor commands via rebound depolarization	375
3.3. Cerebellar circuitry is endowed with multiple plasticity mechanisms	375
4. The Olivo-Cortico-Nuclear cerebellar modules.....	375
5. Cerebro-Cerebellar Connectivity: The multiple Cerebello-Cerebral loops.....	377
5.1. Anatomical cerebro-cerebellar loops	377
5.2. Functional organization	378
6. Neurophysiological aspects of cerebello-cerebral interactions and control of timing	379
7. Cerebellum as a tuner of motor and non motor tasks	380
8. The cerebellar reserve	381
9. Cerebellar syndrome at the 21th century	383
9.1. Control of speech	383
9.2. Control of limb movements	384
9.3. Control of stance and gait	384
10. Conclusion	385
Declaration of Competing Interest	385
References	385

E-mail address: mario.manto@ulb.be

<https://doi.org/10.1016/j.cnp.2022.11.002>

2467-981X/© 2022 International Federation of Clinical Neurophysiology. Published by Elsevier B.V.
This is an open access article under the CC BY-NC-ND license (<http://creativecommons.org/licenses/by-nc-nd/4.0/>).

1. History of cerebellar research

The cerebellum has been a subject of scientific interest from Antiquity. The first clear anatomical report of the anatomy of the cerebellum was provided by Malacarne during the 18th century (Zanatta et al. 2018). This scientist introduced several terms which have remained in the current terminology, such as vermis, tonsil, pyramid, and uvula. Malacarne was also probably the first to suggest that the environment impacted on the number of folia. He proposed that the number of folia was associated with the degree of intelligence.

At the beginning of the 19th century, Rolando noted that cerebellar lesions weaken voluntary movements and posture (Schmahmann, 2016). The first scientist linking cerebellar lesions with a lack of coordination was Flourens. Histologically, Purkinje discovered a monolayer of cerebellar cortical cells in 1838 and left his name. Luciani reported a triad in animals (dogs, primates): atonia (decreased resistance following a passive manipulation), asthenia (compared to a paresia of movement), and astasia (involuntary oscillations during a movement) (Luciani, 1891). Later, he described dysmetria as an error in the metrics of movement. He was the first to report the phenomenon of compensation/decompensation: cerebellar deficits recover after a first lesion and reappear after a lesion of the contralateral motor cortex. However, he refuted the role of the cerebellum in motor coordination. Babinski underlined the role of the cerebellum in the fight against inertia and reported on asynergia (Babinski, 1899). He described dysdiadochokinesia (impaired successive movements) for the first time and cerebellar catalepsy in case of severe hypotonia (extreme immobility during flexion of lower limbs). At the beginning of the following century, Cajal defined with details the fine network structure of the cerebellar cortex. This is a historical landmark for the understanding of the neuronal connectivity of the cerebellar cortex. Simultaneously, the motor deficits in patients were reported in cerebellar patients by Holmes who observed carefully soldiers with gunshot injuries to the cerebellum (Holmes, 1917). Holmes explained with details the errors in the metrics of voluntary movements, providing also the first recordings of motor dysmetria in humans. He considered that dysmetria and kinetic tremor were included in astasia. Another important step was reached with the identification of the 10 lobules (I–X) of the cerebellum by Larsell. The importance of anatomical loops between the cerebellum and cerebral cortex was emphasized at the end of the 20th century. At the same time, Schmahmann reported the cognitive and affective deficits in cerebellar ataxias, clarifying the third cornerstone of modern clinical ataxiology (Manto and Mariën, 2015).

2. Structural anatomy

The cerebellum contains more than 60 % of all neurons of the brain, occupying only 10 % of brain volume. Structurally, the cerebellum contains 4 pairs of nuclei. These nuclei (often called deep cerebellar nuclei, although this terminology is likely inappropriate given the absence of superficial cerebellar nuclei) are located in the white matter which is surrounded by the cerebellar cortex (Colin et al., 2002). One major feature of cerebellar anatomy is the homogeneity of the cerebellar cortex geometry in terms of cellular arrangement. The cerebellar hemispheres have expanded notably in mammals. The medio-lateral growth of cerebellar hemispheres occurs simultaneously to the expansion of the cerebral cortex. The interactions between cerebellum and cerebral cortex increased during the phylogenetic expansion, increasing dramatically information coding and processing capacity (Huang and Ricklefs, 2013). Some authors have argued that the constancy of the cere-

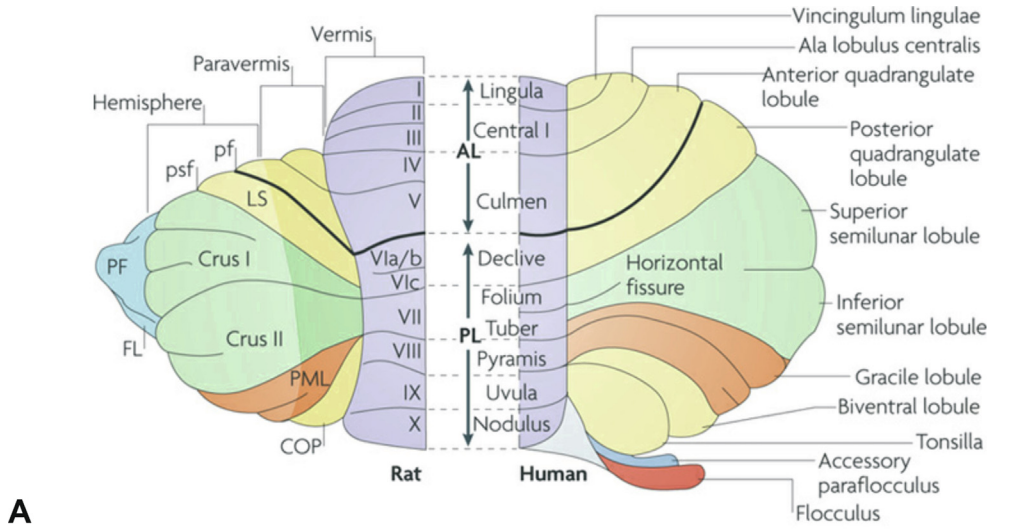
bellar fraction in birds and mammals (about 10–15 % of the whole brain) helps to consider that the cerebellum is a general-purpose computational machine with plasticity characteristics (Huang and Ricklefs, 2013; Herculano-Houzel, 2010).

The cerebellum is highly conserved across mammals. The general aspect is illustrated in Fig. 1. The primary fissure separates the anterior lobe from the posterior lobe, and the posterolateral fissure delineates the posterior lobe from the flocculonodular lobe. The pioneering works of Jansen, Larsell, Dow, and Voogd have paved the way to our current understanding of the global structural organization of the cerebellum (Colin et al., 2002). Jansen considered an anterior lobe, a posterior lobe, and the flocculus/paraflocculus. Larsell divided the cerebellum into 10 lobules (numbered I to X). Dow proposed a subdivision into (a) a vestibulocerebellum (corresponding to the flocculonodular lobe), (b) a paleocerebellum (corresponding to the spinal projections to the cerebellum: spinocerebellum), and (c) a neocerebellum (on the basis of ponto-cerebellar projections) whose growth has been particularly marked during evolution (Cantalupo and Hopkins, 2010).

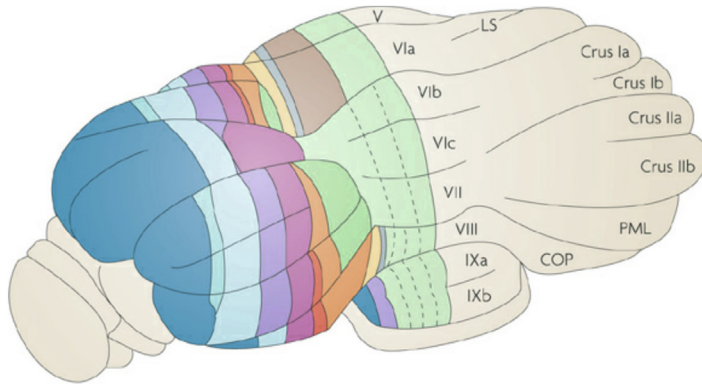
Three layers compose the cerebellar cortex: the molecular layer (external), the Purkinje cell layer (ganglionic layer) and the granular layer (internal) (Fig. 2). Six main neuronal populations (Purkinje, stellate, basket, Lugaro, Golgi and granule cells) occupy the cerebellar cortex. They are all inhibitory (GABAergic), except for the granule cells which are excitatory (glutamatergic). Purkinje neurons exert a strong inhibition via GABA release upon cerebellar nuclei. They also inhibit the vestibular complex composed of the descending, lateral, medial, superior and parasolitary nuclei, all located below the dorsal surface of the medullary brainstem.

The number of Purkinje neurons is about 15 million in the human cerebellum (Colin et al., 2002). Purkinje neurons target cerebellar nuclei and vestibular nuclei. The primary dendrite of the Purkinje neuron is directed externally towards the molecular layer. The dendritic tree within the molecular layer is particularly rich in spines, with a width of about 300 μm . The dendritic spines are the target of parallel fibers emerging from granule cells. The massive convergence of inputs from parallel fibers to Purkinje dendritic trees contributes to the integration of information from different sources. The proximal portion of the primary dendrite of Purkinje cell is surrounded by a climbing fiber originating from the contralateral inferior olive, with a 1:1 relationship. This synapse is one of the most powerful synapses in the CNS.

Three types of fibers provide the afferent information to the cerebellar circuitry. First, the climbing fibers emerge from the contralateral inferior olive and enter in the inferior cerebellar peduncle (also called restiform body). The inferior olivary complex is composed of about 1.5 million cells, with functional units tending to fire synchronously because of gap junctions (Colin et al., 2002). Second, the mossy fibers have multiple origins in the spinal cord and brainstem, conveying numerous types of information: somesthetic, vestibular, visual, acoustic, and cortical. Mossy fibers include projections from the crossed and uncrossed spinocerebellar tracts (dorsal spinocerebellar tract or Flechsig's tract arising from Clarke's column, ventral spinocerebellar tract or Gower's tract, cuneocerebellar tract, rostral spinocerebellar tract), the vestibular afferents projecting to vestibulocerebellum (flocculus, paraflocculus, nodulus, uvula), the acoustic/visual/trigeminal afferents, the reticular nuclei (mainly the lateral reticular nucleus, the nucleus reticularis tegmenti pontis, the paramedian reticular nucleus), the pontine nuclei at the origin of the ponto-cerebellar tracts. Third, the cholinergic/monoaminergic afferents include noradrenergic fibers, dopaminergic fibers, and serotonergic fibers. They are considered as having a modulatory role in the cerebellar circuitry (Colin et al., 2002).



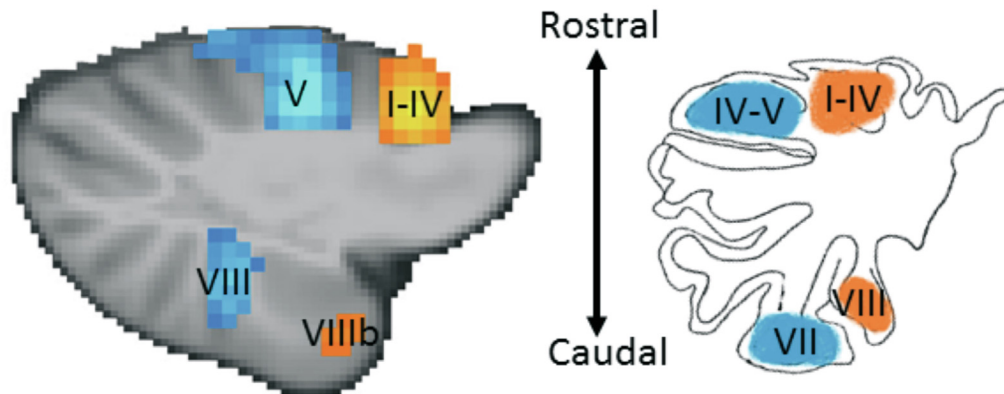
A



B

Hemisphere			Paravermis				Vermis					
D2	D0	D1	C3	C2	CX	C1	A2	B	X	AX	A	Inferior olive (input)
dlPO	dmPO	vlPO	vfDAO	rMAO	iMAO (med)	vfDAO	cMAO (subnuc b/c)	dfDAO	iMAO (lat)	cMAO (subnuc a)	cMAO (subnuc b)	
NL (parvo)	DLH	NL (magno)	NIA	NIP	ICG; NIP	NIA	DLP	LVN	ICG; NIP	MedN (lat; ICG)	MedN (lat; ICG)	Cerebellar nuclei (output)

C



In human, the medial nucleus is called the fastigial nucleus, the globosus nucleus corresponds to the anterior interpositus, the emboliformis nucleus to the posterior interpositus and the dentate nucleus to the lateral nucleus (Colin et al., 2002). The dentate nucleus is the largest cerebellar nucleus. It has a convoluted appearance with a hilus medially. The tracts leaving the cerebellar nuclei (nucleofugal tracts) are glutamatergic, except for the nucleo-olivary tract which is GABAergic and inhibits the inferior olive. Cerebellar nuclei receive excitatory collaterals of both mossy fibers and climbing fibers.

Thanks to major progress in neuroimaging techniques, the anatomy of the cerebellum and the major cerebellar inflow/outflow tracts can now be tracked in vivo, as illustrated in Figs. 3, 4 and 5 showing the tracing based on tractography. Tractograms (DTI: diffusion tensor imaging) of the cortico-pontine tract, the ponto-cerebellar tract, the olivo-cerebellar tract, and the dentato-thalamo-cortical tract can be extracted using MRI.

3. Cellular physiology

3.1. Firing of Purkinje neurons: Simple spikes and complex spikes

One major and unique electrophysiological property of Purkinje neurons resides in their action potentials. Indeed, two types of action potentials are recorded. The first type is a conventional action potential (called simple spike). This is a typical voltage-gated sodium channel-dependent action potential. The second action potential is composed of a burst of decremting spikes (called complex spikes) (Otis, 2016). Complex spikes are sodium channel driven spikelets on a depolarized plateau potential.

At rest, Purkinje neurons fire spontaneously at a regular and high frequency of about 40–85 Hz (simple spikes), inhibiting tonically the cerebellar nuclei and vestibular nuclei (Otis, 2016). The frequency of complex spikes is much lower (about 1 Hz) at the level of the Purkinje neuron. The number of simple spikes is reduced after a complex spike (“post-complex spike pause”) and rates of complex spikes and simple spikes are anticorrelated in response to sensory stimulation (Barmack and Yakhnitsa, 2011).

3.2. Sculpting motor commands via rebound depolarization

Cerebellar nuclei neurons receive 2 excitatory inputs (via collateral projections from mossy and climbing fibers) and 1 strong inhibitory projection from Purkinje cells. Nuclear neurons discharges are characterized by a rebound in firing following a hyperpolarization (Dykstra and Turner, 2016). The rebound is composed of 2

phases: a first increase in the firing frequency of about 100 Hz with a contribution of T-type calcium currents, followed by a second rebound lasting several seconds with a contribution of persistent sodium currents. The current interpretation is that the rebound allows to sculpt nuclear commands towards extra-cerebellar nuclei (Dykstra and Turner, 2016).

3.3. Cerebellar circuitry is endowed with multiple plasticity mechanisms

Both learning and compensatory processes require plasticity mechanisms (see also Section 8). Cerebellum is enriched in multiple plasticity mechanisms at multiple sites, taking advantage of the redundancy of inputs (Fig. 6). The most studied is long-term depression (LTD), which is thought to be critical for motor learning. A concomitant stimulation at a low frequency of the climbing fiber (source: inferior olive) and a parallel fiber (source: granule cell) induces a persistent weakening of the parallel fiber-Purkinje cell synapse (Ito et al., 1982). LTD is associative and saturable. LTP implicates mGluR receptors, clathrin-dependent AMPAR endocytosis, and subsequent rise in internal Ca⁺⁺ (Shen, 2016).

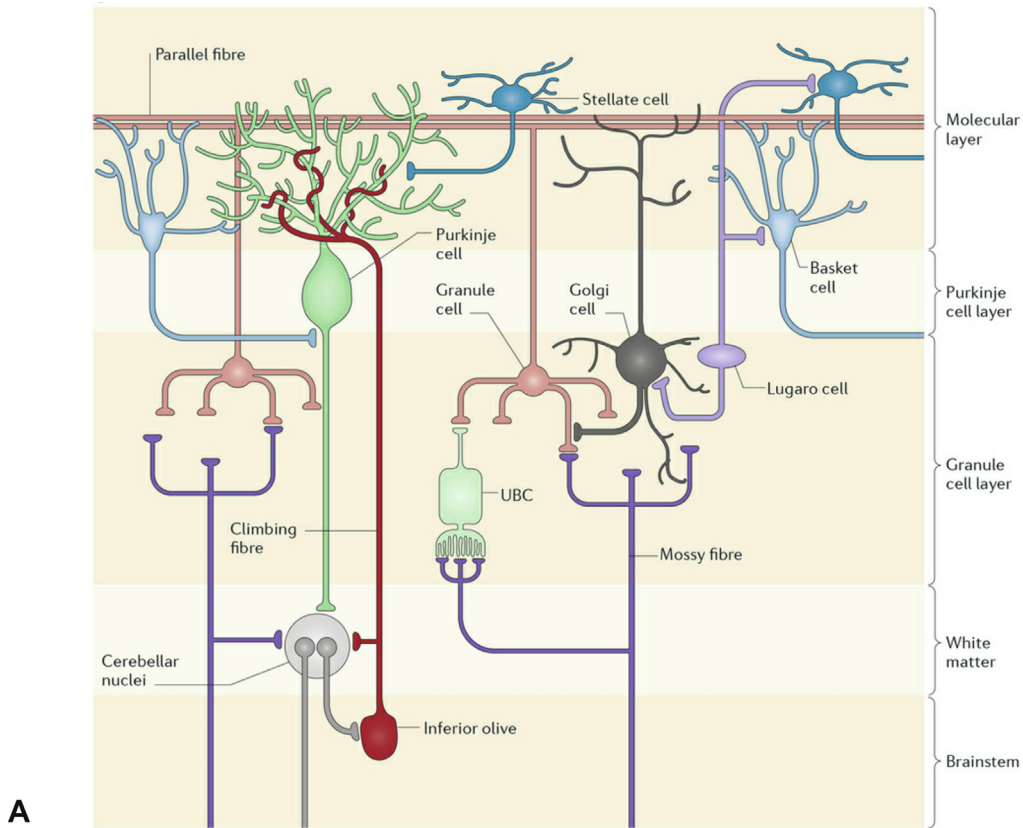
Other forms of plasticity include:

- a spike-timing dependent plasticity (STDP): when the parallel fiber stimulation precedes the climbing fiber-evoked complex spikes by 50–250 msec
- homosynaptic long-term potentiation (homosynaptic LTP): it combines the 1 Hz-post-synaptic LTP and 4–8 Hz pre-synaptic LTP. The 1 Hz LTP might be a resetting mechanism for motor learning purposes
- LTP between interneurons and Purkinje neurons: to tune the spike firing pattern of Purkinje neurons (Häusser and Clark, 1997)
- LTP between the mossy fiber-granule cell synapse, tuning the local coding in the granular layer.

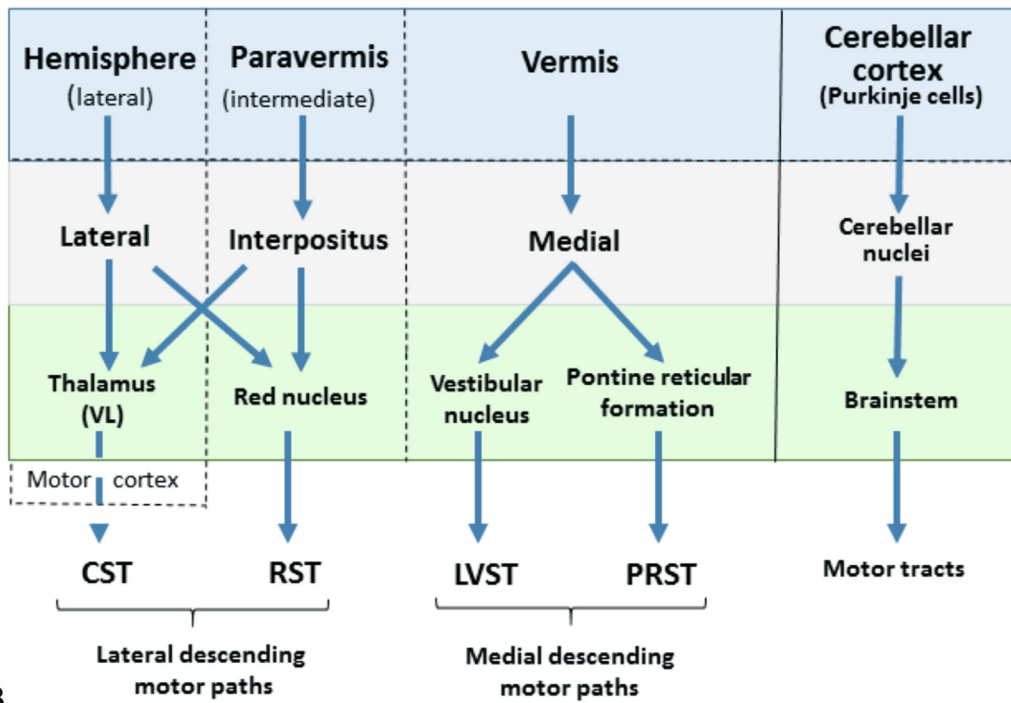
4. The Olivo-Cortico-Nuclear cerebellar modules

The cerebellum is composed of modules arranged longitudinally in the rostro-caudal plane (see also Fig. 1). The white matter of the cerebellum is divided into long longitudinal strips (Voogd and Glickstein, 1998). There are 8 major bands (A, X, B, C1, C2, C3, D1, D2), each of which projects to well-circumscribed regions of cerebellar nuclei and receives climbing fibers from specific areas of the inferior olive (Colin et al., 2002). A given subdivision of the inferior olivary complex targets one or more longitudinal zones of Purkinje

Fig. 1. A. Simplified dorsal view of the rat cerebellum (left) and human cerebellum (right). Equivalent regions in the rat and human cerebellum are given the same color. Note the three longitudinal compartments (the vermis, the paravermis and the hemisphere) indicated on the left. In the rat, lobules in the vermis are numbered according to Larsell's schema, whereas in the human, the corresponding nomenclature as described by Bolk is shown. The primary fissure (pf) dividing the anterior and posterior lobes is highlighted in bold. AL, anterior lobe; PL, posterior lobe. PML, paramedian lobule; COP, copula pyramidis; PF, paraflocculus; FL, flocculus; psf, posterior superior fissure. B. Dorso-posterior view of the rat cerebellum, indicating on the left-hand side the approximate location of different longitudinal zones on the cerebellar surface. Each longitudinal zone is defined by its climbing fiber input from a specific subdivision of the inferior olive and Purkinje cell output to a specific territory within the cerebellar nuclei. From medial to lateral (right to left in the figure) are shown: the A, AX, X, B and A2 zones (in the vermis), the C1, CX, C2 and C3 zones (in the paravermis), and the D1, D0 and D2 zones (in the hemisphere). Longitudinal zones in the paraflocculus and flocculus are not shown. cMAO (subnuc a), subnucleus a of caudal medial accessory olive; cMAO (subnuc b), subnucleus b of caudal medial accessory olive; cMAO (subnuc b1/c), subnucleus b1 and c of caudal medial accessory olive; COP, copula pyramidis; dDAO, dorsal fold of dorsal accessory olive; DLH, dorsolateral hump; DLP, dorsolateral protuberance of medial nucleus; dlPO, dorsal lamella of the principal olive; dmPO, dorso-medial subnucleus of the principal olive; ICG, interstitial cell group; iMAO (lat), lateral part of intermediate medial accessory olive; iMAO (med), medial part of intermediate medial accessory olive; LVN, lateral vestibular nucleus; LS, lobulus simplex; MedN (lat), lateral part of medial nucleus; MedN (med), medial part of medial nucleus; NIA, nucleus interpositus anterior; NIP, nucleus interpositus posterior; NL (magno), magnocellular part of lateral nucleus. NL (parvo), parvocellular part of lateral nucleus; PML, paramedian lobule; rMAO, rostral medial accessory olive; vfDAO, ventral fold of dorsal accessory olive; vlPO, ventral lamella of the principal olive. C. Somatotopical organization within the cerebellum is highly conserved across species. Parasagittal view of the human (left) and rat (right) cerebellar cortex, showing a dual representation of the leg/hindlimb (orange) and the hand/forelimb (blue). In the human, BOLD signal was measured with high resolution fMRI at 3 T. The blue areas indicate regions where BOLD signal was greater during movement of the ipsilateral right hand than during movement of the ipsilateral right foot. The orange areas reflect the reverse contrast (foot > hand). The results were obtained after field-map un-warping and physiological noise correction, and represent a mixed effects analysis of 20 subjects, with a cluster forming threshold of Z greater than 3.09 and FWE corrected cluster significant level of P < 0.05. In the rat, the somatotopically defined regions were determined by recording climbing fiber potentials evoked within the cerebellar cortex or on the surface of the cerebellum in response to low threshold electrical stimulation of the ipsilateral forelimb or hindlimb. Scale bar 1 cm for human cerebellum and ~ 2 mm for rat. From: Ashida et al. (2018). With permission. (For interpretation of the references to color in this figure legend, the reader is referred to the web version of this article.)



A



B

Fig. 2. A. Representation of the principal features of cerebellar cytoarchitecture. Purkinje cells are the output cells of the cerebellar cortex; granule cells, Golgi cells, Lugaro cells, unipolar brush cells (UBCs), stellate cells and basket cells are interneurons. The two main types of afferents that project to the cerebellum are the climbing fibers, which synapse directly with Purkinje cells, and the mossy fibers, which synapse with granule cells. Axons of the granule cells ascend to the molecular layer, where they bifurcate to form parallel fibers, which extend for several millimeters along the folia of cerebellar lobules. Monoaminergic fibers are not shown. B. Simplified diagram showing pattern of outflow from the three cerebellar compartments on each side of the midline (from left to right: hemisphere, paravermis and vermis) and their corresponding brainstem and thalamic/motor cortical connections to different descending motor tracts. CST, Corticospinal tract; LVST, Lateral vestibulospinal tract; PRST, Pontine reticulospinal tract; RST, Rubrospinal tract. From: [Ashida et al. \(2018\)](#). With permission.

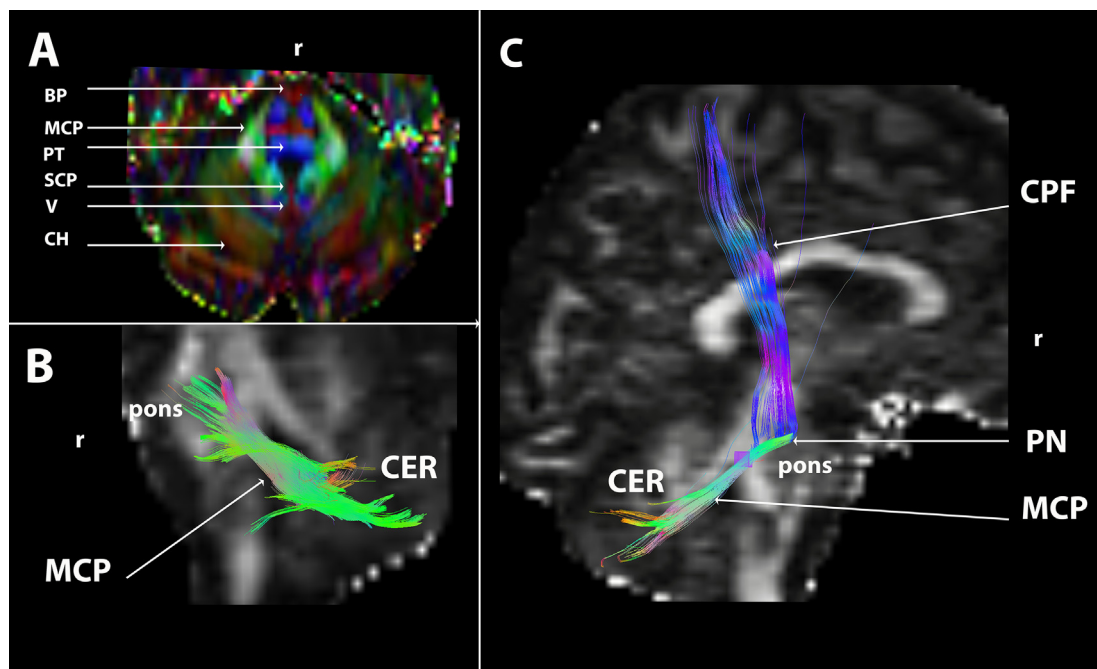


Fig. 3. A: axial fractional anisotropic color map passing through the pons and the cerebellum showing the basis pontis (BP) with transverse fibers originating in the pontine nuclei (in red) and vertical fascicles (in blue), the pontine tegmentum (PT), the middle cerebellar peduncle (MCP), the superior cerebellar peduncle (SCP) near the roof of the fourth ventricle, the vermis (V) and the cerebellar hemispheres (CH). B: colored tractogram of the middle cerebellar peduncle overlaid on a sagittal fractional anisotropic image running from the pons to the white matter of the cerebellum (CER). C: Tractogram of the corticopontine fibers (CPF) terminating in the pontine nuclei (PN) which project to the cerebellum through the MCP. R: rostral. All tractograms in the figures were computed with spherical deconvolution using diffusion-weighted images (256 non-linear gradients, and with a voxel size = 1 mm³). From: [Habas and Manto \(2018\)](#). With permission. (For interpretation of the references to color in this figure legend, the reader is referred to the web version of this article.)

cells in the cerebellar cortex. These zones inhibit clusters of neurons in cerebellar nuclei/vestibular nuclei, and these clusters project back to the inferior olive neurons via the inhibitory nucleo-olivary tract. In other words, it can be considered that a module corresponds to a triangulation inferior olive - Purkinje neurons - nuclei ([Ruigrok, 2011](#)). The neighbouring Purkinje neurons belonging to microzones within a given module are coherently active during a given task ([Broersen et al., 2016](#)). Microzones are composed of approximately 1000 Purkinje neurons showing the same somatotopic receptive field and arranged in a long narrow strip, with privileged cellular interactions as compared to remote Purkinje neurons.

Optogenetic studies have confirmed that the rate of simple spikes in the cerebellar cortex influences the rate of complex spikes ([Witter et al., 2013](#)). Indeed, when the rate of simple spikes decreases, the nucleo-olivary tract is disinhibited. This will decrease the rate of complex spikes within a module, as the nucleo-olivary tract regulates the degree of gap junction coupling between olivary neurons ([Marshall and Lang, 2009](#); [Broersen et al., 2016](#)). The projection is GABAergic and suppresses olivary firing rates.

Each cerebellar nucleus presents a somatotopic representation of the body ([Bastian and Thach, 2002](#)). In a rest condition, nuclear neurons show a permanent rate of discharges of about 40–50 Hz, which influences the target structures including (a) the nodes within the cerebellar modules, (b) brainstem nuclei, (c) thalamic nuclei, and (e) spinal cord. The somatotopic representation within nuclei has to be considered with the cerebellar homunculi at the level of the cerebellar cortex ([Colin et al., 2002](#)).

5. Cerebro-Cerebellar Connectivity: The multiple Cerebello-Cerebral loops

5.1. Anatomical cerebro-cerebellar loops

The cerebro-cerebellar connectivity is arranged into multiple parallel loops, as supported by tracing studies in animals and the tech-

nique of DTI identifying white matter tracts in vivo. Cerebral cortex projects to the contralateral cerebellum via a relay in the pontine nuclei (ponto-cerebellar tract; see [Fig. 3](#)). This is a feed-forward loop running through the middle cerebellar peduncle. In monkey, most of the cortico-pontine fibers have their origin in the motor system, whereas in human they originate from the prefrontal areas ([Ramnani et al., 2006](#); [Ramnani, 2012](#)). The loop is closed by a feedback projection to the cerebral cortex via the cerebello-thalamo-cortical pathway running through the superior cerebellar peduncle (see [Fig. 5](#)). There is a nuclear segregation in terms of projections: given territories of the dentate nuclei target given thalamic and cortical areas at the level of motor, premotor and associative cortices ([Strick et al., 2009](#)). In particular, the ventral portion of the dentate nucleus targets prefrontal and pre-supplementary motor cortices whereas the dorsal portion targets the motor cortex ([Middleton and Strick, 2001](#)). Lobules III–VI and VIII are connected to the motor cortex and Crus II is connected with area BA46 ([Kelly and Strick, 2003](#)). The following closed loops are running in parallel ([Habas, 2016](#)):

- dorsal dentate nucleus, caudal ventro-lateral thalamus, area BA4
- lateral dentate nucleus, X thalamus, area BA6
- caudal dentate nucleus, X thalamus, area BA8
- ventromedial dentate nucleus, caudal ventrolateral and mediodorsal thalamus, area BA9
- ventrolateral dentate nucleus, caudal ventrolateral and mediodorsal thalamus, dorsolateral prefrontal cortex (BA46)
- lateral dentate nucleus, caudal ventrolateral thalamus, BA7

Furthermore, disynaptic cerebello-striatal loops have been uncovered in the laboratory of Strick. The dentate nucleus projects to the pallidum via the thalamus and the subthalamic nucleus projects to the cerebellar cortex (crus II, lobule VIIb) via pontine nuclei ([Bostan et al., 2010](#)).

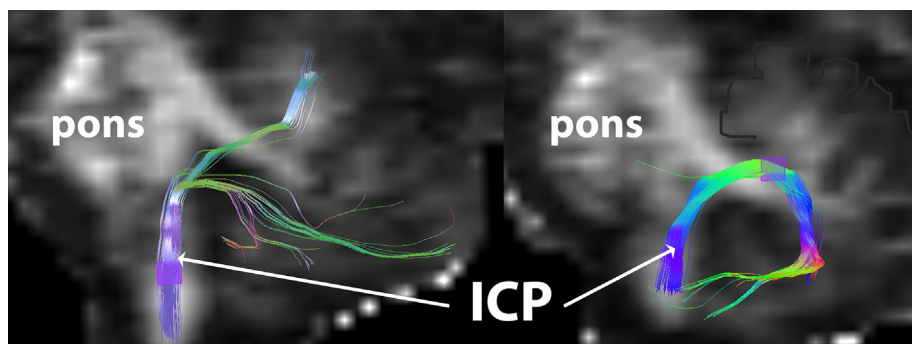


Fig. 4. Sagittal FA image passing through the brainstem and showing tractograms of the inferior cerebellar peduncles (ICP) entering the cerebellum through the restiform corpus before ending mainly in the cerebellar vermis (left side) and, more laterally, in the cerebellar hemispheres (right side). From: [Habas and Manto \(2018\)](#). With permission.

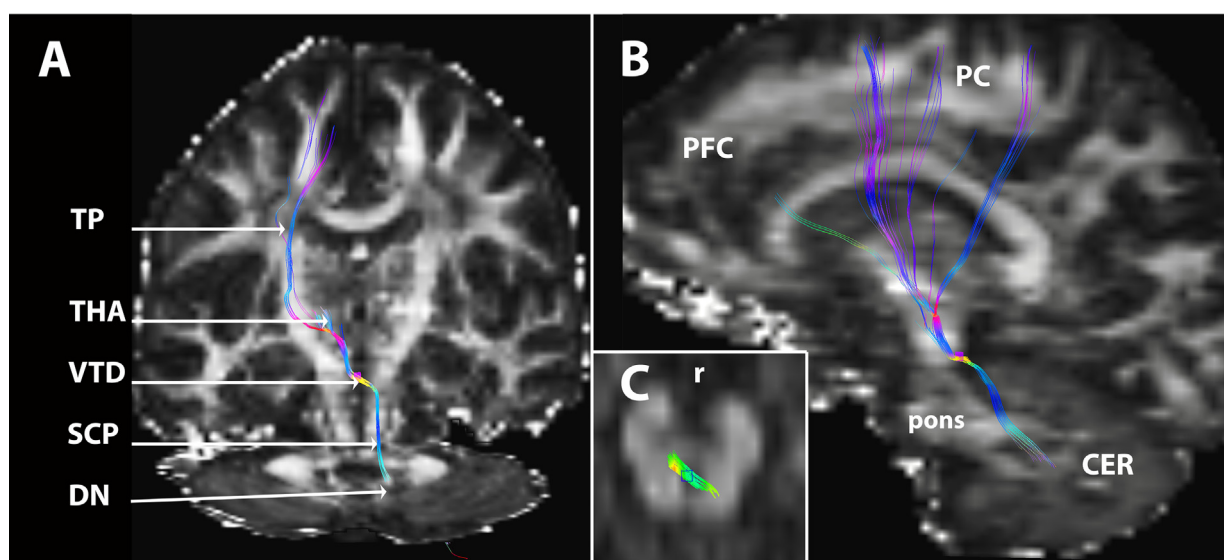


Fig. 5. Tractogram of the dentato-thalamo-cortical fibers (in color) rising from the dentate nucleus (DN) and running through the ipsilateral superior cerebellar peduncle (SCP) before crossing the midline at the level of the ventral tegmental decussation (VTD) and ending in the ventral thalamus (THA) which project to the cerebral cortex through the thalamic peduncles (TP). Tractogram overlaid on: A. a coronal FA map (with a corresponding axial image at the bottom), B. axial FA image passing through the mesencephalon and showing the VTD, and D. a sagittal FA image. R: rostral. From: [Habas and Manto \(2018\)](#). With permission.

Regarding the spinocerebellar projections, the information is conveyed through the inferior and superior cerebellar peduncles. Spinal tracts project (a) to lobules I–V, part of the lobule VI and lobule VIII ([Oscarsson, 1965](#)), and (b) to the inferior olive (spino-olivary tract). By contrast, the remainder of lobule VI and lobule VII (VIIa, Crus I, Crus II, VIIb) receive no direct spinal projection ([Brodal and Brodal, 1981](#)). These cerebellar areas are hugely implicated in cerebello-cerebral loops with prefrontal cortex, posterior parietal cortex, superior temporal cortex, cingulate gyrus and parahippocampus.

5.2. Functional organization

The studies of resting-state networks and the mapping of motor versus non motor tasks (“cognitive”) in the cerebellum have drastically modified our view of the roles of the cerebellum ([Buckner et al., 2011](#); [Guell et al., 2018a, 2018b](#); [Marek et al., 2018](#); [King et al., 2019](#); [Brissenden et al. 2016](#)). It is now established that cerebellum is involved in numerous functions and cannot be seen as a pure motor control engine. A meta-analysis of neuroimaging studies validates the neuroanatomical findings explained above ([Stoodley and Schmahmann, 2009](#)). The concept of task-

dependent engagement of specific cerebellar subregions is now widely recognized.

The independent component analysis (ICA)-based functional connectivity has identified 4 main networks from resting-state fMRI data ([Habas, 2016](#)):

- the sensorimotor network involved in sensorimotor tasks: motor and premotor cortex, lobules V–VI and VIII. Simple movements or tactile tasks activate the sensorimotor homunculi ipsilaterally
- the right and left executive networks: dorsolateral prefrontal and parietal prefrontal cortices, Crus I/II
- the limbic “salience” network involved in interoception, emotional and autonomic regulation: frontal and insular cortices, lobules VI/VII
- the default-mode network involved in self-agency, memory, and mental imagery: dorsomedian prefrontal, posterior cingulate, retrosplenial and parahippocampal cortices, precuneus, lobules VII and IX.

Regarding language, clusters are mainly right-lateralized and involve lobules VI–VII. Verb generation typically activates right-lateralized lobules VI–VII ([Stoodley, 2012](#); [Ashida et al., 2019](#)).

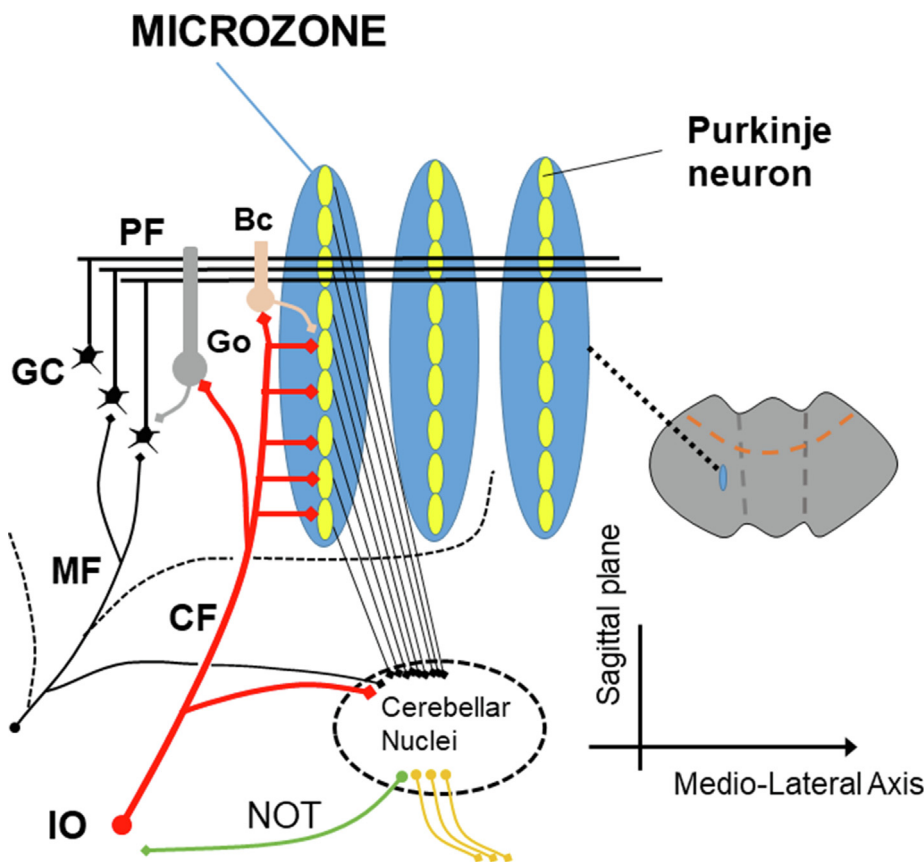


Fig. 6. A functional congruence between the 2 major input systems (mossy fibers, climbing fibers) is observed anatomically, with a contribution of mossy fibers into multizonal microcomplexes integrated in cerebellar modules subserving the operational aspects of the cerebellar machinery. The cerebellum takes advantage of the redundancy of the input informations. PF: parallel fiber, CF: climbing fiber, GC granule cell, Go: Golgi cells, Bc: basket cell, IO: inferior olive. From: [Mitoma et al. \(2021\)](#). With permission.

It is likely that 3 main networks drive cerebellar activity ([Guell et al., 2018b](#)):

- motor network: Activation during movements
- attentional/executive network: stimulus-driven attention (ventral attention network, salience network), goal-oriented attention (dorsal attention network) and related executive functions (frontoparietal network)
- default-mode network: Mind wandering, and deactivation during attention-demanding processes.

Guell and Schmahmann have proposed that cerebellar functional anatomy is based on these 3 poles. There are 2 representations of motor processing in the cerebellar cortex: lobule I–VI and lobule VIII. For the attentional/executive network and the default-mode network, there are 3 representations: lobules VI–Crus I, Crus II–lobule VIIIB, lobules IX–X. Crus I–Crus II are at the intersection of a first and a second default-mode representation. It is conceivable that the progression at a macroscale functional organization evolves from (a) motor to (b) attentional/executive and to (c) default-mode processing.

Our appraisal of emotion processing (engagement of cerebellar vermis), vestibular functions (engagement of cerebellar vermis and lobules IX–X), language processing (lateralization on the right side) and social cognition (engagement of the default-mode network) is being investigated. The social mentalizing (see also [Section 7](#)) activates CrusI/II ([Van Overwalle et al., 2020](#)).

6. Neurophysiological aspects of cerebello-cerebral interactions and control of timing

Focal cerebellar lesions are characterized by a reduced excitability of the contralateral M1; this is interpreted as a reduction in the facilitating tonic drive exerted by cerebellar nuclei over contralateral thalamic nuclei ([Di Lazzaro et al., 1994a, 1994b, 1995](#); [Restuccia et al., 2007, 2001](#)). Experiments in rodents are in agreement with this interpretation and provide arguments for the concept of a remote modulation of the excitability of M1 by the contralateral cerebellar cortex ([Oulad Ben Taib et al., 2005](#)). Indeed, application of cerebellar epidural anodal tDCS decreases the excitability of the contralateral M1, reduces the spinal cord excitability as assessed by F-waves, induces a “smoothing effect” on corticomotor maps, and increases the afferent inhibition of conditioned motor evoked responses ([Oulad Ben Taib and Manto, 2013](#)).

Currently, there is a general agreement that the cerebellum plays a key role in predictions. The cerebellar circuitry would predict the incoming somatosensory stimuli and modulate the activity of the somatosensory cerebral cortex in a given sensorimotor context ([Tesche and Karhu, 2000](#); [Ivry, 2000](#)). The cerebellum sets remotely the activity of inhibitory mechanisms in the primary somatosensory cortex at a very early step of somatosensory input processing ([Restuccia et al., 2001](#)). Altogether, these findings support the notion that the cerebellum monitors remotely both the

excitability of the M1 via thalamic relays and the processing of somatosensory inputs in an anticipatory fashion.

In terms of timing of motor discharges, the cerebellum regulates the timing of activities of agonist/antagonist muscles, as well as sets of synergic muscles that are automatically activated during voluntary movements (Bastian and Thach, 2002). The permanent rate of discharges of cerebellar nuclei tunes the sensitivity of targets especially thalamic nuclei (projecting to the cerebral cortex), brainstem nuclei (including the reticular nuclei) and spinal cord. Cerebellar nuclear neurons show an increase in their firing rates before the movement onset and even before the discharges of the motor cortex, arguing for a key-role of the cerebellum in the initiation of movement, and again in line with the anticipatory functions of the circuitry (Thach, 1975).

It is currently assumed that the numerous tasks of daily life require an integration of the spatial and temporal information in the msec range (Broersen et al., 2016). The predictions are intimately linked to the timing of events. The brain takes into account spatio-temporal cues to perform appropriate anticipatory adjustments and perceptual judgments. The cerebellum contributes to these computations as a node involved in multiple networks including cerebral cortex, basal ganglia, hippocampus, and spinal cord with the goal of updating motor commands (Broersen et al., 2016; Grimaldi and Manto, 2012). This is highly challenging when one considers that sensorimotor delays extend from 50 to 400 msec according to the modality and context (Grimaldi and Manto, 2012). Cerebellar patients show errors in timing both for explicit and implicit tasks (Bares et al., 2011). Given the microanatomy of the cerebellum with its regular cellular arrangement, it is conceivable that timing is an inherent property of the machine. For instance, the length of parallel fibers of several mm (the average length is just below 10 mm for the chicken, about 5 mm in the cat and about 6 mm in the monkey) could be compared to paths between successive train stations (Purkinje neurons): once the information has reached a first train station, it can be anticipated when it will reach the next one. Each cerebellar nucleus contains a body representation, with the myotomes running primarily in the coronal dimension, roughly in the direction of parallel fibers. In other words, a coronal beam of parallel fibers would regulate the nuclear cells controlling synergistic muscles in a myotome (Bastian and Thach, 2002). The microanatomy would drive the elemental function of timing as a result of the duration between action potentials and length of parallel fibers. On the one hand, it is thus presumed that the cerebellum acts as an error detector broadcasting an error signal to other brain areas, in particular via the cerebello-thalamo-cortical pathway, which then adapt subsequent movements. On the other hand, the cerebellum likely provides movement commands as implied by the findings of cerebellar activity prior to movement onset. The current knowledge does not exclude that these 2 aspects of motor control occur together. Another point which remains undetermined is whether the coronal beam of parallel fibers regulating the timing of nuclear cells implies changes in the anatomy of the parallel fibers to control synergistic muscles in a given myotome. Again, the contemporary knowledge does not provide a precise answer. It remains also undetermined whether the detected errors translate into changes in timing/magnitude of muscle discharges via the cerebellum alone, via the cortical motor areas alone or via both structures.

A major objective of the olivocerebellar system and the cerebellar microcomplexes is likely to provide temporal representations and generate complex temporal patterns including intervals between movements (Yarom and Cohen, 2002). These temporal patterns might be used as templates for the coordination of sets

of muscles in a given context. Learning might refine these templates for subsequent use.

7. Cerebellum as a tuner of motor and non motor tasks

Understanding how the cerebellum influences sensorimotor control, affect and emotion is of major importance to elucidate how the human brain operates daily. Given the homogeneous organization of the cerebellar cortex into microcomplexes, it is assumed that the cerebellum exerts a similar control over both motor and non-motor behavior. Schmahmann has suggested the principle of Universal Cerebellar Transform (UCT) which asserts that the main role of the cerebellum is to regulate homeostasis by smoothing performances with the goal of generating a harmonious motor/non motor behavior (Schmahmann, 2019). In other words, cerebellar circuitry would adjust in a similar manner the rate, force, and rhythm of motor activities and the correctness of cognitive/affective/emotional operations. The core symptom in cerebellar patients would be dysmetria. This means that the same basic errors would lead to motor dysmetria, dysmetria of thought, and emotional dysmetria. The cerebellum would perform unique computations in a topographically arranged fashion on the basis of the loops involved in a given task and in a given context. These computations would allow generation and function of internal models which permit predictive computations for motor, cognitive, and affective operations. Such predictions are mandatory due to the unavoidable noise and transmission delays within the peripheral or central nervous structures (Hardwick et al., 2013). In terms of motor control, response latencies are far below those that can be accomplished with a control relying on feedback mechanisms. There is convincing evidence from psychophysical studies, fMRI studies and TMS studies that the cerebellum contributes to motor and non motor predictions (Johansson and Cole, 1992; Ebner, 2013; Shadmehr and Mussa-Ivaldi, 1994; Lackner and Dizio, 1998; Manto et al., 1994). Internal models assign the capacity to the cerebellar circuitry to generate and adapt motor sequences. A mismatch between the predicted and the actual sensory outcomes would lead to motor dysmetria. The internal model theory suits very well with the sequencing hypothesis of Molinari (Leggio and Molinari, 2015) (Fig. 7). According to this model, cerebellar microcomplexes compare sequences of movements with stored sequences. If the sequence stored fits with the current motor plan, the cerebellum will anticipate a sequence of incoming elementary events. In case of mismatch, a signal error is created, and the prediction scheme is revised with a re-calibration. The cerebellum would thus re-adjust to the complex dynamics of multi-joint voluntary movements. This hypothesis may explain the findings of impaired muscle torques observed in fast reaching tasks (Fig. 8). Again, the length of several mm of parallel fibers might be an anatomical substratum to coordinate movements.

In humans, embodied representations might be strongly linked to sensorimotor control loops (Fig. 9). The process of anticipation is crucial not only to perform smooth movements of daily life, but also for smooth social interactions. As proposed in a Consensus paper: “we extensively use re-enactment processes and internal thought manipulations to perform complex forms of embodied problem solving, mostly unconsciously, but occasionally using conscious imagery as well. Although largely automatic, embodied problem solving is a controlled process, and requires the ability to (intentionally) steer internal simulations towards desired ends, to manipulate and reassemble tacit knowledge in open-ended ways” (Kozioł et al., 2014).

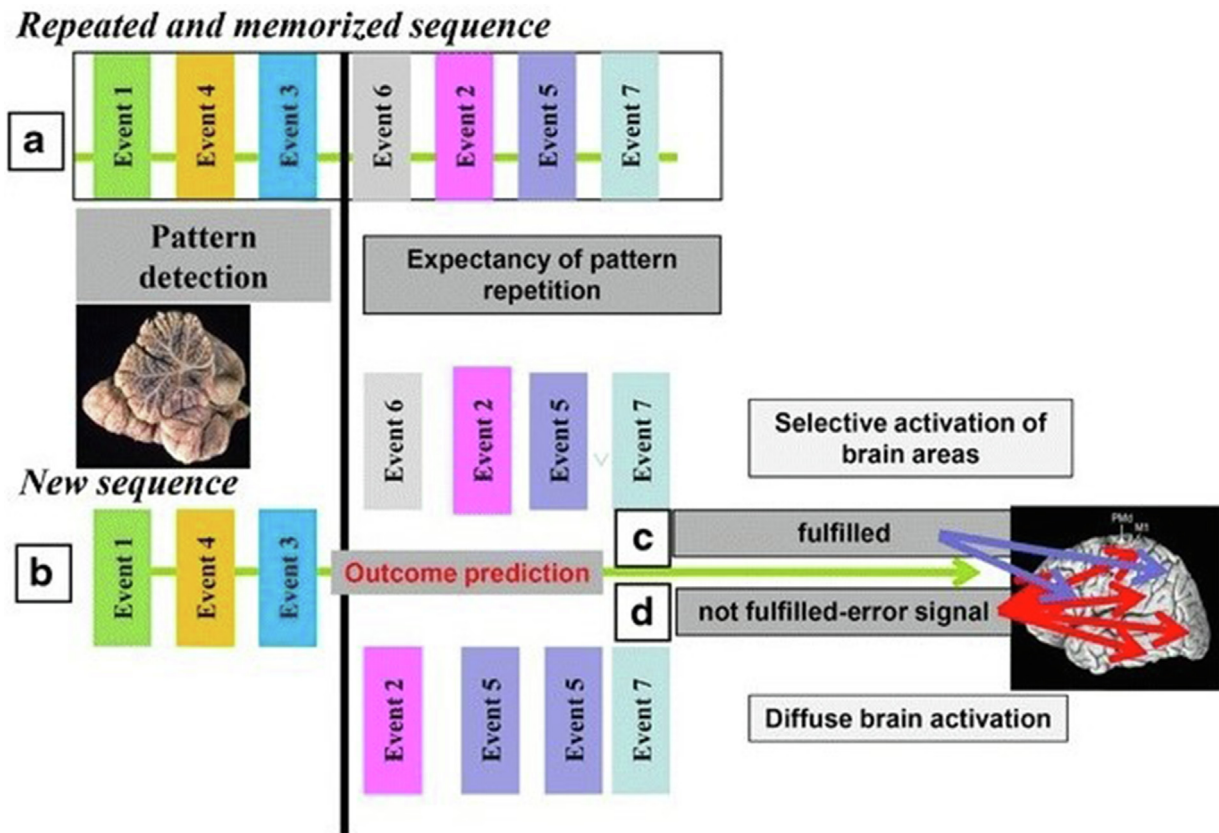


Fig. 7. Sequence detection model of prediction. If sensory events appear in a fixed sequence repeatedly in a short time, the sensory sequence is implicitly memorized which allows cerebellar circuits to compute a prediction for forthcoming perceptual events b. If the prediction holds c, a signal is sent to the cerebral cortex to alert selective brain areas, which become activated prior to the realized event and are thus better suited to process the incoming stimulus. If the prediction fails d, an alert signal is sent, and brain activation is more widespread, accelerating the processing of salient sensory information by the changing events and attuning the behavioral response to the new environment. From: [Baumann et al. \(2015\)](#). With permission.

8. The cerebellar reserve

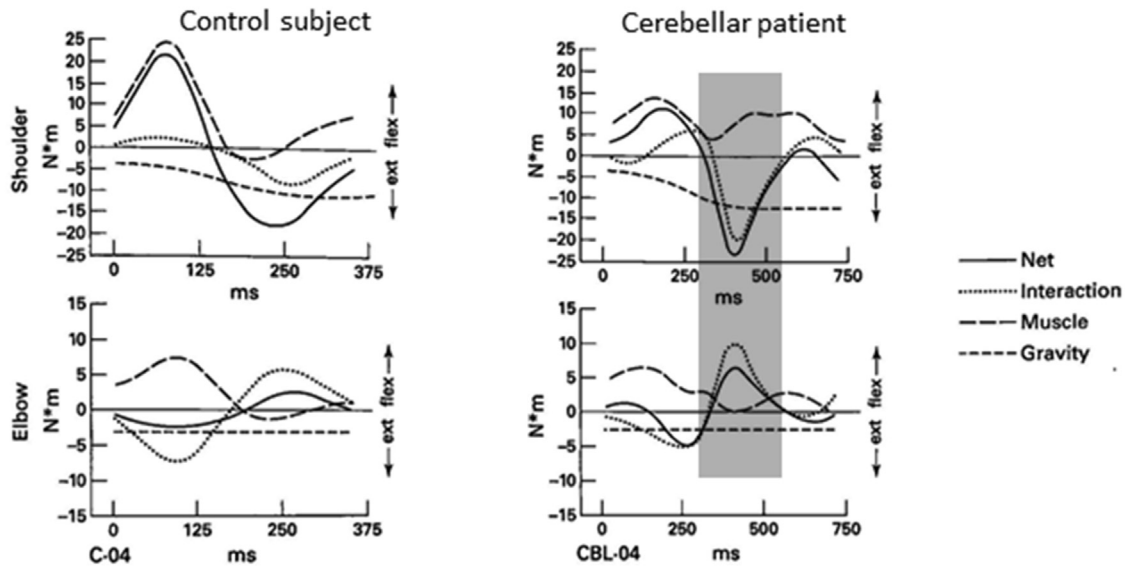
Self-repair is a major feature of cerebellar circuitry, allowing patients to recover clinically from a stroke or surgical ablation ([Luciani, 1891](#); [Manto et al. 2012](#)). Holmes reported the recovery process of motor incoordination in two patients: one had a lesion in the cerebellar hemisphere, and the other had a larger medial lesion ([Holmes, 1917](#)). Despite considerable damage, both patients walked with stability after 58 days and 71 days, respectively. A better understanding of this property of resilience of the cerebellar circuitry may open doors in the daily management of cerebellar disorders.

Cerebellar reserve designates the capacity of the cerebellar circuitry to compensate for tissue damage or loss of function ([Mitoma et al., 2020](#)). The reserve is both structural (compensation by another area of the cerebellum or extra-cerebellar structures, for instance following a stroke) and functional (the affected area itself contributes to compensation, for instance in degenerative or immune ataxias). The concept is applicable to the cerebellar motor syndrome (CMS), the vestibulocerebellar syndrome (VCS), and the cerebellar cognitive affective/Schmahmann's syndrome (CCAS/SS) (see next section). Plasticity mechanisms are particularly present in the cerebellum and cerebellar reserve is sensitive to environmental enrichment or training (see also [Section 10](#)). Reversibility of deficits may be enabled by the unique morphological and functional features of the cerebellum with its stereotyped and highly geometric, lattice-like architecture, and its enormous number of neurons (see [Section 1](#)) ([Mitoma et al., 2020](#)). In addition to changes occurring within the cerebellum itself, a reorganization

of extra-cerebellar structures contributes to the compensation following a cerebellar injury, in particular the sensorimotor cortex ([Mackel, 1987](#)). Compensation is not thus dependent on the sole cerebellar circuitry. Conversely, cerebellum is a key-actor for the recovery after cerebral hemispherectomy ([Mitoma et al., 2020](#)).

Although rats and humans may differ in terms of recovery following brain injuries (rats tend to recover from many lesions), some insights have been gained from experimental works in rodents. Studies in rats have established that both hemicerebellectomy and full cerebellectomy are followed by a recovery of deficits after a few weeks up to a few months. Limb hyperflexion, wide-based locomotion, and the tendency to side falls are observed after cerebellectomy, whereas tremor and body tilt develop after hemicerebellectomy ([Federico et al., 2006](#)). If hemicerebellectomy is performed during the neonatal period, homolateral aberrant cerebello-rubral projections develop ([Naus et al., 1987](#)). In other words, an aberrant mechanism may occur following an acute cerebellar lesion. This has been confirmed in human, both for acute injury and following a chronic progressive disorder ([Manto et al., 1998, 2002](#)). The aberrant recovery following a cerebellar stroke is characterized by 3 successive stages ([Manto et al., 1998](#)). At stage 1, hypermetric movements are associated with three EMG defects: a delayed onset latency of antagonist EMG activity, a reduction of intensity of the agonist EMG activity and a depression of intensity of antagonist EMG activity. At stage 2, movements show terminal oscillations around the target and the onset latency of the antagonist activity has returned to normal. At stage 3, movements become markedly hypometric, the intensity of the antagonist EMG activity has returned to normal, while the intensity of

A. Torques: fast-accurate condition



B. Kinematics

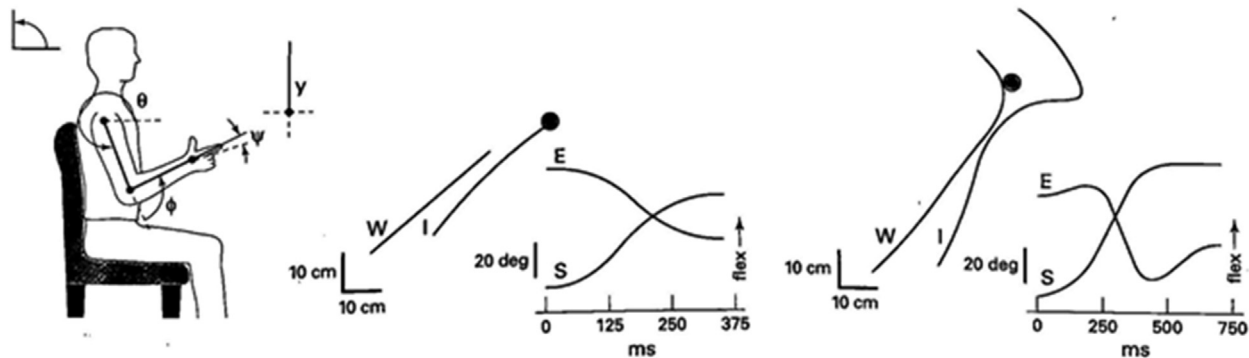


Fig. 8. A. Single trials of the torques produced by one control subject and one cerebellar patient making fast reaches to the target. At the elbow, the control subject produced a flexor muscle torque that was a mirror image of the extension interaction torque. The cerebellar patient produced a flexor muscle torque that did not mirror the extension interaction torque. The elbow extension was caused by an interaction torque inappropriately countered by a muscle torque. A similar pattern was found at the shoulder. B. Kinematics of the same reach. Note the abnormally curved wrist and index path in the cerebellar patient, with hypermetria. From: Bastian et al. (1996). With permission.

the agonist EMG activity is abnormally low. In case of multiple system atrophy (MSA), the initial marked cerebellar syndrome is associated with hypermetric movements. The distal hypermetria is associated with a delayed onset latency of the antagonist EMG activity and decreased intensities of both the agonist and the antagonist EMG activities. The proximal hypermetria is characterized by a defect in the phasic spatial tuning of the EMG activities. The progression to a Parkinsonian syndrome is characterized by a distal hypometria as a result of a decrease in the intensity of the agonist muscle. Proximal hypermetria turns into hypometria, as a result of the loss of directional preference of the EMG activities in proximal muscles. Still, the neurobiological mechanisms behind the aberrant recovery in human remain unknown. One possibility is an aberrant rewiring as mentioned above. In animal models, neonatal transection of cerebellar peduncles is rapidly followed by a reinnervation of the deprived cerebellar cortex by olivocerebellar projections with reformation of a sagittal striped pattern (Angaut et al., 1985). A specific reinnervation develops also in cerebellar nuclei, with the goal of reconstructing a correct map (Zagrebelsky et al., 1997). That means that both cerebellar cortex and cerebellar nuclei are sites of a remodeling of the circuit. Potentially, the abnormal rewiring could occur at both sites.

In terms of internal models, damage to the cerebellum implies a revision for the update, likely through the combination of synaptic plasticity mechanisms (Mitoma et al., 2020). Because a single mossy fiber (conveying information from the periphery or the cerebral cortex) distributes axon terminals in a medio-lateral direction and innervates multiple longitudinal microzones (see Fig. 6), it can be speculated that this redundancy will help the recovery process and that microzones around a lesion will likely change their discharge properties in order to recalibrate the model.

The cerebellum is deeply integrated into major reciprocal loops with the cerebral cortex, brainstem, and spinal cord. Overall, the process of coordination likely derives from the precise regulation of timing/gain in the cerebellar modules of the circuitry (D'Angelo, 2018). Signals conveyed by the mossy fibers are processed in the granular layer and transmitted to Purkinje cells, with a collateral pathway activating the deep cerebellar nuclei. Purkinje cells in turn inhibit the nuclei, so that it can be considered that the cerebellar cortex operates as a side loop controlling hierarchically the nuclei (D'Angelo, 2018). Learning is the result of synaptic plasticity at multiple synapses in the granular layer, molecular layer, and nuclei, together with the dynamic changes of the olivocerebellar pathway.



Fig. 9. An example of embodied problem solving. During climbing competitions, before climbing an unknown route, athletes can pre-view it for some minutes; they typically mimic, imagine, and plan their future climbing movements (in the picture, they do this overtly, but this is not always the case). This is a complex problem solving, as (route settlers ensure that) the sequence of movements to reach the top of the wall is novel and far from trivial. It depends on goal state (the climbing hold to reach) and previous movements. Furthermore, it incorporates the athlete's embodied knowledge, as length of limbs, strength of fingers, affordances offered by the various kinds of climbing holds, possible or impossible kinematics, all constraint the problem solving process. Part of the athletes' skill is in the ability to anticipate relevant information (proprioceptive, body posture at critical points, how much force to use, etc.) prior to climbing, to form motor plans, and to maintain and refine them in memory before climbing. From: [Kozioł et al., 2014](#). With permission.

9. Cerebellar syndrome at the 21th century

Cerebellar deficits are currently divided into 3 cerebellar syndromes ([Cabaraux et al., 2021](#)):

- the CMS: patients show various combinations of ataxic dysarthria (voice is scanning, explosive, with a nasal character), mutism (most commonly observed in children after resection of a large cerebellar midline tumor), ataxia of limbs with lack of coordination (dysmetria, dysdiadochokinesia, tremor, isometraxia (cerebellar patients are unable to maintain constant forces during skilled tasks requiring hand or finger use), hypotonia, cerebellar fits, impaired check and rebound), irregular handwriting (megalographia: writing is abnormally large in some patients), staggering gait and balance, impaired learning of complex motor skills (especially in children). Lesions occur at the level of lobules I-V, VI and VIII.
- the CVS: the syndrome is characterized by various combinations of dysmetria of saccades, saccadic pursuit, nystagmus, impaired vestibulo-ocular responses (VOR) and skew deviation. Vestibular nuclei are connected with lobules IX-X and the dorsal oculomotor vermis corresponding to lobules V to VII. Lesions affect these structures.
- the CCAS/SS: patients exhibit various combinations of dysexecutive deficits, visuospatial deficits, linguistic deficits and affective dysregulation. Lesions occur at the level of lobules VI-IX.

CMS is governed by 5 principles ([Manto, 2002](#)):

1. focal lesions cause homolateral signs, although expanding lesions may produce a false localization
2. motor deficits tend to be symmetrical in so-called degenerative ataxias
3. facing a non-progressive disorder, the symptoms tend to attenuate or even disappear with time (compensation)
4. lesions affecting the afferent or efferent cerebellar tracts mimic a cerebellar lesion
5. symptoms are more affected by location and rate of progression than by the pathological features.

Lesions may affect acutely/subacutely/chronically the cerebellar cortex, cerebellar nuclei ([Table 1](#) summarizes the motor functions of cerebellar nuclei), a mixture of cortical/nuclear areas and/or the afferent/efferent tracts. This contributes to the important clinical heterogeneity of cerebellar disorders in daily practice.

9.1. Control of speech

Anatomically, hemispheric lobule VI is critical for speech because it includes the lip/tongue area of the superior homunculus ([Ziegler, 2016](#)). Furthermore, lobule VIII contains also a tongue representation. Lobule VI is targeted by somatosensory afferent information from oral/facial muscles via the inferior cerebellar

Table 1
Motor functions of cerebellar nuclei.

Fastigius nucleus	Interpositus nucleus	Dentate nucleus
Eye movements	Control of antagonist muscles during mechanical perturbations (corrective movements)	Initiation of movement
Head orientation	Modulation of sensory feedback	Planning
Eye-Head gaze shifts	Modulation of the excitability of the gamma motor neurons	Increasingly active during multi-joint movements
Control of axial muscles during stance and gait		

From: Manto (2018). With permission.

peduncle, conveying information on the sensory state of speech organs. Crus I and Crus II are also involved in language functions (Stoodley and Schmahmann, 2009). In subjects with left cerebral dominance, cerebellar activation predominates on the right side due to a lateralized cerebellar language processing (Jansen et al., 2005). Cerebellar dysarthria is observed in lesions of both cerebellar hemispheres, with a predominance for lesions on the right side at the level of the paravermal parts of the anterior cerebellum (Urban, 2013; Ziegler, 2016). Ataxic dysarthria is explained by incoordination of speech, impaired motor timing and distorted sequencing (Ziegler, 2016). Cerebellar mutism can be part of the posterior fossa syndrome characterized by linguistic, cognitive, behavioral, and affective disturbances (Frank et al., 2007). Symptoms vary strongly between patients as a result of the various locations of lesions and redundancy of the cerebellar circuitry providing some protection. Several elemental mechanisms have been suggested for the triggering of mutism: brainstem compression, lesion of the dentato-thalamic projections, post-operative edema, impaired neurotransmission, axonal injury, vasospasm, and diaschisis (Manto, 2018).

9.2. Control of limb movements

The major features of motor dysmetria are the following: (1) dysmetria is speed-sensitive, (2) inertia increases dysmetria for fast speed movements, (3) there is an increased variability from trial to trial, (4) the movement shows an increased curvature, (5) the initiation of movement is impaired with a delay (Manto et al., 1994; Manto, 2018; Bodranghien et al., 2016; Diener and Dichgans, 1992). Dysmetria is observed for both proximal and distal movements (Hore et al., 1991). Both hypermetria and hypometria are often followed by corrective movements. Timing of agonist/antagonist EMG activities is typically impaired in cerebellar patients (Hallett et al., 1975). Experimentally, cerebellar cooling is associated with decreased phasic discharges in motoneuronal cortical discharges and reduced magnitudes of agonist discharges, in line with the hypothesis that cerebellum contributes to the genesis of agonist commands (Hore and Flament, 1988). Taken together with the results obtained from TMS studies, cerebellum appears as a masterpiece in the neuromodulation of the pyramidal system (Oulad Ben Taib and Manto, 2013).

Cerebellar patients exhibit a variety of tremors. Action tremor was initially reported in monkeys by Ferrier and Turner (Ferrier and Turner, 1893). Lesions of the nucleus interpositus are typically associated with a tremor (Bastian and Thach, 2002). The tremor induced by cooling the nucleus interpositus is more dependent on proprioceptive feedback than visual information (Flament et al., 1984). When the animal attempts to reach food, a 3 to 5 Hz action tremor is observed, suggesting that a key-function of

the interpositus muscle is to damp oscillations of the limb (Manto, 2018). Kinetic tremor is characterized by oscillations between 2 and 7 Hz. Unlike dysmetria, inertia reduces the oscillations near the target, both in humans and in monkeys in the model of nuclear cooling (Chase et al., 1965; Hewer et al., 1972; Hore and Flament, 1986). Not exceptionally, kinetic tremor is worsened a few days or weeks after an initial injury, likely by a mechanism of post-synaptic supersensitivity or due to a maladaptation mechanism (Manto, 2018). Cerebellar postural tremor shows a variable frequency between 2 and 12 Hz (Manto, 2018). The 3 Hz leg tremor with a spindle-like aspect (the oscillations of the lower limb show a waxing and waning amplitude) is observed during Mingazzini manoeuvre (patient is supine and flexes the hips at 90 degrees with the lower legs maintained horizontally) in chronic alcoholic degeneration or following drug intoxication (especially lithium salts) (Manto, 2002). Patients show atrophy of the anterior lobe. Palatal tremor (0.5 to 3 Hz) occurs in patients with a lesion of the dentato-rubro-olivary pathway (Guillain-Mollaret triangle). Tremor may extend to the eyes (oculopalatal tremor), the larynx or diaphragm. Orthostatic tremor is typically relieved when sitting or initiating gait and is either primary or secondary. The primary form shows a frequency of muscle discharges between 13 and 19 Hz. The secondary form (slower frequency) is mainly observed in patients showing lesions of the brainstem or the cerebellum, especially atrophy of the cerebellar cortex, and should be distinguished from orthostatic myoclonus.

9.3. Control of stance and gait

Regarding posture, eye closure typically worsens the ataxia of stance which is broad-based, although this aggravation is less as compared to vestibular ataxia or proprioceptive ataxia (Diener et al., 1984). Lateropulsion is usually observed in the direction of the site of the cerebellar lesion. The oscillations of the head/trunk/lower limbs observed in titubation are typically in the anterior-posterior plane. Facing an external force applied to the body, patients respond by an exaggerated muscle reaction (overshoot) which may lead to a fall in the opposite direction (Horak and Diener, 1994). It is presumed that this postural hypermetria contributes to postural instability in daily life.

Cerebellar gait is characterized by increased body sway, widened base of support, and increased step width (adaptive strategy; Serrao et al. 2012). Gait is irregular, with increased inter-steps variability and multiple corrections. Speed is irregular, the cerebellum regulating step/stride length and cadence (Manto, 2018). Tandem gait is particularly sensitive to detect ataxia (Stolze et al., 2001). Leg movements are dysmetric, with inappropriate timing of foot placements causing missteps (Stolze et al., 2001). Overall, the dynamic balance control is impaired. Impaired anticipatory corrections contribute to the erratic tandem gait. In children who have undergone a surgical transection of the posterior inferior vermis involving lobules VI to X, stance and regular gait are preserved whereas tandem gait is impaired (Bastian et al., 1996). The section of parallel fibers crossing the midline and connecting the Purkinje neurons over a distance of several mm would cause an inability to coordinate the lower limbs.

CVS is due to lesions at the level the dorsal vermis/fastigius nucleus, the flocculus/paraflocculus and/or the uvula/nodulus (Furman et al., 1990; Lewis and Zee, 1993). The dorsal vermis and fastigial nuclei are critical for the initiation, accuracy and dynamics of saccades, whereas the flocculus/paraflocculus play a major role to stabilize the visual image on retina (Fetter et al., 1994). Symptoms can be gathered in 6 categories: disorders of fixation (flutter, macrosaccadic oscillations, opsoclonus), disorders of pursuit (saccadic pursuit), disorders of saccades (dysmetria: hypermetria, hypometria, glissades), nystagmus (gaze-evoked, rebound,

downbeat, upbeat, bobbing, periodic alternating), skew deviation/ocular tilt reaction, impaired VOR/optokinetic responses (Cogan et al., 1982; Leigh and Zee, 1991; Manto, 2002; Selhorst et al., 1976; Shaikh, 2022). Vestibular nuclei contribute not only to oculomotor control via reciprocal loops with the cerebellum and cranial nerves III/IV/VI, but also to the regulation of posture and locomotion. Along with reticular nuclei and interneurons of Rexed's laminae VI-VIII (spinal cord), they are considered as key nodes for convergent input of multisensory feedback in conjunction with efferent copies of the motor command, in order to couple anticipatory or reactive postural adjustments with voluntary movements and render the movement efficient (MacKinnon, 2018). The vestibular nuclei are at a sensory-motor crossroad, since their discharges is modulated by visual signals, neck proprioceptive signals, cerebellum and cerebral cortex (Barmack, 2016).

10. Conclusion

Anatomically, the cerebellum participates in multiple segregated cerebello-cerebral loops and communicates directly with the basal ganglia; one major challenge being to identify the exact contributions of these nodes (Fig. 10). The cerebellum computes motor predictions related to body dynamics and to environmental changes. It is currently assumed that the predictions apply to both motor and non-motor tasks. The cerebellar cortex shapes cerebellar nuclei discharges by a mechanism of inhibition/disinhibition and interacts tightly with the inferior olive through multiple olivo-cortico-nuclear modules. The clinical deficits are currently interpreted in terms of impaired predictions leading to dysmetria, both in the motor and non-motor domain. The discovery that the basal ganglia and cerebellum interact extensively with reciprocal connections through a disynaptic pathway between (a) the dentate nucleus and the striatum as well as (b) between the subthalamic nucleus and the cerebellar cortex (Bostan et al., 2010; Bostan et al., 2013) open novel avenues for the understanding of cerebellar contribution to motor, cognitive, and affective control including in disorders which were historically attributed to basal ganglia impairments such as Parkinson's disease or dystonia. Therapies aiming to reinforce or restore internal models should be implemented, with an attempt to promote recovery when the cerebellar

reserve is still sufficient. Tailoring the therapies may require developing innovative tools to characterize and quantify the cerebellar reserve. For instance, tools estimating the predictive control might be useful for the quantification of the motor cerebellar reserve (Kakei et al., 2019). The assessment of sequences from previous experiences and generation of internal models predicting future events is currently a leading theory to explain both motor and non motor manifestations (Morgan et al., 2021; Kronemer et al., 2021).

Declaration of Competing Interest

The authors declare that they have no known competing financial interests or personal relationships that could have appeared to influence the work reported in this paper.

References

- Angaut, P., Alvarado-Mallart, R.M., Sotelo, C., 1985. Compensatory climbing fiber innervation after unilateral pedunculotomy in the newborn rat: origin and topographic organization. *J. Comp. Neurol.* 236, 161–178.
- Ashida, R., Cerminara, N.L., Brooks, J., Apps, R., 2018. Principles of organization of the human cerebellum: macro- and microanatomy. *Handb. Clin. Neurol.* 154, 45–58.
- Ashida, R., Cerminara, N.L., Edwards, R.J., Apps, R., Brooks, J.C.W., 2019. Sensorimotor, language, and working memory representation within the human cerebellum. *Hum. Brain Mapp.* 40, 4732–4747.
- Babinski, J., 1899. De l'asynergie cérébelleuse. *Rev. Neurol.* 7, 806–816.
- Bares, M., Lungu, O.V., Liu, T., Waechter, T., Gomez, C.M., Ashe, J., 2011. The neural substrate of predictive motor timing in spinocerebellar ataxia. *Cerebellum* 10 (2), 233–244.
- Barmack, N.H., 2016. Vestibular nuclei and their cerebellar connections. In: Gruol, D.L., Koibuchi, N., Manto, M., Molinari, M., Schmahmann, J.D., Shen, Y. (Eds.), *Essentials of Cerebellum and Cerebellar Disorders*. Springer, Switzerland, pp. 69–78.
- Barmack, N.H., Yakhnitsa, V., 2011. Topsy turvy: functions of climbing and mossy fibers in the vestibulo-cerebellum. *Neuroscientist* 17, 221–236.
- Bastian, A.J., Martin, T.A., Keating, J.G., Thach, W.T., 1996. Cerebellar ataxia: abnormal control of interaction torques across multiple joints. *J. Neurophysiol.* 76, 492–509.
- Bastian, A.J., Thach, W.T., 2002. Structure and function of the cerebellum. In: Manto, M., Pandolfo, M. (Eds.), *The Cerebellum and Its Disorders*. Cambridge University Press, Cambridge, UK, pp. 49–66.
- Baumann, O., Borra, R.J., Bower, J.M., Cullen, K.E., Habas, C., Ivry, R.B., et al., 2015. Consensus paper: the role of the cerebellum in perceptual processes. *Cerebellum* 14, 197–220.
- Bodranghien, F., Bastian, A., Casali, C., Hallett, M., Louis, E.D., Manto, M., et al., 2016. Consensus Paper: revisiting the symptoms and signs of cerebellar syndrome. *Cerebellum* 15, 369–391.
- Bostan, A.C., Dum, R.P., Strick, P.L., 2013. Cerebellar networks with the cerebral cortex and basal ganglia. *Trends Cogn. Sci.* 17, 241–254.
- Bostan, A.C., Dum, R.P., Strick, P.L., 2010. The basal ganglia communicate with the cerebellum. *Proc. Natl. Acad. Sci. USA* 107, 8452–8456.
- Brissenden, J.A., Levin, E.J., Osher, D.E., Halko, M.A., Somers, D.C., 2016. Functional Evidence for a Cerebellar Node of the Dorsal Attention Network. *J. Neurosci.* 36, 6083–6096.
- Brodal, P., Brodal, A., 1981. The olivocerebellar projection in the monkey. Experimental studies with the method of retrograde tracing of horseradish peroxidase. *J. Comp. Neurol.* 201, 375–393.
- Broersen, R., Winkelman, B.H.J., Ozyldirim, O., De Zeeuw, C.I., 2016. Physiology of olivo-cerebellar loops. In: Gruol, D.L., Koibuchi, N., Manto, M., Molinari, M., Schmahmann, J.D., Shen, Y. (Eds.), *Essentials of Cerebellum and Cerebellar Disorders*. Springer, Switzerland, pp. 323–327.
- Buckner, R.L., Krienen, F.M., Castellanos, A., Diaz, J.C., Yeo, B.T.T., 2011. The organization of the human cerebellum estimated by intrinsic functional connectivity. *J. Neurophysiol.* 106, 2322–2345.
- Cabarau, P., Gandini, J., Manto, M., 2021. The three cornerstones of cerebellar ataxia: closing the loop of 200 years of cerebellar research. In: Mizusawa, H., Kakei, S. (Eds.), *Cerebellum as a CNS Hub*. Contemporary Clinical Neuroscience. Springer, Switzerland, pp. 459–478.
- Caligiore, D., Pezzulo, G., Baldassarre, G., Bostan, A.C., Strick, P.L., Doya, K., et al., 2017. Consensus paper: towards a systems-level view of cerebellar function: the interplay between cerebellum, basal ganglia, and cortex. *Cerebellum* 16, 203–229.
- Cantalupo, C., Hopkins, W., 2010. The cerebellum and its contribution to complex tasks in higher primates: a comparative perspective. *Cortex* 46, 821–830.
- Chase, R.A., Cullen, J.K., Sullivan, S.A., Ommaya, A.K., 1965. Modification of intention tremor in man. *Nature* 206, 485–487.
- Cogan, D.G., Chu, F.C., Reingold, D.B., 1982. Ocular signs of cerebellar disease. *Arch. Ophthalmol.* 100, 755–760.

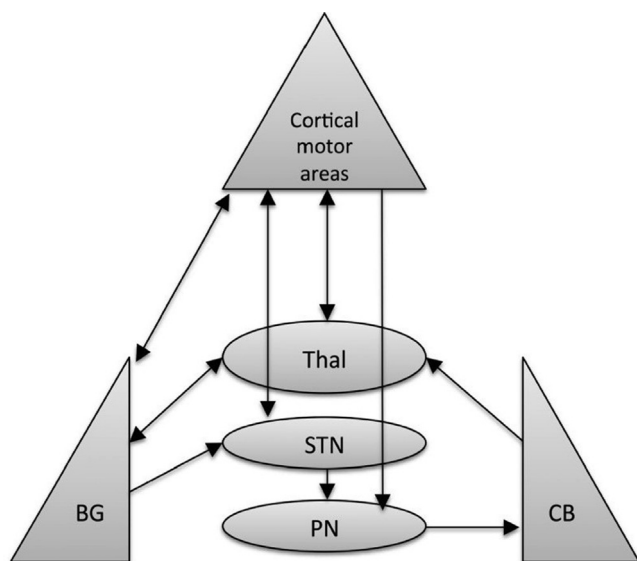


Fig. 10. Schematic representation of the known main communication pathways among the equally important three nodes of the motor control network. From: Caligiore et al. (2017). With permission.

- Colin, F., Ris, L., Godaux, E., 2002. Neuroanatomy of the cerebellum. In: Cerebellum, T., Disorders, I. (Eds.), Cambridge University Press. UK, Cambridge, pp. 6–29.
- D'Angelo, E., 2018. Physiology of the cerebellum. *Handb. Clin. Neurol.* 154, 85–108.
- Di Lazzaro, V., Molinari, M., Restuccia, D., Leggio, M.G., Nardone, R., Fogli, D., et al., 1994a. Cerebro-cerebellar interactions in man: neurophysiological studies in patients with focal cerebellar lesions. *Electroencephalogr. Clin. Neurophysiol.* 93, 27–34.
- Di Lazzaro, V., Restuccia, D., Molinari, M., Leggio, M.G., Nardone, R., Fogli, D., et al., 1994b. Excitability of the motor cortex to magnetic stimulation in patients with cerebellar lesions. *J. Neurol. Neurosurg. Psychiatry* 57, 108–110.
- Di Lazzaro, V., Restuccia, D., Nardone, R., Leggio, M.G., Oliviero, A., Profice, P., et al., 1995. Motor cortex changes in a patient with hemispherectomy. *Electroencephalogr. Clin. Neurophysiol.* 97, 259–263.
- Diener, H.C., Dichgans, J., 1992. Pathophysiology of cerebellar ataxia. *Mov. Disord.* 7, 95–109.
- Diener, H.C., Dichgans, J., Bacher, M., Gompf, B., 1984. Quantification of postural sway in normals and patients with cerebellar diseases. *Electroencephalogr. Clin. Neurophysiol.* 57, 134–142.
- Dykstra, S., Turner, R.W., 2016. Rebound depolarization and potentiation. In: Gruol, D.L., Koibuchi, N., Manto, M., Molinari, M., Schmähmann, J.D., Shen, Y. (Eds.), *Essentials of Cerebellum and Cerebellar Disorders*. Springer, Switzerland, pp. 305–309.
- Ebner, T.J., 2013. Cerebellum and internal models. In: Manto, M., Gruol, D.L., Schmähmann, J.D., Koibuchi, N., Rossi, F. (Eds.), *Handbook of the Cerebellum and Cerebellar Disorders*. Springer, Dordrecht, pp. 1281–1295.
- Federico, F., Leggio, M.G., Mandolesi, L., Petrosini, L., 2006. The NMDA receptor antagonist CGS 19755 disrupts recovery following cerebellar lesions. *Restor. Neurol. Neurosci.* 24, 1–7.
- Ferrier, D., Turner, W.A., 1893. A record of experiments illustrative of the symptomatology and degenerations following lesions of the cerebellum and its peduncles and related structures in monkeys. *Philos. Trans. R. Soc. B* 185, 719–778.
- Fetter, M., Klockgether, T., Schulz, J.B., Faiss, J., Koenig, E., Dichgans, J., 1994. Oculomotor abnormalities and MRI findings in idiopathic cerebellar ataxia. *J. Neurol.* 241, 234–241.
- Flament, D., Vilis, T., Hore, J., 1984. Dependence of cerebellar tremor on proprioceptive but not visual feedback. *Exp. Neurol.* 84, 314–325.
- Frank, B., Schoch, B., Richter, S., Frings, M., Karnath, H.O., Timmann, D., 2007. Cerebellar lesion studies of cognitive function in children and adolescents – limitations and negative findings. *Cerebellum* 6, 242–253.
- Furman, J.M., Wall 3rd, C., Pang, D.L., 1990. Vestibular function in periodic alternating nystagmus. *Brain* 113, 1425–1439.
- Grimaldi, G., Manto, M., 2012. Topography of cerebellar deficits in humans. *Cerebellum* 11, 336–351.
- Guell, X., Gabrieli, J.D.E., Schmähmann, J.D., 2018a. Triple representation of language, working memory, social and emotion processing in the cerebellum: convergent evidence from task and seed-based resting-state fMRI analyses in a single large cohort. *Neuroimage* 172, 437–449.
- Guell, X., Schmähmann, J., Gabrieli, J., Ghosh, S., 2018b. Functional gradients of the cerebellum. *Elife* 7, e36652.
- Habas, C., 2016. Cerebellar closed loops. In: Gruol, D.L., Koibuchi, N., Manto, M., Molinari, M., Schmähmann, J.D., Shen, Y. (Eds.), *Essentials of Cerebellum and Cerebellar Disorders*. Springer, Switzerland, pp. 343–347.
- Habas, C., Manto, M., 2018. Probing the neuroanatomy of the cerebellum using tractography. *Handb. Clin. Neurol.* 154, 235–249.
- Hallett, M., Shahani, B.T., Young, R.R., 1975. EMG analysis of patients with cerebellar deficits. *J. Neurol. Neurosurg. Psychiatry* 38 (12), 1163–1169.
- Hardwick, R.M., Dagioglou, M., Miall, R.C., 2013. State estimation and the cerebellum. In: Manto, M., Gruol, D.L., Schmähmann, J.D., Koibuchi, N., Rossi, F. (Eds.), *Handbook of the Cerebellum and Cerebellar Disorders*. Springer, Dordrecht, pp. 1297–1313.
- Häusser, M., Clark, B.A., 1997. Tonic synaptic inhibition modulates neuronal output pattern and spatiotemporal synaptic integration. *Neuron* 19, 665–678.
- Herculano-Houzel, S., 2010. Coordinated scaling of cortical and cerebellar numbers of neurons. *Front. Neuroanat.* 4, 12. <https://doi.org/10.3389/fnana.2010.00012>. eCollection 2010.
- Hewer, R.L., Cooper, R., Morgan, M.H., 1972. An investigation into the value of treating intention tremor by weighting the affected limb. *Brain* 95 (3), 579–590.
- Holmes, G., 1917. The symptoms of acute cerebellar injuries due to gunshot injuries. *Brain* 40, 461–535.
- Horak, F.B., Diener, H.C., 1994. Cerebellar control of postural scaling and central set in stance. *J. Neurophysiol.* 72, 479–493.
- Hore, J., Flament, D., 1986. Evidence that a disordered servo-like mechanism contributes to tremor in movements during cerebellar dysfunction. *J. Neurophysiol.* 56, 123–136.
- Hore, J., Flament, D., 1988. Changes in motor cortex neural discharge associated with the development of cerebellar limb ataxia. *J. Neurophysiol.* 60, 1285–1293.
- Hore, J., Wild, B., Diener, H.C., 1991. Cerebellar dysmetria at the elbow, wrist, and fingers. *J. Neurophysiol.* 65, 563–571.
- Huang, C., Riecke, R.E., 2013. Cerebellum and human evolution: a comparative and information theory perspective. In: Manto, M., Gruol, D.L., Schmähmann, J.D., Koibuchi, N., Rossi, F. (Eds.), *Handbook of the Cerebellum and Cerebellar Disorders*. Springer, Dordrecht, pp. 1337–1357.
- Ito, M., Sakurai, M., Tongroach, P., 1982. Climbing fibre induced depression of both mossy fibre responsiveness and glutamate sensitivity of cerebellar Purkinje cells. *J. Physiol.* 324, 113–134.
- Ivry, R., 2000. Exploring the role of the cerebellum in sensory anticipation and timing: commentary on Tesche and Karhu. *Hum. Brain Mapp.* 9, 115–118.
- Jansen, A., Flöel, A., Van Randenborgh, J., Konrad, C., Rotte, M., Förster, A.F., et al., 2005. Crossed cerebro-cerebellar language dominance. *Hum. Brain Mapp.* 24 (3), 165–172.
- Johansson, R.S., Cole, K.J., 1992. Sensory-motor coordination during grasping and manipulative actions. *Curr. Opin. Neurobiol.* 2, 815–823.
- Kakei, S., Lee, J., Mitoma, H., Tanaka, H., Manto, M., Hampe, C.S., 2019. Contribution of the cerebellum to predictive motor control and its evaluation in ataxic patients. *Front. Hum. Neurosci.* 13, 216.
- Kelly, R.M., Strick, P.L., 2003. Cerebellar loops with motor cortex and prefrontal cortex of a nonhuman primate. *J. Neurosci.* 23, 8432–8444.
- King, M., Hernandez-Castillo, C.R., Poldrack, R.A., Ivry, R.B., Diedrichsen, J., 2019. Functional boundaries in the human cerebellum revealed by a multi-domain task battery. *Nat. Neurosci.* 22, 1371–1378.
- Koziol, L.F., Budding, D., Andreasen, N., D'Arrigo, S., Bulgheroni, S., Imamizu, H., et al., 2014. Consensus paper: the cerebellum's role in movement and cognition. *Cerebellum* 13, 151–177.
- Kronemer, S.I., Slapik, M.B., Pietrowski, J.R., Margron, M.J., Morgan, O.P., Bakker, C.C., et al., 2021. Neuropsychiatric symptoms as a reliable phenomenology of cerebellar ataxia. *Cerebellum* 20, 141–150.
- Lackner, J.R., Dizio, P., 1998. Gravitoinertial force background level affects adaptation to coriolis force perturbations of reaching movements. *J. Neurophysiol.* 80, 546–553.
- Leggio, M., Molinari, M., 2015. Cerebellar sequencing: a trick for predicting the future. *Cerebellum* 14, 35–38.
- Leigh, R.J., Zee, D.S., 1991. *The Neurology of Eye Movements*. Philadelphia, Davis.
- Lewis, R.F., Zee, D.S., 1993. Ocular motor disorders associated with cerebellar lesions: pathophysiology and topical localization. *Rev. Neurol. (Paris)* 149, 665–677.
- Luciani, L., 1891. *Il cervello. Le Monnier, Nuovi studi di fisiologia normale e patologica*. Firenze.
- Mackel, R., 1987. The role of the monkey sensory cortex in the recovery from cerebellar injury. *Exp. Brain Res.* 66 (3), 638–652.
- Mackinnon, C.D., 2018. Sensorimotor anatomy of gait, balance, and falls. *Handb. Clin. Neurol.* 159, 3–26.
- Manto, M., 2002. Clinical signs of cerebellar disorders. In: Cerebellum, T., Disorders, I. (Eds.), Cambridge University Press. UK, Cambridge, pp. 97–120.
- Manto, M., 2018. Cerebellar motor syndrome from children to the elderly. *Handb. Clin. Neurol.* 154, 151–166.
- Manto, M., Godaux, E., Jacquy, J., 1994. Cerebellar hypermetria is larger when the inertial load is artificially increased. *Ann. Neurol.* 35, 45–52.
- Manto, M., Bower, J.M., Conforto, A.B., Delgado-García, J.M., da Guarda, S.N., Gerwig, M., et al., 2012. Consensus paper: roles of the cerebellum in motor control—the diversity of ideas on cerebellar involvement in movement. *Cerebellum* 11, 457–487.
- Manto, M.U., Hildebrand, J., Jacquy, J., 1998. Shift from hypermetria to hypometria in an aberrant recovery following cerebellar infarction. *J. Neurol. Sci.* 157, 42–51.
- Manto, M.U., Jacquy, J., Legros, B., Bosse, P., 2002. Shift from hypermetria to hypometria in multiple system atrophy: analysis of distal and proximal movements. *Neurol. Res.* 24, 249–258.
- Manto, M., Mariën, P., 2015. Schmähmann's syndrome – identification of the third cornerstone of clinical ataxiology. *Cerebellum Ataxias* 2, 2.
- Marek, S., Siegel, J.S., Gordon, E.M., Raut, R.V., Gratton, C., Newbold, D.J., et al., 2018. Spatial and Temporal Organization of the Individual Cerebellum. *Neuron* 100, 977–993.
- Marshall, S.P., Lang, E.J., 2009. Local changes in the excitability of the cerebellar cortex produce spatially restricted changes in complex spike synchrony. *J. Neurosci.* 29, 14352–14362.
- Middleton, F.A., Strick, P.L., 2001. Cerebellar projections to the prefrontal cortex of the primate. *J. Neurosci.* 21, 700–712.
- Mitoma, H., Buffo, A., Gelfo, F., Guell, X., Fucà, E., Kakei, S., et al., 2020. Consensus Paper. Cerebellar reserve: from cerebellar physiology to cerebellar disorders. *Cerebellum* 19, 131–153.
- Mitoma, H., Kakei, S., Yamaguchi, K., Manto, M., 2021. Physiology of cerebellar reserve: redundancy and plasticity of a modular machine. *Int. J. Mol. Sci.* 22, 4777.
- Morgan, O.P., Slapik, M.B., Iannuzzelli, K.G., LaConte, S.M., Lisinski, J.M., Nopoulos, P. C., et al., 2021. The Cerebellum and implicit sequencing: evidence from cerebellar ataxia. *Cerebellum* 20, 222–245.
- Naus, C.G., Flumerfelt, B.A., Hryciyshyn, A.W., 1987. Ultrastructural study of remodeled rubral afferents following neonatal lesions in the rat. *J. Comp Neurol* 259, 131–139.
- Oscarsson, O., 1965. Functional organization of the spino- and cuneocerebellar tracts. *Physiol. Rev.* 45, 495–522.
- Otis, T.S., 2016. Simple spikes and complex spikes. In: Gruol, D.L., Koibuchi, N., Manto, M., Molinari, M., Schmähmann, J.D., Shen, Y. (Eds.), *Essentials of Cerebellum and Cerebellar Disorders*. Springer, Switzerland, pp. 299–303.
- Oulad Ben Taib, N., Manto, M., Pandolfo, M., Brotchi, J., 2005. Hemispherectomy blocks the enhancement of cortical motor output associated with repetitive somatosensory stimulation in the rat. *J. Physiol. (Lond.)* 567, 293–300.

- Oulad Ben Taib, N., Manto, M., 2013. Trains of epidural DC stimulation of the cerebellum tune corticomotor excitability. *Neural Plast.* 2013, **613197**.
- Ramnani, N., Behrens, T.E., Johansen-Berg, H., Richter, M.C., Pinski, M.A., Andersson, J.L., et al., 2006. The evolution of prefrontal inputs to the cortico-pontine system: diffusion imaging evidence from Macaque monkeys and humans. *Cereb. Cortex* 16, 811–818.
- Ramnani, N., 2012. Frontal lobe and posterior parietal contributions to the cortico-cerebellar system. *Cerebellum* 11, 366–383.
- Restuccia, D., Valeriani, M., Barba, C., Le Pera, D., Capecchi, M., Filippini, V., et al., 2001. Functional changes of the primary somatosensory cortex in patients with unilateral cerebellar lesions. *Brain* 124, 757–768.
- Restuccia, D., Della, M.G., Valeriani, M., Leggio, M.G., Molinari, M., 2007. Cerebellar damage impairs detection of somatosensory input changes. A somatosensory mismatch-negativity study. *Brain* 130, 276–287.
- Ruigrok, T.J., 2011. Ins and outs of cerebellar modules. *Cerebellum* 10 (3), 464–474.
- Schmahmann, J.D., 2016. A brief history of the cerebellum. In: Gruol, D.L., Koibuchi, N., Manto, M., Molinari, M., Schmahmann, J.D., Shen, Y. (Eds.), *Essentials of Cerebellum and Cerebellar Disorders*. Springer, Switzerland, pp. 5–20.
- Schmahmann, J.D., 2019. The cerebellum and cognition. *Neurosci. Lett.* 688, 62–75.
- Selhorst, J.B., Stark, L., Ochs, A.L., Hoyt, W.F., 1976. Disorders in cerebellar ocular motor control. I. Saccadic overshoot dysmetria. An oculographic, control system and clinico-anatomical analysis. *Brain* 99, 497–508.
- Serrao, M., Pierelli, F., Ranavolo, A., Draicchio, F., Conte, C., Don, R., et al., 2012. Gait pattern in inherited cerebellar ataxias. *Cerebellum* 11, 194–211.
- Shadmehr, R., Mussa-Ivaldi, F.A., 1994. Adaptive representation of dynamics during learning of a motor task. *J. Neurosci.* 14, 3208–3224.
- Shaikh, A.G., 2022 Jul 26. Classics to contemporary of saccadic dysmetria and oscillations. *Cerebellum*. <https://doi.org/10.1007/s12311-022-01443>.
- Shen, Y., 2016. Plasticity of the cerebellum. In: Gruol, D.L., Koibuchi, N., Manto, M., Molinari, M., Schmahmann, J.D., Shen, Y. (Eds.), *Essentials of Cerebellum and Cerebellar Disorders*. Springer, Switzerland, pp. 305–30915.
- Stolze, H., Petersen, G., Raethjen, J., Wenzelburger, R., Deuschl, G., 2001. The gait disorder of advanced essential tremor. *Brain* 124, 2278–2286.
- Stoodley, C.J., Schmahmann, J.D., 2009. Functional topography in the human cerebellum: a meta-analysis of neuroimaging studies. *Neuroimage* 44, 489–501.
- Stoodley, C.J., 2012. The cerebellum and cognition: evidence from functional imaging studies. *Cerebellum* 11 (2), 352–365.
- Strick, P.L., Dum, R.P., Fiez, J.A., 2009. Cerebellum and nonmotor function. *Annu. Rev. Neurosci.* 32, 413–434.
- Tesche, C.D., Karhu, J.J., 2000. Anticipatory cerebellar responses during somatosensory omission in man. *Hum. Brain Mapp.* 9, 119–142.
- Thach, W.T., 1975. Timing of activity in cerebellar dentate nucleus and cerebral motor cortex during prompt volitional movement. *Brain Res.* 88, 233–241.
- Urban, P.P., 2013. Speech motor deficits in cerebellar infarctions. *Brain Lang.* 127, 323–326.
- Van Overwalle, F., Manto, M., Cattaneo, Z., Clausi, S., Ferrari, C., Gabrieli, J.D.E., et al., 2020. Consensus Paper: Cerebellum and Social Cognition. *Cerebellum* 19 (6), 833–868.
- Voogd, J., Glickstein, M., 1998. The anatomy of the cerebellum. *Trends Neurosci.* 21, 370–375.
- Witter, L., Canto, C.B., Hoogland, T.M., de Gruijil, J.R., De Zeeuw, C.I., 2013. Strength and timing of motor responses mediated by rebound firing in the cerebellar nuclei after Purkinje cell activation. *Front. Neural Circuits* 7, 133.
- Yarom, Y., Cohen, D., 2002. The olivocerebellar system as a generator of temporal patterns. *Ann. N. Y. Acad. Sci.* 978, 122–134.
- Zagrebelsky, M., Strata, P., Hawkes, R., Rossi, F., 1997. Reestablishment of the olivocerebellar projection map by compensatory transcommissural reinnervation following unilateral transection of the inferior cerebellar peduncle in the newborn rat. *J Comp Neurol* 379, 283–299.
- Zanatta, A., Cherici, C., Bargoni, A., Buzzi, S., Cani, V., Mazzarello, P., et al., 2018. Vincenzo Malacarne (1744–1816) and the first description of the human cerebellum. *Cerebellum* 17, 461–464.
- Ziegler, W., 2016. The phonetic cerebellum: cerebellar involvement in speech sound production. In: Marien, P., Manto, M. (Eds.), *The Linguistic Cerebellum*. Elsevier, London, pp. 1–32.