

Case report

# Myelodysplastic/myeloproliferative neoplasm with ring sideroblasts and thrombocytosis (MDS/MPN with RS-T) complicated by hyperleukocytosis and gene analysis in relation to leukocytosis

Yumi Aoyama,<sup>1)</sup> Kazuko Sakai,<sup>2)</sup> Taiichi Kodaka,<sup>1)</sup> Hiroko Tsunemine,<sup>1)</sup> Kazuto Nishio,<sup>2)</sup> Tomoo Itoh,<sup>3)</sup> Daichi Inoue,<sup>4)</sup> Takayuki Takahashi<sup>1)</sup>

Myelodysplastic/myeloproliferative neoplasm (MDS/MPN) with ring sideroblasts and thrombocytosis (MDS/MPN with RS-T), which exhibits both an increased number of marrow ring sideroblasts and thrombocytosis, is a rare disorder classified as one of the newly established forms of MDS/MPN in the WHO 2016 classification. A 77-year-old female with marked thrombocytosis of  $1,024 \times 10^9/L$  was tentatively diagnosed with essential thrombocythemia in 2011, and the thrombocytosis was controlled using hydroxycarbamide and low-dose busulfan. In 2016, the leukocyte count increased to a peak value of  $68.8 \times 10^9/L$  (86.6% mature neutrophils) during platelet-reduction therapy. Bone marrow aspirate exhibited hypercellularity with ring sideroblasts comprising 41.5% erythroblasts without excess myeloblasts. Cytogenetic examination demonstrated the *JAK2* V617F mutation and chromosomal abnormality of 46,XX,del(20)(q1?). Furthermore, dysplastic features of erythroid and granuloid precursors, as well as many large atypical megakaryocytes, were observed. Further genetic examinations revealed the *SF3B1* K700E mutation, but not amplification of the *JAK2* gene or pathogenic mutations in the 13 other genes examined. A diagnosis of MDS/MPN with RS-T was established and hyperleukocytosis was controlled using a higher dose of hydroxycarbamide. Although the patient maintained a stable disease state, she became RBC transfusion-dependent. Hyperleukocytosis, regardless of chemotherapy, is rare and may be novel in this disorder.

**Keywords:** MDS/MPN with RS-T, hyperleukocytosis, *SF3B1* mutation, *JAK2* mutation

## INTRODUCTION

Myelodysplastic/myeloproliferative neoplasm with ring sideroblasts and thrombocytosis (MDS/MPN with RS-T) is a rare subtype of MDS/MPN, which is characterized by thrombocytosis of greater than  $450 \times 10^9/L$ , ring sideroblasts with greater than 15% marrow erythroblasts, and dysplastic features of erythroid and granuloid precursors with less than 5% blasts.<sup>1</sup> In the WHO 2008 classification,<sup>2</sup> MDS/MPN with RS-T was provisionally registered as refractory anemia with ring sideroblasts associated with marked thrombocytosis (RARS-T), and in the WHO 2016 classification, this provisional entity was established as MDS/MPN with RS-T.


MDS/MPN with RS-T is negative for the *bcr-abl* chimera gene and has a characteristic genetic background in which 2 genes are often mutated; one mutation is *JAK2* V617F,<sup>3</sup> which promotes myeloid proliferation, and the other is *SF3B1* mutation,<sup>4</sup> which causes myelodysplasia with ring sideroblasts (MDS-RS). Therefore, MDS/MPN with RS-T exhibits clinical features of both MPN, especially essential thrombocythemia (ET), and MDS-RS.<sup>1</sup> Although anemia is often present in patients with MDS/MPN with RS-T, in the early stage of this disorder, hemoglobin levels and leukocyte and platelet counts are slightly higher than those in MDS-RS patients, whereas patients with MDS/MPN with RS-T often have lower hemoglobin levels and leukocyte and platelet

Received: October 31, 2018. Revised: November 27, 2018. Accepted: December 12, 2018. J-STAGE Advance Published: February 7, 2019  
DOI:10.3960/jslrt.18037

<sup>1)</sup>Department of Hematology, Shinko Hospital, Kobe, Japan, <sup>2)</sup>Department of Genome Biology, Kindai University Faculty of Medicine, Osaka, Japan, <sup>3)</sup>Department of Diagnostic Pathology, Kobe University Graduate School of Medicine, Kobe, Japan, and <sup>4)</sup>Human Oncology and Pathogenesis Program, Department of Medicine, Memorial Sloan Kettering Cancer, New York, NY, USA.

**Corresponding author:** Takayuki Takahashi, Department of Hematology, Shinko Hospital, 4-47, Wakihama-cho, 1-chome, Chuo-ku, Kobe 651-0072, Japan. E-mail: takahashi.takayuki@shinkohp.or.jp

Copyright © 2018 The Japanese Society for Lymphoreticular Tissue Research

 This work is licensed under a Creative Commons Attribution-NonCommercial-ShareAlike 4.0 International License.

counts than patients with ET.<sup>5</sup> We report a patient with MDS/MPN with RS-T who developed marked leukocytosis of  $68.8 \times 10^9/L$  during platelet-reduction therapy. Such hyperleukocytosis may be rare and novel in this disorder.

**MATERIALS AND METHODS**

**Mutational analysis of the SF3B1 gene and 14 other genes**

Genomic DNA was extracted from whole blood of the present patient in August 2017 when the white blood cell (WBC) count was  $33.3 \times 10^9/L$ , with 84.3% neutrophils, 2.0% monocytes, 5.7% eosinophils, 0.7% basophils, and 7.3% lymphocytes. Mutation analyses using Cancer Hot Panel v2 (CHPv2) targeting 15 genes, including SF3B1 and JAK2, were performed by next-generation sequencing using the IonProton™ system (Torrent server ver. 5.2 and Variant caller ver. 5.2) (Thermo Fisher Scientific, K.K., Tokyo, Japan). Whole exon and target sequencing was performed for SF3B1 and the remaining genes, respectively. These gene analyses were performed at the Department of Genome Biology, Kindai University School of Medicine after obtaining written informed consent from the patient and the approval by the ethics committees of both Shinko Hospital and Kindai University School of Medicine.

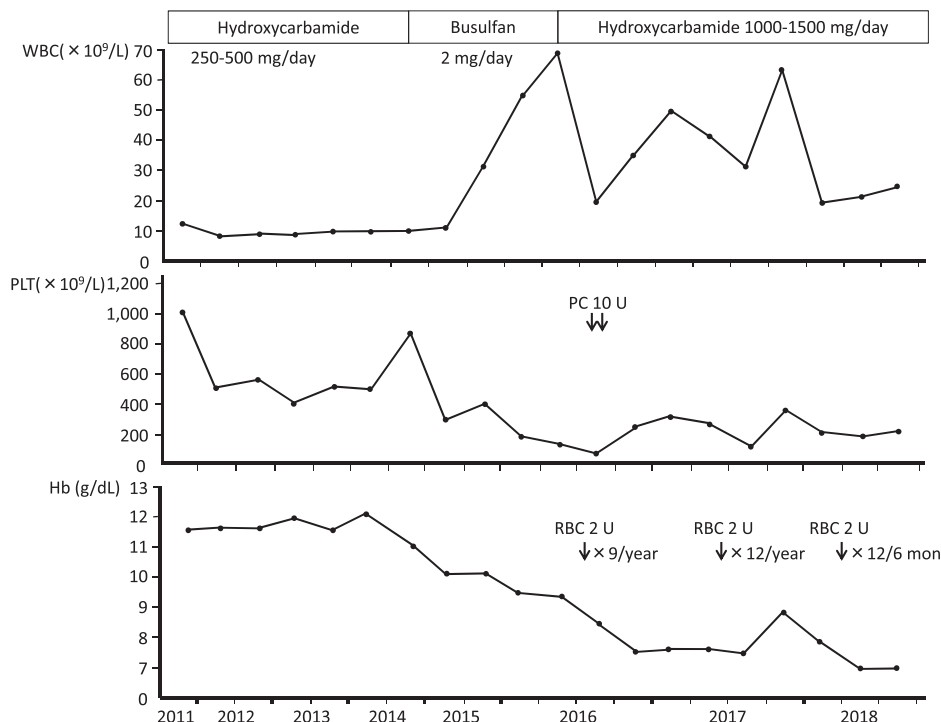
**CASE REPORT**

A 77-year-old female was referred to our hospital because of thrombocytosis of  $1,150 \times 10^9/L$  in 2011. Mild thrombocytosis had been observed from 2004 and it gradually progressed. Mild leukocytosis was also observed from 2007,

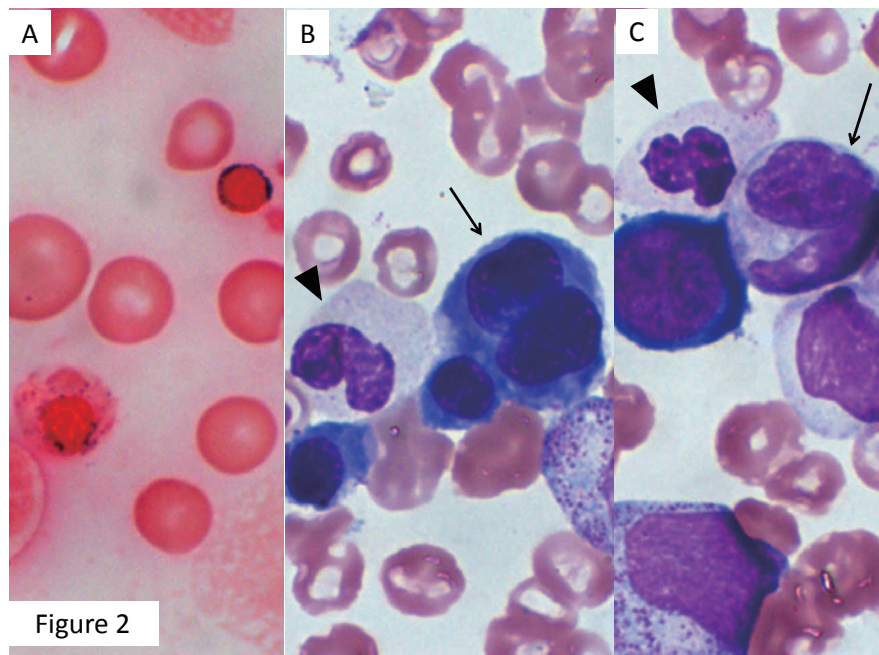
and periodic checkups had been performed regarding these increased blood cell counts at a clinic. Regarding her past medical history, she had pulmonary tuberculosis, sick sinus syndrome, and cerebral lacunar infarction in 1996, 2005, and 2010, respectively. She did not have specific family or life history.

At presentation at our hospital in 2011, she was physically normal, with no hepatosplenomegaly or superficial lymphadenopathy. Laboratory examination revealed a WBC count of  $12.7 \times 10^9/L$ , with 56.8% neutrophils, 8.8% eosinophils, 2.0% basophils, 5.3% monocytes, and 25.6% lymphocytes, a hemoglobin concentration of 11.6 g/dL, and a platelet count of  $1,024 \times 10^9/L$ . Fluorescence *in situ* hybridization (FISH) for the *bcr-abl* chimera gene on circulating neutrophils was negative. The neutrophil alkaline phosphatase (NAP) score was 329, being within normal limits (normally 170 to 330). Serum concentrations of lactic dehydrogenase and vitamin 12 were elevated to 262 IU/L (normally 115 to 245 IU/L) and higher than 1,500 pg/mL (normally 180 to 914 pg/mL), respectively. Other blood chemical and serological tests were normal. Although bone marrow examination was not performed, a tentative diagnosis of ET was made based on these findings.

As she had a past history of cerebral lacunar infarction, the thrombocytosis was controlled using hydroxycarbamide (250-500 mg/day) with subsequent normal platelet counts until November 2014 when the platelet count was elevated to  $827 \times 10^9/mL$  (Figure 1). Then, hydroxycarbamide was switched to busulfan (2 mg/day) with a subsequent platelet count of less than  $300 \times 10^9/L$  until December 2015. In July 2015, the WBC count began to increase to a peak value of  $68.8 \times 10^9/L$  (86.6% mature neutrophils and 0% blasts)



**Fig 1.** Clinical course of the present patient. PC: platelet transfusion, RBC: red blood cell transfusion.

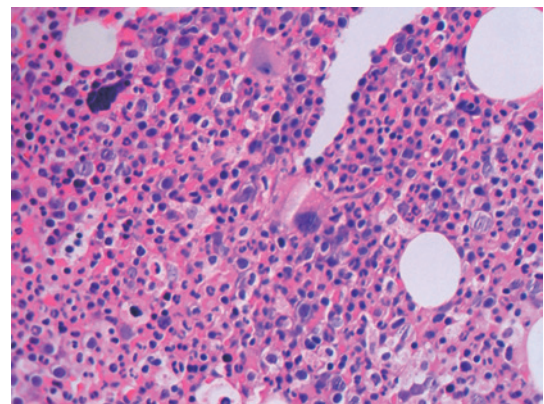


**Figure 2.** Bone marrow image in June 2016. **A:** Two ring sideroblasts were observed (arrows) (iron staining,  $\times 1,000$ ); **B:** A large polychromatophilic erythroblast with abnormal nuclear lobulation (arrow) and a neutrophil with a hypolobulated nucleus were observed (arrowhead) (Wright-Giemsa staining,  $\times 1,000$ ); **C:** A giant metamyelocyte (arrow) and a neutrophil with a hypolobulated nucleus (arrowhead) were observed (Wright-Giemsa staining,  $\times 1,000$ ).

regardless of platelet-reduction therapy with busulfan. Therefore, further examinations were performed in June 2016.

Bone marrow aspirate revealed slight hypercellularity with a nucleated cell count (Ncc) of  $123.2 \times 10^9/L$  and a megakaryocyte count of  $32/\mu L$ . Myeloblasts and ring sideroblasts (Figure 2A) comprised 0.3 and 41.5% of marrow nucleated cells and erythroblasts, respectively. The ratio of myeloid to erythroid cells was 4.1. Dysplastic features of marrow cells, such as erythroblasts with a megaloblastoid chromatin network, abnormal nuclear lobulation (Figure 2B), giant metamyelocytes (Figure 2C), and neutrophils with hypolobulated nuclei (Figure 2C), were observed. Chromosomal analysis of the marrow cells demonstrated an abnormal karyotype of  $46,XX,del(20)(q1?)$  in 20 of 20 dividing cells analyzed. PCR analyses revealed the *JAK2* V617F mutation but not calreticulin (*CALR*) type 1 or 2 mutation. Furthermore, bone marrow biopsy was performed in February 2017. As shown in Figure 3, the bone marrow was highly hyperplastic with many large atypical megakaryocytes. Many ring sideroblasts were histologically noted when stained with potassium ferrocyanide solution (data not shown). Bone marrow fibrosis was not observed. Based on these results, MDS/MPN with RS-T was strongly suspected, and the patient was treated for hyperleukocytosis using a higher dose of hydroxycarbamide (1,500 to 1,000 mg/day), which subsequently improved the WBC count; however, she became RBC transfusion-dependent (Figure 1).

As shown in Table 1, gene analyses using genomic DNA extracted from the whole blood in August 2017 revealed the



**Fig 3.** Histological image of the bone marrow in February 2017. The marrow was hypercellular with many large atypical megakaryocytes. Fibrosis was not noted.

*SF3B1* K700E mutation. The mutation was heterozygous and its frequency was 47.5% among the total DNA analyzed, indicating that almost all leukocytes at that time point had this mutation because the *SF3B1* K700E mutation inevitably occurs heterozygously.<sup>6</sup> The *JAK2* V617F mutation was also detected, being homozygous with a frequency of 94.5%. No amplification of the *JAK2* gene was observed. In the 13 other genes examined, neither a pathogenic single nucleotide variant (SNV) nor gene amplification was noted (Table 1).

Based on the *SF3B1* K700E mutation, marrow ring sideroblasts, dysplastic features of marrow hematopoietic cells, and the thrombocytosis, a diagnosis of MDS/MPN with RS-T was established. The treatment with hydroxycarbamide

**Table 1.** Gene mutation analysis including *SF3B1* and *JAK2* with Cancer Hot Panel v2

Gene	Type	Subsequent Mutation	Zygoty	Frequency	Significance	Amplification
<i>SF3B1</i>	SNV (T→C)	K700E	Heterozygous	47.5%	Likely Pathogenic	None
<i>JAK2</i>	SNV (G→T)	V617F	Homozygous	94.5%	Pathogenic	None
<i>ALK</i>						
<i>ERBB4</i>						
<i>KDR</i>						
<i>FGFR3</i>						
<i>FIP1L1</i>						
<i>PDGFRA</i>						
<i>APC</i>						
<i>CTC-554D6.1</i>						
<i>SMO</i>						
<i>RET</i>						
<i>FLT3</i>						
<i>TP53</i>						
<i>STK11</i>						
Only benign SNVs, insertions, or deletions						None

Analyses of *SF3B1* and *JAK2* genes were performed by next-generation sequencing using the IonProton™ system. Whole exon and target sequencing was performed for *SF3B1* and remaining genes, respectively. SNV: single nucleotide variant.

(1,000 to 1,500 mg/day) was continued with leukocytosis of  $16.3$  to  $27.3 \times 10^9/L$ , normal platelet counts, and anemia requiring RBC transfusion (Figure 1); however, the disease was stable without blasts in the peripheral blood as of October 2018.

## DISCUSSION

Regarding the diagnosis of the present patient, all diagnostic criteria,<sup>7</sup> such as greater than 15% sideroblasts in the marrow cells, less than 1 and 5% blasts in the peripheral blood and bone marrow, respectively, thrombocytosis of greater than  $450 \times 10^9/L$ , *SF3B1* gene mutation, and absence of the *bcr-abl* fusion gene, were fulfilled. The bone marrow examination was performed after platelet-reduction therapy, which had been continued for approximately 5 years; therefore, the ring sideroblasts in the present patient may have been a consequence of the hydroxycarbamide or busulfan treatment. However, there has been no report that these 2 cytotoxic agents induce ring sideroblasts. Furthermore, the presence of *SF3B1* mutation may rule out the secondary ring sideroblasts.

MDS/MPN with RS-T is a rare disorder, whereas ET is common and can be easily diagnosed based on thrombocytosis, *JAK2* or *CALR* mutation, and bone marrow examination. Although iron staining of the marrow preparation is required to differentiate MDS/MPN with RS-T, this staining is not always routinely performed during the diagnostic process for ET. The indicative factors for iron staining in a suspected ET case may include anemia and many dark blue granules in the cytoplasm of erythroblasts or erythrocytes, which can be observed by Wright-Giemsa staining.

Regarding leukocytosis in MDS/MPN with RS-T, Broseus *et al.* reported that the WBC count in MDS/MPN with RS-T is higher and lower than that in MDS-RS and ET, respectively.<sup>5</sup> The leukocytosis in ET is usually mild to moderate,<sup>8</sup> and to the best of our knowledge, marked

leukocytosis in MDS/MPN with RS-T has not been reported. Therefore, hyperleukocytosis of  $68 \times 10^9/L$ , which developed during platelet-reduction therapy, may be novel. The *JAK2* V617F mutation observed in the present patient was considered to play a role in the leukocytosis because it was homozygous, as observed in polycythemia vera,<sup>3,9</sup> in which moderate leukocytosis around  $30 \times 10^9/L$  is occasionally observed.<sup>10</sup> In addition, a homozygous state of *JAK2* V617F in ET is rare, comprising 2 to 4% of ET patients carrying this mutation.<sup>11</sup> This homozygosity may have occurred prior to the leukocytosis due to additional gene abnormalities, but not at the initial stage of the disease. Furthermore, a high allele frequency (94.5%) (Table 1) may also have led to the leukocytosis because a previous study demonstrated a significant but weak correlation between the *JAK2* V617F allele burden and leukocytosis in ET.<sup>12</sup> However, some additional factor may have been required to cause the marked leukocytosis in the present patient. We thus examined the amplified status of the *JAK2* gene, which was negative, and the 13 other genes examined also did not have pathogenic mutations that may cause leukocytosis (Table 1). The chromosomal abnormality of del(20q) noted in the present patient is observed in 5 to 8% of MDS patients. MDS with del(20q) is associated with thrombocytopenia, but not leukocytosis.<sup>13,14</sup> Moreover, the role of genes present in 20q in the pathogenesis of MDS remains unclear. Collectively, the mechanism of hyperleukocytosis in the present patient is not completely understood, and further investigation of other genes, such as *ASXL1*, *TET2*, *CBL*, *NRAS*, *SETBP1*, *BCOR*, *BRAF*, *KIT*, or *KRAS*,<sup>15</sup> is required. In addition, as leukocytosis may promote thrombosis in ET or PV,<sup>16</sup> we tried to reduce the hyperleukocytosis using a higher dose of hydroxycarbamide knowing that it would adversely affect erythropoiesis in the present patient.

The hematological results for the present patient at presentation in 2011 reflected ET, not MDS-RS, in terms of marked thrombocytosis, mild leukocytosis, and the absence of anemia. Cazzola *et al.* described a multistep molecular

pathogenesis of MDS/MPN with RS-T through the sequential acquisition of *SF3B1* and *JAK2* mutations.<sup>17</sup> In the present patient, however, the hematological evidence for ET lasted for at least 5 years from presentation; therefore, the acquisition of the *SF3B1* mutation may have been preceded by *JAK2* mutation. Cazzola *et al.* mentioned this possibility in a small proportion of patients with MDS/MPN with RS-T.<sup>17</sup> However, as bone marrow examination was not performed at presentation for the present patient, the precise pathogenesis remains unclear. Thus, molecular examinations at the early stage of this disorder may be highly important.

## ACKNOWLEDGMENTS

The authors thank Dr. Masafumi Ito of the Departments of Surgery and Pathology, Japanese Red Cross Nagoya First Hospital, Nagoya, Japan, for his precise review regarding the histopathology of the bone marrow biopsy.

## CONFLICT OF INTEREST

The authors declare no conflict of interest in this study.

## REFERENCES

- Orazi A, Hasserjian RP, Cazzola M, Thiele M, Malcovati L. Myelodysplastic/myeloproliferative neoplasm with ring sideroblasts and thrombocytosis. WHO Classification of Tumours of Haematopoietic and Lymphoid Tissues. Revised 4<sup>th</sup> ed, Lyon, International Agency for Research on Cancer. 2017; pp. 93-94.
- Vardiman JW, Bennett JM, Bain BJ, *et al.* Myelodysplastic/myeloproliferative neoplasm unclassifiable. WHO Classification of Tumours of Haematopoietic and Lymphoid Tissues. 4<sup>th</sup> ed, Lyon, International Agency for Research on Cancer. 2008; pp. 85-86.
- Kralovics R, Passamonti F, Buser AS, *et al.* A gain-of-function mutation of *JAK2* in myeloproliferative disorders. *N Engl J Med.* 2005; 352 : 1779-1790.
- Yoshida K, Sanada M, Shiraishi Y, *et al.* Frequent pathway mutations of splicing machinery in myelodysplasia. *Nature.* 2011; 478 : 64-69.
- Broseus J, Florensa L, Zipperer E, *et al.* Clinical features and course of refractory anemia with ring sideroblasts associated with marked thrombocytosis. *Haematologica.* 2012; 97 : 1036-1041.
- Inoue D, Abdel-Wahab O. Modeling *SF3B1* mutations in cancer: Advances, challenges, and opportunities. *Cancer Cell.* 2016; 30 : 371-373.
- Arber DA, Orazi A, Hasserjian R, *et al.* The 2016 revision to the World Health Organization classification of myeloid neoplasms and acute leukemia. *Blood.* 2016; 127 : 2391-2405.
- Thiele J, Kvasnicka HM, Orazi A, *et al.* Essential thrombocythemia. Revised 4<sup>th</sup> ed, Lyon, International Agency for Research on Cancer. 2017; pp. 50-53.
- Rumi E, Pietra D, Ferretti V, *et al.*; Associazione Italiana per la Ricerca sul Cancro Gruppo Italiano Malattie Mieloproliferative Investigators. *JAK2* or *CALR* mutation status defines subtypes of essential thrombocythemia with substantially different clinical course and outcomes. *Blood.* 2014; 123 : 1544-1551.
- Passamonti F. How I treat polycythemia vera. *Blood.* 2012; 120 : 275-284.
- Vannucchi AM, Antonioli E, Guglielmelli P, *et al.* Clinical profile of homozygous *JAK2 617V>F* mutation in patients with polycythemia vera or essential thrombocythemia. *Blood.* 2007; 110 : 840-846.
- Kittur J, Knudson RA, Lasho TL, *et al.* Clinical correlates of *JAK2V617F* allele burden in essential thrombocythemia. *Cancer.* 2007; 109 : 2279-2284.
- Kurtin PJ, Dewald GW, Shields DJ, Hanson CA. Hematologic disorders associated with deletions of chromosome 20q: a clinicopathologic study of 107 patients. *Am J Clin Pathol.* 1996; 106 : 680-688.
- Braun T, de Botton S, Taksin AL, *et al.* Characteristics and outcome of myelodysplastic syndromes (MDS) with isolated 20q deletion: A report on 62 cases. *Leuk Res.* 2011; 35 : 863-867.
- Delic S, Rose D, Kern W, *et al.* Application of an NGS-based 28-gene panel in myeloproliferative neoplasms reveals distinct mutation patterns in essential thrombocythaemia, primary myelofibrosis and polycythaemia vera. *Br J Haematol.* 2016; 175 : 419-426.
- Barbui T, Carobbio A, Rambaldi A, Finazzi G. Perspectives on thrombosis in essential thrombocythemia and polycythemia vera: is leukocytosis a causative factor? *Blood.* 2009; 114 : 759-763.
- Cazzola M, Rossi M, Malcovati L; Associazione Italiana per la Ricerca sul Cancro Gruppo Italiano Malattie Mieloproliferative. Biologic and clinical significance of somatic mutations of *SF3B1* in myeloid and lymphoid neoplasms. *Blood.* 2013; 121 : 260-269.