

Diaphragmatic Hernia Masquerading as Pleural Effusion

Z Nalladaru, A Wessels

Department of Cardiothoracic Surgery, The City Hospital, Dubai Health Care City, Dubai, United Arab Emirates

ABSTRACT

Rupture of the diaphragm is almost always due to major trauma. We present here an unusual and rare case of late presentation of diaphragmatic hernia after an innocuous injury. The patient was initially misdiagnosed as a left pleural effusion on the basis of chest X-ray and ultrasound findings. Finally, the diagnosis was confirmed on computerized scanning.

KEYWORDS: Pleural effusion, CT scan, diaphragmatic hernia

Address for correspondence:

Dr. Zubin Nalladaru,
Department of Cardiothoracic Surgery, The City Hospital,
Dubai Health Care City, PO Box 505004, Dubai, United Arab Emirates.
E-mail: zubin.nalladaru@thecityhospital.com

Access this article online

Quick Response Code:



Website: www.nigerianjsurg.com

DOI:
10.4103/1117-6806.103116

INTRODUCTION

Diaphragmatic injuries result from either blunt or penetrating trauma. They are usually associated with thoraco-abdominal trauma, but may rarely occur in isolation. Acute traumatic rupture of the diaphragm may go unnoticed and there may be a delay between the injury and diagnosis. As many as 30% of diaphragmatic hernias present late.^[1] We present an unusual case report of a late presentation of isolated diaphragmatic injury, after apparently minor blunt trauma, which was initially misdiagnosed as pleural effusion.

CASE REPORT

A 40-year-old man slipped and fell against the edge of his bath tub. He presented to a clinic where he was treated with analgesics and discharged after an apparently normal chest X-ray. After a year, he presented to the internal medicine department of another hospital with chest pain and shortness of breath. There was no history of cough or fever. On examination, he was afebrile with normal vital signs and oxygen saturation. Examination of the chest revealed dullness in the left infra-mammary and infra-scapular regions with markedly diminished breath sounds. X-ray chest was suggestive of left pleural effusion [Figure 1a]. Ultrasound of the chest was reported as thick effusion and marked for thoracocentesis.

A needle aspiration was attempted, but failed. Subsequently, a computerized tomography (CT) scan revealed a 2.5 cm defect in the anterior aspect of the left hemidiaphragm with herniation of omentum into the left chest

[Figure 1b]. The patient was then referred to our center for further management.

At thoracotomy, the omentum was found densely adherent to the diaphragm, left lung, pericardium, and chest wall [Figure 2a]. There was no herniation of stomach, colon, or spleen. The adhesions were carefully released. An omentectomy [Figure 2b, inset] was done as it was not possible to reduce the entire herniated omentum into the abdomen. The defect in the diaphragm [Figure 2b] was closed with

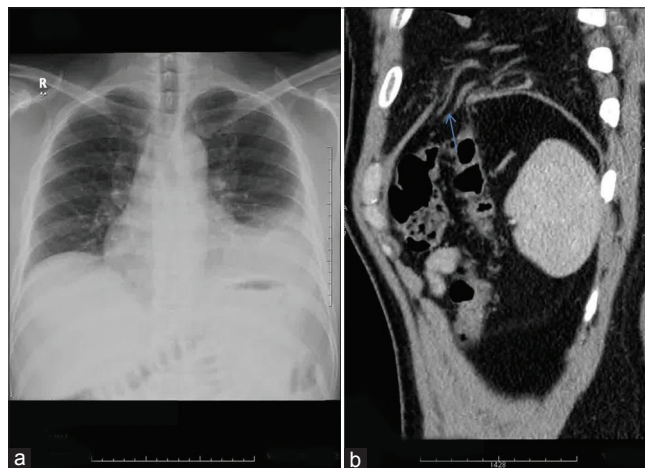


Figure 1: (a) Chest X-ray suggestive of left pleural effusion. CT scan (b) Defect in left hemidiaphragm (blue arrow) with herniation of omentum into the chest

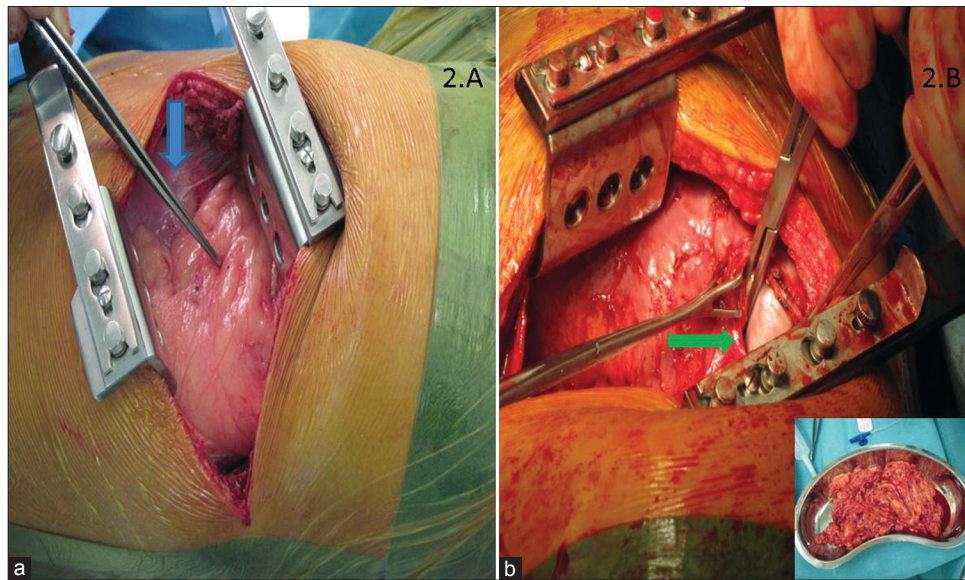


Figure 2: (a) Shows the omentum (forceps) herniating into the chest. Blue arrow points to the diaphragm; (b) Defect in the diaphragm (green arrow) is clearly defined. Partial omentectomy (see inset) was done

interrupted horizontal mattress sutures of 2-0 ethibond. Postoperative recovery was uneventful. He was asymptomatic at 1 year follow-up.

DISCUSSION

Rupture of the diaphragm after blunt trauma is relatively uncommon, occurring in approximately 0.8–1.6% of patients.^[2] It usually occurs in patients involved in major road traffic accidents and is associated with severe multi-system injuries because of the large force required to rupture the diaphragm.

On searching the literature, we found one other case of delayed diaphragmatic rupture after minor blunt trauma.^[3]

Delayed presentation of ruptured diaphragm can be explained by two hypotheses: Delayed rupture and delayed detection.^[4] Delayed rupture occurs when diaphragmatic muscle gets devitalized during the initial injury but remains a tenuous barrier until several days later when the inflammatory process weakens it. Delayed detection assumes that a diaphragmatic defect created at the time of injury becomes clinically evident only when herniation occurs.

Diagnosis of late presenting diaphragmatic hernia can be difficult to the inexperienced. Audible bowel sounds on auscultation of the chest suggest displaced bowel loops. A chest X-ray is the first line of investigation. CT has a sensitivity of 73% and specificity of 90%.^[5] Our patient was misdiagnosed initially as pleural effusion on the basis of chest X-ray. Even the ultrasound findings were misleading. Sonographically, a pleural effusion appears as an anechoic homogenous space between the parietal and visceral pleura. In our case, the herniated omentum was mistaken as pleural

fluid by the referring hospital. However, CT scan clinched the diagnosis as it demonstrated the presence of omentum in the left thorax as well as the diaphragmatic discontinuity.

Surgical repair for delayed presentation of diaphragmatic hernias is best dealt with the thoracic approach. This is because of the extensive adhesions that may form between the herniated organ and the chest as was evident in our case. In our case, only the omentum was found herniated into the chest. This could be explained by the fact that the ruptured area was small (2.5 cm) and allowed only the omentum to pass through. As the defect in the diaphragm was small, we repaired it with direct closure. Other techniques for closure of the defect include double-layered closure and use of a synthetic patch. Video-assisted thoracoscopic surgery (VATS) has also been reported for the delayed repair of post-traumatic diaphragmatic hernias.^[6]

CONCLUSION

In conclusion, rupture of the diaphragm may occur after seemingly minor injury. A high index of suspicion is required to diagnose this condition in patients who have a past history of blunt trauma to the chest or abdomen.

REFERENCES

1. Pappas-Gogos G, Karfis E, Kakadellis J, Tsimoyiannis EC. Intrathoracic cancer of the splenic flexure. *Hernia* 2007;11:257-9.
2. Shah R, Sabanathan S, Mearns AJ, Choudhary AK. Traumatic rupture of the diaphragm. *Ann Thorac Surg* 1995;60:1444-9.
3. Goh BK, Wong AS, Tay KH, Hoe MN. Delayed presentation of a patient with a ruptured diaphragm complicated by a gastric incarceration and perforation after apparently minor blunt trauma. *CJEM* 2004;6:277-80.

4. Johnson CD. Blunt injuries of the diaphragm. *Br J Surg* 1988;7:226-30.
5. Sirbu H, Busch T, Spillner J, Schachtrupp A, Autschbach R. Late bilateral diaphragmatic rupture: Challenging diagnostic and surgical repair. *Hernia* 2005;9:90-2.
6. Mizobuchi T, Iwai N, Kohno H, Okada N, Yoshioka T, Ebana H. Delayed diagnosis of traumatic diaphragmatic rupture. *Gen Thorac Cardiovasc Surg* 2009;57:430-2.

How to cite this article: Nalladaru Z, Wessels A. Diaphragmatic hernia masquerading as pleural effusion. *Niger J Surg* 2012;18:94-6.

Source of Support: Nil. **Conflict of Interest:** None declared.

Announcement

“QUICK RESPONSE CODE” LINK FOR FULL TEXT ARTICLES

The journal issue has a unique new feature for reaching to the journal’s website without typing a single letter. Each article on its first page has a “Quick Response Code”. Using any mobile or other hand-held device with camera and GPRS/other internet source, one can reach to the full text of that particular article on the journal’s website. Start a QR-code reading software (see list of free applications from <http://tinyurl.com/yzlh2tc>) and point the camera to the QR-code printed in the journal. It will automatically take you to the HTML full text of that article. One can also use a desktop or laptop with web camera for similar functionality. See <http://tinyurl.com/2bw7fn3> or <http://tinyurl.com/3ysr3me> for the free applications.