



Case report

Successful treatment of pulmonary injury after nitrogen oxide exposure with corticosteroid therapy: A case report and review of the literature



Yasutoshi Kido ^{a, b}, Akihisa Mitani ^{a, *}, Hideaki Isago ^a, Hideyuki Takeshima ^a,
Osamu Narumoto ^a, Goh Tanaka ^a, Yasuhiro Yamauchi ^a, Daiya Takai ^c, Nobuya Ohishi ^a,
Takahide Nagase ^a

^a Department of Respiratory Medicine, The University of Tokyo Hospital, Japan

^b Department of Biomedical Chemistry, Graduate School of Medicine, University of Tokyo, Japan

^c Department of Clinical Laboratory, The University of Tokyo Hospital, Hongo, Bunkyo-ku, Tokyo, Japan

ARTICLE INFO

Article history:

Received 9 October 2016

Received in revised form

12 January 2017

Accepted 13 January 2017

ABSTRACT

Nitrogen oxides are representative chemicals of occupational and environmental exposure, which can lead to fatal pulmonary injury. These oxides are also known to cause delayed occurrence of bronchiolitis obliterans (BO). Herein, we report a case of nitrogen oxide-induced lung injury. A 50-year-old man developed pulmonary edema after nitric acid exposure. Hypoxemia and respiratory failure were immediately improved after introduction of corticosteroid pulse therapy with supplemental oxygen. This was followed by administration of oral prednisolone, and delayed BO did not develop. This case supports the therapeutic efficacy of corticosteroids against pulmonary injury and late-onset BO after nitrogen oxide exposure.

Key clinical message: Prolonged oral prednisolone might be a potential therapy to prevent delayed onset of bronchiolitis obliterans after nitric acid exposure.

© 2017 The Authors. Published by Elsevier Ltd. This is an open access article under the CC BY-NC-ND license (<http://creativecommons.org/licenses/by-nc-nd/4.0/>).

1. Introduction

Nitrogen oxides, which are chemically converted from nitric acid, are occupational and environmental causes of toxic gas-related bronchiolar disorders [1]. Such disorders have been reported in industrial manufacturing, metal etching, and feed soils. The symptoms of these gas-related disorders are nonspecific and include exertional dyspnea and cough. Although the most frequently reported therapy is corticosteroid administration, dosing and duration of therapy are undetermined and dependent on a few case reports/series [2,3]. Herein, we report a case of nitrogen oxide-related pulmonary injury that was immediately resolved after corticosteroid pulse therapy and the successful prevention of delayed bronchiolitis obliterans (BO) by post-remission therapy with prednisolone.

2. Case

A 50-year-old man without any notable medical history presented to the emergency room of our hospital with a complaint of dyspnea. Approximately 18 h before arrival, he was performing electroless nickel plating using concentrated nitric acid without a protective mask even though he knew the ventilation system in the room was not operational. Immediately after he noticed irritant odors, which could be speculated as nitrogen oxide gas during the working process, he complained of cough and stopped working. After 30 min of rest, the cough and shortness of breath disappeared. However, 14 h after exposure, cough and shortness of breath recurred and gradually worsened.

Upon arrival to the emergency room, he had a productive cough and labored breathing at a rate of 26 breaths/min. Oxygen therapy was immediately administered, and his oxygen saturation on a non-rebreather mask with 6 L/min oxygen reached 96%. Body temperature was 36.8 °C; blood pressure was 148/93 mmHg; and heart rate was 86 beats/min. On physical examination, late inspiratory crackles were heard in both lung fields, while eye/nasal

* Corresponding author.

E-mail address: mitania-tky@umin.ac.jp (A. Mitani).

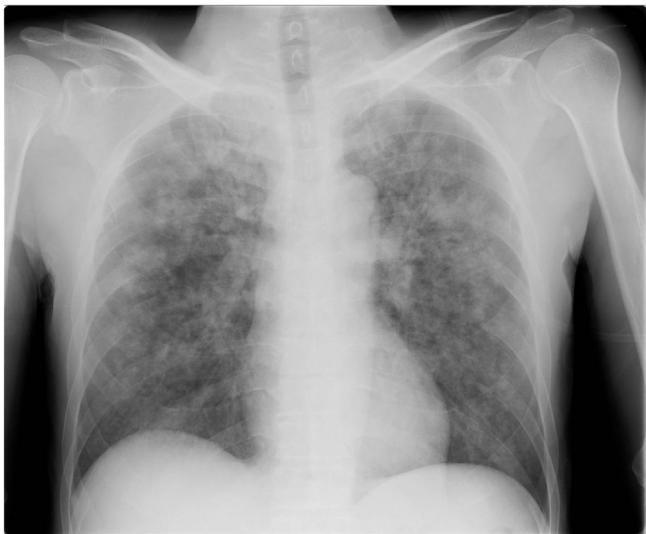

Fig. 1. A chest X-ray obtained on admission showed diffuse infiltration throughout all lung fields.

irritation and laryngeal edema were not observed. Serum laboratory tests showed that the white blood cell count was elevated to 17,600/ μ L (neutrophils: 91.4%, lymphocytes: 5.6%, eosinophils: 0.1%, and monocytes: 2.7%), and also showed the elevation of serum lactate dehydrogenase (LDH) (391 IU/L), total bilirubin (1.6 mg/dL), C-reactive protein (1.49 mg/dL), and surfactant protein D (150 ng/

mL). Serum β -D-glucan level (below detection limit), procalcitonin (0.15 ng/mL), and KL-6 (370 U/mL) were within normal limits.

An arterial blood gas was obtained on arrival, with the patient on a non-rebreather mask with 6 L/min of oxygen flow, and the results were pH 7.42, PCO_2 39 mmHg, PO_2 139 mmHg, and HCO_3^- 25.1 mmol/L, with a base excess of 0.8 mmol/L. Methemoglobin was 1.0%. A chest X-ray obtained on admission (Fig. 1) showed diffuse infiltration predominantly in the upper and middle regions of both lung fields, and thoracic computed tomography (CT) (Fig. 2) disclosed bilateral peribronchovascular ground glass opacities as well as centrilobular faint nodules. This case was categorized as acute lung injury (ALI) according to the AECC definition of 1994, although the criteria of ARDS by the Berlin definition of 2012 was not fulfilled [4].

These findings and his history of nitric oxide exposure were consistent with a diagnosis of pulmonary injury due to nitrogen oxide gas inhalation. The lesions were predominantly distributed in the distal airway, which explained the lower respiratory tract symptoms. The onset of the patient's symptoms was subacute, and rapid exacerbation was observed 14 h after exposure.

His clinical course is shown in Fig. 3. The patient was transferred to the intensive care unit, and his respiratory dysfunction was carefully monitored without intubation. Since his clinical course was indolent and the respiratory disorder did not resolve by supplemental oxygen, methylprednisolone pulse therapy (500 mg/day intravenously for 3 days) was initiated on day 2 of hospitalization, approximately 40 h after exposure. During the three days of pulse therapy, his dyspnea and chest X-ray findings dramatically improved, and oral prednisolone (30 mg per day) was initiated on day 5, which was then gradually reduced. No oxygen inhalation was

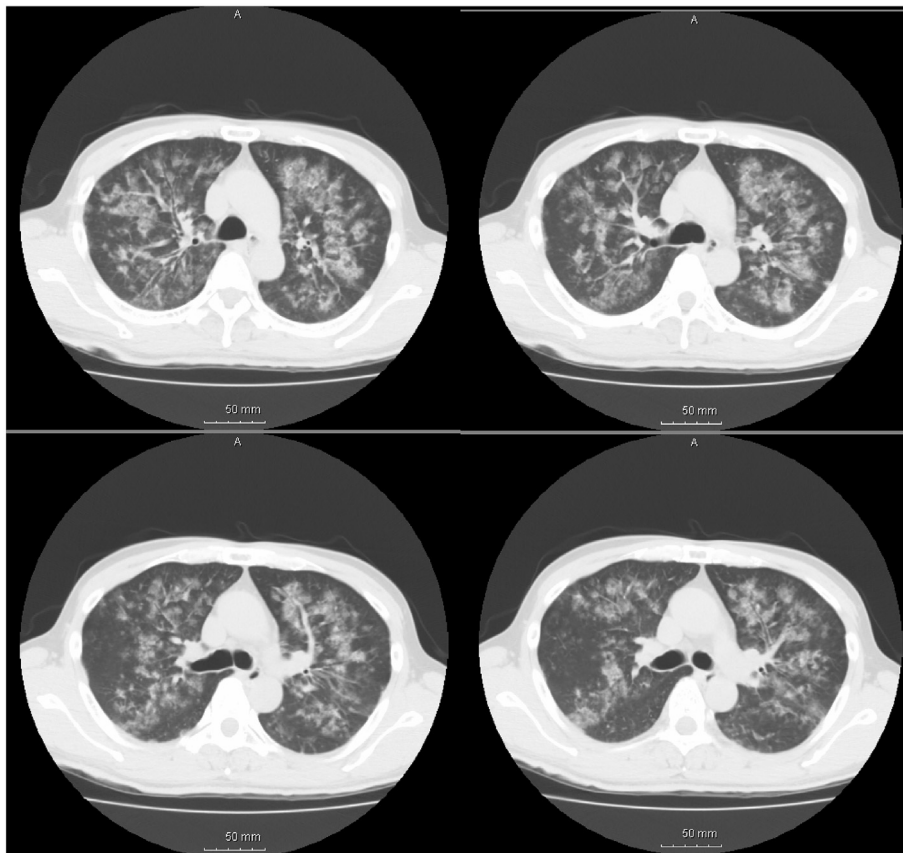


Fig. 2. Thoracic computed tomography (CT) disclosed bilateral peribronchovascular ground glass opacity, as well as centrilobular faint nodules.

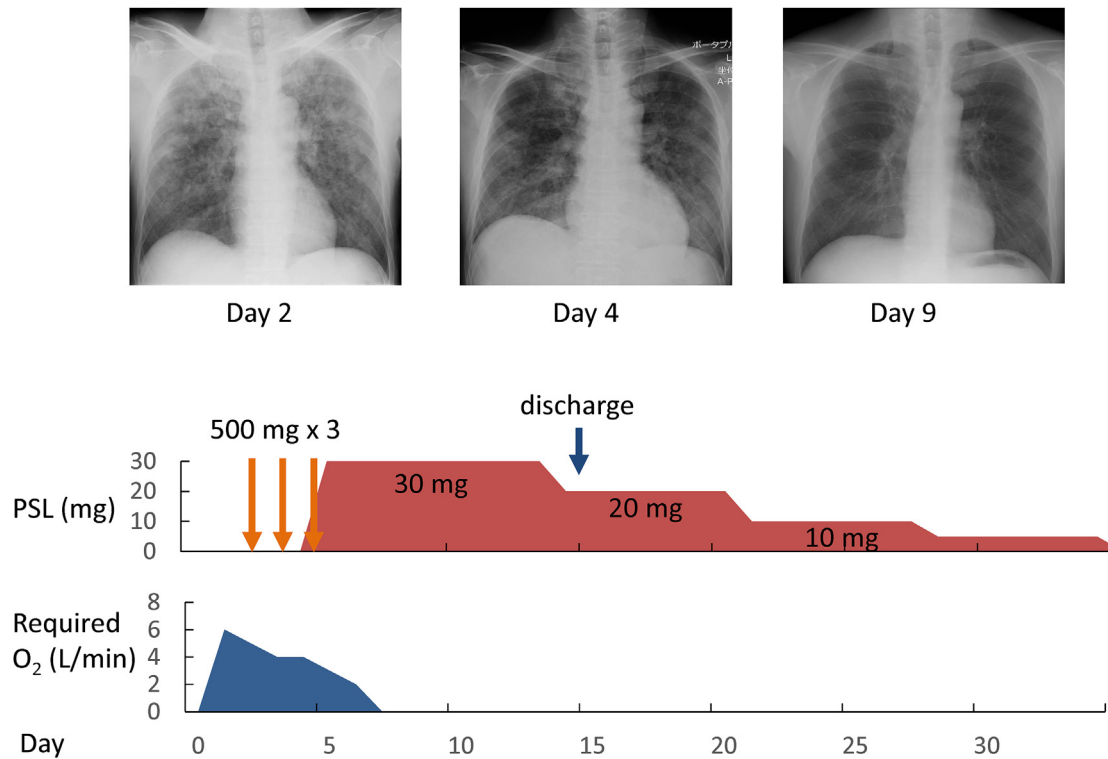


Fig. 3. Clinical course and treatments (PSL: prednisolone).

required on day 7, and the findings of respiratory function test on day 9 was normal (Table 1). He was discharged on day 15. Oral prednisolone administration was continued until day 34 without re-exacerbation, and he had not developed BO four months after exposure and had normal pulmonary function (Table 1).

3. Discussion

The symptoms and pathogenesis of occupational and environmental exposure-related toxicity are widely varied, primarily depending on the responsible chemical properties [5]. Solubility and concentration of the chemical compounds and the duration of exposure could affect the distribution and severity of respiratory tract lesions. A comparison between nitrogen oxide and ammonia leads to a comprehensive understanding of association between solubility and lesions distribution. Nitrogen oxide is low-water-soluble gas and is able to permeate to the distal bronchioles and adjacent alveoli, whereas ammonia has high water solubility, damaging the upper respiratory tract, which eventually causes eye irritation, scratchy throat, and laryngeal edema. Our case showed typical CT findings with ground glass opacity around the distal bronchioles.

The onset of manifestations after nitrogen oxide exposure widely varies from a few hours to months, and its symptoms are characterized by three different phases: acute, subacute, and delayed.

In the acute phase, symptoms, such as cough and dyspnea, emerge immediately after the exposure. The clinical effects depend on the concentration and duration of exposure. Although sudden death from laryngospasm and bronchospasm occasionally occurs at higher concentrations [2], the symptoms spontaneously disappear in many cases.

Subacute symptoms, such as dyspnea, tachypnea, cyanosis, and bronchospasm, emerge from a few hours to a day after exposure, but the latency period occasionally lasts for weeks. The pathogenesis of nitrogen oxide exposure in this subacute phase is considered to be a direct injury to the alveolar epithelial cells through generation of toxic free radicals. This chemical bronchiolar and alveolar injury sometimes develops to diffuse alveolar damage, which is often severe and associated with fatal pulmonary edema. Therefore, intensive follow-up after such exposure is strongly required for a minimum of 24 h of observation, even if patients are initially asymptomatic, because the much lower concentrations at which there is no indication of mucous membrane irritation may cause a

Table 1
The results of pulmonary function test.

	Day 7	One month after discharge	Four months after discharge
VC (L)	4.37	4.41	4.35
% VC (%)	116	118	116
FEV1.0 (L)	3.44	3.41	3.31
FEV1.0% (%)	79	77	78
PEF (L/sec)	7.9	8.8	9.4
V50 (L/sec)	4.0	3.7	3.8
DLCO (mL/min/mmHg)	28.7	28.9	31.9

Table 2
The case reports of pulmonary injury due to nitrogen oxide.

Author (year)	N	Age/sex	Severity	PaO ₂ (mmHg)	glucocorticoid	duration	prognosis
Horvath (1978)		63/M			40mg/day	3 weeks	Improved but relapsed shortly after discontinuation
Hajela (1990)		19/M	severe	42	60mg/day	7 weeks	survived
		36/M	severe	50	–	1 day	died
		44/M	severe	45	–	1 day	died
Zwemer (1992)	20	21/M	severe	43	–	1 day	died
			10 severe		3 cases	1 day	4 died
			10 mild		4 cases	>1 day	6 survived
Bur (1997)		56/M	severe	56	1000mg/day	3 days	died
Tanaka (2007)		65/M	severe	42	160mg/day	19 days	survived
		52/M	severe	57	160mg/day	5 days	survived
Jayalakshmi (2009)		37/F	severe	48	30mg/day	8 days	survived
		30/M	mild	60	125mg/day	4 days	survived
		35/M	mild		+	4 days	survived
Murphy (2010)		28/M	mild		+	2 days	survived
		66/M	severe	74	125mg/day	1 day	died
Lee (2013)		50/M	mild		50mg/day	5 days	Improved but developed BO 1 month later
Our case		50/M			+	4 weeks	survived

*1 Severe case was defined as PaO₂ < 60 mmHg at initial assessment.

*2 prednisolone.

delayed response. Concentration of 50–150 ppm may cause only mild-to-moderate irritant symptoms but induce serious damage to the lungs [2]. Exposure to only 5 ppm of NO₂ reportedly increases airway resistance by 40–60% [6]. For permeability pulmonary edema, supportive measures, such as supplemental oxygen and mechanical ventilation, are conventional therapy, and topical and systemic application of steroids has also been recommended [7]. Histological studies of the lung revealed marked thickening of the alveolar walls with lymphocytic cellular infiltrates [8]. No histological studies were performed in the present case. However, the clinical course and the findings on computed tomography suggest us that, in our case, direct alveolar injury by nitrogen oxide must have caused the similar histological change around the distal bronchioles, without the development of diffuse alveolar damage.

In the delayed phase, inflammation and fibroproliferative response are persistent, leading to fibrosis [9,10]. The resulting alveolar and bronchiolar damage are pathologically described as BO. Again, patients should be evaluated and observed regardless of the severity. BO usually has good response to steroid treatment [9], and introduction of corticosteroids is likely to reduce deaths and BO development, although some cases including silo-filler's disease have been reported wherein steroid treatment was not effective, with poor prognostic outcome [2,11,12].

Table 2 summarizes case reports of pulmonary injury due to nitrogen oxides [1,3,9,11,13–15]. In most cases, steroid therapy was induced, and in our case, the lung injury did not resolve until corticosteroids were administered. We suggest that corticosteroid therapy is applicable for pulmonary edema due to nitrogen oxides, at least for severe cases, unless contraindicated, although the duration of its administration is still undetermined. A randomized clinical trial is needed, but it is extremely difficult since such occupational and environmental accidents are rare. Because symptomatic relapses are reported when corticosteroids were discontinued after three weeks of treatment, continued corticosteroid therapy for a minimum of four weeks may be desirable [2].

There are few case reports of late-onset BO. In many cases, medical follow-up was discontinued once the symptoms improved. Lee et al. reported that BO developed one month later after five-day treatment with prednisolone [9], leading us to expect that prolonged prednisolone may be beneficial for preventing BO. In our case, we continued corticosteroid therapy for four weeks, and the

patient did not develop BO during the follow-up observation of four months. We suggest prolonged prednisolone treatment as one of the therapeutic options.

Herein, this case report demonstrates the successful therapeutic efficacy of corticosteroid therapy against a nitrogen oxide-related bronchiolar disorder. Once nitrogen gas-related bronchiolar disorders with impending respiratory failure are recognized, corticosteroid administration should be considered. Prolonged corticosteroid treatment for four weeks may be beneficial to prevent BO development.

References

- [1] C.M. Murphy, H. Akbarnia, S.R. Rose, Fatal pulmonary edema after acute occupational exposure to nitric acid, *J. Emerg. Med.* 39 (2010) 39–43.
- [2] E.P. Horvath, G.A. doPico, R.A. Barbee, H.A. Dickie, Nitrogen dioxide-induced pulmonary disease: five new cases and a review of the literature, *J. Occup. Med.* 20 (1978) 103–110.
- [3] N. Tanaka, T. Emoto, T. Matsumoto, N. Matsunaga, R. Tsuruta, D.A. Lynch, Inhalational lung injury due to nitrogen dioxide: high-resolution computed tomography findings in 3 patients, *J. Comput. Assist. Tomogr.* 31 (2007) 808–811.
- [4] V.M. Ranieri, G.D. Rubenfeld, B.T. Thompson, N.D. Ferguson, E. Caldwell, E. Fan, L. Camporota, A.S. Slutsky, Acute respiratory distress syndrome: the Berlin definition, *JAMA* 307 (2012) 2526–2533.
- [5] M. Gorguner, M. Akgun, Acute inhalation injury, *Eurasian J. Med.* 42 (2010) 28–35.
- [6] G. Bylin, Health risk evaluation of nitrogen oxide. Controlled studies on humans, *Scand. J. Work Environ. Health* 19 (Suppl 2) (1993) 37–43.
- [7] M.H. Kollef, D.P. Schuster, The acute respiratory distress syndrome, *N. Engl. J. Med.* 332 (1995) 27–37.
- [8] F.E. Donaghue, H.W. Schmidt, Farmer's lung and silo-filler's disease, *Med. Clin. N. Amer* 48 (1964) 903–910.
- [9] L.T. Lee, C.H. Ho, T.C. Putti, Bronchiolitis obliterans organizing pneumonia following nitric acid fume exposure, *Occup. Med. (Lond)* 64 (2014) 136–138.
- [10] K. Kreiss, Occupational causes of constrictive bronchiolitis, *Curr. Opin. Allergy Clin. Immunol.* 13 (2013) 167–172.
- [11] F.L. Zwemer Jr., D.S. Pratt, J.J. May, Silo filler's disease in New York State, *Am. Rev. Respir. Dis.* 146 (1992) 650–653.
- [12] E.G. Scott, W.B. Hunt Jr., Silo filler's disease, *Chest* 63 (1973) 701–706.
- [13] A. Bur, A. Wagner, M. Roggla, A. Berzlanovic, H. Herkner, F. Sterz, A.N. Laggner, Fatal pulmonary edema after nitric acid inhalation, *Resuscitation* 35 (1997) 33–36.
- [14] R. Hajela, D.T. Janigan, P.L. Landrigan, S.F. Boudreau, S. Sebastian, Fatal pulmonary edema due to nitric acid fume inhalation in three pulp-mill workers, *Chest* 97 (1990) 487–489.
- [15] T.K. Jayalakshmi, S. Shah, I. Lobo, A. Uppe, A. Mehta, Acute lung injury following exposure to nitric acid, *Lung India* 26 (2009) 149–151.