

Oncology

Successful Radiotherapy for Advanced Small Cell Carcinoma of the Prostate with Syndrome of Inappropriate Secretion of Antidiuretic Hormone



Masanari Fukasawa^a, Norifumi Sawada^{a,*}, Hiroshi Shimura^a, Tatsuya Ihara^a, Satoru Kira^a, Hidenori Zakoji^b, Takahiko Mitsui^a, Masayuki Takeda^a

^a Department of Urology, Interdisciplinary Graduate School of Medicine, University of Yamanashi, Chuo City, Yamanashi, Japan

^b Department of Urology, Tokai University Hachioji Hospital, Hachioji, Japan

ARTICLE INFO

Article history:

Received 11 April 2017

Accepted 20 April 2017

Key words:

Radiotherapy

Small cell carcinoma of the prostate

Syndrome of inappropriate secretion of antidiuretic hormone

Hyponatremia

Neuron-specific enolase

ABSTRACT

Small cell carcinoma of the prostate (SCCP) is rare in clinical practice. It is often accompanied with the syndrome of inappropriate antidiuretic hormone secretion (SIADH). We present a case of SCCP with SIADH that was successfully treated with radiotherapy in the metastatic lymphnodes and prostate. The patient was an 81-year-old male with a castrate-resistant prostate cancer (CRPC) with invaded rectum and multiple metastases of pelvic lymphnodes. Hyponatremia was present. After radiotherapy, serum sodium increased and neuron-specific enolase (NSE) decreased. To our knowledge, this is the first case of SCCP with SIADH treated with radiotherapy to improve hyponatremia.

© 2017 The Authors. Published by Elsevier Inc. This is an open access article under the CC BY-NC-ND license (<http://creativecommons.org/licenses/by-nc-nd/4.0/>).

Introduction

The syndrome of inappropriate secretion of antidiuretic hormone (SIADH) is associated with numerous clinical conditions including malignancy, benign pulmonary and neurologic diseases, and a drug side effect. Lung small cell carcinoma is the most common cause of SIADH.¹ Bartter revised cardinal findings in 1973 as follows: 1) hypotonicity of plasma with hyponatremia, 2) urinary solute concentration higher than plasma solute concentration, 3) excretion of sodium in urine, 4) depression of plasma renin despite hyponatremia, and 5) normal renal function.² There are few reports of SIADH derived from prostate cancer.^{3,4}

We report a rare case of SIADH in the advanced small cell carcinoma of the prostate (SCCP) treated with radiation therapy. This case emphasizes the treatment option of radiotherapy for hyponatremia induced by SCCP.

Case presentation

An 81-year-old male with a castrate-resistant prostate carcinoma (CRPC) was hospitalized in orthopedic department for the

surgery of a compression fracture which was due to the metastasis of the prostate cancer. He had already diagnosed poorly differentiated adenocarcinoma, Gleason 5 + 5 (Fig. 1A and B). His serum prostate specific antigen (PSA) was 21.0 ng/mL. He had received combined androgen block (CAB) therapy with bicalutamide in combination with gonadotropin-releasing hormone agonist goserelin. After a year and two months, PSA increased and hyponatremia has emerged. The antiandrogen drug was changed to abiraterone. Hyponatremia was controlled with 9 g of sodium chloride intake. Then he incidentally had the compression fracture of third lumbar vertebra and admitted to the orthopedic unit in our hospital. The lumbar vertebra was fixed and he was referred to our department for CRPC. Computed tomography (CT) revealed an enlarged prostate cancer that is involving the rectum and multiple metastases of pelvic lymph nodes. Stony hard prostate was palpable in the physical examination. Laboratory data demonstrated serum sodium 120 (mEq/L), serum osmolality 250 (mOsm/kg), plasma renin activity 0.4 (ng/mL/h), serum antidiuretic hormone (ADH) 6.8 (pg/mL), eGFR 82 (mL/min), urine sodium 127 (mEq/L) and urine osmolality 422 (mOsm/kg). Serum PSA was 8.49 (ng/mL). Results of a complete endocrine evaluation, including thyroid function test, serum cortisol, drug screening and head and chest CT were normal. From the following reasons, the patient was diagnosed with SIADH. Treated with sodium chloride infusion with sodium chloride intake of 9 g, however, it was difficult to control hyponatremia.

* Corresponding author.

E-mail address: nsawada@yamanashi.ac.jp (N. Sawada).

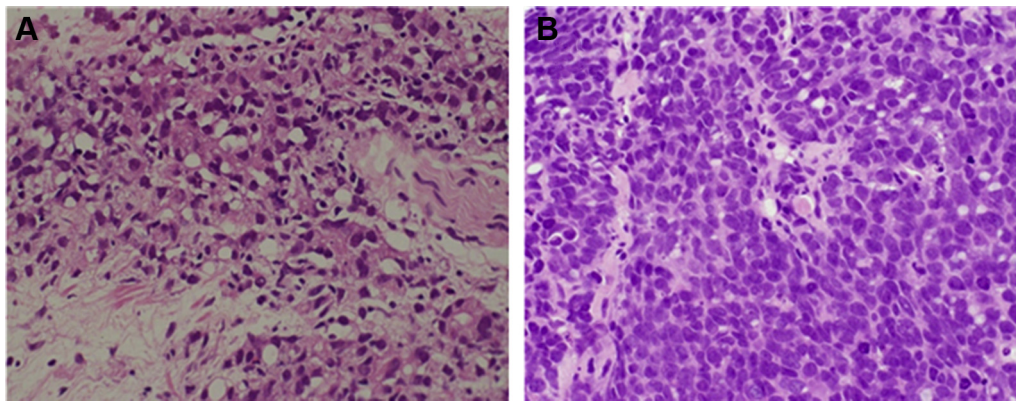


Figure 1. Comparison of the initial (A) and the advanced stage (B) pathologic findings of transrectal ultrasound prostate biopsy. The initial biopsy shows poorly differentiated adenocarcinoma, Gleason score 5 + 5 (A). Biopsy finding in the advanced stage showed polygonal or round small cells that showed sheet, nest, and strand configurations. The tumor cells had scanty cytoplasm and pleomorphic hyperchromatic nuclei (B). (H&E, $\times 400$).

To confirm the pathogenesis of SIADH, we performed transrectal needle re-biopsy of the prostate. Pathology revealed SCCP. He had a continuing rectal bleeding, therefore, we decided to irradiate the prostate and the rectum for hemostasis, including the pelvic lymph nodes. The radiotherapy 28 Gy (4 Gy \times 7 days) was first performed to the bone metastatic lesion in the third lumbar vertebrae and 45 Gy (3 Gy \times 15 days) was then continued to the prostate lesion including the involved rectum and pelvic lymph nodes. After the radiation, the average serum sodium has increased from 120 to 130 mEq/mL, while NSE has decreased from 344.3 to 151.4 (ng/mL) (Fig. 2). One month after the radiotherapy completed, he died of hemorrhagic shock due to sudden rectal bleeding. He had not been treated with sodium injection therapy after the radiotherapy.

Discussion

Hyponatremia is the most common electrolyte abnormality in patients with malignancy, and SIADH is one of the major causes of malignancy-associated hyponatremia. It is characterized by impaired water excretion caused by impaired water excretion caused by the improperly increased ADH secretion. Although the plasma ADH level in this patient was 6.8 pg/mL, this level was abnormal in considering the hypo-osmolar state of this patient. This patient exhibited all of the serum and urinary findings consistent with this syndrome, and he was clinically euvoletic. After the extensive investigation, diagnosis of SIADH was made by the exclusion of other causes and all other sources of ADH secretion. Of

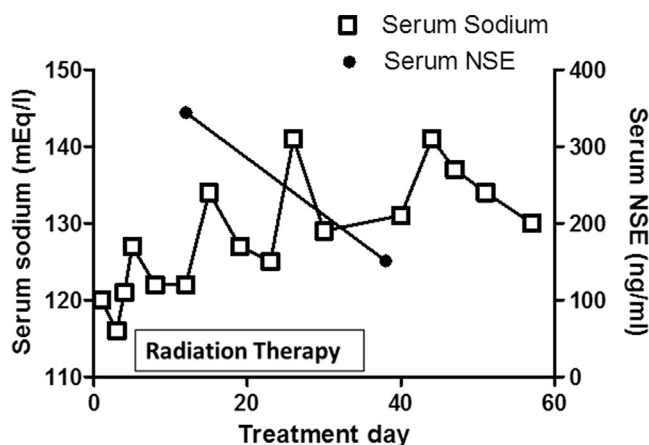


Figure 2. Clinical course and serum levels of sodium and NSE in the patient. \square , Serum sodium (mEq/l); \bullet , serum NSE (ng/mL).

the tumors that cause SIADH, small cell carcinoma of lung is the most common, with reported incidence of 11%.⁵

This patient had the pathological findings of poorly differentiated adenocarcinoma, Gleason Grade 5 + 5 = 10 in the initial biopsy and was started CAB therapy in a clinic. The serum PSA maintained around 0.5 mg/mL for a year and 2 months, however, there was a slight increase in PSA and the patient was diagnosed as CRPC. Hyponatremia was detected from his disorientation episodes at the same time when he was treated abiraterone. After the admission to our hospital for the third lumbar fracture, control of the serum sodium level had become extremely difficult. The transrectal prostate biopsy revealed the poorly differentiated cells and high nuclear-cytoplasmic (N/C) ratio and he was diagnosed as SCCP.

There is no standardized therapy for small cell carcinoma. Considering that CT scan has revealed the prostate cancer involving the rectum and pelvic lymph nodes, we determined to perform radiation therapy to the prostate and the surrounding rectal and lymph metastasis. A total 45 Gy to the prostate, rectum and pelvic lymph nodes, and 28 Gy to the bone metastasis was radiated to the patient. After the radiation, the average serum sodium concentration had increased, while NSE has decreased. It is likely that radiation had an effect in the prostate, pelvic lymphatic nodes, and the metastatic third vertebrae.

Conclusions

To our knowledge, this is a very rare case of SCCP in which hyponatremia was successfully managed with radiation therapy. One month after the radiation therapy, the patient died of relapsed rectal bleeding. We presented this case to report that radiation therapy can be one of the best supportive cares for the SIADH induced by advanced prostate cancer.

Conflict of interest

The authors state that they have no financial conflict of interest.

References

- Esposito P, Piotti G, Bianzina S, et al. The syndrome of inappropriate antidiuresis: pathophysiology, clinical management and new therapeutic options. *Nephron Clin Pract.* 2011;119:c62–c73. discussion c73.
- Bartter FC. The syndrome of inappropriate secretion of antidiuretic hormone (SIADH). *Dis Mon.* 1973;1–47.
- Ito H, Nishimura T, Abe H, et al. Adenocarcinoma of the prostate with ectopic antidiuretic hormone production: a case report. *Hinyokika Kyo.* 2000;46:499–503.
- Lee KS, Kang TW, Ma SK, et al. SIADH associated with prostate cancer. *Electrolyte Blood Press.* 2007;5:47–49.
- List AF, Hainsworth JD, Davis BW, et al. The syndrome of inappropriate secretion of antidiuretic hormone (SIADH) in small-cell lung cancer. *J Clin Oncol.* 1986;4:1191–1198.