



**Mohammad Hosny Awad,
Amany El-Hawary, Gehan Sawah,
Nehad Nasef**

Department of Pediatrics, Faculty of Medicine,
University of Mansoura, Mansoura, Egypt

Received: August 18, 2020
 Revised: January 24, 2021
 Accepted: January 25, 2021

Corresponding author:
 Mohammad Hosny Awad, MD
 Department of Pediatrics, Mansoura University
 Children's Hospital, Gomhoria Street, Mansoura
 35516, Egypt
 Tel: +20-11116966363, Fax: +20-11116966363
 E-mail: mo7amed_hosny@hotmail.com

No potential conflict of interest relevant to this
 article was reported.

Pan-vasculitis and fulminant hepatitis following routine vaccination at the age of 4 months

Vaccines are known to have side effects, most of which are tolerable. Vasculitis following vaccination is reported and has various modes of presentation. We report a 4-month-old girl presented with an unusual presentation of fulminant hepatitis, pan vasculitis, and diffuse body aneurysms following routine immunization diagnosed by echocardiography and computed tomography angiogram. It is important to be aware of different possible adverse effects following vaccines and their different modes of presentation as well as possible treatments such as intravenous immunoglobulins and high dose methylprednisolone.

Keywords: Immunization, Vaccine, Vasculitis

Introduction

Vasculitis is defined as the presence of inflammation in the walls of blood vessels [1]. Numerous causes have been connected to vasculitis, for example, infectious microorganisms, connective tissue disease, malignancies, medications, and other causes remains unknown [2]. Vasculitis have been reported as adverse events following immunization with various varieties of vaccines [3]. We report a case of systemic vasculitis with picture of fulminant hepatic failure presented 2 days after routine immunization for diphtheria-tetanus-pertussis (DPT)-haemophilus influenzae type b (Hib)-hepatitis B virus (HBV) vaccine.

Case Report

A 4-month-old, previously healthy, female infant was admitted to the hospital 2 days after receiving her routine 4-month immunizations including DPT, hepatitis B, and Hib vaccines. The infant suffered an initial fever which was relieved with antipyretics. Two days later her fever subsided, and she developed deep jaundice, tachycardia (140 bpm), tachypnea (45/min), and normal initial blood pressure. She had purulent bilateral conjunctivitis, diffuse maculopapular skin rash all over the body with normal heart, lung, and abdominal examination. Her initial laboratory investigations showed leukocytosis ($42,400/\text{mm}^3$), anemia (9 g/dL), thrombocytopenia ($68,000/\text{mm}^3$), high C-reactive protein (97 mg/L), high erythrocyte sedimentation rate (24 mm/hr), direct hyperbilirubinemia (serum total and direct bilirubin were 11 mg/dL and 9 mg/dL, respectively), hypoalbuminemia (2.2 g/dL), prolonged international normalized ratio

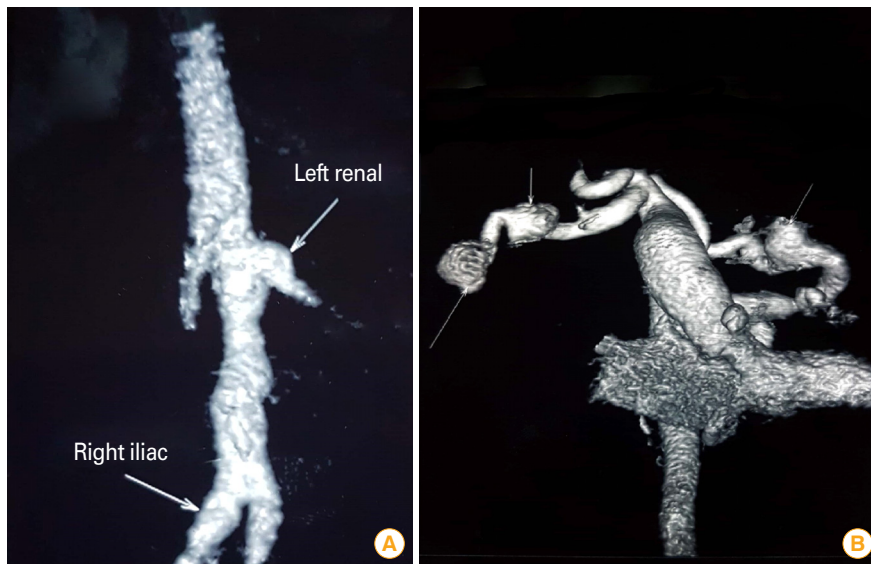


Fig. 1. (A) Computed tomography (CT) angiogram showing left renal and right iliac arteries aneurysms (arrows). (B) CT angiogram showing bilateral subclavian arteries aneurysms (arrows).

(INR), and elevated liver enzymes (alanine transaminase 51 U/L and aspartate transaminase 65 U/L). Her initial serum electrolytes, urine analysis, chest X-ray, echocardiography, and computed tomography (CT) of the brain were all reported to be normal. She had negative blood culture as well as screens for cytomegalovirus, Epstein-Barr virus, hepatitis A virus, hepatitis B virus, hepatitis C virus, and human immunodeficiency virus.

She was maintained on supportive treatment of intravenous fluid, antibiotics, and repeated blood products transfusion with a provisional diagnosis of infection induced disseminated intravascular coagulation. One week after admission she developed disturbed conscious level, hypertension, and cardiomegaly on her chest X-ray. Echocardiography was repeated showing aneurysmal dilatation of the right coronary artery (6 mm), left anterior descending artery (6 mm), left main coronary artery (4 mm), mild aortic regurg (grade 1), and moderate mitral regurg (grade 2). Atypical Kawasaki disease was suspected, and she was started on 5 days course of intravenous immunoglobulins (IVIG) therapy 1 week after admission without clinical improvement. CT angiogram was performed revealing ectatic coronary arteries with fusiform aneurysm in the left circumflex artery (15×9 mm) and right coronary artery (7.4×11 mm) together with ectasia in the iliac arteries (6 mm), subclavian saccular aneurysm (Fig. 1B) (13×12 mm), axillary arteries multiple saccular aneurysms (2×1.5 cm), ectasia of the common trunk originating the common carotid artery, and brachiocephalic artery (9 mm). Further-

more, a small (6×6 mm) fusiform aneurysm at the origin of left renal artery was found (Fig. 1A). Magnetic resonance angiography of the brain was done revealing multiple minute aneurysms with small foci of intracerebral hemorrhages. Immunological work up for pan vasculitis including ANCA (antineutrophil cytoplasmic autoantibodies), ANA (antinuclear antibody), anti ds-DNA (anti-double stranded DNA), and serum C3 were all normal. The pathological assessment was not performed as all involved arteries were non-accessible. Follow-up liver function revealed persistent elevation of liver enzymes, direct hyperbilirubinemia, and prolonged INR.

She was diagnosed to have immune-mediated pan-vasculitis and hepatitis and was treated with high dose methylprednisolone at a dose of 30 mg/kg for 3 days with the gradual improvement of her conscious level and liver function tests. She was gradually weaned off antibiotics and other supportive measures over 1 week. She was discharged home with residual hypertension maintained on antihypertensive and antiplatelet therapy. A repeat CT angiogram 2 months later revealed regression of previously described aneurysms with residuals in the coronary arteries, which were persistently unchanged on repeated echo assessments over the first year of life. Patient's caregiver provided written informed consent for publication of the research details and clinical images.

Discussion

Vaccinations are normally well tolerated all around with known

possible adverse effects as fever, pruritus, muscle pain, and skin rash [4]. To our knowledge, this is the first described case to develop pan-vasculitis with concomitant fulminant hepatitis following routine immunization for DPT-Hib-HBV vaccine at 4 months of age.

Different types of vasculitis were reported following routine vaccination, including leukocytoclastic vasculitis following influenza vaccines [5], Kawasaki disease following hepatitis B vaccination [4] and DTaP-IPV-Hib (diphtheria, tetanus, pertussis, polio, Hib) vaccine [6], giant cell arteritis following influenza vaccine [7], and polyarteritis nodosa following hepatitis B vaccine [8].

Although initially diagnosed as post vaccination atypical Kawasaki vasculitis based on coronary arteries aneurysms on echocardiographic assessment, lack of response to IVIG therapy together with absence of other features of Kawasaki disease excluded this possibility. Further radiological assessment revealed involvement of small, medium, and large arteries together with the coronary system including the subclavian artery, axillary arteries, common carotid artery, brachiocephalic artery, left renal artery, and small intra-cerebral arteries. This picture of pan-vasculitis together with hepatitis, thrombocytopenia, and anemia suggested a possible immune-mediated response to the vaccine. The immediate response to methylprednisolone therapy with regression of all aneurysms, except for the coronary arteries, as well as an improved picture of hepatitis and platelet count further supports the possible immune-mediated response following routine immunization.

One limitation to our case report is the lack of histopathological diagnosis; however, the instability of the infant and the non-accessibility of the involved vessels disallowed this confirmation.

In general, vaccines are safe and most side effects are well tolerated. In rare situations, some side effects, like immune-mediated vasculitis, can be severe and endanger the patient life. Physicians should be aware of different possible adverse effects following vaccines and their different modes of presentation as well as possible treatments such as IVIG and high dose methylprednisolone.

ORCID

Mohammad Hosny Awad

<https://orcid.org/0000-0002-9177-6554>

Amany El-Hawary <https://orcid.org/0000-0003-0453-2381>

Gehan Attia Alsawah <https://orcid.org/0000-0002-8999-2231>

Nehad Nasef <https://orcid.org/0000-0001-7650-123X>

References

1. Gardner-Medwin JM, Dolezalova P, Cummins C, Southwood TR. Incidence of Henoch-Schonlein purpura, Kawasaki disease, and rare vasculitides in children of different ethnic origins. *Lancet* 2002;360:1197-202.
2. Zafrir Y, Agmon-Levin N, Shoenfeld Y. Post-influenza vaccination vasculitides: a possible new entity. *J Clin Rheumatol* 2009;15:269-70.
3. Felicetti P, Trotta F, Bonetto C, et al. Spontaneous reports of vasculitis as an adverse event following immunization: a descriptive analysis across three international databases. *Vaccine* 2016;34:6634-40.
4. Miron D, Fink D, Hashkes PJ. Kawasaki disease in an infant following immunisation with hepatitis B vaccine. *Clin Rheumatol* 2003;22:461-3.
5. Ulm S, Hummel M, Emig M, et al. Leukocytoclastic vasculitis and acute renal failure after influenza vaccination in an elderly patient with myelodysplastic syndrome. *Onkologie* 2006;29:470-2.
6. Ece I, Akbayram S, Demiroren K, Uner A. Is Kawasaki disease a side effect of vaccination as well? *J Vaccines Vaccin* 2014;5:234.
7. Wada M, Asai J, Asai A, Nakai D, Kishimoto S, Katoh N. Giant cell arteritis with polymyalgia rheumatica associated with influenza vaccination. *J Dermatol* 2011;38:1099-101.
8. Tan C, Zhu WY, Min ZS. Papular elastorrhesis located on occipito-cervical and mandibular regions. *Eur J Dermatol* 2009;19:399-400.