

Received: 2021.07.07

Accepted: 2021.08.30

Available online: 2021.09.17

Published: 2021.10.19

A Challenging Case of Using Manta Ray Skin Flaps in a Severe Post-Traumatic First Web Space Contracture

Authors' Contribution:

Study Design A
Data Collection B
Statistical Analysis C
Data Interpretation D
Manuscript Preparation E
Literature Search F
Funds Collection G

ABCDEF **Tsvetan Tsenkov**
ACDG **Nikolay Dimitrov**

Department of Orthopaedics and Traumatology, Medical University – Sofia,
University Hospital of Orthopaedics "Prof. B. Boichev", Sofia, Bulgaria

Corresponding Author: Tsvetan Tsenkov, e-mail: tsvetan.tsenkov@icloud.com
Financial support: None declared
Conflict of interest: None declared

Patient: Male, 36-year-old
Final Diagnosis: Web space contracture
Symptoms: Joint stiffness • loss of thumb abduction • severe scarring
Medication: —
Clinical Procedure: Contracture release
Specialty: Orthopedics and Traumatology • Plastic Surgery

Objective: Unusual clinical course

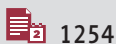
Background: First web space contracture affects thumb function and grasping capacity. This pathology alters normal anatomy and results in decreased ability to use the hand. Appropriate release and resurfacing are needed to restore normal hand function. Principles of successful treatment also include providing healthy compliant skin for a tension-free closure and a smooth healing period. The Manta Ray skin flaps are utilized in children, allowing the position of as much local skin as possible with minimal dorsal scarring. The technique has potential use in adults who have less skin plasticity and pliability.

Case Report: We present the case of a 36-year-old patient with a severe first web space contracture of the dominant hand. Primary concerns of the patient were loss of hand mobility, limited grasping ability, and an inability to “give a proper handshake”. Medical history suggests a gunshot wound in early childhood treated operatively by a mild web release after the point of trauma, with insufficient outcomes. We proceeded with the Manta Ray flap technique using 3 dorsally-based flaps and 4 palmar-based flaps, with excellent results.

Conclusions: Although the Manta Ray flap procedure was developed for moderate web space contractures in children, it combines advantages of several flap techniques. It ensures sufficient web space lengthening and may be applicable in older patients if enough healthy unscarred skin is available. These unique properties and potential led us to use the method for this challenging case.

Keywords: Case Reports • Contracture • Reconstructive Surgical Procedures

Full-text PDF: <https://www.amjcaserep.com/abstract/index/idArt/933907>




1254



—



5



13



Background

Proper hand function is ensured by the thumb [1]. This is achieved by normal anatomical and physiological relations. Web space contractures disrupt these relations and alter thumb mobility and grasping [2].

First web space contracture may involve not only skin, but also subcutaneous tissue, fascia, muscles, and joint ligaments. The etiology of this condition can be congenital or acquired (eg, trauma, infection, arthritis). Existing web contractures require operative reconstruction consisting of adhesion release and skin resurfacing [3]. The former may be difficult to estimate before actual surgical exploration, while the latter can be done using different methods (eg, skin flaps or skin grafts), and the preferred approach depends on the contracture grade and skin properties.

Severe post-traumatic cases can be challenging and they depend on the extent of tissue involvement, local skin status, previous corrections, and patient age. The surgeon must decide how to reconstruct the first web space and which method best suits the particular patient.

Case Report

We present the case of a 36-year-old patient with a severe first web space contracture of the dominant hand. Primary concerns of the patient were loss of hand mobility, limited grasping ability, and an inability to “give a proper handshake”. His medical history suggested a gunshot wound in early childhood, treated operatively by a mild web release after the point of trauma, with insufficient outcomes. The patient was not satisfied with the results of the procedure and did not feel his hand had improved. After that, he did not seek further medical attention until the point of current admission.

A clinical examination described a severe thumb contracture, with a thumb index angle of about 12 degrees (**Figure 1**). Additionally, dorsal scarring was evident, affecting the region from the first web space to the proximal part of the first metacarpal bone. Range of motion was impaired – the mean range of palmar abduction of the carpometacarpal joint (CMCJ) was of about 20 degrees, retroposition of about 10 degrees, radial abduction of about 22 degrees, opposition Kapandji grade 5, and adduction of about 2 degrees. Proximal and distal joint motion was physiological. Manual muscle testing was not objective due to the adaptive properties of intrinsic hand muscles. Neurovascular function was normal.

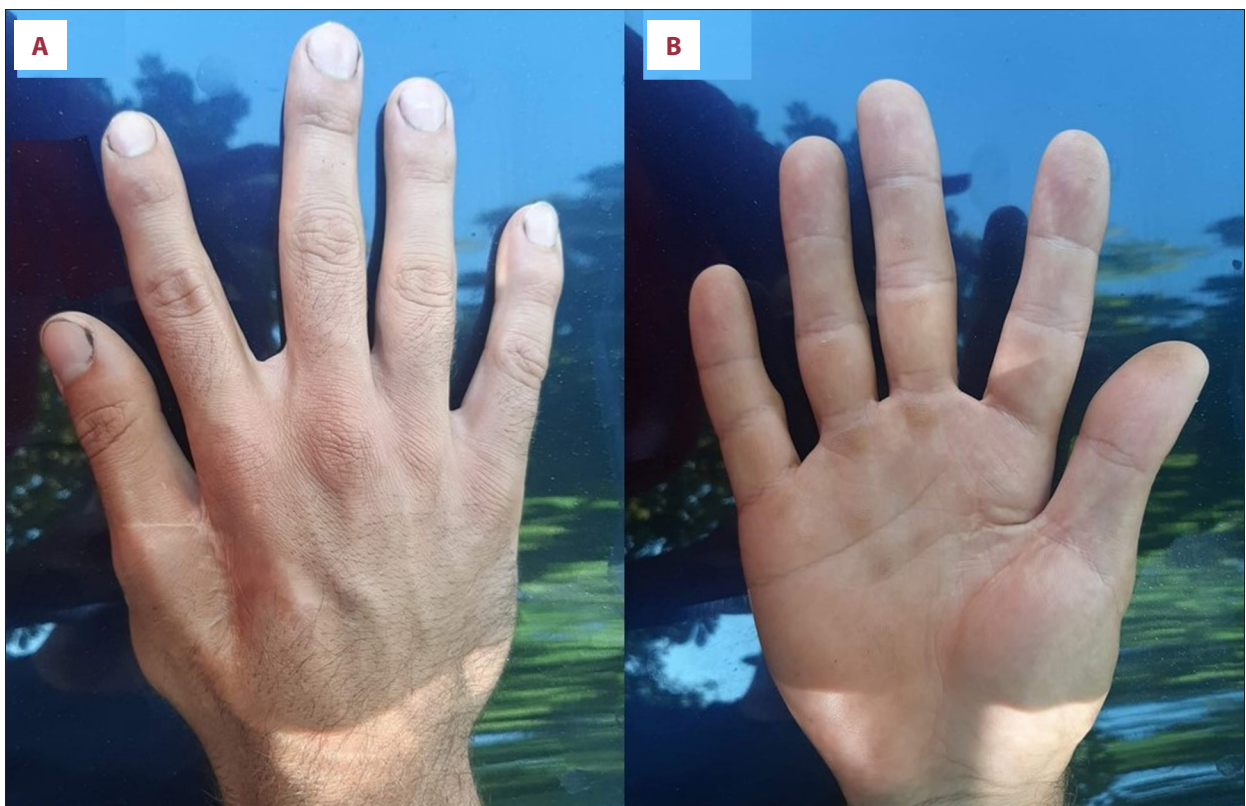


Figure 1. Dorsal (A) and palmar (B) side of affected arm. Post-traumatic severe thumb adduction contracture with a thumb index angle of about 12 degrees.

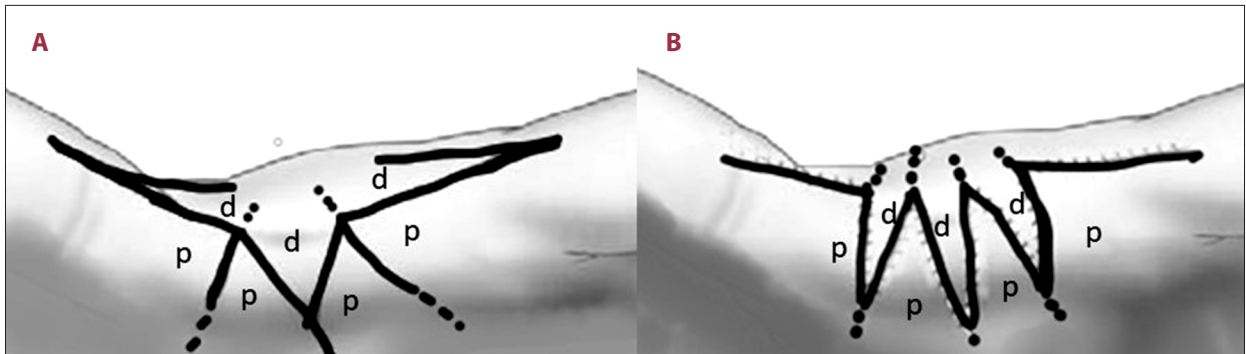


Figure 2. Preoperative (A) and postoperative (B) method schema and design of the Manta Ray flaps. p – palmar flaps; d – dorsal flaps

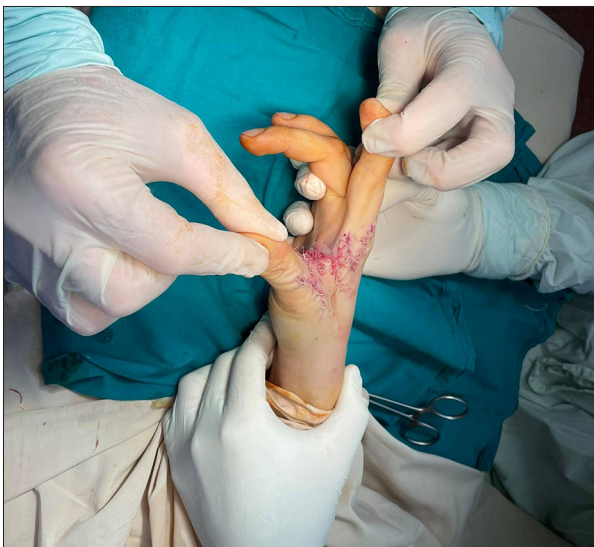

Figure 3. Manta Ray skin flaps: 3 dorsally-based flaps and 4 palmar-based flaps.

Diagnostic testing included goniometry of the thumb index angle, X-rays of the affected hand, and a patient-answered survey. We measured the thumb index angle to determine the severity of the condition. The X-rays excluded other diagnoses that affect the bones and/or joints, like arthritis and congenital dysplasia. Finally, The Disabilities of the Arm, Shoulder and Hand (DASH) questionnaire was used to evaluate impairments of activities. A DASH score of 52 indicated moderate disability.

We proceeded with the Manta Ray flap technique using 3 dorsal skin flaps and 4 palmar skin flaps (Figure 2). According to the originally described procedure, the length of the flap on the radial side of the index and ulnar side of the thumb can be up to 75% of the length of the corresponding proximal phalanx of that digit [4]. We achieved an 80% ratio. After that, we determined the flap width and projected how to properly close the donor sides (Figure 3).

The first dorsal interosseous muscle fascia was incised. The muscle itself was deeply scarred and not functional. We continued

with an extensive release of the remaining muscle and CMCJ contractures. The ulnar neurovascular bundle to the thumb, the radial neurovascular bundle to the index finger, and the terminal branches of the superficial radial nerve on the dorsum of the first web were intact.

After a satisfactory release, the flaps were repositioned and the skin was approximated with absorbable sutures (Figure 4). Postoperatively, we applied a thumb abduction splint with about 65-70 degrees of fixed thumb index angle.

We reviewed the wound at several follow-ups and the patient proceeded with an aggressive rehabilitation program for 3 months. No complications affecting the healing process were noted. Outcomes were the following: thumb index angle was 62 degrees (Figure 5), range of palmar abduction of the CMCJ was 45 degrees, retroposition was 14 degrees, radial abduction was 44 degrees, opposition Kapandji grade was 9, and abduction was 5 degrees. The DASH score improved to 22. No adverse or unanticipated events were recorded.

Discussion

The primary issue in patients with an addition thumb contracture is to release and to resurface the web space. After release, reconstruction requires the distribution of well-vascularized, flexible, and sensate skin [5]. The surgeon must decide which technique to use for the web space skin lengthening. This involves the incorporation of new skin into the web space and can be done by using flaps or grafts [3]. Flap techniques are divided into local flaps, regional flaps, and distant flaps. The first may be intraweb or extraweb. This includes Z-plasty techniques, square flaps, transposition flaps, rotation flaps and tissue expansion [6-11]. Regional methods for adding skin include pedicled forearm flaps, pedicled, free groin, and other free flaps [12,13].

Choosing the flap technique depends on the expected skin defect. It is determined by the severity of the web space

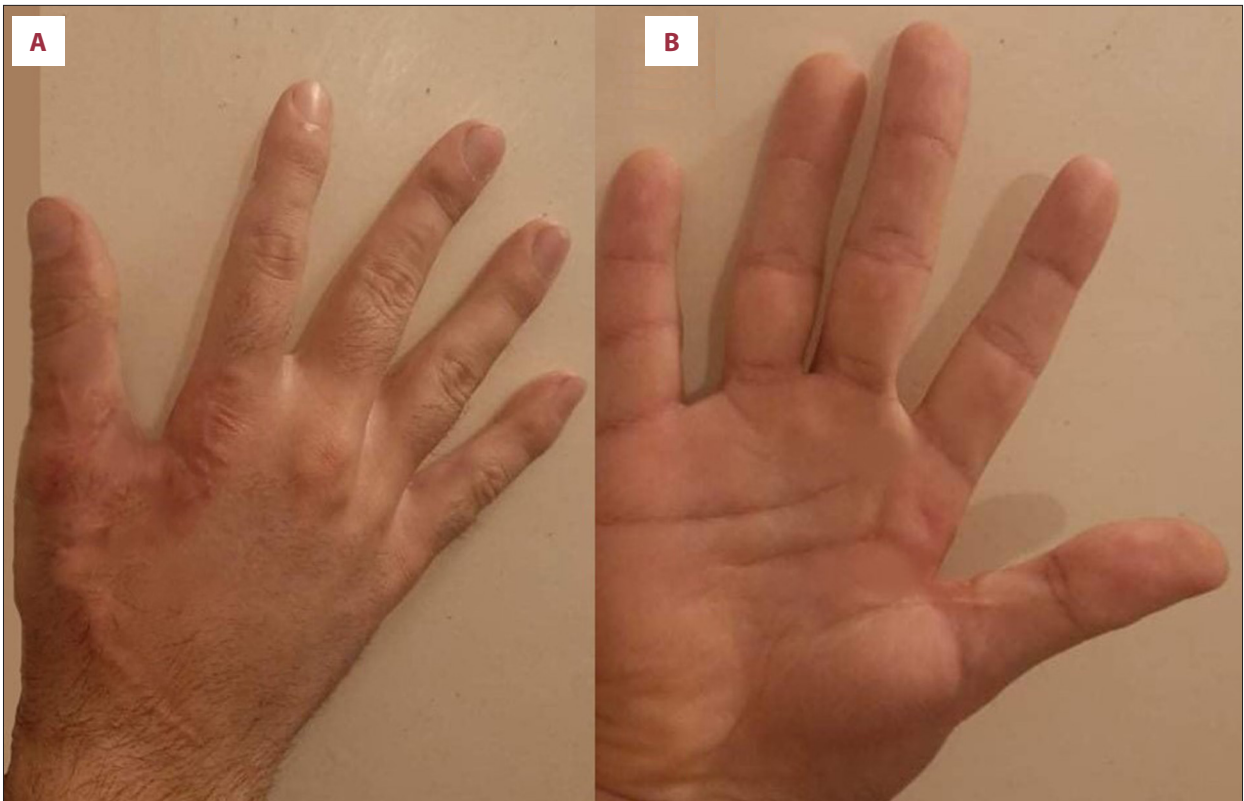


Figure 4. (A, B) Postoperative result. Skin flaps were approximated with absorbable sutures.

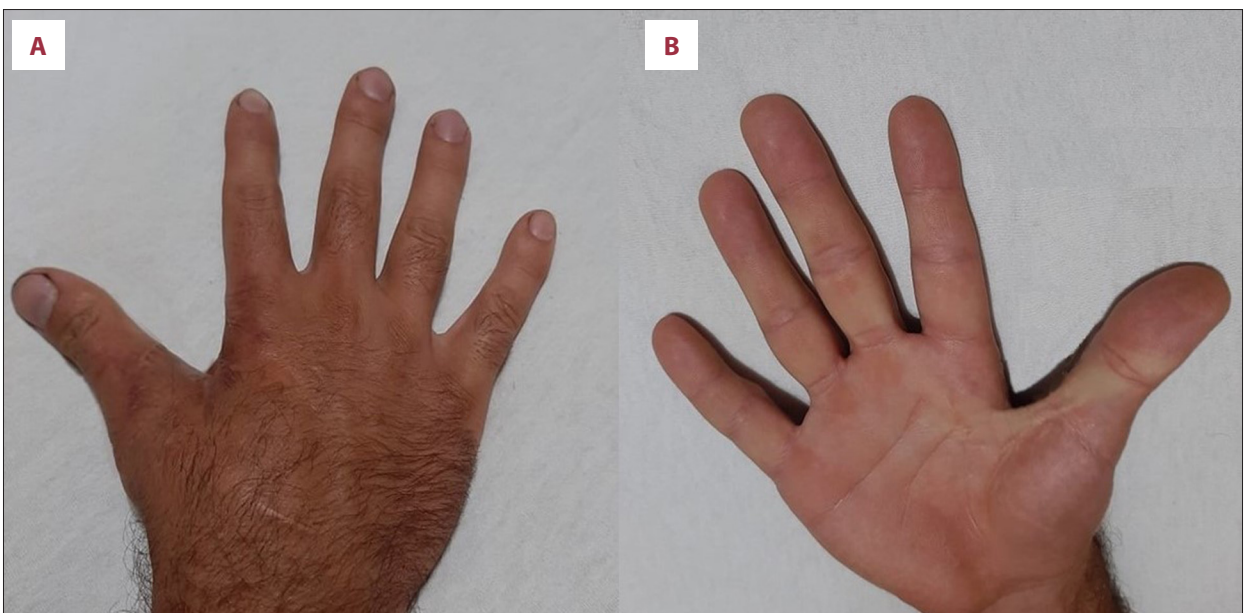


Figure 5. Three-month follow-up results. The dorsal (A) and palmar (B) side of the hand show minimal scarring from the current procedure. Thumb index angle of 62 degrees converting the contracture from severe to mild using Manta Ray skin flaps.

contracture. The 3 categories of contracture are mild, moderate, and severe. Mild contractures present with a thumb index angle of 60 to 90 degrees. A good result can be achieved with an increase of 50% of web space skin length. Moderate contractures have a thumb index angle of 40 to 60 degrees and require a 50% to 125% increase of web space skin length. Severe web space contractures have a thumb index angle of below 40 degrees and need a more than 125% increase of web space skin length [2].

Local skin flap procedures have the tendency to under-release the web in cases of moderate contracture. Type 3 and type 4 flaps seem to overcorrect the release. The Manta Ray flap is a mixture of type 1 and type 2 flaps, importing as much skin as possible into the web [4]. Other methods, such as the large dorsal-based rotation flaps, can be quite complex and esthetically unacceptable, often requiring skin grafts for secondary defects. The Manta Ray keeps scarring within the web space of the thumb and the palmar space, leaving minimal dorsal scarring on the socially presented surface of the hand. Furthermore, the procedure ensures good vascularization and sensation, allowing excellent surgical exposure of structures and a healthy web space increase.

Known complications of the procedure are infection, flap necrosis, and inadequate web lengthening [4]. Insufficient release

usually occurs due to a significant dorsal skin contracture or a more severe first web space contracture. In the present case, the web space contracture was severe, and an extensive but careful adhesiolysis was performed. The dorsal skin was sufficient and had good elastic properties despite the patient's age and scarring from the previous operation.

Conclusions

Although the Manta Ray procedure is a popular choice for moderate contractures and is often used in children, we decided to utilize it in this severe case due to its excellent properties and advantages over other flap techniques. The procedure ensures minimal dorsal scarring and sufficient web space lengthening and may be applicable in older patients if enough healthy unscarred skin is available. Although the Manta Ray flap technique was developed for moderate web space contractures in children, its unique properties and potential led us to use this challenging method for this post-traumatic adult patient.

Declaration of Figures' Authenticity

All figures submitted have been created by the authors, who confirm that the images are original with no duplication and have not been previously published in whole or in part.

References:

1. Rabinovich RV, Polatsch DB, Shin SS, Beldner S. Thumb carpometacarpal instability. *J Am Acad Orthop Surg.* 2021 [Online ahead of print]
2. Moody L, Galvez MG, Chang J. Reconstruction of first web space contractures. *J Hand Surg Am.* 2015;40(9):1892-95
3. Brown M, Chung KC. Postburn contractures of the hand. *Hand Clin.* 2017;33(2):317-31
4. Coombs CJ, Thomas DJ. The manta ray flap: A technique for first web space release. *Tech Hand Up Extrem Surg.* 2010;14(1):41-45
5. Greyson MA, Wilkens SC, Sood RF, et al. Five essential principles for first web space reconstruction in the burned hand. *Plast Reconstr Surg.* 2020;(1):578E-87E
6. Coombs CJ, Mutimer KL. Tissue expansion for the treatment of complete syndactyly of the first web. *J Hand Surg Am.* 1994;19(6):968-72
7. Kim H II, Kim HS, Park JH, et al. Reconstruction of a small defect of the lower vermilion adjacent to white roll using a modified O-Z flap. *Arch Craniofacial Surg.* 2021;22(3):164-67
8. Ahmad M, Khan ZA, Khan TU, et al. Influence of surgical flap design (Envelope and Szmyd) for removal of impacted mandibular third molars on clinical periodontal parameters: A clinical trial. *Int J Environ Res Public Health.* 2021;18(9):4465
9. Tamborini F, Baroni T, Garutti L, et al. Superior helical rim reconstruction with a retroauricular perforator transposition flap: The importance of a "lifeboat" vascular supply. *Indian J Plast Surg.* 2021;54(2):240-41
10. Friedman R, Wood VE. The dorsal transposition flap for congenital contractures of the first web space: A 20-year experience. *J Hand Surg Am.* 1997;22(4):664-70
11. Sari E, Tellioglu AT, Altuntas N, et al. Combination of rhomboid flap and double Z-plasty technique for reconstruction of palmar and dorsal web space burn contractures. *Burns.* 2015;41(2):408-12
12. Hough M, Fenn C, Kay SP. The use of free groin flaps in children. *Plast Reconstr Surg.* 2004;113(4):1161-66
13. Lee JH, Choi HJ, Kwak SH, et al. Anterolateral thigh free flaps with T-shaped pedicles and multiple venous anastomosis for extremity reconstruction. *Medicine (Baltimore).* 2021;100(27):e26575